

INTRAOPERATIVE TRANSCRANIAL DOPPLER ULTRASOUND MONITORING OF THE CEREBRAL BLOOD FLOW DURING CAROTID ENDARTERECTOMY, SURGICAL MANAGEMENT OF INTRACRANIAL ANEURYSMS AND CORONARY ARTERY BYPASS GRAFTING

Erih Tetičkovič¹, Marija Menih¹, Kazimir Miksić², Vojko Flis², Gorazd Košir³ and Gorazd Bunc⁴

¹Department of Neurology, ²Department of Vascular Surgery, ³Department of Cardiovascular Surgery, ⁴Department of Neurosurgery; Maribor Teaching Hospital, Maribor, Slovenia

SUMMARY – Intraoperative transcranial Doppler monitoring of intracranial blood flow during carotid endarterectomy, surgical management of intracranial aneurysms and coronary artery bypass grafting is important because it enables recording of the flow in the middle cerebral artery in real time. An adequate blood flow through the middle cerebral artery during carotid endarterectomy allows for selective choice of intraluminal shunt as well as an operation without it, timely identification of cerebral hyperperfusion, vasospasm and hypoperfusion, and detection of cerebral microembolisms, thus minimizing postoperative neurologic complications such as cerebrovascular events or cognitive dysfunction.

Key words: *Aortic diseases – ultrasonography; Coronary artery bypass; Endarterectomy carotid; Ultrasonography – Doppler – transcranial; Monitoring – intraoperative*

Introduction

Intraoperative Doppler imaging of intracranial arteries was first described in 1979 by Nornes and his colleagues¹. They used a pulse device with small probes from 6 to 10 MHz. In 1982, Aaslid *et al.* showed the original access for examination of intracranial circulation using pulse wave Doppler at a low frequency of 2 MHz and placing the probe at the thinnest part of the temporal bone, just above the zygomatic arch, so-called temporal acoustic window². In the last 20 years, transcranial Doppler (TCD) has become a very important noninvasive method for assessment of cerebral hemodynamics, allowing for cerebral flow monitoring, detecting and recording. Results of the intracranial blood flow examination in the middle cerebral artery (MCA) during percu-

taneous transluminal aortic valvuloplasty (PTAV) were first described by Karnik *et al.* in 1985³. Later investigations showed the significant role of TCD monitoring of intracranial blood flow during carotid endarterectomy (CE), surgical management of ruptured aneurysms in subarachnoid hemorrhage (SAH), and open heart operations with and without the use of extracorporeal circulation (ECC). TCD reveals direct changes in cerebral hemodynamics and perfusion, even before secondary metabolic changes, thus providing immediate information during the operation on the possible risks or efficacy of the intervention and enabling decisive therapeutic modifications to be made on time.

Intraoperative Monitoring of Cerebral Flow

In our hospital, we use Translink 8000 Rimed ultrasonic device with 2 MHz probes that are placed on temporal acoustic window for intraoperative recording of blood flow in MCA. Although there are different con-

Correspondence to: *Erih Tetičkovič, MD*, Department of Neurology, Maribor Teaching Hospital, Ljubljanska 5, SI-2000 Maribor, Slovenia
Received May 23, 2005, accepted June 29, 2005

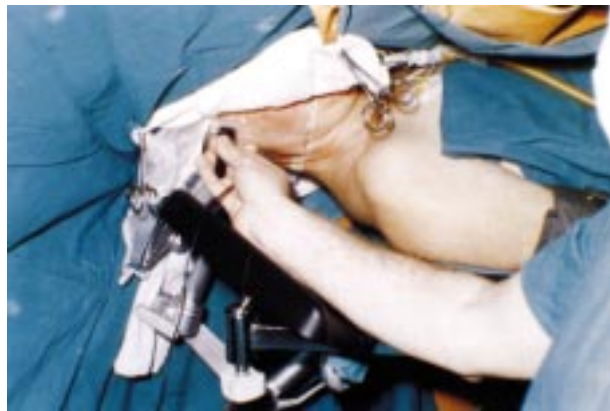


Fig. 1. Manual placing of 2 MHz probe on the temporal acoustic window during intraoperative monitoring of cerebral blood flow.

structions for fixing the probe onto the head, it is necessary to fix the probe on the temporal acoustic window by hand during the operation. In any case, this mode of monitoring requires great physical effort, especially on long lasting operations. We have constructed a special mechanical support to relieve the hand (Fig. 1). We follow cerebral flow in the initial segment (M1) of MCA on the side of operation (CE, SAH), or in coronary artery bypass grafting on the side where we find a hemodynamically significant internal carotid artery (ICA) stenosis. We detect optimal ultrasound signal at 55-60 mm depth from the temporal bone. The mean flow velocity (MFV) is the most significant spectral parameter. Therefore, most authors recommend MFV as a sign for TCD signal⁴. We try to find spectrum also in other arteries of the carotid system, when an initial vasospasm is suspected. In MCA the normal value of MFV is 62 ± 12 cm/s⁵. Experience in TCD monitoring has generally been mostly collected during CE.

TCD Monitoring during Carotid Endarterectomy

In our hospital, the majority of data and experience in TCD monitoring of cerebral blood flow have also been collected during CE. During a 20-year period (1977-1997), we performed 629 CE procedures. We recorded the first TCD monitoring after 1985 and performed 119 TCD monitoring procedures by the end of 1997^{4,6}. As representatives of Slovenia we were included in the Asymptomatic Carotid Surgery Trial (ACST) and performed 44 CE with 29 TCD monitoring procedures during the trial period⁷.

We follow hemodynamic changes in MCA on the side of CE using a modified scheme used by Padayachee *et al.*⁸ MFV in M1 segment of MCA is analyzed in the following phases: basal state; narcosis; preparation of carotid bifurcation; clamping of carotid branches; placing of intraluminal shunt; declamping of carotid branches; end of operation; and 30 minutes after wakening.

Like other authors, we have also observed that following the hemodynamics in MCA is of utmost importance, especially during the operative steps of clamping, intraluminal shunt placement, and declamping of carotid branches⁹. In contrast to previous opinion of vascular surgeons, the clamping of ICA causes only minimal changes of flow in MCA. The placement of intraluminal shunt poses a real risk. About two thirds of patients do not need the shunt. The velocity of 30 cm/s prevents the risk of possible ischemia during clamping of ICA¹. TCD monitoring of MFV in MCA and in combination with somatosensory evoked potentials shows that only the absence of flow in MCA can cause evident changes in somatosensory evoked cortical response. It is well known that the lowest limit for recording flow velocity in MCA is 6 cm/s. This finding presumes that perioperative neurologic deficits are caused by thrombosis and/or embolisms which are connected with the operation. The placement of intraluminal shunt is indicated in situations when TCD shows insufficient flow in MCA (Figs. 2 and 3).

Hyperperfusion syndrome may be a significant complication during and soon after CE; it is more common in patients with a high postoperative risk. In the hyperperfusion syndrome the flow in MCA is increased due to paralysis of the autoregulation, which may more frequently occur in patients with high blood pressure and

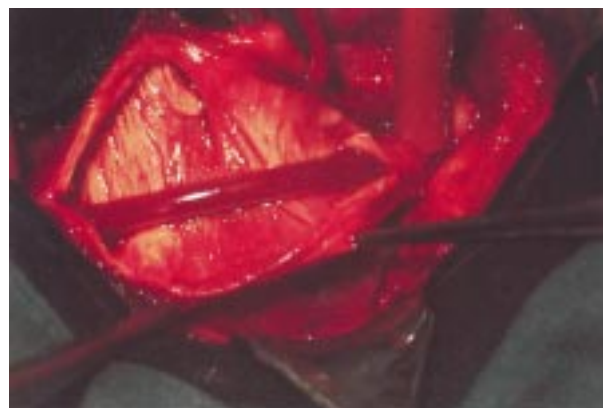


Fig. 2. Intraluminal shunt placement.

subtotal stenosis of ICA. Early detection of hyperperfusion enables introduction of appropriate therapy during the operation and immediately after it. Otherwise, mild postoperative hyperperfusion is a usual finding on TCD monitoring for several days after the operation.

TCD Monitoring during Surgical Therapy for Cerebral Aneurysms

Aneurysmal SAH is a serious disease which can cause numerous secondary complications. Because of the disease heterogeneity, the surgery for aneurysms has been compared with playing the chess. A successful surgeon has to think one step ahead¹⁰, and this is where TCD monitoring can prove highly useful.

A spasm of basal cerebral arteries is a difficult complication that may result from SAH. The incidence of different neurologic complications due to spasm ranges from 2% to 55%¹¹. Experiences until now show that MFV in MCA higher than 120 cm/s is a critical, and MFV higher than 140 cm/s an extremely critical value. These levels of flow velocities often result in ischemic cerebral lesions accompanied by brain edema and elevated intracranial pressure.

TCD monitoring of the cerebral blood flow before and after the operation in situations of aneurysmal SAH is important for offering the possibility of an early detection of the initial vasospasm.

The situation is quite different during intraoperative monitoring because it is not possible to monitor on the same side of the operation. The problem can be

overcome by placing the probe on the opposite acoustic window with a greater depth of insonation to follow the signal from MCA on the same side of the operation (usually at a depth of 85-88 mm). The quality of the ultrasound signal is thus attenuated by about 5%. When can we talk about the initial vasospasm?

According to our experience, the initial vasospasm occurs when MFV in MCA on the side of the operation increases above 90 cm/s, lasts for more than 3 minutes, and increased MFV values are also recorded in other arteries on both the operated and opposite side. This hemodynamic situation represents the moment when we have to immediately initiate therapy with nimodipine in infusion, following a protocol that depends on the degree of the vasospasm¹². It is known that the infusion of nimodipine can dilate the arteries in pia mater in anesthetized cats by 43%¹³.

Many investigations show that nimodipine is successful for prevention of cerebral vasospasm, thus reducing both the mortality and morbidity by 30%-40%¹¹ (Fig. 4). There are interesting hemodynamic changes of MFV in MCA during different operative phases: an increase of MFV in MCA is very often recorded on bone whetting, dura opening, and especially during mechanical irritation of cerebral arteries. This increase of MFV usually lasts for a few seconds up to one minute and represents a local spastic vascular reaction, which can spread to the neighboring region and is over soon upon cessation of mechanical irritation but is not the same as the initial vasospasm¹².

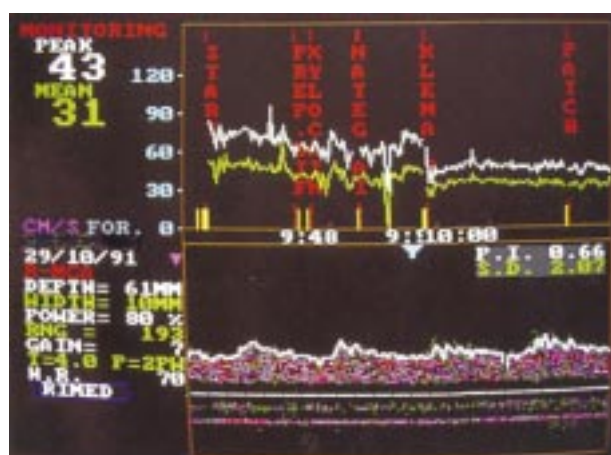


Fig. 3. Intraoperative TCD monitoring after carotid trunk clamping shows sufficient blood flow in ICA, thus enabling carotid endarterectomy without intraluminal shunt.

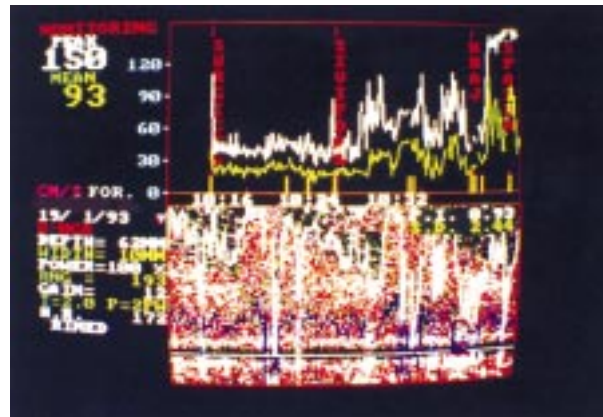


Fig. 4. Initial vasospasm: intraoperative TCD monitoring of blood flow in MCA at the end of surgical procedure shows a rapid increase in the peak flow velocity in systole (white curve) and mean flow velocity (yellow curve). The lower part of the image shows a manifest spectral broadening.

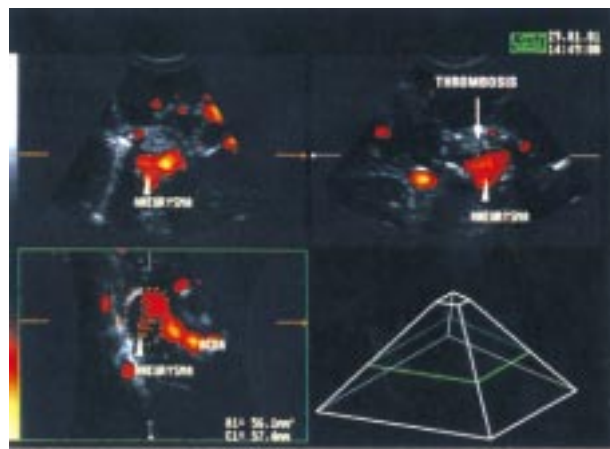


Fig. 5. Direct placing of the intraoperative probe on the aneurysm: analysis of the multiplanar image shows a partly thrombosed aneurysm of a. communicans anterior (ACoA) in all three orthogonal planes.

Three-dimensional ultrasonography (3D-US) offers new diagnostic possibilities during the operation with the use of a special 6-12 MHz probe that can show a cerebral artery, aneurysm or other vascular malformation, and the result of its exclusion from the circulation. 3D-US also allows for detection of an early cerebral vasospasm¹⁴ (Figs. 5 and 6).

TCD Monitoring during Coronary Artery Bypass Grafting

In the end of 2003, we started TCD monitoring of cerebral blood flow in MCA during open heart surgery

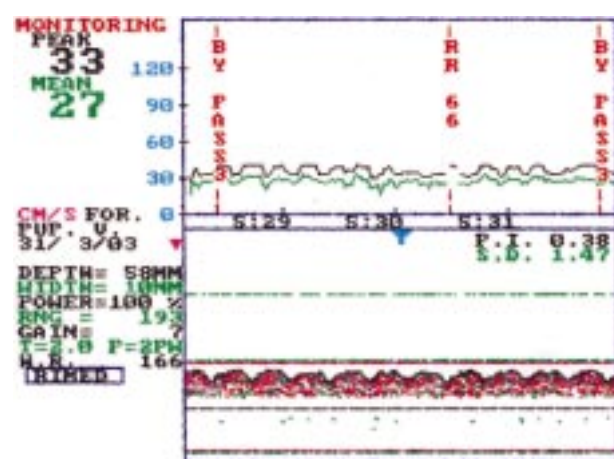


Fig. 7. TCD monitoring during coronary artery bypass grafting (on-pump) shows cerebral hypoperfusion (MFV 27 cm/s).




Fig. 6. CINE-mode of the same aneurysm of ACoA.

and coronary artery bypass grafting (CABG). It is known that the classic operation using ECC, i.e. on-pump operation, results in neurologic complications such as cerebrovascular events in 15%¹⁵ and postoperative cognitive dysfunction in 80%-90% of patients¹⁶. Results of our investigations of 10 on-pump operations and 10 off-pump operations are consistent with other studies reported in the world. Intraoperative recording of hemodynamic changes in MCA shows a higher degree of cerebral hypoperfusion than of cerebral microembolisms, especially in the on-pump group of patients, which showed a significantly higher occurrence of postoperative cognitive dysfunction as compared with the off-pump group. Clinical studies and our experience confirm the theory that postoperative encephalopathy occurs due to criti-

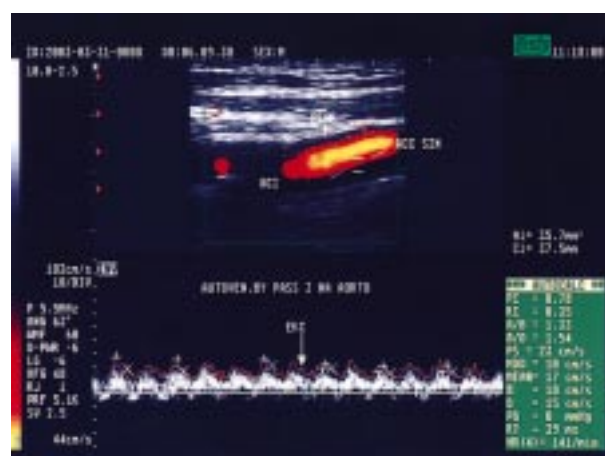


Fig. 8. Blood flow in the carotid trunk in Angio-mode (upper part of the image) and Doppler spectral analysis during on-pump coronary artery bypass grafting.

cal hypoperfusion. Cerebral hyperperfusion may also play a role, with and without the loss of autoregulation (Figs. 7 and 8). Cerebral microembolisms due to air bubbles or atherosclerotic plaque fragments appear to play a minor role. Intraoperative TCD monitoring of the flow in MCA and 3D-US monitoring of the atherosclerotic plaque in ICA on the neck show a portion of the plaque in cerebral microembolisms. Using the special M-mode it is possible to simultaneously record B-image of the bifurcation and special image of ICA, thus enabling visualization of both the blood flow and small air bubbles or plaque particles (Fig. 9). Declamping of the aorta, which is on TCD recorded as a high intensity transient signal (HITS), is associated with a high risk of cerebral microembolism (Fig.10).

Using intraoperative TCD and transesophageal echo (TEE), Barbut *et al.* observed that in patients operated on-pump 84% of HITS occurred during the clamping and declamping of the aorta. The majority of HITS occurred in the first 10 seconds upon declamping^{17,18}. There is a tendency to use TCD and TEE monitoring concurrently. TEE imaging of the ascending aorta directly before the operation enables the choice of a relatively atherosclerotically undisturbed area to place the cannula or clamp. Some authors suggest a special intra-aortic filter to place immediately before the clamping of the aorta to prevent cerebral microembolisms¹⁹.

The rates of hemodynamic changes and clinical post-operative neurologic complications are lower in off-pump operations. That is why off-pump operation should be the method of choice for high risk and elderly patients whenever possible²⁰. Some authors use bidirectional

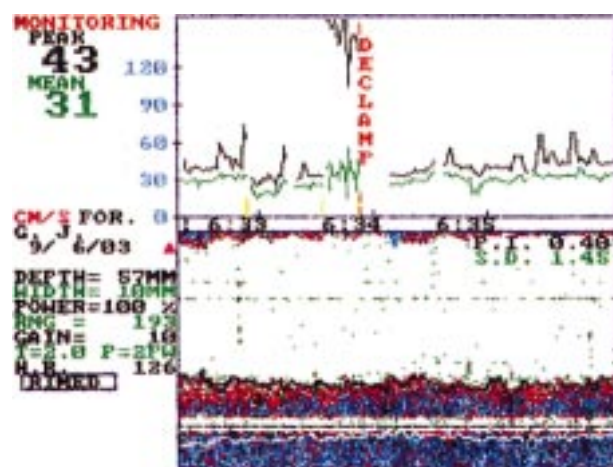


Fig. 9. Intraoperative TCD monitoring reveals HITS immediately after cross-aorta declamping.

TCD monitoring by placing the probes on both temporal acoustic windows, however, most of them place the probe just onto one side of the head. Experiences show that TCD monitoring of intracranial hemodynamics has a high sensitivity (91.8%) at a depth of 55-88 mm²¹.

The new digital devices with power M-mode enable automatic detection of the microembolism.

Conclusion

Intraoperative TCD monitoring of cerebral blood flow in MCA is of utmost importance in the prevention of post-operative neurologic complications, as it allows for selective choice of intraluminal shunt in CE or operation without it, successful shunt placement in the lumen of ICA, and detection of cerebral microembolisms while placing the shunt. During neurosurgical operations for cerebral aneurysms it allows for an early detection of the initial vasospasm, while the special intraoperative 3D probe enables visualization of the aneurysm and of the efficacy of exclusion from the cerebral circulation. During open heart surgery it is important to detect cerebral embolisms, mostly microembolisms during the clamping and declamping of the aorta, and detection of hypoperfusion as the most important issue. Intraoperative finding of the hemodynamic changes described enables immediate decision making on appropriate therapy, thus lowering peri-operative morbidity and mortality.

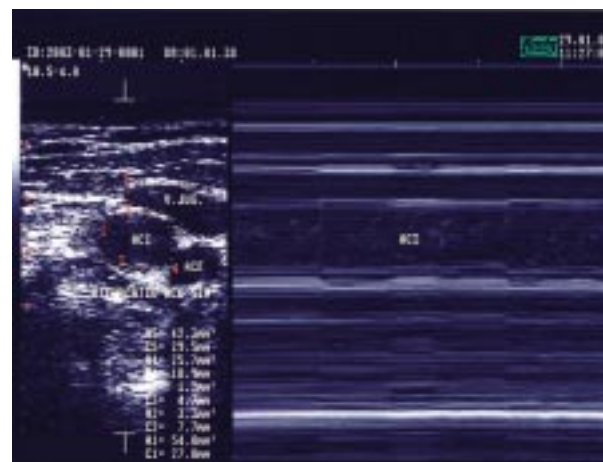


Fig. 10. M-mode immediately after cross-aorta declamping: small hyperechogenic particles are seen in the ICA blood flow (right part of the image), probably originating from atherosclerotic aorta plaques; B-scan shows unchangeable plaque in ICA (left part of the image).

References

1. DEMARIN V. Dijagnostika poremećaja moždanog krvotoka. In: Demarin V *et al.*, eds. Moždani krvotok – klinički pristup. Zagreb: Naprijed, 1994:103-32.
2. AASLID R, MARKWALDER TM, NORNES H. Noninvasive transcranial doppler ultrasound recording of flow velocity in basal cerebral arteries. *J Neurosurg* 1982;57:769-74.
3. KARNIK R, VALUTIN A, BONNER G, ZIEGLER B, SLANY J. Transcranial Doppler monitoring during percutaneous transluminal aortic valvuloplasty. *Angiology* 1990;2:106-11.
4. TETIČKOVIĆ E, MIKSIĆ K, TETIČKOVIĆ S. Transkranielle Dopplersonographie während der Karotisendarterektomie. *Nervenarzt* 1992;63:347-51.
5. DEMARIN V, ŠTIKOVAČ M, THALLER N. Doppler sonografija krvnih žila. Zagreb: Školska knjiga, 1990.
6. MIKSIĆ K, FLIS V, PAVLOVIĆ M, TETIČKOVIĆ E. Karotidna endarterektomija – 20-letne izkušnje. *Med Razgl* 1999;38 (Suppl 5):91-6.
7. FLIS V, MIKSIĆ K, ŠTIRN B, TETIČKOVIĆ E. Prevention of disabling and fatal strokes by successful carotid endarterectomy in patients without recent neurological symptoms: randomised controlled trial. MRC Asymptomatic Carotid Surgery Trial (ACST) Collaborative Group. *Lancet* 2004;363:1491-502.
8. PADAYACHEE TS, GOSLING RG, BISHOP CC, BURNAND K, BROWSE NL. Monitoring middle cerebral artery blood velocity during carotid endarterectomy. *Br J Surg* 1986;73:98-100.
9. BERNSTEIN EF. Role of transcranial Doppler in carotid surgery. *Surg Clin North Am* 1990;70:225-34.
10. MARTI-FABREGAS J, MARTI-VILALTA JL. Primary ventricular haemorrhage. *Rev Neurol* 2000;31:187-91.
11. DORSCH NWC. Cerebral arterial spasm – a clinical review. *Br J Neurosurg* 1995;9:403-12.
12. TETIČKOVIĆ E. Medoperativno ugotavljanje spazma bazalnih možganskih arterij s transkranijskim Dopplerjevo sonografijom pri anevrizmatskih subarahnoidnih krvavitvah. *Med Razgl* 1999;38 (Suppl 5):97-104.
13. MÜCK H. Hirleistungsstörungen im Alter. Pharmakologische Wirkung und therapeutisches Potential des Calciumantagonisten Nimodipin. Stuttgart: Schwe, 1990.
14. LYDEN PD, NELSON TR. Visualization of the cerebral circulation using three-dimensional transcranial power Doppler ultrasound imaging. *J Neuroimaging* 1997;7:35-9.
15. ROACH GW, KANCHUGER M, MANGANO CM, *et al.* Adverse cerebral outcomes after coronary bypass surgery. *N Engl J Med* 1996;335:1857-63.
16. DIEGELERA, HIRSCH R, SCHEIDER F, *et al.* Neuromonitoring and neurocognitive outcome in off-pump *versus* conventional coronary bypass operation. *Ann Thorac Surg* 2000;69:1162-6.
17. BARBUT D, YAO FS, HAGER DN, KAVANOUGH P, TRIFFI-LETTI RR, GOLD JP. Comparison of transcranial Doppler ultrasonography and transesophageal echocardiography to monitor emboli during coronary artery bypass surgery. *Stroke* 1996;27:87-90.
18. SYLVIRIS S, LEVIĆ J, MATALARIS G, *et al.* Pattern and significance of cerebral microemboli during coronary artery bypass grafting. *Ann Thorac Surg* 1998;66:1674-8.
19. HARRINGER W and the International Council of Emboli Management Study Group. Capture of particulate emboli during cardiac procedures in which aortic cross-clamp is used. *Ann Thorac Surg* 2000;70:1119-23.
20. TETIČKOVIĆ E, KOŠIR G, FELSER RAKOVEC Z, BOBIĆIĆ R, MAGDIĆ J. Medoperativno ultrazvučno spremljanje možganskega krvnega pretoka in pooperativno ugotavljanje kognitivne disfunkcije pri operacijah z aortokoronarnimi obvodni. In: TETIČKOVIĆ E, ŽVAN B, eds. Sodobni pogledi na možganskožilne bolezni. Maribor: Obzorja 2003:6-75.
21. GEORGIADIS D, UHLMANN F, ASTHER M, CENCETTI S, ZIERZ S. Automated identification of Doppler microembolic signals: comparison of two techniques. *Neuro Res* 2000;22:738-40.

Sažetak

INTRAOPERACIJSKO PRAĆENJE MOŽDANOG KRVNOG PROTOKA TRANSKRANIJSKIM DOPPLEROM TIJEKOM KAROTIDNE ENDARTEREKTOMIJE, KIRURŠKOG LIJEČENJA MOŽDANIH ANEURIZMA I KORONARNOG PREMOŠĆIVANJA

E. Tetičković, M. Menih, K. Miksić, V. Flis, G. Košir i G. Bunc

Intraoperacijsko praćenje moždanog krvnog protoka transkranijskim Dopplerom za vrijeme karotidne endarterektomije, kirurškog liječenja moždanih aneurizma i koronarnih premoštenja veoma je značajno, jer omogućava promatranje protoka u srednjoj moždanoj arteriji u stvarnom vremenu. Dostatan protok krvi u srednjoj moždanoj arteriji za vrijeme karotidne endarterektomije omogućava selektivan izbor intraluminalog spoja (*shunt*) i operaciju bez njega, pravodobno otkrivanje moždane hiperperfuzije, vazospazma, hipoperfuzije i cerebralnih mikroembolija, što može bitno smanjiti poslijepoperacijske neurološke komplikacije kao cerebrovaskularni incident ili kognitivnu disfunkciju.

Ključne riječi: *Bolesti aorte – ultrasonografija; Premošćenje koronarne arterije; Endarterektomija karotide; Ultrasonografija – Dopplerova – transkranijska; Praćenje – intraoperacijsko*