

ULTRASOUND ENHANCED THROMBOLYSIS FOR STROKE

Andrei V. Alexandrov

Therapeutic Neurosonology Laboratory and the Stroke Research Program, Barrow Neurologic Institute, Phoenix, AZ, USA

SUMMARY – Spontaneous arterial recanalization occurs at a rate of 6% *per* hour, and it can be doubled with intravenous tissue plasminogen activator (TPA) therapy since early dramatic clinical improvement, a substitute for early thrombus break-up, occurs in TPA treated patients. TPA activity can be enhanced with ultrasound including 2 MHz transcranial Doppler (TCD). TCD identifies residual blood flow signals around thrombi, and, by delivering mechanical pressure waves, exposes more thrombus surface to circulating TPA. In the CLOTBUST trial, the dramatic clinical recovery from stroke coupled with complete recanalization within 2 hours after TPA bolus occurred in 25% of patients treated with TPA+TCD compared to 8% of those that received TPA alone ($p=0.02$). Complete clearance of a thrombus and dramatic recovery of brain function during treatment are feasible goals for ultrasound-enhanced thrombolysis that can lead to sustained recovery. An early boost in brain perfusion seen in the CLOTBUST target group resulted in a trend of 13% more patients achieving favorable outcome at 3 months, thus providing the rationale for a pivotal trial. The ability of TPA to break up thrombi can be further enhanced with harmless diagnostic ultrasound contrast agents. Current ongoing clinical trials include phase II studies of 2 MHz TCD with ultrasound contrast agents, or microbubbles: TCD+TPA+Levovist; TCD+TPA+MRX nano-platform (C_3F_8 ImaRx). Intra-arterial ultrasound-enhanced TPA delivery is tested in the Interventional Management of Stroke (IMS) clinical trial using 1.7-2.1 MHz pulsed wave ultrasound catheter (EKOS). Dose escalation studies of microbubbles, ultrasound exposure and the development of an operator independent ultrasound device are currently underway.

Key words: *Cerebrovascular accident – therapy; Thrombolytic therapy; Ultrasonography, Doppler, transcranial – therapy; Fibrinolytic agents – therapeutic use; Thrombolysis – outcomes*

Introduction

In a recent review of observational studies and acute stroke clinical trials, spontaneous arterial recanalization was observed in 17% of patients undergoing angiography between 6 to 8 hours of stroke onset¹. In addition, spontaneous arterial recanalization was estimated to occur at a rate of 6% *per* hour in patients with the middle cerebral artery occlusion who did not receive thrombolytic drugs².

The pilot clinical studies of thrombolysis for ischemic stroke did not document dramatic, or “on the table” clinical recovery during treatment³⁻⁵. Subsequent pivotal

trials of TPA have not reported any differences between the groups at 2 and 24 hours post treatment in the pre-specified end-points⁶⁻⁹. However, a post-hoc analysis of the NINDS trial¹⁰ showed that by 24 hours, 27% of TPA-treated patients improved by ≥ 10 points on the National Institutes of Health Stroke Scale (NIHSS) or resolved their neurological deficit completely compared to 12% in the placebo group ($p=0.002$). Broderick *et al.* found the total NIHSS score of 0-2 points at 24 hours to be the most sensitive measure of successful treatment with iv. TPA predicting good outcome at 90 days¹¹. This early clinical recovery can be indicative of early arterial recanalization and nutritious reperfusion. However, the proportion of treated patients experiencing this dramatic recovery is relatively low.

Early clinical improvement after stroke usually occurs after arterial recanalization¹²⁻¹⁵. Recanalization was

Correspondence to: *Andrei V. Alexandrov, MD*, Therapeutic Neurosonology Laboratory and the Stroke Research Program, Barrow Neurologic Institute, Phoenix, AZ, USA
E-mail: avalexandrov@att.net

Received September 12, 2006, October, 2006

measured in a pilot angiographic study of TPA therapy for stroke but not in the NINDS rt-PA Stroke Study or European Cooperative Stroke Studies⁶⁻⁹. Since early recanalization can lead to dramatic recovery¹²⁻¹⁵, any additional enhancement of TPA-associated thrombus dissolution, with increased early arterial recanalization rates should, in theory, produce even higher early dramatic recovery rates among patients with ischemic stroke.

The rationale for use of a mechanical pressure wave, i.e. ultrasound, to enhance thrombolysis was first observed and recognized in the 1970s¹⁶ and 1980s¹⁷, and confirmed by several investigators using various experimental models¹⁸⁻²¹. A simple analogy is that if you put sugar in a cup of water, sugar promptly goes down to the bottom, and it will take some time for it to dissolve completely since there is no water motion. However, if you stir water with a spoon, the sugar dissolves much faster.

Ultrasound, as its pressure wave propagates through the tissues, induces fluid motion and facilitates delivery of TPA to reach the binding sites on clot bound fibrin. Researchers have proposed three different mechanisms of ultrasound-enhanced thrombolysis: (a) fluid streaming around clot surface; (b) disaggregation of non cross-linked fibrin fibers; and (c) creating more binding sites for TPA without heating or cavitation^{23,24} (Fig. 1). Low kilohertz (kHz) frequencies are better at potentiating TPA effects than are higher frequencies²⁵. However, these systems are not available for clinical practice due to safety concerns and inability to image vasculature with this frequency/wavelength range. Fortunately, the carrier frequency range that is safely used for diagnostic ultrasound examinations, 1-2.2 MHz, can enhance TPA-induced thrombus dissolution^{23,24}, although the optimal frequency has not been determined.

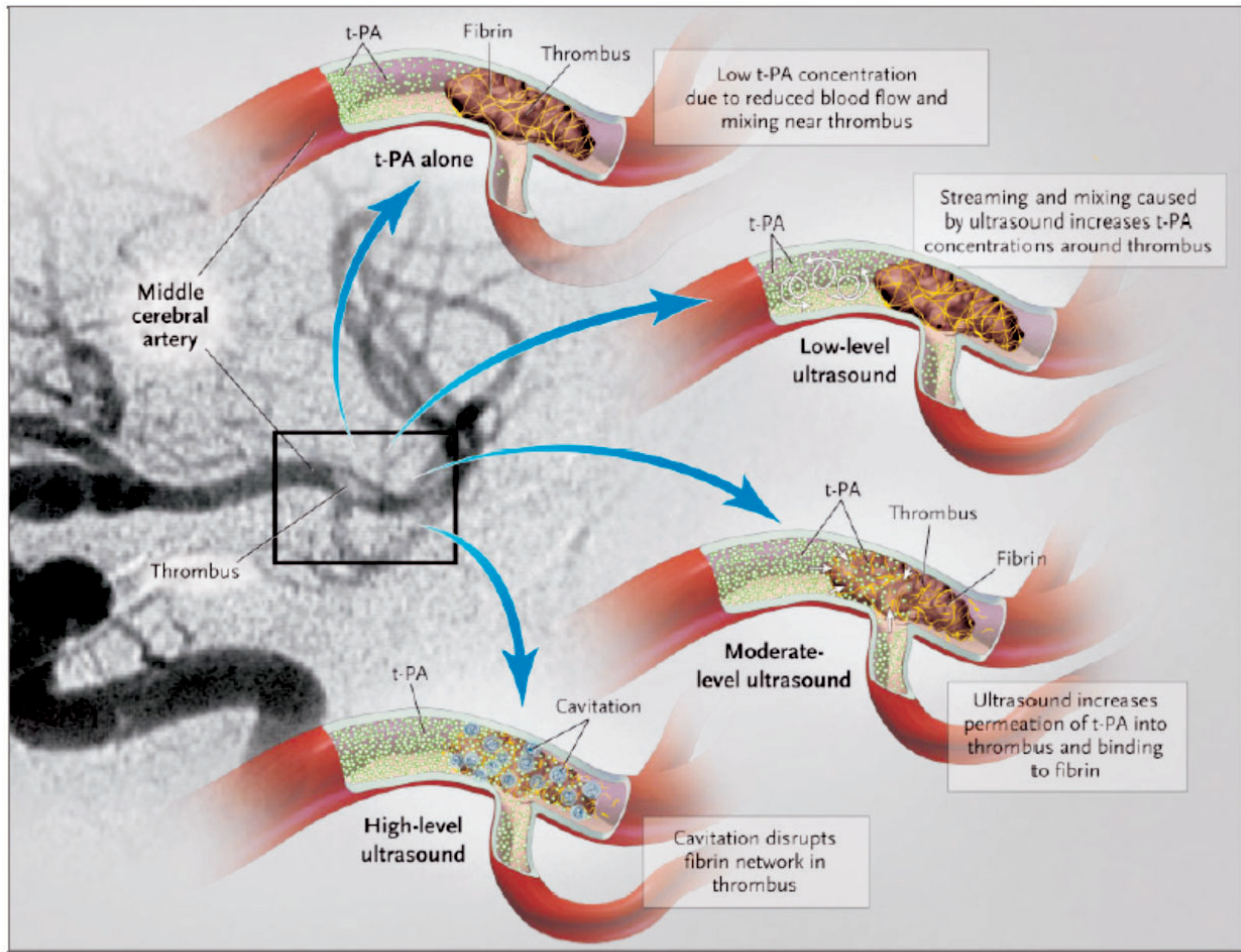


Fig. 1. Potential mechanisms of ultrasound-enhanced thrombolysis (reproduced with permission from Polak JF. *N Engl J Med* 2004;351:2154-5).

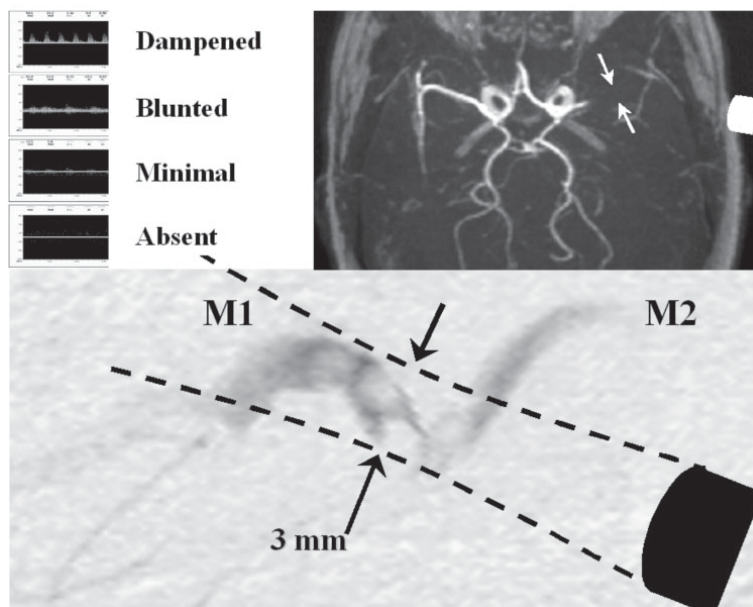


Fig. 2. Abnormal arterial residual flow signals sampled from thrombus-residual flow interface (arrows) at the site of an acute thromboembolic MCA occlusion (reprinted with permission from Alexandrov AV. *Ultrasound identification and lysis of clots. Stroke* 2004;35(Suppl 1):2722-5).

Portable diagnostic 2 MHz TCD equipment can be used in the emergency room to rapidly identify the presence and location of an arterial occlusion, or lesions amenable to intervention²⁶, and to continuously monitor TPA infusion in acute ischemic stroke patients²⁷. With prior training and experience in interpretation of TCD, this test, particularly in combination with urgent carotid/vertebral duplex scanning, can yield high degrees of accuracy for detection and localization of arterial occlusion as well as assessment of recanalization at the bedside^{26,27}.

The diagnosis of an acute arterial obstruction to flow and subsequent recanalization depends on finding abnormal residual flow and signs of compensatory flow diversion²⁶. Once abnormal residual flow signals are identified, an ultrasound beam can be steadily focused at the presumed intracranial thrombus location (Fig. 2), and arterial recanalization can be monitored in real time²⁵. When intravenous TPA infusion was continuously monitored with 2 MHz TCD²⁷, we observed early recanalization and dramatic recovery rates higher than expected from pivotal trials³. This non-randomized study of patients treated with different TPA doses²⁷ suggested a potential therapeutic effect of TCD, which led to a prospective randomized pilot clinical trial.

The CLOTBUST Trial

The CLOTBUST (Combined Lysis of Thrombus in Brain ischemia using transcranial Ultrasound and Sys-

temic TPA) was a phase II clinical randomized multicenter international pilot trial with centers in Houston, Barcelona, Edmonton, and Calgary²⁸. It had pre-specified safety and signal of efficacy end-points and a pre-determined sample size of 63 patients *per group*²⁸. All enrolled patients had an acute ischemic stroke, and were treated with a standard 0.9 mg/kg dose of intravenous TPA therapy within 3 hours of symptom onset. All patients also had MCA occlusions on pretreatment TCD. They were randomized (1:1) to continuous TCD monitoring (target) or placebo monitoring (control). The primary safety end-point was symptomatic brain hemorrhage (sICH) causing worsening of the neurological deficit by 4 or more NIHSS points. The primary combined clinical outcome end-point was complete recanalization on TCD or dramatic clinical recovery, by the total NIHSS score ≤ 3 points or improvement by ≥ 10 NIHSS points within 2 hours after TPA bolus. Clinical investigators were blinded to group assignment (active or sham monitoring) done by sonographers.

All projected 126 patients received TPA and were randomized 1:1 to target (median pretreatment NIHSS 16 points) or control (NIHSS 17 points). Age, occlusion location on TCD and time to TPA bolus were similar between the groups. sICH occurred in 4.8% of target and 4.8% of control patients. Primary end-point was achieved by 31 (49%, target) *vs.* 19 (30%, control) ($p=0.03$) patients. At 3 months, 42% target and 29% control patients achieved favorable outcomes (mRS 0-1 points) ($p=NS$) (Fig. 3). This trend in favorable clinical

cal outcomes supports the feasibility of a pivotal phase III clinical trial that, with 274 patients *per* group, would be properly powered (80% or 90%?) to detect this difference in outcomes at 3 months²⁸.

Other Clinical Trials

Transcranial duplex technology was recently tested in a smaller randomized clinical trial²⁹. Duplex transducers are different from the ones used in CLOTBUST since they generate multiple small beams at dual emitting frequencies, one for Doppler and one for gray scale imaging. One of the major limitations of this technology is that there are no reliable head frames for transducer fixation, and most studies are to be carried out handheld.

Eggers *et al.* evaluated 25 patients (11 target TPA+ duplex monitoring, 14 controls TPA alone) and reported a trend in the target group towards higher recanalization rates, more hemorrhagic transformations, and better outcomes at 3 months compared to patients who received TPA alone²⁹. This study did not have a predetermined sample size, and the results may have been affected by a small number of patients enrolled. More studies are needed to evaluate the potential of transcranial duplex technology to enhance thrombolysis.

The same group and others³⁰⁻³² have reported provocative findings that patients who are not eligible for systemic TPA therapy may potentially benefit from continuous monitoring with ultrasound alone since, hypothetically, ultrasound may help facilitate the endogenous thrombolytic process that leads to spontaneous recanalization in acute stroke patients. It is unclear if only partial recanalization can be induced by ultrasound alone, and if this exposure would result in a significant difference at 3 months justifying a large clinical trial.

Therapeutic, i.e. non-imaging ultrasound has been tested in the TRanscranial low-frequency Ultrasound-Mediated thrombolysis in Brain Ischemia (TRUMBI) trial³³. Patient enrollment was stratified by time of symptom onset, 0-3 hours and 3-6 hours. In addition, the investigators used a very low KHz system (<40 KHz) that produced intolerable tinnitus and was withdrawn from clinical testing (Daffertshofer M, unpublished data). It was replaced by a mid-KHz system operating at 300 KHz. Brain hemorrhage was defined by findings on both CT and MRI scans mandated by the trial. The trial was terminated after 26 patients were enrolled with a 36% rate of symptomatic hemorrhage in the target group and no signal of efficacy on early recanalization or clinical outcomes at 3 months³⁴. The trial demonstrated bio-effects of mid-KHz ultrasound that promoted bleeding,

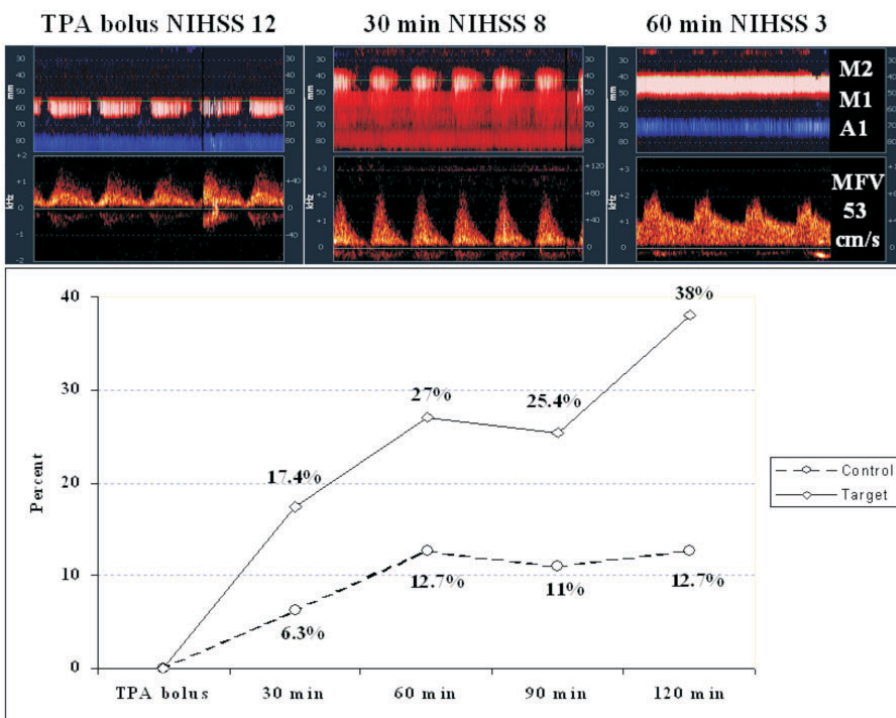


Fig. 3. Upper panel: complete MCA recanalization on power-motion TCD and dramatic clinical recovery within 60 minutes of TPA bolus; lower panel: early recanalization rates with ultrasound-enhanced TPA therapy for acute thromboembolic MCA occlusion in the CLOTBUST trial (re-printed with permission from Alexandrov AV. Ultrasound identification and lysis of clots. Stroke 2004;35(Suppl 1):2722-5).

including brain areas not affected by ischaemia³³. However, the results were unclear as to the exact timing of the brain hemorrhages. Further research should determine if “standing” pressure waves and endothelial disruption may cause these adverse effects. If confirmed in *in vivo* models, this will have implications on the design of future KHz-based systems.

Ultrasound transducers have also been incorporated into a catheter for intra-arterial delivery of a thrombolytic drug (EKOS Corporation). This intra-arterial device uses 1.7-2.1 MHz pulsed wave ultrasound with the emitting power of 400 mW, parameters similar to extracranially applied transcranial Doppler. The EKOS catheter is now being tested in phase II-III Interventional Management of Stroke (IMS) trials³⁵.

Future Directions

Different experimental strategies are being tested in an extended time window for acute stroke treatment. Continuous, short duration exposure to ultrasound may find its application while the patient may be receiving other agents such as glycoprotein IIb-IIIa receptor antagonists, direct thrombin inhibitors or is awaiting an endovascular recanalization procedure (pharmacologic or mechanical).

Ultrasound-enhanced thrombolysis can be further amplified by adding gaseous microbubbles³⁶⁻³⁹. Microbubbles, safe ultrasound contrast agents, are micron-sized lipid shells that when exposed to ultrasound, expand and produce stable cavitation with stronger reflected echoes. This is used to generate ultrasound images with better resolution. At the same time, microbubbles agitate fluid where they are released by ultrasound and this is useful in drug delivery and mechanical “grinding” of a thrombus. In fact, microbubbles have their own ability to lyse thrombi without a lytic drug³⁹.

Several studies have been reported with different types of commercially available microbubbles⁴⁰. Molina *et al.* report on the largest study to date that compared the CLOTBUST target arm to the CLOTBUST target insonation protocol combined with Levovist air microbubbles (Schering AG)³⁸. Investigators demonstrated that at 2 hours after TPA bolus the TPA+TCD +Levovist group achieved a 55% sustained recanalization rate compared to 38% in the TPA+TCD group of the CLOTBUST trial. An international multi-center study of a new and more stable C₃F₈ microbubble, MRX 815 nano-platform, is underway⁴¹.

One technical problem that may limit the development of ultrasound and microbubble assisted stroke therapies is the need of an experienced sonographer to find intracranial thrombus, and expose its surface to residual flow in order to lodge more TPA and agitate stagnant flow. Personnel with these skills are lacking in most emergency centers. Future studies will focus on finding the optimal frequency and duration of exposure to ultrasound⁴² as well as the development of an operator-independent ultrasound device that can be used by existing medical personnel regardless of their experience in diagnostic ultrasound.

Acknowledgment

CLOTBUST studies are Investigator Sponsored Clinical Trials (MRX-815 Nano-platform, ImaRx Therapeutics, Inc, A2207s, Genentech, Inc, NIH 1 K23 NS-02229-01 grant to Dr Alexandrov). Study sites include Houston, Barcelona, Phoenix, Heidelberg, Charlotte, Calgary, and Edmonton.

References

1. KASSEM-MOUSSA H, GRAFFAGNINO C. Nonocclusion and spontaneous recanalization rates in acute ischemic stroke: a review of cerebral angiography studies. *Arch Neurol* 2002;59:1870-3.
2. ALEXANDROV AV, BLADIN CF, NORRIS JW. Intracranial blood flow velocities in acute ischemic stroke. *Stroke* 1994;25:1378-83.
3. del ZOPPO GJ, POECK K, PESSIN MS, WOLPERT SM, FURLAN AJ, FERBERT A, ALBERTS MJ, ZIVIN JA, WECHSLER L, BUSSE O, GREENLEE R, BRASS L, MOHR JP, FELDMANN E, HACKE W, KASE CS, BILLER J, GRESS D, OTIS SM. Recombinant tissue plasminogen activator in acute thrombotic and embolic stroke. *Ann Neurol* 1992;32:78-86.
4. BROTT TG, HALEY EC, LEVY DE *et al.* Urgent therapy for stroke. Part I pilot study of tissue plasminogen activator administered within 90 minutes. *Stroke* 1992;23:632-40.
5. HALEY EC, LEVY DE, BROTT TG *et al.* Urgent therapy for stroke. Part II pilot study of tissue plasminogen activator administered 91-180 minutes from onset. *Stroke* 1992;23:641-5.
6. The National Institutes of Neurological Disorders and Stroke rt-PA Stroke Study Group. Tissue plasminogen activator for acute ischemic stroke. *N Engl J Med* 1995;333:1581-7.
7. HACKE W, KASTE M, FIESCHI C *et al.* Intravenous thrombolysis with recombinant tissue plasminogen activator for acute ischemic stroke: the European Cooperative Acute Stroke Study. *JAMA* 1995;274:1017-25.
8. HACKE W, KASTE M, FIESCHI C *et al.* Randomised double-blind placebo-controlled trial of thrombolytic therapy with intravenous alteplase in acute ischemic stroke (ECASS II):

- Second European-Australasian Acute Stroke Study Investigators. *Lancet* 1998;352:1245-51.
9. HACKE W, DONNAN G, FIESCHI C, KASTE M, von KUMMER R, BRODERICK JP, BROTT T, FRANKEL M, GROTTA JC, HALEY EC Jr, KWIATKOWSKI T, LEVINE SR, LEWANDOWSKI C, LU M, LYDEN P, MARLER JR, PATEL S, TILLEY BC, ALBERS G, BLUHMKI E, WILHELM M, HAMILTON S; ATLANTIS Trials Investigators; ECASS Trials Investigators; NINDS rt-PA Study Group Investigators. Association of outcome with early stroke treatment: pooled analysis of ATLANTIS, ECASS, and NINDS rt-PA stroke trials. *Lancet* 2004;363:768-74.
 10. HALEY EC, LEWANDOWSKI C, TILLEY BC. Myths regarding NINDS rt-PA Stroke Trial: setting the record straight. *Ann Emerg Med* 1997; 30:676-82.
 11. BRODERICK JP, LU M, KOTHARI R, LEVINE SR, LYDEN PD, HALEY EC, BROTT TG, GROTTA JC, TILLEY BC, MARLER JR, FRANKEL M. Finding of the most powerful measures of the effectiveness of tissue plasminogen activator in the NINDS tPA Stroke trial. *Stroke* 2000;31:2335-41.
 12. DEMCHUK AM, FELBERG RA, ALEXANDROV AV. Clinical recovery from acute ischemic stroke after early reperfusion of the brain with intravenous thrombolysis. *N Engl J Med* 1999;340:894-5.
 13. GROTTA JC, ALEXANDROV AV. TPA-associated reperfusion in acute ischemic stroke demonstrated by SPECT. *Stroke* 1998;29:429-32.
 14. HEISS W-D, GROND M, THIEL A, von STOCKHAUSEN H-M, RUDOLF J, GHAEMI M, LOTTGEN J, STENZEL C, PAWLIK G. Tissue at risk of infarction rescued by early reperfusion: a positron emission tomography study in systemic recombinant tissue plasminogen activator thrombolysis of acute stroke. *J Cereb Blood Flow Metab* 1998;18:1298-307.
 15. RINGELSTEIN EB, BINIEK R, WEILLER C, AMMELING B, NOLTE PN, THRON A. Type and extent of hemispheric brain infarctions and clinical outcome in early and delayed middle cerebral artery recanalization. *Neurology* 1992;42:289-98.
 16. TRUBESTEIN R, BERNARD HR, ETZEL F, SOBBE A, CREMER A, STUMPF U. Thrombolysis by ultrasound. *Clin Sci Mol Med* 1976;51:697-8.
 17. TACHIBANA K, TACHIBANA S. Ultrasonic vibration for boosting fibrinolytic effects of urokinase *in vivo*. *Thromb Haemost* 1981;46:211. (abstract)
 18. LAUER CG, BURGE R, TANG DB, BASS BG, GOMEZ ER, ALVING BM. Effect of ultrasound on tissue-type plasminogen activator-induced thrombolysis. *Circulation* 1992;86:1257-64.
 19. KIMURA M, IJIMA S, KOBAYASHI K, FURUHATA H. Evaluation of the thrombolytic effect of tissue-type plasminogen activator with ultrasound irradiation: *in vitro* experiment involving assay of the fibrin degradation products from the clot. *Biol Pharm Bull* 1994;17:126-30.
 20. AKIYAMA M, ISHIBASHI T, YAMADA T, FURUHATA H. Low-frequency ultrasound penetrates the cranium and enhances thrombolysis *in vitro*. *Neurosurgery* 1998;43:828-32.
 21. SUCHKOVA V, SIDDIQI FN, CARSTENSEN EL, DALECKI D, CHILD S, FRANCIS CW. Enhancement of fibrinolysis with 40-kHz ultrasound. *Circulation* 1998;98:1030-5.
 22. BEHRENS S, DAFFERTSHOFFER M, SPIEGEL D, HENNERICI M. Low-frequency, low-intensity ultrasound accelerates thrombolysis through the skull. *Ultrasound Med Biol* 1999;25:269-73.
 23. BEHRENS S, SPENGOS K, DAFFERTSHOFER M, SCHROECK H, DEMPFFLE CE, HENNERICI M. Transcranial ultrasound-improved thrombolysis: diagnostic *vs.* therapeutic ultrasound. *Ultrasound Med Biol* 2001;27:1683-9.
 24. BLINC A, FRANCIS CW, TRUDNOWSKI JL, CARSTENSEN EL. Characterization of ultrasound-potentiated fibrinolysis *in vitro*. *Blood* 1993;81:2636-43.
 25. SPENGOS K, BEHRENS S, DAFFERTSHOFER M, DEMPFFLE CE, HENNERICI M. Acceleration of thrombolysis with ultrasound through the cranium in a flow model. *Ultrasound Med Biol* 2000;26:889-95.
 26. CHERNYSHEV OY, GARAMI Z, CALLEJA S, SONG J, CAMPBELL MS, NOSER EA, SHALTONI H, CHEN CI, IGUCHI Y, GROTTA JC, ALEXANDROV AV. The yield and accuracy of urgent combined carotid-transcranial ultrasound testing in acute cerebral ischemia. *Stroke* 2005;36:32-7.
 27. ALEXANDROV AV, DEMCHUK AM, FELBERG RA, CHRISTOU I, BARBER PA, BURGINS WS, MALKOFF M, WOJNER AW, GROTTA JC. High rate of complete recanalization and dramatic clinical recovery during TPA infusion when continuously monitored by 2 MHz transcranial Doppler monitoring. *Stroke* 2000;31:610-4.
 28. ALEXANDROV AV, MOLINA CA, GROTTA JC, GARAMI Z, FORD SR, ALVAREZ-SABIN J, MONTANER J, SAQQUR M, DEMCHUK AM, MOYE LA, HILL MD, WOJNER AW. Ultrasound-enhanced systemic thrombolysis for acute ischemic stroke. *N Engl J Med* 2004;351:2170-8.
 29. EGGERS J, KOCH B, MEYER K, KONIG I, SEIDEL G. Effect of ultrasound on thrombolysis of middle cerebral artery occlusion. *Ann Neurol* 2003;53:797-800.
 30. EGGERS J, SEIDEL G, KOCH B, KONIG IR. Sonothrombolysis in acute ischemic stroke for patients ineligible for rt-PA. *Neurology* 2005;64:1052-4.
 31. CINTAS P, Le TRAON AP, LARRUE V. High rate of recanalization of middle cerebral artery occlusion during 2-MHz transcranial color-coded Doppler continuous monitoring without thrombolytic drug. *Stroke* 2002;33:626-8.
 32. SKOLOUDI D, BAR M, HRADILEK P, VACLAVIK D, SKODA O. Safety and efficacy of thrombotripsy – acceleration of thrombolysis by TCCS. CD-ROM Proceedings of the NSRG 2003 Meeting, Germany.
 33. DAFFERTSHOFFER M, HENNERICI M. Ultrasound in the treatment of ischaemic stroke. *Lancet Neurology* 2003;2:283-90.
 34. DAFFERTSHOFER M, GASS A, RINGLEB P, SITZER M, SLIWKA U, ELS T, SEDLACZEK O, KOROSHETZ W, HENNERICI MG. Transcranial low-frequency ultrasound-

- mediated thrombolysis in brain ischemia: increased risk of hemorrhage with combined ultrasound and tissue plasminogen activator. *Stroke* 2005;36:1441-6.
35. The IMS Study Investigators. Combined intravenous and intra-arterial recanalization for acute ischemic stroke: The Interventional Management of Stroke Study. *Stroke* 2004;35: 904-12.
 36. UNGER EC, PORTER T, CULP W, LABELL R, MATSUNAGA T, ZUTSHI R. Therapeutic applications of lipid-coated microbubbles. *Adv Drug Deliv Rev* 2004;56:1291-314.
 37. CULP WC, PORTER TR, McCOWAN TC, ROBERTSON PK, JAMES CA, MATCHETT WJ, MOURSI M. Microbubble-augmented ultrasound declotting of thrombosed arteriovenous dialysis grafts in dogs. *J Vasc Interv Radiol* 2003;14:343-7.
 38. MOLINA CA, RIBO M, ARENILLAS J, RUBIERA M, MONTANER J, SANTAMARINA E, HUERTAS R, DEALGADO P, PURROY F, ALVAREZ-SABIN J. Microbubbles administration accelerates clot lysis during continuous 2 MHz ultrasound monitoring in stroke patients treated with intra-venous tPA. *Stroke* 2005;36:419. (abstract).
 39. CULP WC, PORTER TR, LOWERY J, XIE F, ROBERSON PK, MARKY L. Intracranial clot lysis with intravenous microbubbles and transcranial ultrasound in swine. *Stroke* 2004;35:2407-11.
 40. MARTINA AD, MEYER-WIETHE K, ALLEMANN E, SEIDEL G. Ultrasound contrast agents for brain perfusion imaging and ischemic stroke therapy. *J Neuroimaging* 2005; 15:217-32.
 41. http://www.imarx.com/ImaRx/thera4_0
 42. SLOAN MA, ALEXANDROV AV, TEGELER CH, SPENCER MP, CAPLAN LR, FELDMANN E, WECHSLER LR, NEWELL DW, GOMEZ CR, BABIKIAN VL, LEFKOWITZ D, GOLDMAN RS, ARMON C, HSU CY, GOODIN DS. Assessment: transcranial Doppler ultrasonography: report of the Therapeutics and Technology Assessment Subcommittee of the American Academy of Neurology. *Neurology* 2004;62:1468-81.

Sažetak

ULTRAZVUKOM POJAČANA TROMBOLIZA KOD MOŽDANOG UDARA

A.V. Alexandrov

Spontana arterijska rekanalizacija odvija se po stopi od 6% na sat, što se može udvostručiti pomoću terapije intravenskim aktivatorom tkivnog plazminogena (TPA), jer u bolesnika liječenih pomoću TPA dolazi do ranog dramatičnog kliničkog poboljšanja kao nadomjestak za rano razbijanje tromba. Aktivnost TPA može se pojačati ultrazvukom uključujući transkranijalni Doppler (TCD) od 2 MHz. TCD identificira signale ostatnog krvnog protoka oko trombusa te kroz stvaranje valova mehaničkog tlaka izlaže veću površinu tromba cirkulirajućem TPA. U pokusu CLOTBUST je značajan klinički oporavak od moždanog udara uz potpunu rekanalizaciju unutar 2 sata od davanja bolusa TPA nastupio u 25% bolesnika liječenih pomoću TPA+TCD, u usporedbi s 8% bolesnika koji su primili samo TPA (p=0,02). Potpuno uklanjanje tromba i značajan oporavak moždane funkcije tijekom liječenja izvedivi su ciljevi ultrazvukom pojačane trombolize koji mogu dovesti do održivog oporavka. Kao rezultat ranog stimuliranja moždane perfuzije, zabilježenog u ciljnoj skupini studije CLOTBUST, 13% više bolesnika postiglo je povoljan ishod nakon 3 mjeseca, pruživši time razlog za ključni pokus. Sposobnost TPA da razbije trombe može se dodatno pojačati neškodljivim dijagnostičkim kontrastnim sredstvima za ultrazvuk. Upravo su u tijeku kliničke studije 2. faze s kontrastnim sredstvima za ultrazvuk od 2 MHz ili mikrokuglicama TCD+TPA+Levovist; TCD+TPA+MRX nano-platforma (C₃F₈ ImaRx). Intraarterijsko davanje TPA pojačano ultrazvukom ispituje se u kliničkom pokusu Interventional Management of Stroke (IMS) uz primjenu ultrazvučnog katetera pulsni valova od 1,7-2,1 MHz (EKOS). U tijeku su studije pojačavanja mikrokuglica, izlaganja ultrazvuku, kao i razvoj ultrazvučnog uređaja neovisnog o operatoru.

Ključne riječi: *Cerebrovaskularni incident – terapija; Trombolitična terapija; Ultrazvuk, Doppler, transkranijalni – terapija; Fibrinolitična sredstva – terapijska primjena; Tromboliza – ishodi*