

## CONTACT ALLERGIC SENSITIVITY TO *CLOSTRIDIUM* PEPTIDASE WITH CHLORAMPHENICOL IN A PATIENT WITH VENOUS LEG ULCER

Mirna Tomljanović-Veselski<sup>1</sup> and Ines Zelić<sup>2</sup>

<sup>1</sup>Department of Dermatology and Venereology, Dr. Josip Benčević General Hospital, Slavonski Brod; <sup>2</sup>Private Family Practice, Bukovlje, Croatia

**SUMMARY** – Contact dermatitis caused by topical drugs is rather common all over the world. A case is presented of a 76-year-old female patient with venous leg ulcer, who developed contact sensitivity to *Clostridium* peptidase with chloramphenicol, i.e. Iruxol, a topical antiulcerative used for years for leg lesions. Patch testing confirmed sensitivity to Iruxol, and specific testing for chloramphenicol confirmed sensitivity to the antibiotic component of the ointment. Contact allergic dermatitis is a very common disease in patients with lower limb ulcer and venous hypostatic dermatitis.

**Key words:** *Leg ulcer – drug therapy; Dermatologic agents – adverse effects; Dermatitis, allergic-contact – etiology; Dermatitis, allergic-contact – diagnosis; Patch tests; Case report*

### Introduction

Long-term topical application of medicines frequently induces contact allergic dermatitis (CAD) all over the world. CAD may occur as a typical medicamentous eruption radiating centrifugally from the center, or as a medicamentous reaction of the urticarial, irritative, phototoxic, lichenoid, exudative erythema or dermatophytosis type. CAD develops as a delayed sensitivity reaction, where Langerhans cells and hapten-specific lymphocytes secreting specific cytokines play a major role<sup>1</sup>.

Contact allergic sensitivity superimposed on a previous dermatosis frequently proceeds unrecognized. The predilection sites for CAD are skin areas more frequently exposed to medication or occlusion, and previous skin lesions. CAD is typically underlain by a chronic cutaneous disease such as atopic dermatitis, or by venous ulcer, when multiple medications are applied while the condition is worsening. It is especially pronounced in

case of frequent use of antibiotic ear drops, suppositories and topical antiulceratives<sup>2</sup>.

Iruxol (*Clostridium* peptidase and chloramphenicol) is a dermatopharmaceutical containing a proteolytic enzyme and an antibiotic, used in the treatment of wounds and skin lacerations for enzymatic clearance of necrotic, fibrin and purulent deposits. *Clostridium* peptidase A is a collagenase produced by fermentation of *Clostridium histolyticum*. Chloramphenicol is a low-molecular, broad-spectrum, mostly lipophilic antibiotic from the group of amphenicols, suitable for cutaneous application.

### Case Report

A 76-year-old female patient had been treated for varicose veins and intermittent occurrence of leg lesions for some ten years. During this period, she had used various topical preparations in the form of compresses, ointments and creams, including Iruxol ointment. Patient history revealed frequent use of Chloramphenicol ointment for ocular lesions some ten years before. Four months before presentation to the hospital, a lesion opened on the left leg (Fig. 1). The use of various topi-

Correspondence to: *Mirna Tomljanović-Veselski, MD*, Department of Dermatology and Venereology, Dr. Josip Benčević General Hospital, Ul. Andrije Štampara 42, HR-35000 Slavonski Brod, Croatia

Received June 29, 2006, accepted in revised form August 21, 2006

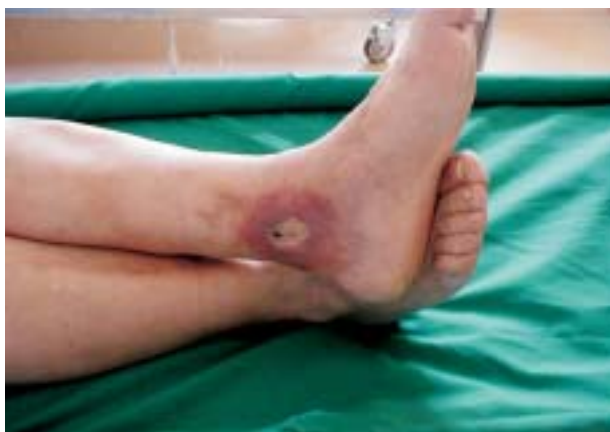

Fig. 1. Venous ulcer.

cal agents failed to produce any substantial improvement, thus the patient was hospitalized. Upon admission, Iruzol ointment was applied, however, in several hours the patient started complaining of severe prickling and itching in the area of the lesion. Pruritus at the site of ointment application turned ever more severe, the patient reported a strong sensation of burning, and the ointment was removed, revealing severe rubor of the area around the lesion. The treatment was continued with the application of alginate compresses. In two weeks, partial epithelialization of the lesion occurred, the lesion size and depth were reduced by half, and the surrounding skin gradually regained normal appearance. Control examination in one month showed complete epithelialization of the lesion, with a residual hypopigmented scar.

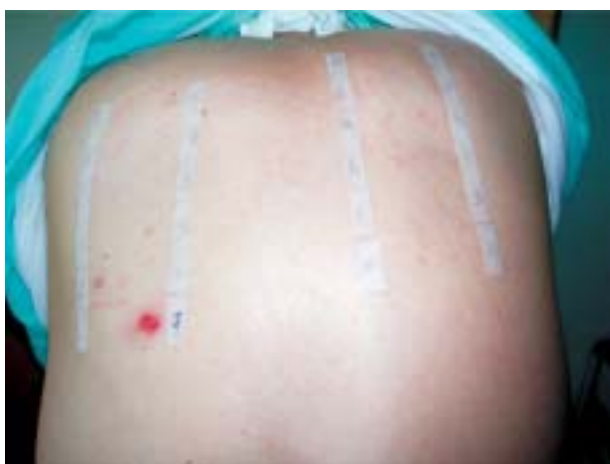

Fig. 2. Patch testing to a standard allergen panel and Iruzol ointment.

On one-month control visit, the patient underwent patch testing to standard allergen panel and Iruzol ointment. A strongly positive reaction (+++) to Iruzol was seen on the skin of the back (Fig. 2). Repeat patch testing to a target panel consisting of ten topical medications frequently used in the management of leg lesions, other dermatoses and skin conditions (e.g., varicose veins) was performed in two weeks. The test panel consisted of chloramphenicol (Chloramphenicol ung.), gentamicin (Garamycin ung.), mupirocin (Betrion ung.), silver sulfadiazine (Dermazin cream), chloramphenicol + *Clostridium* peptidase (Iruzol ung.), hydrocortisone + oxytetracycline (Geokorton ung.), betamethasone dipropionate + gentamicin (Belogent ung.), clotrimazole (Plimycol cream), heparin (Heparin gel), and bacitracin + neomycin (Bivacyn ung.) (Fig. 3). These tests yielded a strong positive reaction to Iruzol and to chloramphenicol ointment alone.

### Discussion

Contact allergic dermatitis has for years been recognized in patients with venous ulcers and hypostatic dermatitis, thus being widely investigated in numerous studies. A great variety of preparations in the form of ointment, powder, compression, etc. are applied directly onto the lesion and irritated skin around the lesion, thus many potent allergens coming in contact with open wound and its macerated surrounding. In addition, occlusion of the lesion and adjacent skin contributes to producing favorable conditions for allergen absorption and development of contact sensitivity.

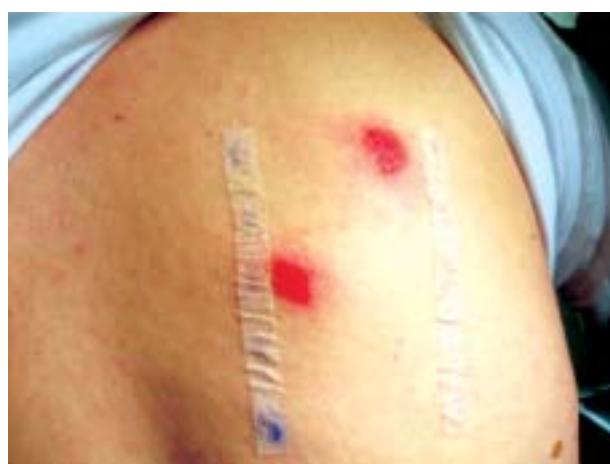


Fig. 3. Specific allergen panel – positive reaction to Iruzol and chloramphenicol.

Patch test is a biological test to determine the presence or absence of delayed allergic reaction to specific allergens. The techniques of test performance and interpretation have considerably changed; however, the basic principles have remained unchanged<sup>3</sup>. Patients with CAD verified by patch test showed significant improvement already at 6 months as compared with those not submitted to testing<sup>4</sup>.

Contact sensitivity to medicament ingredients and media in topical preparations is quite common in patients with leg ulcers. Topical antibiotics are a frequent cause of contact sensitivity, as demonstrated in many studies<sup>5-9</sup>. The presence of bacteria does not mean that it will interfere with ulcer healing. Routine application of neomycin, Garamycin or fucidin, formerly widely used in the management of ulcers, is not justified, because they represent highly potent allergens. Our patient showed a very strong reaction to Chloramphenicol ointment. Besides Chloramphenicol, the patient was tested for Betrion ointment, Bivacyn and Garamycin from the group of antibiotic ointments, however, with no positive reaction to these medicines.

The rate of positive patch tests is significantly higher in patients with dermatitis surrounded by an ulcer, which persists for a longer time in these patients. Ulcer healing is retarded in comparison with patients with no signs of inflammation on the skin surrounding the ulcer. It may be quite difficult to find an appropriate preparation for patients with identified sensitivity to various topical medications.

It is not only the active ingredient that causes CAD, as patients may also exhibit sensitivity to preservatives, dyes, scents, emulsifiers, and various media. Vehicle dermatitis is a complication quite frequently encountered in the treatment of venous ulcers, and is usually caused by lanolin and its derivatives, and by parabene mix<sup>10</sup>. Skin areas around the ulcer and the skin affected with hypostatic dermatitis are especially sensitive and prone to adverse reactions to topical drugs, with frequent irritation and sensitization. Patients develop sensitization to topical medications due to the recurrent and prolonged contact with chemical substances. The presence of lymphocytic infiltration in the dermis around the lesion contributes to sensitization, with the loss of epidermal barrier<sup>11</sup>. Ulcer healing is precipitated by avoiding the allergen identified, while the time to healing can be significantly reduced by timely elimination of the allergen<sup>12</sup>.

Our patient was first tested to Iruzol ointment, i.e. chloramphenicol + *Clostridium* peptidase, then to Iruzol and Chloramphenicol ointment, yielding allergic reactions of a comparable severity. We could only presume it was a case of sensitivity to the latter, because sensitivity testing for *Clostridium* peptidase alone was not available.

Contact allergic dermatitis is a very common disease in patients with lower limb ulcer and venous hypostatic dermatitis.

## References

- LEBREC H, BACHOT IG, GASPARD, IKERDINE S *et al.* Mechanisms of drug-induced allergic contact dermatitis. *Cell Biol Toxicol* 1999;15:57-62.
- GUIN JD, KINCANNONY. Medication-induced contact reactions. *Clin Dermatol* 1997;15:511-25.
- BELISTO DV. Patch testing with a standard allergen ("screening") tray: rewards and risks. *Dermatol Ther* 2004;17:231-9.
- RAJAGOPALAN R, ANDERSON RT, SARMA S *et al.* An economic evaluation of patch testing in the diagnosis and management of allergic contact dermatitis. *Am J Contact Dermatitis* 1998;9:149-54.
- WILSON CL, CAMERON J, POWELL SM, CHERRY G, RYAN TJ. High incidence of contact dermatitis in leg-ulcer patients – implication for management. *Clin Exp Dermatol* 1991;16:250-3.
- KATSAROU-KATSARI A, ARMENAKA M, KATSENI K *et al.* Contact allergens in patients with leg ulcers. *J Eur Acad Dermatol Venereol* 1998;11:9-12.
- KULOZIK M, POWELL SM, CHERRY G, RYAN TJ. Contact sensitivity in community-based leg ulcer patients. *Clin Exp Dermatol* 1988;13:82-4.
- GETTE MT, MARKS JG, MALONEY ME. Frequency of postoperative allergic contact dermatitis to topical antibiotics. *Arch Dermatol* 1992;128:365-7.
- KASTAROU A, KALOGEROMITROS D, ARMENAKA M *et al.* Trends in the results of patch testing to standard allergens over the period 1984-1995. *Contact Dermatitis* 1997;37:245-6.
- SKINNER S, MARKS JG. Allergic contact dermatitis to preservatives in topical medicaments. *Am J Contact Dermatitis* 1998;9:199-201.
- KOKELJ F, CANTARUTTI A. Contact dermatitis in leg ulcers. *Contact Dermatitis* 1986;15:47-9.
- BELDON P. Avoiding allergic contact dermatitis in patients with venous leg ulcers. *Br J Commun Nurs* 2006;11:S6, S8, S10-2.

## Sažetak

## KONTAKTNA ALERGIJSKA PREOSJETLJIVOST NA KLOSTRIDIOPEPTIDAZU S KLORAMFENIKOLOM U BOLESNICE S VENSКИM ULKUSOM POTKOLJENICE

*M. Tomljanović-Veselski i I. Zelić*

Lijekovi za lokalnu primjenu česti su uzročnici kontaktnog dermatitisa širom svijeta. Opisuje se slučaj 76-godišnje bolesnice s venskim ulkusom u koje se je tijekom dugogodišnje terapije rana na potkoljenicama razvila kontaktna preosjetljivost na klostridiopeptidazu s kloramfenikolom, topičnim pripravkom za liječenje ulkusa poznatim pod imenom Iruzol. Kod bolesnice se epikutanim testom potvrdila preosjetljivost na mast Iruzol, dok se izoliranim testiranjem na kloramfenikol potvrdila preosjetljivost na antibiotsku sastavnicu pripravka. Kontaktni alergijski dermatitis česta je pojava u bolesnika s venskim ulkusom i hipostatičnim dermatitisom.

*Ključne riječi: Ulkus donjih ekstremiteta – terapija lijekovima; Dermatološki lijekovi – štetni učinci; Dermatitis, alergijski-kontaktni – etiologija; Dermatitis, alergijski-kontaktni – dijagnostika; Patch testovi; Prikaz slučaja*