

## CHOICE OF OPERATIVE METHODS FOR PRIMARY VESICoureTERAL REFLUX

Borislav Spajić<sup>1</sup>, Jasna Đelmiš<sup>2</sup>, Marija Spajić<sup>3</sup>, Goran Štimac<sup>1</sup>, Josip Katušić<sup>1</sup> and Ognjen Kraus<sup>1</sup>

<sup>1</sup>University Department of Urology, <sup>2</sup>University Department of Pediatrics, Sestre milosrdnice University Hospital, Zagreb; <sup>3</sup>Department of Pediatrics, Karlovac General Hospital, Karlovac, Croatia

**SUMMARY** – Results of ureteral reimplantation in infants with primary vesicoureteral reflux (VUR) were retrospectively reviewed and evaluated. From January 1991 till December 2000, a total of 156 patients with primary VUR underwent ureteral reimplantation at University Department of Urology, Sestre milosrdnice University Hospital, Zagreb, Croatia. The indications for surgery were high-grade reflux, breakthrough urinary tract infections, and non-compliance with medical treatment. Ureteral reimplantation was performed according to Cohen's method (134/156) and Gil-Vernet (22/156) transvesical method. Out of 156 patients treated for primary VUR, 57 patients presented with left sided VUR and 40 with right sided VUR, whereas 52 patients required treatment for bilateral VUR, giving a total of 219 VUR repairs. Five patients had ureteral duplication accompanied by one sided VUR, whereas two patients had ureteral duplication accompanied by bilateral VUR. Out of the 156 surgically treated patients 2 (1.28%) presented with recurrent VUR, 3 (1.93%) with contralateral VUR, 5 (3.2%) patients were treated for urinary tract infection postoperatively, and none of our patients presented with stenosis. The overall complication-free percentage of surgically treated VUR in our study was 93.6%, while 96.8% were successfully treated for VUR. The present results show that transvesical ureteral repairs in infants are safe and very effective for the prevention of urinary tract infections. After surgical treatment in infancy, the individual renal growth of children with primary VUR is stable.

**Key words:** *Vesico-ureteral reflux – therapy; Vesico-ureteral reflux – surgery; Ureter surgery – methods; Child*

### Introduction and Objectives

The most common congenital anomaly of the urinary tract is vesicoureteral reflux (VUR), present in 29%-50% of infants and children investigated for urinary tract infections (UTI)<sup>1,2</sup>. VUR is an anomaly of the urinary tract which develops due to insufficiency of the ureterovesical junction and consequently the retrograde flow of urine from the bladder to the upper urinary tract (ureter or kidney). Reflux is found in approximately 1:200 female children and 1:1000 male children<sup>2</sup>. In 1903, Sampson was the first to describe the connection between the valve mechanism and VUR in dogs and rab-

bits, although VUR was recognized since the time of Galen<sup>1</sup>. Kretchmer was the first to describe this anomaly in children in 1916<sup>1</sup>. According to the International Reflux Study Committee, VUR is a congenital disease mainly caused by a deficiency of the longitudinal muscle of the intravesical ureter<sup>1</sup>. The valve mechanism is composed of the intramural and submucosal ureter that end at the ureteral orifice. The most critical factor to a competent ureterovesical junction is the length of submucosal ureter relative to its diameter. A 5:1 ratio of tunnel length to ureteral diameter was found in normal children without reflux<sup>2</sup>. Anatomical relationships of the ureterovesical junction change with growth in children, referred to as maturing of the ureterovesical junction. The ratio of the ureteral diameter and the length of the submucosal ureter increases from 1:2.4 in infants to up to 1:5 in adults<sup>1</sup>. Therefore, in patients whose ureterovesical junctions are not extensively damaged there is

Correspondence to: *Borislav Spajić, MD*, University Department of Urology, Sestre milosrdnice University Hospital, Vinogradska c. 29, HR-10000 Zagreb, Croatia  
E-mail: [borislav.spajic1@zg.t-co.m.hr](mailto:borislav.spajic1@zg.t-co.m.hr)

Received June 2, 2006, accepted August 28, 2006

a tendency to allow spontaneous disappearance of VUR. Secondary reflux is caused by bladder outlet obstruction and its consequent elevated pressures. Such obstructions are either anatomic or functional. The most common anatomic cause is posterior urethral valve, which is associated with reflux in approximately 50% of affected boys<sup>2</sup>. Anatomic obstructions in females are extremely rare. Instead, functional causes are by far more common in both sexes. These include neurogenic bladder, non-neurogenic bladder, and bladder instability or dysfunction. UTIs have been considered to be the main cause of permanent renal parenchymal damage in children with reflux. Therefore, the management of these children has been directed at preventing infection by antibiotic prophylaxis and/or surgical correction of reflux. However, controversy remains as to the optimum strategies for the management of children with primary VUR. The correlation of reflux nephropathy, UTI and VUR is well established<sup>3</sup>; reflux nephropathy is irreversible and may lead to renal insufficiency, renin-mediated hypertension, chronic renal failure, decreased somatic growth and morbidity during pregnancy. To avoid further development of renal scarring these patients must be treated under strict control of UTI. VUR is the leading cause of hypertension in children, and renal scarring from this condition accounts for 5% to 15% of end-stage renal failure in whites under 50 years of age<sup>4</sup>. Siblings of patients with reflux have a much greater risk of having reflux than the normal population<sup>4</sup>. In this article we evaluate our experience in surgical treatment of primary VUR.

## Patients and Methods

From January 1991 till December 2000, a total of 156 patients were admitted to University Department of Urology, Sestre milosrdnice University Hospital, Zagreb, Croatia, for surgical treatment of primary VUR. VUR was diagnosed by voiding cystourethrography (VCUG) and graded according to the criteria of the International Reflux Study Committee<sup>1</sup>. Cystoscopy was also performed. The indications for surgery were high-grade reflux, breakthrough UTIs, and non-compliance with prophylaxis. Ureteral prosthesis was only introduced when modeling was required or bilateral VUR was treated. Ureteral prosthesis was removed on day 3 postoperatively. Transurethral catheter was placed after the surgery and removed on postoperative day 5. The average hospital stay was 5 days. Antibiotic prophylaxis was administered for 3 months postoperatively.

## Results

Out of 156 patients treated for primary VUR, 57 patients presented with left sided VUR, 40 with right sided VUR, whereas 52 patients required treatment for bilateral VUR, giving a total of 219 VUR repairs. Five patients had ureteral duplication accompanied by one sided VUR, whereas two patients had ureteral duplication accompanied by both sided VUR. Prior to surgical treatment seven patients had grade I VUR, 60 grade II VUR, 124 grade III VUR, and 28 grade IV VUR. Out of 156 patients, 134 were selected for Cohen operative approach and 22 for Gil-Vernet operative method. Out of 156 surgically treated patients, two (1.28%) presented with recurrent VUR, three (1.93%) with contralateral VUR, five (3.2%) patients were treated for UTI postoperatively, and none of our patients presented with stenosis. Contralateral low grade reflux occurred in six of 74 (8.1%) patients with unilateral reflux preoperatively. After reimplantation, 13 febrile UTI episodes were documented in ten patients. The overall complication-free percentage of surgically treated VUR in our study was 93.6%, while 96.8% were successfully treated for VUR.

## Discussion

There is convincing evidence that a child with a UTI who has grade III or greater VUR is at a significant risk of acute pyelonephritis that may cause irreversible kidney damage, so a cystogram should be included in the imaging evaluation following a first upper UTI<sup>5,6</sup>. The purpose of imaging evaluation of the urinary tract following a first-time episode of acute pyelonephritis is to identify children with obstructive abnormalities that need prompt correction and those with VUR who may benefit from suppressive antibacterial therapy. It should be emphasized that these imaging studies are recommended for children who have had an acute febrile UTI; that is, acute pyelonephritis, not cystitis. It is generally accepted that children with voiding symptoms or foul-smelling urine with little or no fever but with significant bacteriuria have a lower UTI and are at a low risk of renal damage. Most authorities recommend a cystogram after a first documented febrile UTI in a child younger than 3 years, whereas others suggest this for children up to age five<sup>6</sup>. There is general agreement that any boy with a first febrile UTI should have upper tract imaging and a cystogram. Current standard for grading is based on the appearance of contrast in the ureter and

upper collecting system during VCUG (International Reflux Study Committee) (Fig. 1):

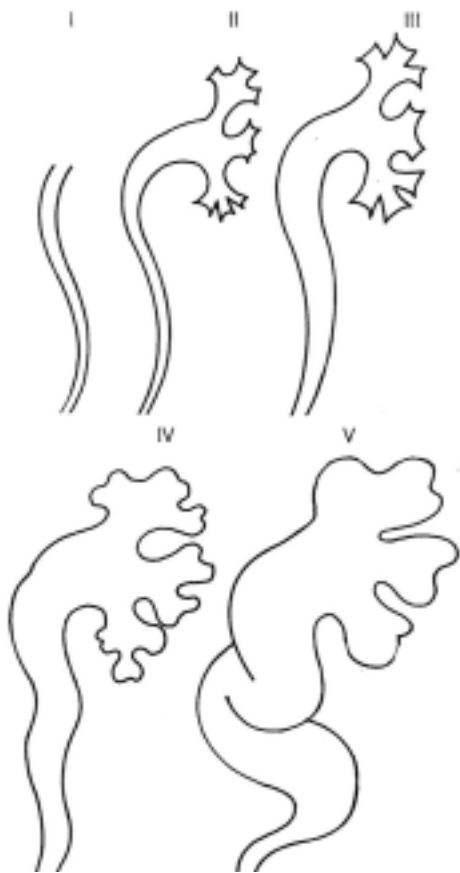


Fig. 1. Grading of vesicoureteral reflux based on the appearance of contrast in the ureter and upper collecting system during voiding cystourethrography (International Reflux Study Committee)

- grade I – into the nondilated ureter;
- grade I – into the pelvis and calyces without dilatation;
- grade III – mild to moderate dilation of the ureter, renal pelvis and calyces with minimal blunting of the fornices;
- grade IV – moderate ureteral tortuosity and dilation of the pelvis and calyces;
- grade V – gross dilation of the ureter, pelvis and calyces, loss of papillary impressions, and ureteral tortuosity<sup>1</sup>.

Some experienced clinicians suggest that all children have upper tract imaging and a cystogram upon a first-time episode of acute pyelonephritis. In the past, it was

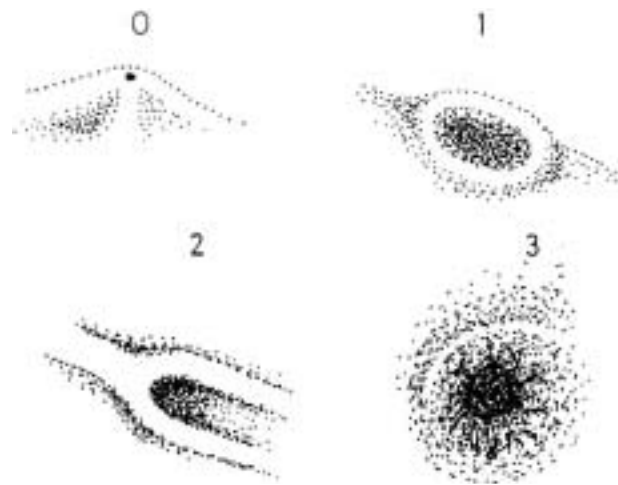


Fig. 2. Ureteral orifices, forms: 0 – normal orifice; 1 – stadium orifice, low grade vesicoureteral reflux (VUR); 2 – horseshoe-like orifice, medium grade VUR; 3 – golf-hole orifice, high grade VUR

common to recommend a waiting period of 4 to 6 weeks after an acute UTI before obtaining the cystogram<sup>5,6</sup>. This is no longer usual practice. Evidence indicates that the cystogram will provide the needed information for patient care if it is obtained once the infection has cleared and the voiding pattern has reverted to that present before the UTI. A nuclear cystogram minimizes radiation exposure but does not provide good anatomic detail of the bladder nor allows for precise grading of VUR. For this reason, a standard contrast voiding cystogram is recommended for the first study in both boys and girls, and a nuclear cystogram is recommended for follow-up studies in which the focus is on VUR. During preoperative evaluation of patients we also perform cystoscopy (Fig. 2). Visualization of the position and formation of ureteral orifices makes planning surgery easier. It also confirms additional anomalies (duplicated collecting systems, ectopic orifices, etc.) and may change the course of surgical correction.

The management of VUR has traditionally balanced between medical management with antibiotic prophylaxis and open surgical correction. With a 95% to 98% success rate for open surgery in most centers, it has been difficult to find a suitable replacement for this approach (Table 1)<sup>4</sup>. The indications for surgery are listed in Table 2. Endoscopic subureteric injection techniques were initially popularized in the early 1980s, with documented early success rates in the range of 75% to 90%<sup>7,8</sup>. The biggest impediment for widespread use have been the

*Table 1. The success rate in resolving vesicoureteral reflux according to stage of disease and type of treatment*

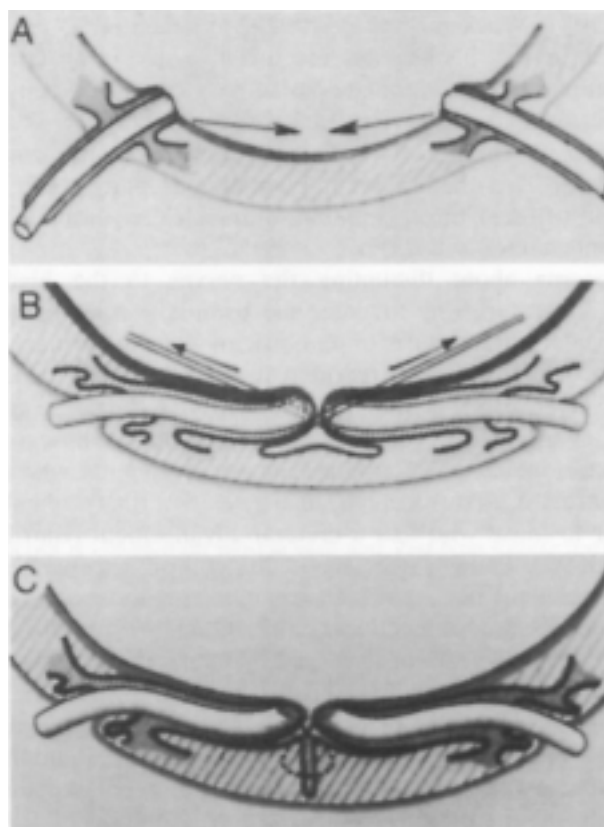
Stage/Treatment	Chemo-prophylaxis	Surgical treatment
I	90%	
II	80%	overall
III	50%	95%-99%
IV	10%	
V	0%	

associated risks of particle migration, granuloma formation, immune reaction, and degradation of the injectable material. A variety of traditional techniques have been described for the correction of VUR. These are anatomically categorized as extravesical, intravesical, or combined, depending on the approach to the ureter, and suprahiatal or infrahiatal, depending on the position of the new submucosal tunnel in relation to the original hiatus.

These methods have been chosen since in our experience they proved highly successful in treating VUR (96.8%), while demonstrating a low incidence of complications<sup>4</sup>. Intravesical ureteral reimplantation such as Leadbetter-Politano, Gil-Vernet or Cohen cross-trigonal procedures are currently the most popular way to manage VUR. First described by Cohen in 1975, the versatile cross-trigonal reimplantation is probably the most popular technique in use today<sup>9</sup>. In our experience, achieving adequate submucosal length along the posterior aspect of the bladder is possible in virtually every patient with this intravesical, infrahiatal advancement.

*Table 2. Indications for surgical correction of vesicoureteral reflux*

Breakthrough urinary tract infections despite prophylactic antibiotics
Noncompliance with medical management
Severe reflux (grade IV or V), especially with pyelonephritic changes
Failure of renal growth, the presence of new renal scars, or deterioration of renal function on serial ultrasound examinations or scans
Reflux that persists in girls as full linear growth is approached at puberty
Reflux associated with congenital abnormalities at the ureterovesical junction (e.g., bladder diverticula)



*Fig. 3. Gil-Vernet technique for bilateral vesicoureteral reflux: A – the principle of advancing ureters across the trigone; B – traction sutures are used for advancement; C – ureteral orifices are in close proximity and the submucosal length has been increased.*

The extravesical technique was first described in Europe by Lich in 1961<sup>10</sup> and subsequently in the United States by Gregoir in 1964<sup>11</sup>. With this technique, the bladder is left intact and it is generally associated with the advantages of minimal hematuria, infrequent urinary leaks, reduced bladder spasms, and potentially shorter hospital stay but lesser postoperative success regarding long time resolution of VUR<sup>12</sup>. Lich-Gregoir procedure is a typical example of extravesical approach where ureteral orifice is left intact, while the submucosal tunnel is formed by extravesical incision of the bladder wall<sup>9</sup>. Overall, surgical treatment eliminates VUR in approximately 95%-99% of patients<sup>4</sup>.

We perform Cohen cross-trigonal and Gil-Vernet procedures at our institution. For bilateral VUR repair we prefer Gil-Vernet technique (Fig. 3), whereas for unilateral VUR we perform Cohen technique (Fig. 4). The goal of surgical management is to create a long enough

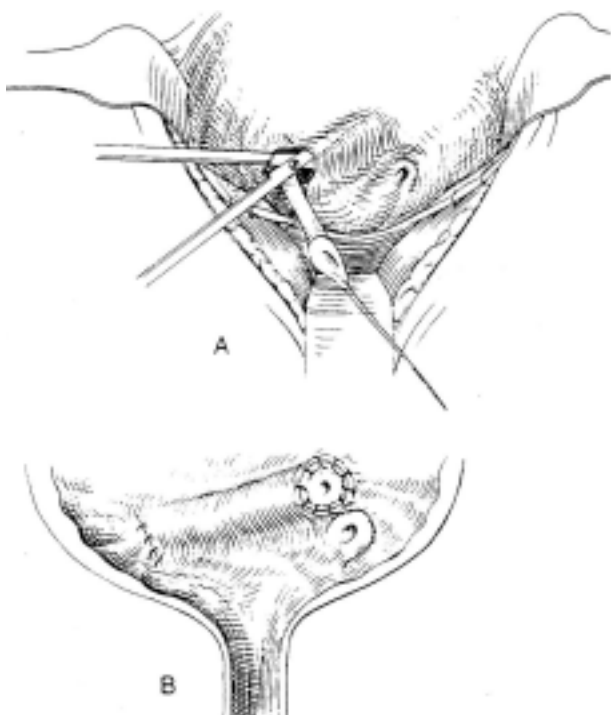


Fig. 4. Cohen cross-trigonal repair technique for unilateral vesicoureteral reflux: A – creation of submucosal tunnel; B – ureter is pulled through submucosal tunnel above the contralateral ureteral orifice.

ureteral submucosal tunnel by reimplantation of the ureter into the bladder wall. The treatment of VUR should be individualized.

### Conclusion

Based on our experience at this institution, transvesical reimplantation by both Cohen and Gil-Vernet techniques is a reliable procedure and our results are comparable to those reported from other institutions. We demonstrated the surgical treatment of VUR to be both safe and successful, with a low incidence of post-operative complications.

### References

1. International Reflux Study Committee. Medical *versus* surgical treatment of vesicoureteral reflux: a prospective international reflux study in children. *J Urol* 1981;125: 277-83.
2. GLEESON FV, GORDON I. Imaging in urinary tract infection. *Arch Dis Child* 1991;66:1282-3.
3. WALLIN L, BAJC M. The significance of vesicoureteric reflux on kidney development assessed by dimercaptosuccinate renal scintigraphy. *Br J Urol* 1994;73:607-11.
4. ELDER JS, PETERS CA, ARANT BS Jr *et al.* Pediatric Vesicoureteral Reflux Guidelines Panel. Summary report on the management of primary vesicoureteral reflux in children. *J Urol* 1997;157:1846-53.
5. HELLERSTEIN S. Urinary tract infections: old and new concepts. *Pediatr Clin North Am* 1995;42:1433-57.
6. RUSHTON HG. Vesicoureteral reflux and scarring. In: BARRATT TM, AVNER ED, HARMON WE, eds. *Pediatric nephrology*. 4<sup>th</sup> ed. Baltimore: Lippincott Williams & Wilkins, 1999:851-71.
7. MEVORACH R, RABINOWITZ R, BECK C, HULBERT W. Endoscopic treatment of vesicoureteral reflux with copatite: the first 50 patients. Program and abstracts of the 97<sup>th</sup> Annual Meeting of the American Urological Association, Orlando, Florida, May 25-30, 2002; Abstract 429.
8. CHERTIN B, DeCALUWE D, PURI P. Endoscopic treatment of primary grade IV and V vesicoureteral reflux (VUR) in children by subureteral injection of polytetrafluoroethylene (PTFE). Program and abstracts of the 97<sup>th</sup> Annual Meeting of the American Urological Association, Orlando, Florida, May 25-30, 2002; Abstract 431.
9. ATALAA, KEATING MA. Vesicoureteral reflux and megaureter. In: WALSH PC, RETIK AB, VAUGHAN DE Jr, WEIN AJ Jr, eds. *Campbell's urology*. Philadelphia: WB Saunders, 2002: 2085.
10. LICH R Jr, HOWERTON LW, DAVIS LA. Recurrent urosepsis in children. *J Urol* 1961;86:554.
11. GREGOIR W, Van REGEMORTER GV. Le reflux vesicoureteral congenital. *Urol Int* 1964;18:122.
12. WACKSMAN J, GILBERT A, SHELDON CA. Results of the renewed extravesical reimplant for surgical correction of vesicoureteral reflux. *J Urol* 1992;148:359.

## Sažetak

## IZBOR OPERATIVNE METODE ZA LIJEČENJE PRIMARNOG VEZIKOURETERALNOG REFLUKSA

B. Spajić, J. Đelmiš, M. Spajić, G. Štimac, J. Katusić i O. Kraus

Proveden je retrospektivni pregled i procjena rezultata reimplantacije uretera u dojenčadi s primarnim vezikoureteralnim reflusom (VUR). Od siječnja 1991. do prosinca 2000. godine ukupno je 156 bolesnika s primarnim VUR podvrgnuto reimplantaciji uretera na Klinici za urologiju Kliničke bolnice Sestara milosrdnica u Zagrebu, Hrvatska. Indikacije za operaciju bile su refluks visokog stupnja, masivna infekcija mokraćnog sustava te nepridržavanje medikamentnog liječenja. Reimplantacija uretera provedena je prema Cohenovoj metodi (134/156) i Gil-Vernetovoj transvezikalnoj metodi (22/156). Od 156 bolesnika liječenih zbog primarnog VUR 57 ih je imalo lijevostrani VUR, a 40 desnostrani VUR, dok je 52 bolesnika imalo obostrani VUR, tj. ukupno 219 popravaka zbog VUR. Petoro bolesnika je imalo duplikaciju uretera praćenu jednostranim VUR, dok ih je dvoje imalo duplikaciju uretera praćenu jednostranim VUR. Od 156 kirurški liječenih bolesnika dvoje (1,28%) ih je došlo s ponovljenim VUR, troje (1,93%) s kontralateralnim VUR, petoro (3,2%) ih je poslijeoperacijski liječeno zbog infekcije mokraćnog sustava, dok se stenoza nije razvila ni u jednog od naših bolesnika. Sveukupni postotak kirurški liječenog VUR bez komplikacija u našoj studiji je iznosio 93,6%, dok je postotak uspješnog izliječenja VUR bio 96,8%. Ovi rezultati pokazuju kako je transvezikalni popravak uretera u dojenčadi siguran i vrlo učinkovit u sprječavanju infekcije mokraćnog sustava. Rast pojedinog bubrega u djece s primarnim VUR je stabilan nakon kirurškog liječenja u dojenačkoj dobi.

Ključne riječi: *Vesiko-ureterni refluks – terapija; Vesiko-ureterni refluks – kirurfska; Kirurgija uretera – metode; Dijete*