

BRAINSTEM (DURET) HEMORRHAGE: A RARE COMPLICATION OF ISCHEMIC STROKE IN THE MIDDLE CEREBRAL ARTERY TERRITORY: A CASE REPORT

Alexandar Y. Gur¹, Irith Irena Reider-Groswasser², Yoram Segev², M. Hoffman³ and Natan M. Bornstein¹

¹Department of Neurology, ²Section of Neuroradiology, Department of Imaging, and ³Department of Internal Medicine "A", Tel Aviv Sourasky Medical Center, Sackler Faculty of Medicine, Tel Aviv University, Tel Aviv, Israel

SUMMARY – We report on an unusual case of brainstem Duret hemorrhage after ischemic stroke in the anterior circulation. The patient showed a clinical and neuroradiological picture of an acute and malignant middle cerebral artery infarct with increased intracranial pressure followed by a brainstem hemorrhage. The report suggests that the descending transtentorial herniation of any etiology might be complicated by a Duret hemorrhage.

Key words: Brain-Stem hemorrhage – diagnosis; Brain-Stem hemorrhage – physiopathology; Cerebral hemorrhage – radiography; Case report

Introduction

The term Duret hemorrhage has been used to describe secondary brainstem hemorrhage since the time Henri Duret produced brainstem hemorrhage in dogs after rapidly increasing intracranial pressure more than 100 years ago¹. This type of intracerebral hemorrhage is traditionally referred to as a posttraumatic sequel². In the traumatic brain, the presence of Duret hemorrhage is associated with the definitive diagnosis of transtentorial herniation³. We report on an unusual case of a patient with ischemic infarct in the anterior circulation who suffered from secondary brainstem or Duret hemorrhage.

Case Report

A 68-year-old man with a history of arterial hypertension was admitted after the sudden onset of confusional state, deviation of eyes to the right, left central

facial paresis and left hemiplegia. Two brain computerized tomography (CT) studies were performed. In the first study, which was carried out within six hours of clinical presentation, only a hyperdense middle cerebral artery (MCA) was noted (not shown). The patient's condition continued to worsen during the following 48 hours. Because of coma (GCS-6) and progressive disturbances of vital functions, brain CT studies were repeated and the pertinent findings of this set are displayed in Figure A and B. The patient died four days later.

Discussion

Published cases of secondary brainstem or Duret hemorrhage after ischemic stroke are scanty. In the pre-CT era, Nedergaard *et al.*⁴ found secondary brainstem hemorrhage in 15% of cerebral infarctions based on autopsy. In this neuropathological study cerebral infarctions were divided into those with and without intracranial thrombosis, and there were no data on infarct localization. Parizel *et al.*⁵ report four cases in three patients admitted for acute subdural hematoma and one patient with intraparenchymal hemorrhage. Descending transtentorial and subfalcial herniations were present in all four cases. We report on a patient who showed a clinical

Correspondence to: A. Y. Gur, MD, PhD, Stroke Unit, Department of Neurology, Tel Aviv Sourasky Medical Center, 6 Weizmann Street, Tel Aviv 64239, Israel

E-mail: strokeun@tasmc.health.gov.il

Received April 10, 2006, accepted May 19, 2006

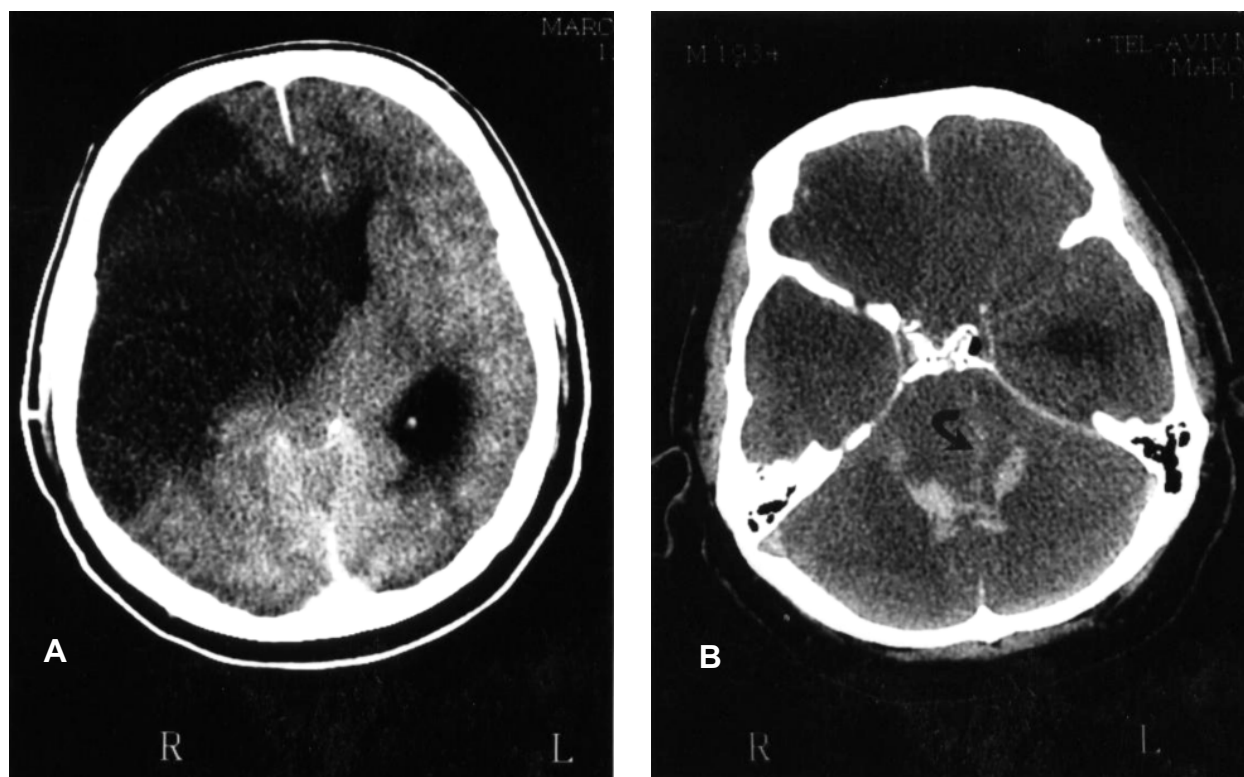


Fig. 1. (A) A large subacute infarction involving the cortical and subcortical right middle cerebral artery territory, including marked midline shift to the left and contralateral hydrocephalus. (B) A brainstem Duret hemorrhage (curved arrow), seen as the blood present in the fourth ventricle. The area was normal on the first study.

and neuroradiological picture of an acute and large ischemic stroke in the anterior circulation. The stroke was followed by a brainstem hemorrhage as the result of a malignant MCA infarct with increased intracranial pressure that resulted in transtentorial herniation.

Our case report suggests that there are multifactorial reasons for delayed secondary brainstem or Duret hemorrhage, and that descending transtentorial herniation of any etiology might be complicated by a Duret hemorrhage.

Acknowledgment. We thank Esther Eshkol for editorial assistance.

References

1. ALEXANDER E Jr, KUSHNER J, SIX EG. Brainstem hemorrhages and increased intracranial pressure: from Duret to computed tomography. *Surg Neurol* 1982;17:107-10.
2. CAPLAN LR, ZERVAZ NT. Survival with permanent midbrain dysfunction after surgical treatment of traumatic subdural hematoma: the clinical picture of a Duret hemorrhage? *Ann Neurol* 1977;1:587-9.
3. HOLLAND BA, BRANT-ZAWADZKI M, PITTS LH. The role of CT in the evaluation of trauma. Second edition. Baltimore: Williams & Wilkins, 1986:1-3.
4. NEDERGAARD M, KLINKEN BM, PAULSON OB. Secondary brain stem hemorrhage in stroke. *Stroke* 1986;4:501-5.
5. PARIZEL PM, MAKKAT S, JORENS PG *et al.* Brainstem hemorrhage in descending transtentorial herniation (Duret hemorrhage). *Intensive Care Med* 2002;28:85-8.

Sažetak

DURETOVO KRVARENJE: RIJETKA KOMPLIKACIJA ISHEMIJSKOG MOŽDANOG UDARA U PODRUČJU SREDIŠNJE MOŽDANE ARTERIJE – PRIKAZ SLUČAJA

A. Y. Gur, I. I. Reider-Groswasser, Y. Segev, M. Hoffman i N. M. Bornstein

Opisuje se rijedak slučaj Duretova krvarenja moždanoga debla nakon ishemijskog moždanog udara u prednjem krvotoku. Bolesnik je pokazivao kliničku i neuroradiološku sliku akutnog i zloćudnog infarkta središnje moždane arterije uz povišen intrakranijski tlak, nakon čega je uslijedilo krvarenje u moždanom deblu. Ovaj prikaz ukazuje na to da se Duretovo krvarenje može pojaviti kao komplikacija kod silazne transtentorijske hernijacije bilo koje etiologije.

Ključne riječi: Krvarenje u moždanom deblu – klinička slika; Krvarenje u moždanom deblu – fiziopatologija; Krvarenje u moždanom deblu – neurološka obrada