

MALIGNANT THYROID LYMPHOMAS

¹Branko Bećejac, ²Petar Gačina, ²Vladimir Stančić, ²Dubravka Čaržavec, ²Silva Čurić-Jurić
and ¹Martina Matovinović

¹Department of Endocrinology, Diabetes and Metabolic Diseases, ²Department of Hematology, University Department of Medicine, Sestre milosrdnice University Hospital, Zagreb, Croatia

SUMMARY – Primary thyroid lymphoma is a rare disease that accounts for about 5% of all thyroid neoplasms. It shows a female predominance, especially in women with a pre-existing Hashimoto's disease. During a 15-year period, 11 patients were diagnosed with primary thyroid lymphoma at Department of Endocrinology, Diabetes and Metabolic Diseases, Sestre milosrdnice University Hospital. There were no records on associated Hashimoto's thyroiditis in any of them, which is inconsistent with the international literature reporting on such association in 40%-80% of cases. Painless neck edema was the most common physical symptom for patient presentation. The diagnosis was based on fine needle aspiration cytology, while the spread of disease to other organ systems was ruled out by other studies (computed tomography, ultrasonography and gallium scintigraphy). However, it should be noted that diffuse or nodular lymphoma cannot always be classified only by aspiration cytology. The World Health Organization classification was used. Today, it has been generally accepted that thyroid lymphomas belong to a group of lymphomas associated with mucosa-associated lymphoid tissue (MALT). The most common form of non-Hodgkin's lymphoma (NHL) of the thyroid was B-cell phenotype lymphoma with a high malignancy grade. All patients were treated with chemotherapy according to the CHOP protocol (cyclophosphamide, doxorubicin, vincristine, prednisone). Eight patients underwent surgical treatment, three of them for compressive syndrome, followed by radiotherapy. The follow-up of patients with primary thyroid lymphoma revealed high disease aggressiveness and short survival, while complete remission was only occasionally recorded.

Key words: *Thyroid neoplasms – etiology; Thyroid neoplasms – diagnosis; Thyroid neoplasms – pathology; Lymphoma – etiology; Lymphoma – therapy; Thyroiditis, autoimmune – complications*

Introduction

Primary thyroid lymphoma is a rare disease that frequently develops in association with other malignancies¹⁻³. Formerly they were considered to belong to the group of poorly differentiated small-cell carcinomas (anaplastic carcinomas), whereas now they have been separated from this group as a special entity. They account for 5% of all thyroid neoplasms and 2.5%-7% of all extranodal lymphomas^{4,6}. Primary thyroid lymphoma is more commonly found in middle and older age groups, especially

in women with a previously diagnosed lymphocytic thyroiditis (Hashimoto's disease)^{7,8}. The risk of lymphoma development in a patient with lymphocytic thyroiditis is 40- to 80-fold that in the general population, while malignant transformation takes 20-30 years on an average. The majority of thyroid lymphomas are B-cell lymphomas with a high grade of malignancy. In contrast, the less common low malignancy lymphomas have recently been included in the group of mucosa-associated lymphoid tissue (MALT) lymphomas. Nowadays, the World Health Organization classification of lymphoid malignant tumors has been generally accepted. It is based on the definition of particular types of lymphoma by use of all parameters available such as lymphatic cell morphology and immunophenotyping to determine lymphocyte

Correspondence to: *Branko Bećejac, MD*, Department of Endocrinology, Diabetes and Metabolic Diseases, Sestre milosrdnice University Hospital, Vinogradska c. 29, HR-10000 Zagreb, Croatia
E-mail: mmatovin@kbsm.hr

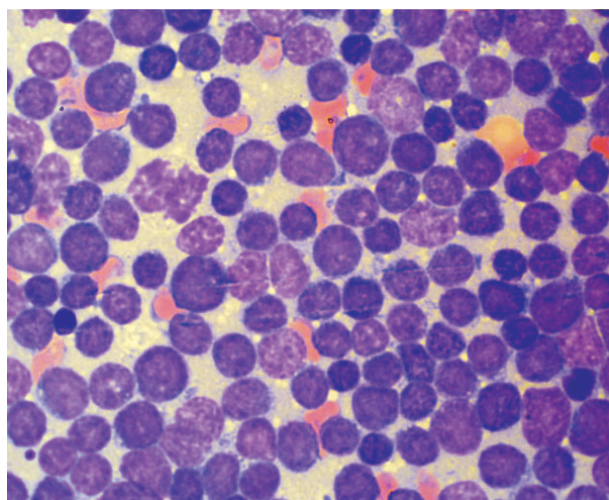


Fig. 1. NHL – high malignancy grade monomorphic lymphoblasts.

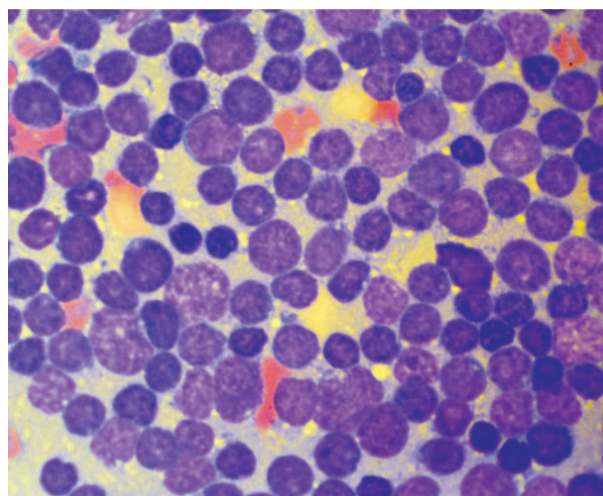


Fig. 2. NHL – high malignancy grade monomorphic lymphoblasts.

T or B clonality, gene transformation tests and clinical picture^{1,6}. This classification was also used in our patients, who underwent thyroidectomy, i.e. resection of thyroid lymphoma. Primary diagnosis included fine-needle aspiration biopsy cytology, which enables lymphoma classification to high-grade (consisting of blastic, i.e. morphologically immature large cells) and low-grade malignancy (small cell lymphoma)^{1,9}. Surgical procedure (thyroid biopsy) was not performed in all patients because aspiration biopsy proved adequate for diagnosis in some patients.

Patients and Methods

During a 15-year period (1991-2006), eleven patients were diagnosed with and treated for thyroid lymphoma at Department of Hematology, Sestre milosrdnice University Hospital. The WHO classification was used on disease identification. There were eight female and three male patients aged 21-74. Thyroid enlargement was the leading symptom for patient presentation. The diagnosis of thyroid lymphoma was made by target ultrasound guided fine-needle aspiration biopsy cytology. In eight patients, an additional histopathologic analysis was performed, showing findings consistent with cytologic diagnosis. The material was stained by the May-Grünwald-Giemsa method standardized according to Pappenheim, and by standardized immunocytochemistry methods (APAP) in some cases. Lymphoma localization was confined to the thyroid, and its potential

dissemination to other body regions was ruled out by bone marrow aspiration biopsy, skeleton scintigraphy, whole body gallium scintigraphy, ultrasonography (US) of the axillae and neck, and abdominal and thorax computed tomography (CT). All patients were treated with chemotherapy according to CHOP protocol (cyclophosphamide, doxorubicin, vincristine, prednisone), and eight patients underwent operative therapy (total thyroidectomy in six and partial strumectomy in two patients), three of them for acute obstructive syndrome, followed by radiotherapy.

Results

Non-Hodgkin's lymphoma (NHL) was found in ten patients, and Hodgkin's lymphoma in only one of 11 patients. High-grade malignancy NHL was recorded in seven and low-grade malignancy NHL in two patients, whereas NHL transformation to a high malignancy lymphoma occurred in one patient. None of our patients had any other malignancy. In eight patients, the cytologic diagnosis was confirmed by histopathologic analysis. In all patients, the leading symptom was neck edema, i.e. thyroid enlargement. All patients received treatment according to CHOP protocol. Eight patients underwent thyroid surgery, three of them for local compressive syndrome, followed by radiotherapy. Six of 11 patients died within 15 days to 20 months of the diagnosis.

Discussion

Data on our patient series were consistent with the respective literature reports on thyroid NHL to predominantly occur in female population aged 60-70^{1,9}. Our patient series of 11 patients included eight (73%) women, mean age 57. Most patients (90%) present for medical examination due to painless edema of the neck, and only some due to dysphagia, hoarseness or dyspnea, i.e. local compressive syndrome. Eight (73%) of 11 patients presented for painless neck edema, and three (27%) patients exhibited signs of compressive syndrome and were operated on. None of the study patients reported elevated body temperature, night sweating, or weight loss (B symptoms). The association of Hashimoto's disease (chronic lymphocytic thyroiditis) and NHL has been known for a long time now, and the two entities may occasionally be quite difficult to differentiate^{7,8}. The chronic inflammatory response in Hashimoto's disease has been postulated to eventually induce malignant lymphocyte transformation to lymphoma cells. Interestingly enough, in our patient series a pre-existing chronic lymphocytic thyroiditis was neither cytologically verified nor suggested by history data, with the exception of one female patient with a 10-year history of goiter and possible Hashimoto's disease. We are inclined to believe that some of our patients did suffer from Hashimoto's thyroiditis but without major symptoms, thus having no need to present for medical examination. None of our patients had history data on neck irradiation, described in the literature as a potential risk factor for the development of thyroid lymphoma¹⁰. Aspiration biopsy cytology of the thyroid is usually adequate for making primary diagnosis of the disease¹¹. Extra-thyroid localization of NHL should be excluded by x-ray of the thorax, US and CT of the abdomen, and bone marrow biopsy. In all our patients, the diagnosis of thyroid NHL was made by aspiration biopsy cytology, and confirmed by histopathology in eight patients. Extrathyroid localization of NHL was ruled out by additional studies.

Surgical resection is the traditional approach in the management of localized thyroid NHL (stage I and II). However, recent studies have shown that a combination of systemic chemotherapy and radiotherapy (multimodal chemoradiotherapy) provides most efficacious therapy and results in local regression¹²⁻¹⁵. Surgical procedure should only be reserved for cases of vague diagnosis for histopathologic verification, and in case of acute obstruction. All our patients were treated according to

CHOP protocol, and eight patients also underwent surgery for tumor reduction, three of them for acute obstruction syndrome; operative treatment was followed by radiotherapy. There are literature reports on a relatively good prognosis in patients with localized thyroid NHL^{9,11}. However, more than half of our patients (six of eleven) died within 15 days to 20 months, indicating short survival and high mortality in our patients with localized thyroid NHL. Such unfavorable data may be attributed to the older age of our patients, along with other concurrent diseases (e.g., cardiovascular disease) that may have been the cause of death. However, tumor aggressiveness should also be taken in consideration. Other patients achieved complete remission.

References

1. SKARGARD ED, CONNORS IM, ROBINS RE. A current analysis of primary lymphoma of the thyroid. *Arch Surg* 1991;126:1199-203; Discussion 1203-4.
2. HOLME L, BRAUGREN H, LOWHAGEN T. Cancer risk in patients with chronic lymphocytic thyroiditis. *N Engl J Med* 1985;312:601-4.
3. AOZASA K, INOUE A, TAJIMA A, MIYAUCHI A, MATSUZUKA F, KUNA K. Malignant lymphoma of the thyroid gland: analysis of 79 patients with an emphasis on histologic prognostic factors. *Cancer* 1986;58:100-4.
4. JUNOR EJ, PAUL J, REED NS. Primary non Hodgkin's lymphoma of the thyroid. *Eur J Surg Oncol* 1992;18:312-21.
5. ISAACSON P, SPENCER J. Malignant lymphoma of mucosa-associated lymphoid tissue. *Histopathology* 1987;11:445-62.
6. RASBACH D, MONDSCHHEIN M, HARRIS N. Malignant lymphoma of the thyroid gland: a clinical and pathologic study of twenty cases. *Surgery* 1985;98:1166-70.
7. HYJEK E, ISAACSON P. Primary B cell lymphoma of the thyroid and its relationship to Hashimoto's thyroiditis. *Human Pathol* 1988;19:1315-26.
8. SCHOLEFIELD J, QUAYLE A, HARRIS S, TALBOT C. Primary lymphoma of the thyroid, the association with Hashimoto's thyroiditis. *Eur J Surg Oncol* 1992;18:89-92.
9. MAKEPEACE AR, FERMONT DC, BENNETT MH. Non-Hodgkin's lymphoma of the thyroid. *Clin Radiol* 1987;38:227-81.
10. HA SC, SHADLE MK, MEDEIROS LJ, WILDER BR, HESS AM, CABANILLAS F, COX DJ. Localized non-Hodgkin lymphoma involving the thyroid gland. *Cancer* 2001;91:629-35.
11. DETWEILER RE, KATZ RL, ALAPAT C, EL-NAGGAR A, ORDONEZ N. Malignant lymphoma of the thyroid: a report of two cases diagnosed by fine-needle aspiration. *Diagn Cytopathol* 1991;7:163-71.
12. WIRTZFELD AD, WINSTON SJ, HICKS LW, LOREE RT. Clinical presentation and treatment of non-Hodgkin's lymphoma of the thyroid gland. *Ann Surg Oncol* 2001;8:338-41.
13. VIGLIOTTI A, KONG JS, FULLER LM, VELASQUEZ WS. Thyroid lymphoma stages IE and IIE: comparative results for

- radiotherapy only, combination chemotherapy only, and multimodality treatment. *Int J Radiat Oncol Biol Phys* 1986;12:1807-12.
14. MILLER TP, DAHLBERG S, CASSADY IR, ADELSTEIN DJ, SPIER CM, GROGAN TM et al. Chemotherapy alone compared with chemotherapy plus radiotherapy for localized intermediate and high-grade non-Hodgkin's lymphoma. *N Engl J Med* 1998;339:21-6.
15. GLICK J, KIM K, EARLE J, O'CONNEL M. An ECOG randomized phase III trial of CHOP vs CHOP plus radiotherapy (XRT) for intermediate grade early stage non-Hodgkin's lymphoma. *Proc Am Soc Clin Oncol* 1995;14:391.

Sažetak

MALIGNI LIMFOMI ŠTITNJAČE

B. Bečejac, P. Gačina, V. Stančić, D. Čaržavec, S. Čurić-Jurić i M. Matovinović

Primarni limfomi štitnjače su rijetka bolest, a pojavljuju se u oko 5% slučajeva svih neoplazma štitnjače. Češće se javljaju kod žena, osobito onih s prethodno postojećom Hashimotovom bolešću. U Zavodu za hematologiju Kliničke bolnice "Sestre milosrdnice" u 15-godišnjem razdoblju dijagnosticirano je 11 bolesnika s primarnim limfomom štitnjače. Ni za jednog bolesnika, međutim, nije se znalo da boluje od pridruženog Hashimotovog tiroiditisa, što se ne uklapa u podatke iz svjetske znanstvene literature koji govore o 40%-80%. Najčešći simptom koji je doveo bolesnika na pregled liječniku bila je bezbolna oteklina vrata. Dijagnoza je postavljena putem aspiracijske citopunkcije, a ostalim pretragama (CT, UZV, scintigrafija tijela radiogalijem) isključena je proširenost bolesti u druge organske sustave (*staging*). Treba, međutim, napomenuti kako isključivo citopunkcijom nije uvijek moguće klasificirati difuzni i nodularni limfom. Klasifikacija je provedena prema Svjetskoj zdravstvenoj organizaciji. Danas je općenito prihvaćeno mišljenje da limfomi štitnjače pripadaju skupini limfoma pridruženih mukoznom limfatičnom tkivu (MALT, *mucosa associated lymphoid tissue*). Najčešći oblik ne-Hodgkinovog limfoma (NHL) štitnjače bio je B stanični fenotip visokog stupnja malignosti. Svi bolesnici su liječeni kemoterapijom po shemi CHOP (ciklofosfamid, doksorubicin, vinkristin, prednizon), a kod 8 bolesnika je primijenjen kirurški zahvat, od toga kod troje zbog kompresivnog sindroma, a potom je provedena radioterapija. Praćenjem bolesnika s primarnim limfomom štitnjače uočena je velika agresivnost bolesti i kratko preživljavanje, ali su rjeđe moguće i potpune remisije.

Ključne riječi: *Neoplazme štitnjače – etiologija; Neoplazme štitnjače – dijagnostika; Neoplazme štitnjače – patologija; Limfom – etiologija; Limfom – terapija; Tiroiditis,*