

Dragana Gabrić¹, Davor Katanec²

Elevacija dna maksilarnog sinusa

Maxillary Sinus Floor Elevation

¹ Klinički bolnički centar, Klinika za stomatologiju*Clinical Hospital Center Zagreb, University Dental Clinic*² Zavod za oralnu kirurgiju, Stomatološki fakultet, Sveučilište u Zagrebu*Department of Oral Surgery, School of Dental Medicine, University of Zagreb*

Sažetak

Distalna bezubost gornje čeljusti, povezana s jakom resorpcijom alveolarnog grebena ili jakom pneumatizacijom maksilarnog sinusa, često je limitirajući čimbenik implanto-protetske rehabilitacije. Insuficijentni koštani volumen moguće je nadomjestiti operativnim zahvatom tako da se podigne dno maksilarnog sinusa (elevacija dna maksilarnog sinusa ili osinus-lifting). Elevacija dna sinusa operativni je zahvat kojim se premješta sinusno dno prema kranijalnoj kosti, uz istodobnu augmentaciju koštanog defekta kako bi se stvorila dovoljna visina koštanog fundamenta potrebnog za ugradnju dentalnih implantata. Ta operativna tehnika uobičajena je u kliničkoj primjeni od godine 1986. i od tada se sve više modificira i usavršava. Svrha ovoga rada jest predstaviti različite tehnike podizanja dna maksilarnog sinusa sa svim prednostima i nedostacima, kako bi u kliničkoj praksi njihova primjena bila što uspješnija. Elevacija dna maksilarnog sinusa, uz augmentaciju aloplastičnim ili autolognim koštanim implantatima, pouzdana je tehnika kojom se jako proširuju indikacije za ugradnju dentalnih implantata u molarnu regiju alveolarnog nastavka, što nije bilo moguće zbog voluminoznog maksilarnog sinusa.

Zaprimljen: 4. ožujka 2005.

Prihvaćen: 10. travnja 2006.

Adresa za dopisivanje

Prof.dr.sc. Davor Katanec
Sveučilište u Zagrebu
Stomatološki fakultet
Zavod za oralnu kirurgiju
Gundulićeva 5, 10 000 Zagreb
katanec@sfzg.hr

Ključne riječi

maksilarni sinus; oralna kirurgija;
maksilofacijalnipostupci; dentalni
implantati

Uvod

Implanto-protetska rehabilitacija distalne bezubosti u gornjoj čeljusti izborna je terapija pacijenata koji se ne mogu zbrinuti mobilnim protetskim nadomjescima ili žele fiksno-protetsku konstrukciju kojom se isključuje niz estetsko-funkcionalnih aberacija vezanih za mobilni nadomjestak. To su pacijenti s povećanim refleksom na povraćanje, profesionalni svirači puhaćih glazbala i posebice oni s jakom atrofijom alveolarnog grebena (1,2).

Osnovni uvjet za uspješnu ugradnju implantata jest ispravna indikacija. Indikacije za ugradnju dentalnih implantata jesu: potrebna kakvoća kosti, visina i širina koštanog fundamenta te odnos prema okolnim koštanim strukturama (1). Novija istraživanja dokazala su da je maksila zbog bolje prokrvljenosti povoljnija za ugradnju usatka. Kaplan-Mejerova analiza, na osnovi rezultata skupine autora,

Introduction

Implant-prosthetic rehabilitation of distal edentulousness in the maxilla is a treatment of choice for patients who cannot be treated using only removable partial dentures or for patients who want fixed prosthetic restorations which avoid a number of esthetic and functional disadvantages of removable restorations. These patients usually have pronounced reflex, professionally play wind instruments or present with severe atrophy of the alveolar crest (1,2).

The main prerequisite for successful implant placement is determining proper indication. Implant placement indications are: sufficient bone quality, height and width of the bone base as well as the relationship with the surrounding structures (1). Latest research showed that maxillary bone is better suited for graft placement due to better vascularization. Kaplan-Meier analysis showed that the success

pokazuje uspješnost ugradnje dentalnih implantata u molarnoj regiji gornje čeljusti 96,9%, a u molarnoj regiji donje čeljusti 87,9% (3). Limitirajući čimbenik za molaru regiju gornje čeljusti je voluminoznost maksilarnog sinusa, zbog čega postojeća koštana masa nije dovoljna za primarnu stabilnost implantata. Samo u 24% slučajeva gornje distalne bezubosti visina kosti je dovoljna za ugradnju implantata (4,5,6). U 76% slučajeva u gornjoj molarnoj regiji, zbog pneumatizacije sinusa, smanjena je vertikalna dimenzija alveolarne kosti (manje od 10 mm), a horizontalna dimenzija je zadovoljavajuća (4). Mogućnost implantacije tada je vrlo ograničena i u takvim slučajevima potrebno je primijeniti jednu od metoda podizanja dna maksilarnog sinusa kojom se može nadoknaditi manjak kosti i tako znatno proširiti indikacija za ugradnju implantata u molaru regiju gornje čeljusti (4,5,7).

Elevacija dna sinusa jest operativna tehnika premještanja sinusnog dna prema kranijalnoj kosti, uz istodobnu augmentaciju koštanog defekta kako bi se stvorila dovoljna visina koštanog fundamenta potrebnog za implantaciju. Postoji više tehnika toga operativnog zahvata, a izbor ovisi o pravilno postavljenoj indikaciji te individualnim sklonostima operatera (2,5).

Materijali koji se koriste za augmentaciju koštanog defekta kod elevacije sinusnog dna su autologni i aloplastični, ili njihova kombinacija (8,9).

Podizanje dna maksilarnog sinusa danas je uobičajen operativni zahvat u sklopu pretprotetske kirurgije. Mogućnost postoperativnih komplikacija postoji, ali svedena je na minimum detaljnom preoperativnom evaluacijom pacijentova stanja i preciznim intraoperativnim radom. Najčešća komplikacija je maksilarni sinusitis (oko 26% slučajeva), a ostale su: hematoma, perforacija sinusne membrane, otežano cijeljenje rane, infekcija ili dehiscijencija rane, nastanak oro-antralne komunikacije te sekvestracija koštanog implantata ili transplantata (10).

Metoda kirurškog podizanja dna maksilarnog sinusa se, prema svim recentnim kliničkim studijama, pokazala uspješnom, jer je dala dobre i trajne rezultate te je postala neizostavni dio pretprotetske kirurgije i suvremene implantološke rehabilitacije (6,11).

Operativne tehnike

Koštana masa je najvažniji čimbenik za stabilizaciju svih implantoloških sustava. Kada visina alveolarne kosti u predjelu maksilarnog sinusa iznosi manje od 10 milimetara, indicirana je neka od metoda elevacije dna maksilarnog sinusa, kako bi se izbjegla perforacija sluznice i prodor usatka u šu-

rate in bone grafting for the maxillary molar region is 96.9%, and in mandibular molar region 87.9% (3). A limiting factor in the upper molar region is the volume of the maxillary sinus, since the existing bone mass is not sufficient for the implant's primary stability. Only 24% of the cases involving maxillary edentulousness have sufficient bone height for implant placement (4,5,6). In 76% of the maxillary molar region cases, there is a decreased vertical dimension (less than 10 mm) of the alveolar bone due to sinus pneumatization, while the horizontal dimension remains acceptable (4). In such cases, implant possibilities are limited and sinus floor lifting is necessary to compensate for the bone loss, in order to expand the indications for implant placement in the maxillary molar region (4,5,7).

Sinus floor elevation is an operative technique of transferring the sinus floor cranially, with simultaneous augmentation of the bone defect, with the purpose of creation of the sufficient height of the bone fundament needed for implantation. Several methods exist for this operative procedure, depending on the indication and the individual preferences of the surgeon (2,5). The materials used for bone defect augmentation in sinus floor elevation are allografts and autologous materials or their combination (8,9).

Sinus floor lifting is a common operative procedure in pre-prosthetic surgery. The possibility of post-operative complications occurring exists, but it is reduced to a minimum through detailed pre-operative patient evaluation and precise intra-operative work. The most common complication is maxillary sinusitis (ca. 26%). Other complications are hematoma, sinus membrane perforation, difficult wound healing and infection, wound dehiscence, oroantral communication and sequestration of the bone implant or graft (10).

The surgical method for sinus floor elevation is, according to recent literature, a successful method which produces good and lasting results. Therefore, it is an unavoidable part of pre-prosthetic surgery and contemporary implant-prosthetic rehabilitation (6,11).

Operative procedures

Bone mass is the most important factor for implant stabilization. If the alveolar bone height in the maxillary sinus area is less than 10 mm, one of the sinus floor elevation procedures is indicated, with the purpose of avoiding sinus membrane perforation and insertion of implant in the sinus space (11).

pljinu sinusa (11). Prvi put je takav operativni zahvat opisao Tatum godine 1976. Do danas je opisano više metoda i u literaturi se za većinu kirurških tehnika koristi izraz "sinus lifting" (9). Za neke od tih metoda koriste se, zbog primarne stabilnosti implantata, slobodni koštani transplantati (intraoralni- mandibularna simfiza, tuber maksile ili ekstraoralni - spongiozna kost ili hrskavica kriste ilijake, rebro, metafiza tibije) ili aloplastični materijali (kolagena vlakna, staklena keramika, hidroksilapatit te trikalcij-fosfat) (12-15). Danas se, zajedno s materijalima za augmentaciju kosti, primjenjuju i membrane temeljene na principu vođene koštane regeneracije (engl. guided bone regeneration, GBR). Resorptivne i neresorptivne membrane koje se postavljaju preko defekta mehaničke su zapreke kako bi se onemogućile migracije epitela i vezivnog tkiva gingive u područje kirurške rane, što osigurava nesmetano stvaranje koštanog tkiva. Resorptivne membrane (kolagenske: Bio-Gide, BioMend, Avitene; sintetični materijali: Gore-Resolut, Guidor, Epi-Guide) koriste se za jednofaznu tehniku rada, a one neresorptivne (Gore-Tex, titanska, ePTFE) moraju se ukloniti naknadnim kirurškim zahvatom nakon 4 do 6 tjedana i omogućuju bolje kliničke rezultate. (16).

Tehnika elevacije dna sinusa ovisna je o visini alveolarne kosti i zato je Misch 1985. objavio subantralnu klasifikaciju kosti gornje čeljusti:

1. kod visine kosti oko 12 milimetara elevacija nije potrebna;
2. visina kosti između 8 i 12 milimetara zahtijeva povećanje kosti pristupom kroz ležište implantata;
3. visina kosti između 5 i 8 milimetara zahtijeva povećanje grebena i istodobnu ugradnju implantata (jednofazni postupak);
4. visina kosti između 0 i 5 milimetara zahtijeva dvofazni postupak - u prvoj fazi elevaciju i subantralno povećanje kosti te implantaciju nakon 8 do 10 mjeseci. (17)

1. Pristup kroz ležište implantata

Ako visina alveolarne kosti iznosi od 8 do 10 milimetara, primjenjuje se ograničeno podizanje dna sinusa kroz ležište za implantat. Ta je metoda unutrašnja, za razliku od svih ostalih - one su vanjske, a jedna od najstarijih je tehnika elevacije. Tijekom trepanacije kroz alveolarnu kost, svrdla se zaustavljaju 1 do 2 milimetra ispod koštanog dna sinusa. Zatim se u ležište postavlja mjerač dubine i blagim udarcima čekićem odlomi dio koštanog dna sinusa te zajedno sa sinusnom sluznicom za koju je pričvršćen, potisne prema kranijalnoj kosti (7,13,18). (Slike 1.- 4.)

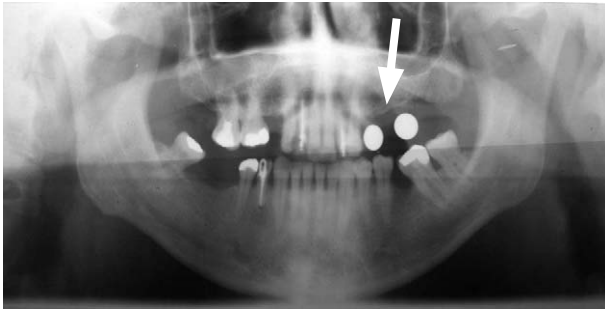
Tatum first described the operative procedure in 1976. Since then, many new procedures were described and the term "sinus lifting" has been used in literature concerning most surgical techniques in this domain (9). In some of these procedures either free bone transplants (from the mandibular symphysis, tuberosity or iliac crest, costal bone or tibia metaphysis) or allografts (collagen fibers, glass ceramics, hydroxylapatite and tricalciumphosphate) are used (12-15). Today, membranes are also used together with materials for bone augmentation, according to the principle of guided bone regeneration (GBR). Resorbable and non-resorbable membranes are placed over the defect as a mechanical barrier, with the purpose of disabling epithelial migration and gingival fibrous tissue growth into the surgical wound area, which enables the creation of bone tissue. Resorbable membranes (collagen membranes - Bio-Gide, BioMend, Avitene; synthetic material membranes - Gore Resolut, Guidor, Epi-Guide) are used for one-phase working techniques, while non-resorbable membranes (Gore-Tex, titanium, ePTFE) must be removed surgically after 4 to 6 weeks, providing better clinical results (16).

The sinus floor elevation procedure depends on alveolar bone height. Misch classified the maxillary bone subantrally as follows:

- More than 12 mm - elevation is not necessary
- Bone height between 8 and 12 mm - bone augmentation by the implant site approach
- Bone height between 5 and 8 mm - bone augmentation with simultaneous implant placement (one phase procedure)
- Bone height between 0 and 5 mm - two-phase procedure; elevation in the first phase and subantral bone augmentation and implant placement after 8-10 months (17).

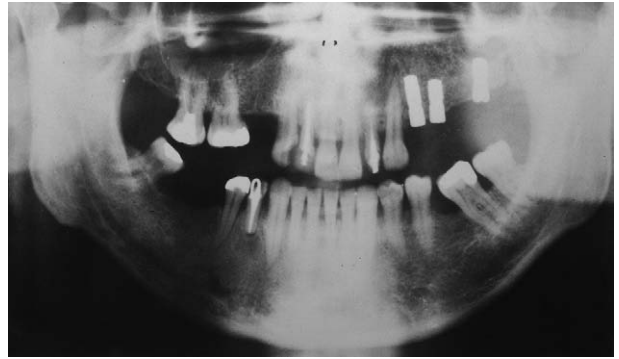
1. Implant site approach

In cases in which alveolar bone height is between 8 and 10 mm, limited sinus floor lifting through implant site is applied. This procedure is internal and it is one of the oldest elevation techniques, as opposed to all others which are external. During drilling through the alveolar bone, burrs stop at the area 1 to 2 mm underneath the sinus floor. Then, a depth meter is placed in the site and by light hammer blows a part of the sinus floor is broken and pushed cranially together with the sinus membrane (7,13,18) (Figs. 1-4).



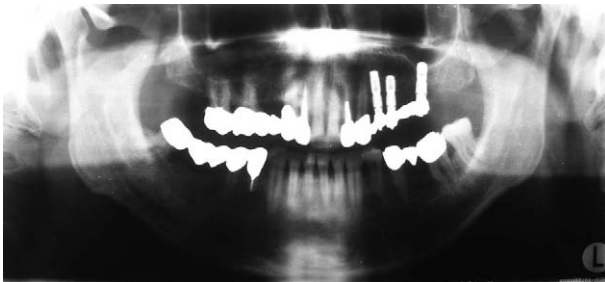
Slika 1. Vodilice na ortopantomogramu za dijagnostiku i planiranje ležišta implantata.

Figure 1 Orthopantomogram with markers for diagnostic and implant site planning.



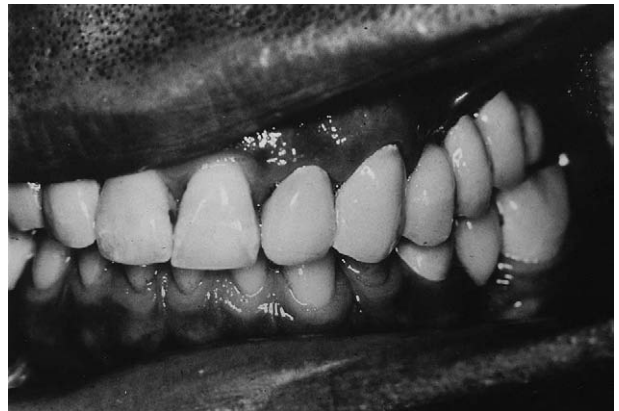Slika 2. Elevacija sinusnog dna pristupom kroz ležište implantata.

Figure 2 Sinus floor elevation, side approach through implant site.



Slika 3. Kontrolni RTG 12 godina nakon opterećenja fiksnom konstrukcijom.

Figure 3 X-ray, 12 years after placement of a fixed prosthetic restoration.



Slika 4. Intraoralni nalaz 12 godina nakon operativnog zahvata i protetske rekonstrukcije.

Figure 4 Intraoral situation 12 years after operative procedure and prosthetic reconstruction.

2. Bočni pristup kroz trepanacijski otvor

Indikacija za tu tehniku je visina alveolarne kosti između 6 i 8 milimetara. Na prednjoj stijenci maksile, iznad planiranog mjesta za usadak trepanira se kost dijamantnim svrdlom kojim se izbjegava perforacija sluznice te se trepanacijski otvor proširuje kliještima za kost. Sluznica se odvaja od koštanog dna sinusa tupom preparacijom kiretom. Tijekom preparacije ležišta za implantat, sluznica se štiti pogodnim instrumentom budući da se svrdlom namjerno trepanira koštani pod sinusa. Nakon ugradnje implantata, stvoreni mrtav prostor ispunjava se nekim od materijala za punjenje koštanih defekata (12,19,20).

3. Bočni pristup s odizanjem koštanog poklopca

Kod visine alveolarne kosti od samo nekoliko milimetara, nije dovoljno samo podignuti sluznicu, nego je indicirana augmentacija dna maksilarnog sinusa. Ta se metoda može obaviti na dva na-

2. Lateral trephine opening approach

The indication for this technique is alveolar bone height between 6 and 8 mm. On the anterior maxillary wall, above the planned implant site, bone is fenestrated using a diamond bur to avoid membrane perforation and the bone forceps is used for widening the trepanation site. The sinus membrane is separated from the sinus floor with a blunt curette. During the implant site preparation, an appropriate instrument protects the sinus membrane, since the bone at the sinus floor has been purposely fenestrated with the bur. After implant placement, the created "dead space" should be filled with an augmentation material (12,19,20).

3. Lateral window approach

If the alveolar bone height amounts to only a few millimeters, it is not enough to simply lift the sinus membrane; the floor of the maxillary sinus needs to be augmented. There are two procedures; the si-

čina - augmentacijom s odgođenom implantacijom i augmentacijom uz istodobnu implantaciju (imeditatna implantacija) (21). U oba se slučaja primjenjuje osteoplastični pristup, što znači da se stvara koštani poklopac u obliku pravokutnika, a pričvršćen je za sluznicu sinusa. Metodu je opisao Tatum godine 1976., a prilagodio 1986., pa se ona danas najčešće koristi (22).

3.1. Osteoplastični pristup

Na visini od 4 do 5 milimetara od vrha alveolarnog grebena, dijamentnim se svrdlom obavlja horizontalna osteotomija čija dužina ovisi o broju planiranih usadaka. Od kraja horizontalne osteotomije polaze vertikalne osteotomske linije dužine 10 milimetara u kranijalnom smjeru, čiji se krajevi spajaju multiplim perforacijama koje tada čine točkastu liniju, usporednu s donjom horizontalnom osteotomijom. Tako zalomljena kost potisne se pritiskom te rotira medijalno i kranijalno prema sinusu, uz istodobno odljubljivanje sluznice raspatorijem od dna sinusa i okoline vertikalnih osteotomija. Potiskivanjem formiranog koštanog poklopca odlome se i preostali koštani mostići u gornjem dijelu točkaste osteotomije te se na taj način poklopac, pričvršćen uz sluznicu sinusa, dovodi u horizontalan položaj tvoreći novo dno sinusa (18,22).

3.2. Augmentacija s odgođenom implantacijom

Indikacija za tu tehniku jest visina kosti najviše do 5 milimetara. Nakon osteoplastičnog pristupa, novostvoreni prazan prostor popunjava se koštanim autotransplantatom ili nekim aloplastičnim materijalom. Ako se koristi koštani blok, potrebno ga je imobilizirati, a okolne prazne prostore popuniti spongiozom ili prekriti membranom, čime se sprječava da meko tkivo urasta u prazne prostore. Implantati se ugrađuju nakon 6 do 9 mjeseci (23,24).

3.3. Augmentacija uz istodobnu (imeditatnu) implantaciju

Ta se tehnika danas najčešće koristi, a indicirana je kada je visina kosti alveolarnog grebena između 5 i 8 milimetara (17,25). Nakon što se podigne koštani poklopac, određuje se veličina praznog prostora koji treba ispuniti koštanim transplantatom ili samo aloplastičnim materijalom. Na odabranom se mjestu (intraoralno ili ekstraoralno) okruglim čeličnim svrdlom točkastim perforacijama označe anatomске linije. Zatim se fisurnim svrdlom prerežu koštani mostići. U sredini tako formiranoga budućeg transplantata, trepanira se ležište za implantat. Tran-

nus floor can be augmented either with simultaneous or with delayed implantation (21). In both cases, the osteoplastic approach that includes preparing a rectangular window in the bone attached to the sinus membrane is performed. This method was described by Tatum in 1976 and modified in 1986, and is still the most commonly used method (22).

3.1 Osteoplastic procedure

Horizontal osteotomy (whose length depends on the number of implants planned) is performed by a diamond bur at 4 and 5 mm in height from the top of the alveolar bone. From the end of the horizontal osteotomy, vertical osteotomies (10 mm in length) are made in the cranial direction, and their ends are joined with multiple perforations that form a dotted line, parallel with the lower horizontal osteotomy. The bony window is pushed and rotated medially and cranially towards the sinus with the simultaneous membrane detachment using an elevator from the sinus floor and vertical osteotomy area. The pressure of the newly formed costal flap causes breaking of the remaining bone formations in the upper part of the dotted osteotomy, and in this way the flap, attached to the sinus membrane, falls in the horizontal position forming the new sinus floor (18,22).

3.2 Augmentation with delayed implant placement

This technique is indicated when bone height is less than 5 mm. After the osteoplastic approach, the newly created empty space is filled with bone autotransplant or some allograft. Immobilization is necessary when using the costal block; empty spaces surrounding the block are filled with cancellous bone or covered with membrane to prevent the soft tissue from growing inside the empty spaces. Implants are placed after 6 to 9 months (23,24).

3.3 Augmentation with simultaneous (immediate) implant placement

Today this is the most frequently used technique, and it is indicated in situations when 5 to 8 mm of alveolar bone remains (17,25). The size of the space to be augmented is determined after lateral window elevation. The anatomical lines are marked using a steel bur on the donor site and bony bridges are cut with a fissure bur. A hole for the implant is made in the middle of the bone transplant. The graft is luxated from the site using a chisel and elevators. The sinus floor is fenestrated with implant burs. The transplant is placed on the sinus floor with

splantat se odvaja od ležišta dlijetom i raspatorijem pokretima luksacije. Koštano dno sinusa trepanira se svrdlima za pravljenje ležišta usatka. Koštani transplantat, nakon što se iz njega izvadi ureznica, postavlja se na dno sinusa korteksom okrenutim prema dolje (kaudalno). Kroz trepanacijski otvor na dnu sinusa postavlja se implantat koji ulazi u svoje ležište na koštanom transplantatu te ga se uvrtaњem fiksira za dno sinusa. Koštani poklopac mora se osloniti na vrh implantata koji prominira kroz transplantat, a preostali prazan prostor ispunjava se aloplastičnim koštanim materijalom. Isti je postupak i kod metode bez transplantata – tada se šupljina u kojoj je implantat augmentira samo aloplastičnim materijalom (26-28).

Postoperativne komplikacije

Elevacija dna maksilarnog sinusa vrlo je precizna i osjetljiva operativna tehnika. Postoji velika mogućnost za postoperativne komplikacije zbog nemarnog rada operatera, a posljedice mogu biti jatrogena perforacija membrane maksilarnog sinusa, neadekvatna fiksacija koštanoг implantata, kontaminacija sinusa mikroorganizmima tijekom zahvata i loše zašivena rana. Prema tome moguće postoperativne komplikacije mogu biti: hematoma, perforacija sinusne membrane, otežano cijeljenje rane, infekcija ili dehiscijencija rane, nastanak oro-antralne komunikacije, sekvestracija koštanoг implantata ili transplantata te sinusitis (29,30).

Najčešća postoperativna komplikacija jest sinusitis – čak u 26% slučajeva. Sinusitis se javlja kod pacijenata kod kojih je predoperativno utvrđena neadekvatna drenaža ili im je patološki promijenjena sluznica. Također može biti i posljedica perforacije vulnerabilne Schneiderianove membrane (31,32). Endoskopska evaluacija stanja sinusne sluznice sastavni je dio predoperativne pripreme. ispiranje usne šupljine 0,12%-tnim klorheksidinom smanjuje mogućnost kontaminacije nesaprofitnim mikroorganizmima tijekom zahvata (33).

Patološke promjene sinusa i postoperativni kronični maksilarni sinusitis mogu ugroziti inkorporaciju koštanoг grafta i uspjeh zahvata. Zato je važno preventivno ordinirati antibiotik širokog spektra koji se uzima sljedećih deset dana u postoperativnom razdoblju (34).

Rasprava i zaključak

Elevacija dna maksilarnog sinusa s razlogom se smatra pouzdanom operativnom tehnikom, što su svojim istraživanjima dokazali mnogi autori. Jedna

the cortex turned towards the oral cavity (caudally). An implant is then positioned through the fenestration and fixed onto the sinus floor. The bony window is placed on the top of the implant which is protruding through the graft, and the remaining space is filled with allograft bone material. The technique is the same when only bone substitute material is used (26-28).

Postoperative complications

Maxillary sinus floor elevation is a very precise and sensitive procedure. There is a high risk of postoperative complications that may be caused by unsatisfactory tissue management during the procedure. These include: membrane perforation, inadequate fixation of the bone graft, sinus contamination with microorganisms during the procedure and poor wound closure. Possible postoperative complications include haematoma, sinus membrane perforation, difficult healing, infection or wound dehiscence, oroantral communication, bone graft sequestration and sinusitis (29,30).

The most frequently occurring event is sinusitis, seen in 26% of the cases. Sinusitis appears in patients with pre-operatively determined inadequate drainage, or in patients with sinus membrane pathology. It can also be a result of perforation of the vulnerable Schneider's membrane (31,32). Endoscopic evaluation of the sinus membrane state is an essential part of the treatment planning. Rinsing the mouth with 0,12% chlorhexidine decreases the possibility of contamination with non-saprofite microorganisms during the procedure (33).

Pathological sinus changes and postoperative chronic maxillary sinusitis can influence healing, bone regeneration and the success of the procedure. It is important to administer wide a spectrum antibiotic that is to be taken during the first 10 days postoperatively (34).

Discussion and conclusion

Maxillary sinus floor elevation is considered a reliable operative technique, which is proven in literature. Raghoobar et al. presented a study which

od najopsežnijih takvih studija je ona Raghoeara i suradnika koja vrlo detaljno i na velikom uzorku ispitanika pokazuje što se prognostički može očekivati nakon tog zahvata. Spomenuti autori ugradili su 392 implantata koristeći se tehnikom sinus-lifta - od toga broja imali su gubitak od samo 32 usatka, što znači da je postotak uspješnosti te metode 91,8%. Zanimljivo je da je signifikantna razlika u uspješnosti iste tehnike kod potpuno i parcijalno bezubih pacijenata. Uspješnost terapije kod potpuno bezubih pacijenata iznosi 90,8%, a kod djelomične bezubosti čak 97% (15). Vrlo slični rezultati dobiveni su i u studiji Esposito i suradnika (35). Objašnjenja je nekoliko: bezuba čeljust zahvaćena je većim stupnjem resorpcije; žvačne sile se s protetske konstrukcije prenose i na prirodne zube kod djelomično bezube čeljusti te rasterećuju koštani fundament; kod potpuno bezubih pacijenata povećan je rizik za loše biomehaničke vrijednosti implantata zbog slabije kvalitete kosti. Rezultati pokazuju da je parcijalna bezubost primarna indikacija toga kirurškog zahvata, što potvrđuju i naša iskustva.(15,35).

Ni jedna skupina autora nije pronašla znatnu razliku u uspješnosti terapije s obzirom na augmentaciju s istodobnom ili odgođenom implantacijom (13).

Autori navode varijabilne rezultate učestalosti sinusitisa u rasponu od 5% do 25% (15,35). Uglavnom je riječ o prolaznom sinusitisu, a tek kod nekolicine pacijenata opisan je purulentni sinusitis i to kao posljedica intraoperativne perforacije membrane (15).

Najbolje prognostičke rezultate osigurava primjena autolognih koštanih implantata, jer djeluju oseoinduktivno i pokazuju visoku koncentraciju osteokompetentnih stanica, što potvrđuje Moyeva histomorfometrijska studija (36).

Svi autori slažu se da je elevacija dna sinusa vrlo pouzdana operativna tehnika s dugoročnim rezultatima i izrazito visokim postotkom uspješnosti te se tim zahvatom znatno proširuju indikacije za implanto-protetsku terapiju. Rezultati recentnih svjetskih studija govore u prilog sve većoj primjeni metode podizanja dna maksilarnog sinusa u implantološkoj terapiji.

describes what can be expected after the procedure in detail and on a large number of subjects. They positioned 392 implants using the sinus-lift method, and reported the loss of only 32 implants, the success rate being 91.8%. Interestingly, there is a significant difference in success rates between totally and partially edentulous patients. The success rate in totally edentulous patients is 90.8% and in partially edentulous 97% (15). Similar results were presented by Esposito et al. (35). There are several possible explanations of these findings: the edentulous jaw is severely resorbed; masticatory forces are transferred from the prosthetic restoration on to the natural teeth in the partially edentulous jaw, relieving the bone fundament; in totally edentulous patients there is an increased risk of inadequate biomechanical implant values due to poor bone quality. Results show, and our experience confirms, that partial edentulousness is a primary indication for this surgical procedure (15,35).

There is no significant difference in success rates with regard to simultaneous or postponed implantation in combination with sinus elevation procedure (13).

Sinusitis occurs in a range from 5 to 25% of patients (15,35). Mostly, it is mild sinusitis, and only in several patients was purulent sinusitis described - usually a consequence of intraoperative sinus membrane perforation (15).

Autologous bone grafts show the best results because of their osseoinductive activity and a high concentration of osseocompetent cells, as Moy showed in his histomorphometric study (36).

Literature shows that sinus floor elevation is a very reliable procedure with long-lasting results and high success rates. This procedure significantly broadens the indications for implant-prosthetic therapy. The results of new studies confirm the value of sinus floor elevation in implant therapy.

Abstract

Distal edentulousness of the maxilla, together with extensive resorption of the alveolar crest or high pneumatization of the maxillary sinus, is often a limiting factor for implant-prosthetic rehabilitation. It is possible to compensate insufficient bone volume by elevating the floor of the maxillary sinus using an operative procedure (sinus floor elevation or sinus lifting). Elevation of the sinus floor is an operative procedure based on moving the bottom of the sinus cranially while simultaneously augmenting the bone defect, with the purpose of creating sufficient height at the bone fundament needed for the placement of dental implants. This operative technique has been routine in clinical practice since 1986 and is constantly being improved and modified. The purpose of this review is to present the different techniques in sinus lifting with all their advantages and disadvantages in order to render their implementation in clinical practice as successful as possible. Elevating the maxillary sinus floor by augmentation with allograft or autologous bone implants is a reliable method which broadens the indications for the placement of dental implants in the molar region of alveolar bone A, where, due to extensive pneumatization of the maxillary sinus, it was not previously possible.

Received: March 4, 2005

Accepted: April 10, 2006

Address for correspondence

Professor Davor Katanec, DDS
University of Zagreb
School of Dental Medicine
Department of Oral Surgery
Gundulićeva 5, HR-10 000 Zagreb
katanec@sfzg.hr

Key words

Maxillary Sinus; Surgery; Oral;
Maxillofacial Procedures; Dental
Implants

References

- Knežević G, i suradnici. Osnove dentalne implantologije. Zagreb: Školska knjiga; 2002.
- Peterson JL, Ellis E, Hupp RJ, Tucker RM. Contemporary Oral and Maxillofacial Surgery. St. Louis: Mosby; 2002.
- Lauc T, Krnić D, Katanec D. Implant failure: regional versus cumulative evaluation. *Coll Antropol.* 2000;24 (suppl.1): 91-6.
- Van Den Bergh JP, Ten Bruggenkate CM, Disch FJ, Tuining DB. Anatomical aspects of sinus floor elevations. *Clin Oral Implants Res.* 2000;11(3):256-65.
- Chanavaz M. Sinus graft procedures and implant dentistry: a review of 21 years of surgical experience (1979-2000). *Implant Dent.* 2000; 9(3):197-206.
- Katanec D, Vukovojac S, Muretić Ž, Krmopotić I, Gašparac-Predanić H, Ivaniš T. Multidisciplinarni pristup rješavanju distalne parcijalne bezubosti fiksnim protetskim nadomjestkom- prikaz slučaja. *Hrvatski stomatološki vjesnik.* 1994;2:17-20.
- Woo I, Le BT. Maxillary sinus floor elevation: review of anatomy and two techniques. *Implant Dent.* 2004;13(1): 28-32.
- Solar P, Geyerhofer U, Traxler H, Windisch A, Ulm C, Watzek G. Blood supply to the maxillary sinus relevant to sinus floor elevation procedures. *Clin Oral Implants Res.* 1999;10(1):34-44.
- Garg AK. Augmentation grafting of the maxillary sinus for placement of dental implants: anatomy, physiology and procedures. *Implant Dent.* 1999;8(1):36-46.
- Smiler DG, Johnson PW, Lozada JL et al. Sinus lift grafts and endosseous implants. Treatment of the atrophic posterior maxilla. *Dent Clin North Am.* 1992;36(1):151-86.
- Ten Bruggenkate CM, Van Den Bergh JP. Maxillary sinus floor elevation: a valuable pre-prosthetic procedure. *Periodontol* 2000. 1998;17:176-82.
- Katanec D. Kompjutorizirana denzitometrijska analiza i standardizacija kliničkih i laboratorijskih kriterija u procjeni terapijske vrijednosti hidroksilapatitnih koštanih implantata (Disertacija). Zagreb: Stomatološki fakultet; 1997.
- Jensen J, Sindet-Pedersen S, Oliver AJ. Varying treatment strategies for reconstruction of maxillary atrophy with implants: results in 98 patients. *J Oral Maxillofac Surg.* 1994;52(3):210-6.
- Raghoobar GM, Vissink A, Reintsema H, Batenburg RH. Bone grafting of the floor of the maxillary sinus for the placement of endosseous implants. *Br J Oral Maxillofac Surg.* 1997;35(2):119-25.
- Raghoobar GM, Timmenga NM, Reintsema H, Stengenga B, Vissink A. Maxillary bone grafting for insertion of endosseous implants: results after 12-124 months. *Clin Oral Implants Res.* 2001;12(3):279-86.
- Buser D, Hirt HP, Dula K, Berthold H. Membrane technique/oral implantology. The simultaneous use of membranes in implants with peri-implant bone defects. *Schweiz Monatsschr Zahnmed.* 1992;102(12):1490-505.
- Misch CE. Maxillary sinus augmentation for endosteal implants: organized alternative treatment plans. *Int J Oral Implantol.* 1987;4(2):49-58.
- Stajčić Z, Stojčev Lj. Atlas oralne implantologije. Beograd: Stojčev; 2001.
- Penarrocha-Diago M, Uribe-Origone R, Guarinos-Carbo J. Implant supported rehabilitation of the severely atrophic maxilla: a clinical report. *J Prosthodont.* 2004; 13(3): 187-91.
- Mazor Z, Peleg M, Gross M. Sinus augmentation for single-tooth replacement in the posterior maxilla: a 3-year follow-up clinical report. *Int J Oral Maxillofac Implants.* 1999;14(1):55-60.
- Hürzeler MB, Kirch A, Ackermann KL, Quinones CR. Reconstruction of the severely resorbed maxilla with dental implants in the augmented maxillary sinus: a 5-year clinical investigation. *Int J Oral Maxillofac Implants.* 1996; 11(4):466-75.
- Tatum H. Maxillary and sinus implant reconstructions. *Dent Clin North Am.* 1986;30(2):207-29.
- Cawood JJ, Stoelting PJ, Bronus JJ. Reconstruction of the severely resorbed (Class VI) maxilla. A two-step procedure. *Int J Oral Maxillofac Surg.* 1994;23(4):219-25.
- Lundgren S, Nyström E, Nilson H, Gunne J, Lindhagen O. Bone grafting to the maxillary sinuses, nasal floor and anterior maxilla in the atrophic edentulous maxilla. A two-stage technique. *Int J Oral Maxillofac Surg.* 1997;26(6):428-34.
- Kent JN, Block MS. Simultaneous maxillary sinus floor bone grafting and placement of hydroxylapatite-coated implants. *J Oral Maxillofac Surg.* 1989;47(3):238-42.
- Lundgren S, Moy P, Johansson C, Nilsson H. Augmentation of the maxillary sinus floor with particulated mandible: a histologic and histomorphometric study. *Int J Oral Maxillofac Implants.* 1996;11(6):760-6.
- Raghoobar GM, Brouwer TJ, Reintsema H, Van Oort RP. Augmentation of the maxillary sinus floor with autogenous bone for the placement of endosseous implants: a preliminary report. *J Oral Maxillofac Surg.* 1993;51(11): 1198-203.

28. Krekmanov L. A modified method of simultaneous bone grafting and placement of endosseous implants in the severely atrophic maxilla. *Int J Oral Maxillofac Implants.* 1995;10(6):682-8.
29. Moses JJ, Arredondo A. Sinus lift complications: avoiding problems and finding solutions. *Dent Implantol Update.* 1997;8(9):70-2.
30. Doud Galli SK, Lebowitz RA, Giacchi RJ, Glickman R, Jacobs JB. Chronic sinusitis complicating sinus lift surgery. *Am J Rhinol.* 2001;15(3):181-6.
31. Aimetti M, Romagnoli R, Ricci G, Massei G. Maxillary sinus elevation: the effect of macrolacerations and microlacerations of the sinus membrane as determined by endoscopy. *Int J Periodontics Restorative Dent.* 2001; 21(6):581-9.
32. Kasabah S, Krug J, Simunek A, Lecaro MC. Can we predict maxillary sinus mucosa perforation? *Acta Medica (Hradec Kralove).* 2003;46(1):19-23.
33. Young MP, Korachi M, Carter DH, Worthington HV, McCord JF, Drucker DB. The effects of an immediately pre-surgical chlorhexidine oral rinse on the bacterial contaminants of bone debris collected during dental implant surgery. *Clin Oral Implants Res.* 2002;13(1):20-9.
34. Timmenga NM, Raghoebar GM, Van Weissenbruch R, Vis-sink A. Maxillary sinusitis after augmentation of the maxillary sinus floor: a report of 2 cases. *J Oral Maxillofac Surg.* 2001;59(2):200-4.
35. Esposito M, Hirsch JM, Lekholm U, Thomsen P. Biological factors contributing to failures of osseointegrated oral implants. (I) Success criteria and epidemiology. *Eur J Oral Sci.* 1998;106(1):527-51.
36. Moy PK, Lundgren S, Holmes RE. Maxillary sinus augmentation: histomorphometric analysis of graft materials for maxillary sinus floor augmentation. *J Oral Maxillofac Surg.* 1993;51(8):857-62.