

Danica Vidović Juras¹, Ana Cekić-Arambašin¹, Anđelko Vidović²

Individualne termoplastične udlage u liječenju protetskog palatitisa

Custom Thermoformed Trays in the Treatment of Denture Stomatitis

¹ Zavod za oralnu medicinu Stomatološkog fakulteta Sveučilišta u Zagrebu, Gundulićeva 5, Zagreb, Hrvatska
Department of Oral Medicine, School of Dental Medicine, University of Zagreb, Gundulićeva 5, Zagreb, Croatia

² Imunološki zavod, Rockefellerova 10, Zagreb, Hrvatska
Institute of Immunology, Rockefellerova 10, Zagreb, Croatia

Sažetak

Svrha je istraživanja ispitati djelotvornost mikonazolnog gela primijenjenog pomoću individualne termoplastične udlage kao prekonocnog držača lijeka u liječenju protetskog palatitisa, u usporedbi s klasičnom primjenom lijeka koju je propisao proizvođač. Sudjelovala su 44 nositelja mobilnih stomatoloških gornjih nadomjestaka s dijagnosticiranim protetskim palatititom. Ispitna skupina (n = 22) liječena je 2-postotnim gelom mikonazolima, a nanosio se tijekom noći u individualnu udlagu. Kontrolna skupina (n = 22) liječena je unošenjem 2,5 ml istog lijeka u usta četiri puta na dan. Određivali su se intenzitet upale i inficiranosti. Provedeni su sljedeći klinički testovi: intenzitet upale prema Newtonu, veličina eritematoznih lezija na sluznici nepca ispod ležišta nadomjestka, digitalna termometrija sluznice i bris za kulturu *Candida albicans*. Zabilježeni su i podaci o starosti, higijeni proteze i nosi li pacijent protezu tijekom noći. Rezultati su pokazali bržu i potpuniju sanaciju protetskog palatitisa u ispitnoj skupini bolesnika u odnosu prema kontrolnoj. U ispitnoj skupini zapažena je i veća redukcija kolonija kulture *Candida albicans*, što upućuje na njihovu djelotvorniju eliminaciju iz usta primjenom lijeka novom metodom. Ta metoda dodatno potiče bolesnika da slijedi upute o terapiji i higijeni nadomjestka. Individualna udlaga kao okluzijski zavoj pokazala se djelotvornijom i bolesniku ugodnijom od liječenja klasično ordiniranim antimikotikom, što bi klinički moglo biti vrlo važno u liječenju protetskog palatitisa.

Zaprimljen: 17. srpnja 2006.

Prihvaćen: 8. rujna 2006.

Adresa za dopisivanje

Danica Vidović Juras
Sveučilište u Zagrebu
Stomatološki fakultet
Zavod za oralnu medicinu
Gundulićeva 5, 10 000 Zagreb, Hrvatska
djuras@sfg.hr
Tel. +385-1-4802174
Fax +385-1-4830819

Ključne riječi

kandidijaza, oralna; stomatitis, protetski; nosači lijeka; udlaga; mikonazol

Uvod

Protetski palatititis (PP - palatititis ili stomatitis prothetica) je upala sluznice nepca i gingive u neposrednom doticaju s gornjim stomatološkim mobilnim nadomjestkom (1). Od PP-a obolijeva 24 do 60% osoba koje nose djelomične i totalne mobilne nadomjestke (2) i to češće u ženskoj populaciji, a prevalencija raste s dobi (3). Klinička slika PP-a nije jedinstvena, nego se mijenja ovisno o nizu čimbenika. Posljedica su različite klasifikacije PP-a, a najčešća je ona prema Newtonu. (4). U literaturi

Introduction

Denture stomatitis (DS) ("stomatitis prothetica", "denture sore mouth") describes inflammation of the palatal and gingival mucosa underneath the upper denture (1). DS is found in 24-60% of complete and partial denture wearers (2), more frequently females, and the prevalence is higher with age. Clinical features of DS are not unique and vary due to many reasons. Subsequently, several classifications of DS can be found, although classification according to Newton is widely accepted (4). There are numerous fac-

se navode mnogobrojni čimbenici koji se smatraju uzrokom PP-a (1-5). Budtz-Jorgensen (6) svrstava palatitis u entitete povezane s kulturom *Candida albicans* (CA). Ona je prisutna u promijenjenim uvjetima u ustima i uz sve uzročne i predisponirajuće čimbenike, čini se glavnim pokretačem razvoja. Tome osobito pridonosi stalno nošenje nadomjestka i neodgovarajuća higijena tog pomagala, jer se na njegovoj površini nakuplja plak, a on je idealno hranilište za kvasnice i druge mikroorganizme te tako pridonosi razvoju infekcije i upali sluznice u neposrednom kontaktu s ležištem mobilnoga nadomjestka (3).

Prevalencija CA-a je kod osoba koje nose mobilni nadomjestak (78,39%) dvostruko veća nego kod onih s prirodnim zubima (36,85%) (7). Kod zdravih osoba s mobilnim nadomjestkom znatno je rjeđi nalaz CA-a negoli kod bolesnika s PP-om. Intenzitet upale raste s porastom broja kolonija CA-a (8).

Liječenje PP-a usmjereno je na uklanjanje mikrobnog uzročnika iz usne šupljine lijekovima te na provedbu različitih mehaničkih, kemijskih i fizikalnih postupaka zaštite nadomjestka od infekcije. Time se saniraju već postojeće upalne i druge promjene koje definiraju PP ili se prevenira njihov nastanak. Od svih antimikotika u liječenju se najčešće koristi mikonazol i to kao 2-postotni gel. Mikonazol je imidazolski, širokospektralni antimikotik, posebice djelotvoran na vrste roda *Candida*. Fungistatik je, a može djelovati i fungicidno, ovisno o koncentraciji. Primijenjen lokalno nema ni alergizirajući, ni iritirajući efekt. Ne djeluje ni teratogeno, ni embriotoksično. U klasičnoj primjeni liječenja PP-a, 2,5 ml mikonazolskog gela rabi se četiri puta na dan i zadržava nekoliko minuta u ustima, a zatim proguta. Liječenje traje od dva do pet tjedana, do potpunog nestanka lezije. Nakon toga se preporučuje još nekoliko dana nastaviti liječenje kako bi se spriječio recidiv (9, 10).

Liječenje PP-a uspješno je samo ako uključuje i antimikrobni tretman nadomjestka, čime se prevenira reinfekcija kontaminiranim nadomjestkom. U vezi s tim opisano je mnoštvo preparata i postupaka od kojih ističemo: mehaničko čišćenje nadomjestka četkanjem abrazivnom pastom, tretman različitim kemijskim otopinama, sterilizaciju mikrovalovima i dezinfekciju ozonskim mjehurićima (3).

Svrha ovog istraživanja bila je ocijeniti djelotvornost novog načina primjene mikonazolskog gela u okluzijskom zavoju, pomoću individualne udlage kao cjelonožnog nosača lijeka, u usporedbi s djelotvornošću klasično primijenjenoga mikonazol-

tors contributing to the development of DS described in literature (1-5). Budtz-Jorgensen (6) classifies DS as entity related to *Candida albicans* (CA). The presence of CA in the altered oral environment together with all above mentioned etiologic and predisposing factors seems to be a major initiative factor in the development of DS. Constant denture wearing and inadequate denture hygiene results in the plaque accumulation on the denture surface, which is ideal nursery for fungi and other microorganisms, contributing to the infection and inflammation of the mucosa in direct contact with the dentures (3).

The prevalence of CA in complete denture wearers (78.39%) is two-fold higher when compared to the dentate persons (36.85%) (7). The finding of candidal infection in healthy denture wearers is less frequent when compared to those with DS. The inflammation intensity increases with increase of CA colony count (8).

Treatment of DS is directed toward elimination of microbial agent from the oral cavity by use of medication, together with the use of various mechanical, chemical and physical infection control measures for dentures. By using the above mentioned procedures, already present pathologic changes can be cured or their development can be prevented. The drug most frequently used among antifungals is miconazole, usually available in the form of 2% gel. Miconazole is imidazole, a broad spectrum antifungal drug, especially effective on *Candida* species. It has fungistatic properties, sometimes fungicidal, depending on its concentration. When applied locally it has neither allergenic nor irritational effect. It has been also documented that no teratogenic or embryotoxic properties are found within its use. It is recommended to be used four times daily in a single dose of 2,5 ml, held in the mouth for few minutes and then swallowed. The treatment period includes 2-5 weeks until the definitive resolution of lesions. It is recommended that treatment should be continued for the next few days after the lesions have disappeared in order to prevent recurrence (9, 10).

The DS therapy is considered successful only when the antimicrobial treatment of the dentures is included in order to prevent the reinfection of the oral cavity with the contaminated appliance. Various medications and procedures have been described for prevention of these pathologic changes: mechanical cleaning of the denture by use of brush with abrasive paste, treatment with various chemical solutions, microwave sterilization and ozone disinfection (3).

skog gela. Očekivana hipoteza pokusa bila je da će učinak novog načina primjene biti djelotvorniji od klasičnoga.

Ispitanici i postupci

U ispitivanju su sudjelovala 44 ispitanika (31 žena i 13 muškaraca) s potpunim stomatološkim ili djelomičnim gornjim mobilnim nadomjescima u dobi od 39 do 100 godina (prosječna dob 74 godine) s klinički dijagnosticiranim PP-om. Metodom slučajnog uzorka podijeljeni su u dvije skupine - ispitnu i kontrolnu. Ispitnu skupinu činila su 22 ispitanika kod kojih je liječenje obavljeno uz pomoć individualnog nosača lijeka, a u kontrolnoj su bila 22 ispitanika, a liječeni su klasično.

Klinički pregledi

Svaki ispitanik ispitne i kontrolne skupina klinički je pregledan sedam puta i to sljedećim režimom: *0. dan* - 1 dan prije početka terapije mikonazolom; *2. dan* - 2 dana nakon početka terapije mikonazolom; *4. dan* - 4 dana nakon početka terapije; *6. dan* - 6 dana nakon početka terapije; *8. dan* - 8 dana nakon početka terapije; *14. dan* - 14 dana nakon početka terapije. Tada je prekinuta uporaba mikonazola i ispitanici su pregledani i *21. dan* - 7 dana nakon završetka terapije. Tijekom svakoga kliničkog pregleda zapisane su sve patološke promjene u ustima, posebice na sluznici nepca ispod ležišta nadomjestka. Za opis intenziteta upale sluznice nepca koristili smo se klasifikacijom prema Newtonu (4). Registrirana je i veličina eflorescencija na sluznici. Eritematozna područja su, što je bilo moguće preciznije, aproksimirana u poligone čije su se stranice prenosile šestarom na papir na kojemu se naknadno računala površina u četvornim centimetrima. Kako bi se potvrdila upala, mjerila se i temperatura na tri mjesta na nepcu digitalnim termometrom DT-1 (FER, Hrvatska), i to u središtu gornjih sekstanata obilježenih prema sustavu Svjetske stomatološke udruge (WHO-a) za obilježavanje površina u usnoj šupljini (desni gornji sekstant - 03; prednji gornji sekstant - 04; lijevi gornji sekstant - 05) (11) Zabilježena je srednja kumulativna vrijednost triju mjerenja tijekom 0., 14. i 21. dana.

Zabilježena je starost i stupanj higijene nadomjestka te nose li ga pacijenti i noću.

Higijena nadomjestka ocijenjena je na temelju količine plaka, kamenca i pigmentacije na površi-

The aim of this study was to evaluate the efficacy of newly introduced procedure of miconazole gel delivery as applied in occlusal splint using custom tray as an overnight drug carrier, as well as its comparison with classically applied miconazole gel. This study's hypothesis is that the new method is more efficient than the classic one.

Subjects and Methods

44 participants (31 women and 13 men) were included in this study with either complete or partial upper dentures, age range 39-100 yrs (mean 74 yrs), with clinically confirmed diagnosis of DS. Randomly selected participants were divided into two groups: experimental and control. The experimental group consisted of 22 participants which were treated with miconazole gel in custom tray as a drug carrier. Control group consisted of 22 participants who were classically treated.

Clinical examination

Every participant from the experimental group was examined seven times according to the following procedure: *day 0* - one day before miconazole therapy, *2nd day* - two days after miconazole therapy introduction, *4th day* - four days after miconazole therapy introduction, *6th day* - sixth day after miconazole therapy introduction, *8th day* - eight days after miconazole therapy introduction, *14th day* - fourteen days after miconazole therapy introduction. The use of miconazole was disrupted and participants were re-examined on the *day 21* - 7 days after the therapy termination. The clinical examination included the registration of all pathological changes, especially on the palatal mucosa underneath denture base. Inflammatory changes on the palatal mucosa were graded according to Newton (4). The size of mucosal lesions were also recorded. Erythematous areas of the palatal mucosa were, as precisely as possible under the circumstances, approximated in polygons whose sides were transferred to the paper, and subsequently were made calculations of affected area in cm². In order to confirm inflammation, temperature was measured on three different locations on the palate using digital thermometer DT-1 (FER, Croatia): in the midline of upper sextants which were marked according to WHO system (right upper sextant - 03; frontal upper sextant - 04; left upper sextant - 05) (11). The mean cumulative value of the three measurements was noted.

Oldness and hygiene status of every appliance was recorded as well as habit of overnight denture

ni materijala nadomjestka i ocijenjena je kao: dobra [3] - bez plaka, kamenca i pigmentacije na nadomjestku; zadovoljavajuća [2] - nalaz kamenca samo s vanjske vestibularne strane površine ne veće od 1 cm; loša [1] - naslage plaka, kamenca i pigmentacije prisutne s nepčane strane nadomjestka (12).

Mikološke kulture

Od svih ispitanika uzeti su ubrisci za mikološku dijagnostiku za *Candida spp.* prije terapije mikonazolom – nulti dan i sedam dana nakon terapije, tj. dvadeset i prvi dan. Ubrisci su sterilnim vatiranim štapićem uzeti sa sluznice nepca i vestibuluma gornje čeljusti te su naneseni na hranjivu podlogu Sabouraud-dextrose agar (Becton-Dickinson & Co, Cockeysville, SAD). Nakon inkubacije od 48 sati u aerobnim uvjetima u termostatu na temperaturi 37°C, očitana je broj kolonija *Candida spp.* Analiza nalaza mikološke kulture odnosila se na brojnost kolonija i procijenjena je semikvantitativno te iskazana u stupnjevima prema Olsenu: stupanj 0 = bez nalaza kolonija; stupanj 1 = 1 - 9 kolonija; stupanj 2 = 10 - 24 kolonija, stupanj 3 = 25 -100 kolonija; stupanj 4 = konfluentni rast kolonija (13).

Liječenje

Kod svih se ispitanika za dvotjedno liječenje PP-a koristio 2-postotni mikonazol u obliku gela (Rojazol gel, Belupo, Koprivnica, Hrvatska). Ispitna skupina liječena je 2-postotnim mikonazolom gelom apliciranim tijekom cijele noći u individualnom nosaču lijeka od folije koja se može termički oblikovati, dakle, metodom okluzijskog zavoja. Kontrolna skupina tretirana je 2-postotnim mikonazolom gelom klasično ordiniranim prema uputi proizvođača (10). Ti su ispitanici četiri puta na dan oblagali sluznicu usne šupljine s pola mjerne žlice (2,5 ml) lijeka. Higijenu nadomjestka u obje skupine, kako bi se spriječila reinfekcija, obavljali su svaku večer sami ispitanici prema našoj uputi: mehaničkim četkanjem, zatim uranjanjem nadomjestka pet minuta u 2 postotni NaOCl i ispiranjem dvije minute pod mlazom vode te ostavljanjem preko noći u čaši s vodom. Taj dio postupka nije bio pod nadzorom autora.

Izrada okluzijskog zavoja i upute bolesnicima ispitne skupine

Bolesnicima ispitne skupine uzet je anatomski alginatni otisak gornje čeljusti i napravljen odljev od tvrde sadre. Odljev je na mjestu ležišta nadomjestka cirkularno jedan centimetar od ruba prema-

wearing. Denture hygiene was evaluated on the basis of the plaque presence, calcifications and pigmentations on the surface of the material and was graded as: good [3] - without plaque, stones and pigmentations; satisfying [2] - presence of stones only on the external vestibular side of the denture, in the area not bigger than 1 cm; inadequate [1] - plaque accumulation, calcifications, pigmentations present on the palatal side of the denture (12).

Candida cultures

Prior to the investigation the swabs for *Candida* detection were taken from each participant on the day 0, and seven days after treatment, i.e. on the 21st day. The swabs were taken by sterile cotton stick from palatal mucosa and vestibular part of the upper jaw and incubated on Sabouraud's-dextrose agar base (Becton-Dickinson & Co, Cockeysville, USA). After the 48 hours incubation period at the temperature of 37°C, the count of *Candida* colonies was recorded. The analysis included the found colonies that were further semi-quantitatively evaluated and graded according to Olsen: stage 0 = no colonies found; stage 1 = 1-9 colonies; stage 2 = 10-24 colonies; stage 3 = 25-100 colonies; stage 4 = confluent growth of colonies (13).

Treatment

All the participants were prescribed the 2% miconazole gel (Rojazol gel, Belupo, Koprivnica, Croatia) during fourteen days. The experimental group was treated with 2% miconazole gel which was applied overnight in the drug carrier custom made from thermoformed foil as method of occlusive dressing. In the control group, participants were prescribed 2% miconazole gel, classically recommended by the manufacturer (10). These participants were instructed to apply miconazole gel in the oral cavity four times daily using half of the provided spoon (2,5 ml). Both groups performed denture hygiene in order to prevent reinfection: every evening the procedure included mechanical brushing, subsequent soaking of dentures into 2% NaOCl for fifteen minutes and rinsing for two minutes under running water and left overnight in a glass of water.

Formation of the occlusal splint and instructions to the participants in the experimental group

After the alginate impression of the upper jaw had been taken, hard plaster cast was made. The cast was circularly isolated with varnish 1 cm around the edge of the denture base approximately to the total

zan slojevima laka za izolaciju do debljine približno 0,3 mm (Slika 1.). Na premazani odljev termički je prilagođena termoplastična folija u termopreši Erkopress ES 2002 (Erkodent, Njemačka). Folija je izrezana škaricama do spojišta pomične i nepomične sluznice (Slika 1.). Oštri rubovi folija obrađeni su LISKO diskovima i frezama (Erkodent, Njemačka) radi prevencije eventualne iritacije sluznice usne šupljine pri nošenju. Model je premazan lakom za izolaciju kako bi se stvorio prostor u foliji za ampu koja će sadržavati lijek.

Tijekom predaje gotove udlage ispitanicima su dane sljedeće upute:

Prije aplikacije noćnog okluzijskog zavoja usta je potrebno jednokratno premazati s pola mjerne žlice (2,5 ml) mikonazolnog gela. Zatim se u individualnu udlagu stavlja tanki premaz mikonazolnog gela i zavoj nosi cijelu noć. Ujutro se nosač lijeka treba isprati od termoplastične folije i osušiti te danju rabiti mobilni nadomjestak.

Statistička analiza

S obzirom na to da podaci nisu bili normalno distribuirani, u analizi se koristila neparametarska statistika. Sve analize koje uključuju više od dva ponovljena mjerenja provedene su testom Friedman ANOVA, a nakon toga slijedile su višestruke usporedbe parova unutar skupina prema Conoveru. U slučaju dva ponovljena mjerenja koristio se Wilcoxonov test. Usporedbe između skupina obavljene su Mann-Whitneyjevim testom s korekcijama za višestruke usporedbe prema Bonferroniju. Podaci su analizirani pomoću statističkoga programskog paketa Statistica 6,0 (StatSoft, Tulsa, SAD).

Rezultati

Stupanj upale nepca

Stupanj upale nepca bolesnika (koji smo derivirali iz klasifikacije prema Newtonu) prije liječenja bio je najčešće 2 i 3. Prije terapije mikonazolnim gelom skupine se statistički nisu razlikovale ($p = 0,589$). Nakon završetka liječenja (14. dan) u obje su skupine upale znatno smanjene. Ipak, učinkovitost liječenja bila je izraženija u ispitnoj skupini – znatno je smanjen stupanj upale u usporedbi s kontrolnom skupinom ($p < 0,001$) (Slika 2.). Većina bolesnika ispitne skupine, osim petorice, na kraju terapije nije imala upalu. Nakon liječenja većina bolesnika iz kontrolne skupine imala je još naznake upale (stupnjevi 1 do 3), a samo šest je bilo bez upale.

thickness of 0.3 mm (Figure 1.). Thermoplastic foil was adapted on the overlaid cast in thermo-pressing machine Erkopress ES 2002 (Erkodent, Germany). The foil was cut to the mucogingival junction of the mucosa (Figure 1). Sharp foil edges were adjusted with LISKO polishers and special burrs (Erkodent, Germany) in order to prevent the irritation of the oral mucosa. Varnish overlay provides additional space under the foil for drug application.

Instructions to participants

Before the application of the overnight occlusal splint, half of the measuring spoon (2,5 ml) of the miconazole gel should be taken into the mouth, swished and swallowed. Besides that a thin layer of miconazole gel should be applied into the custom tray which is to be worn overnight. In the morning a thermoformed foil drug carrier should be washed and dentures should be worn during the day.

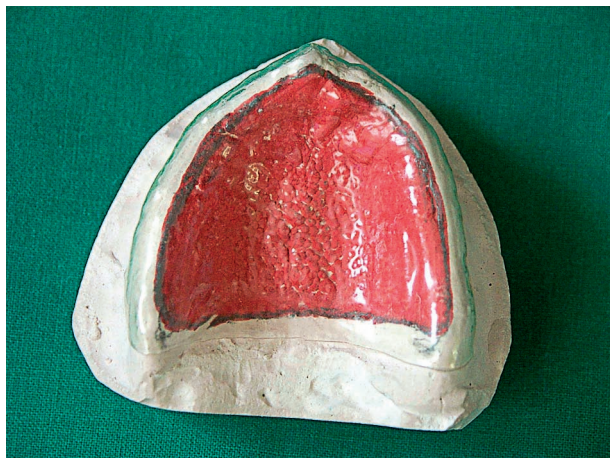
Statistical analyses

Since the data didn't follow Gaussian distribution, nonparametric statistical analyses was used. All the repeated measures analyses with more than two assessments were performed using Friedman ANOVA followed by within-group pairwise multiple comparisons according to Conover. In case of two repeated measurements, Wilcoxon signed rank test was used. Between-group comparisons were made by Mann-Whitney tests with Bonferroni corrections for multiple comparisons. The data were analyzed using Statistica 6.0 software (StatSoft, Tulsa, USA).

Results

Stage of the palatal inflammation

The inflammatory intensity (as derived by classification according to Newton) most frequently found before treatment was 2 and 3. Before miconazole gel was applied (day 0) no significant differences in intensity of palatal inflammation between the experimental and control group was found ($p = 0.589$). Reduction of inflammation was significant in both groups at the end of the treatment (day 14). However, treatment effect was more pronounced in the experimental group with the inflammation intensity significantly lower when compared to the control group ($p < 0.001$) (Figure 2.). Most of the participants in the experimental group were free from inflammation and only 5 subjects were still showing signs of inflammation. After the treatment, majority of control subjects still had inflammation (grade 1-3) and only 6 participants were devoid of signs.



Slika 1. Odljev gornje čeljusti od tvrde sadre s individualnom udlagom. Obratiti pozornost na papilarnu hiperplaziju tvrdog nepca (*Newton III*).

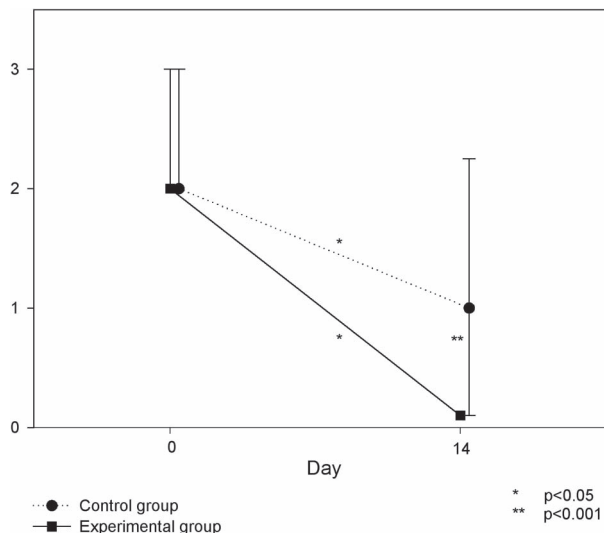
Figure 1. Cast of the upper jaw with individual tray. Note papillary hyperplasia of the hard palate (*Newton III*).

Eritem

Prije primjene mikonazolnog gela (nulti dan) između ispitne i kontrolne skupine nije bilo statističke razlike srednje površine eritema ($p = 0,540$). Tijekom terapije površina eritema znatno se promijenila u obje skupine ispitanika - kontrolnoj (Friedman ANOVA $\chi^2 = 82,44$, $df = 6$, $p < 0,001$) i ispitnoj (Friedman ANOVA $\chi^2 = 113,71$, $df = 6$, $p < 0,001$). Znatno smanjenje zapaženo je četvrti dan u obje skupine (dan 4. vs. dan 0., $p < 0,001$) uz konstantno niske vrijednosti do kraja studije (Slika 3.). Ispitna je skupina u usporedbi s kontrolnom imala znatno niži medijan eritematozne površine drugog dana terapije i ostala je takva tijekom istraživanja. Nakon terapije (14. dan) medijan eritematoznog područja reduciran je u ispitnoj skupini prosječno za 94% u odnosu prema početnoj vrijednosti, a u kontrolnoj skupini pronađena je prosječna redukcija od 59%. U posljednje tri vremenske točke nije bilo eritematoznog područja na nepcu kod većine bolesnika ispitne skupine (kod 19 od 22). Nakon liječenja medijan eritematoznog područja u ispitnoj je skupini bio znatno niži u usporedbi s kontrolnom skupinom ($p < 0,001$).

Temperatura

Na prvom pregledu digitalni je termometar pokazao srednji zbroj temperaturnih vrijednosti izmjerenih u sredini triju gornjih sekstanata u ispitnoj sku-



Slika 2. Usporedba intenziteta upale nepca (prema Newtonu) između ispitne i kontrolne skupine prije terapije i nakon nje. Točke predstavljaju medijane, a okomite crte interkvartilni raspon.

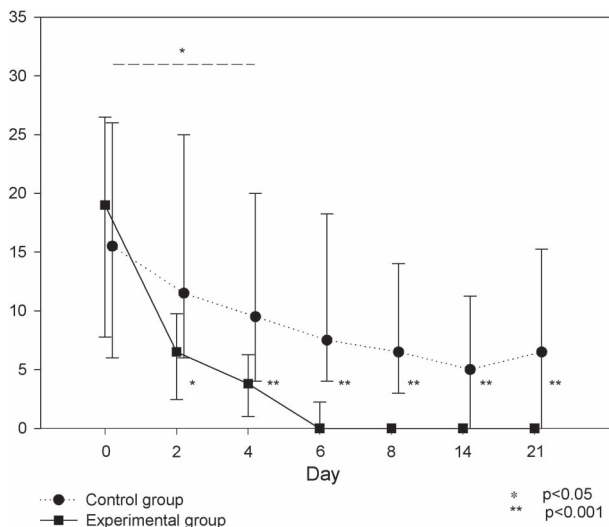
Figure 2. Comparison of palatal inflammation intensity (according to Newton) between the experimental and control group before and after treatment. The points represent medians and the error bars denote interquartile range.

Erythema

Before miconazole gel was applied (day 0) no significant differences in median erythematous area between the experimental and control group was found ($p = 0.540$). Erythematous area significantly diminished over time in both control (Friedman ANOVA $\chi^2 = 82.44$, $df = 6$, $p < 0.001$) and experimental group (Friedman ANOVA $\chi^2 = 113.71$, $df = 6$, $p < 0.001$). Significant decline was noted on the day 4 in both groups (day 4 vs. day 0, $p < 0.001$) and remained constantly low throughout the study (Figure 3). The experimental group had significantly lower median erythematous area than the control group on the second day of the treatment and remained lower during the study. After the treatment (day 14) median erythematous area was averagely reduced by 94% from the initial in the experimental group, whereas in the control group average reduction of 59% was found. On the last three assessments, erythematous area was not measurable in the majority of subjects in the experimental group (19 of 22). After the treatment, median erythematous area in the experimental group was significantly lower when compared to the control group ($p < 0.001$).

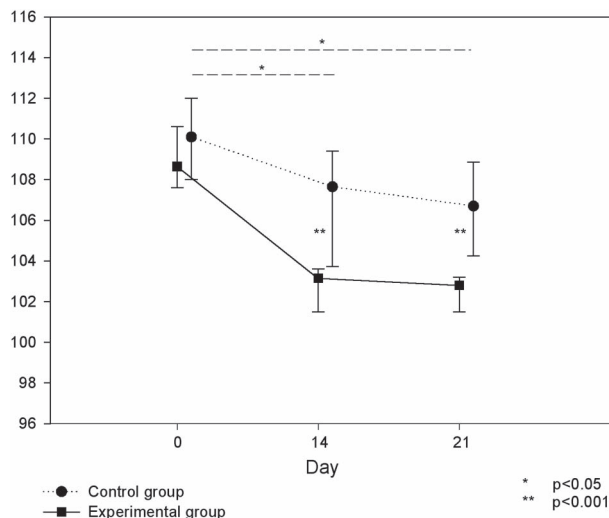
Temperature

Initial measurement with digital thermometer revealed median sum of temperature values measured in the midline of three upper sextants of 108.7°C (in-



Slika 3. Usporedba srednje površine eritema između ispitne i kontrolne skupine od 0. do 21. dana. Točke predstavljaju medijane, a okomite crte interkvartilni raspon.

Figure 3. Comparison of median erythematous surface between experimental and control group in days 0-21. The points represent medians and the error bars denote interquartile range.



Slika 4. Usporedba temperaturnih zbivanja na dan 0., 14. i 21. između ispitne kontrolne skupine. Temperaturne vrijednosti (x-os) predstavljaju zbroj temperatura izmjerenih u središtima triju gornjih sekstanata (WHO). Točke predstavljaju medijane, a okomite crte interkvartilni raspon.

Figure 4. Comparison of temperature events on the day 0, 14 and 21 between experimental and control group. Temperature events (x-axis) represent sum of temperature values measured in the midline of three upper sextants (according to WHO). The points represent medians and the error bars denote interquartile range.

pinu $108,7^{\circ}\text{C}$ (interkvartilni raspon, $107,6 - 110,6$), a u kontrolnoj $110,1^{\circ}\text{C}$ ($108,0 - 112,0$). Neposredno prije terapije mikonazolom, nultog dana, usporedbom između ispitne i kontrolne skupine nije pronađena statistički znatna razlika ($p = 0,123$), što je te skupine činilo usporedivima. Četrnaestoga dana u ispitnoj skupini srednja izmjerena temperatura bila je $103,2^{\circ}\text{C}$ ($101,5 - 103,6$), a u kontrolnoj $107,7^{\circ}\text{C}$ ($103,8 - 109,4$). Dvadeset i prvi dan u ispitnoj skupini srednja izmjerena temperatura bila je $102,8^{\circ}\text{C}$ ($101,5 - 103,2$), a u kontrolnoj $106,7^{\circ}\text{C}$ ($104,5 - 108,6$) (Slika 4.). Temperaturne vrijednosti znatno su se smanjivale u kontrolnoj skupini (Friedman ANOVA $\chi^2 = 35,43$, $df = 6$, $p < 0,001$) i u ispitnoj skupini (Friedman ANOVA $\chi^2 = 23,14$, $df = 6$, $p < 0,001$). No, učinkovitost tretmana bila je izrazitija u ispitnoj skupini sa znatno nižim temperaturnim vrijednostima na kraju terapije (dan 14., $p < 0,001$) i sedam dana nakon završetka terapije (dan 21., $p < 0,001$).

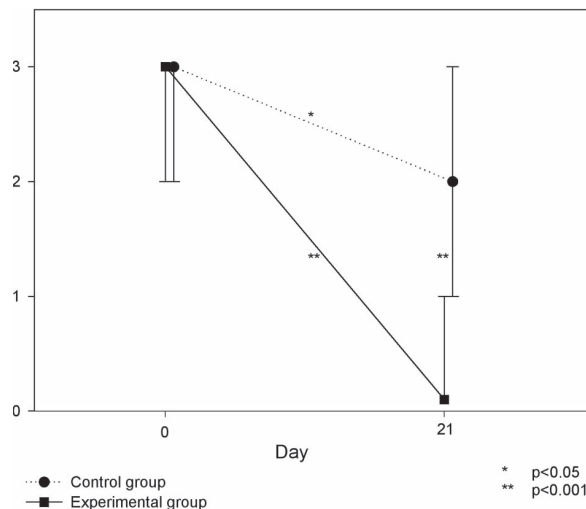
Inficiranost nepca CA-om

Usporedbom ispitne skupine s kontrolnom ustanovljeno je da nema statistički znatne razlike između skupina prije terapije ($p = 0,879$), što ih čini usporedivima. U obje skupine pronađeno je statistički

interkvartilni raspon, $107,6 - 110,6$) in the experimental group, and $110,1^{\circ}\text{C}$ ($108,0 - 112,0$) in the control group, respectively. No significant differences in temperature values on the day 0 before miconazole gel was applied between the experimental and control group were found ($p = 0,123$). On the fourteenth day, median measured temperature was $103,2^{\circ}\text{C}$ ($101,5 - 103,6$) in the experimental group, and $107,7^{\circ}\text{C}$ ($103,8 - 109,4$) in the control group, respectively. On the twenty first day, median measured temperature was $102,8^{\circ}\text{C}$ ($101,5 - 103,2$) in the experimental group, and $106,7^{\circ}\text{C}$ ($104,5 - 108,6$) in the control group, respectively. Temperature events significantly declined during the treatment in the control group (Friedman ANOVA $\chi^2 = 35,43$, $df = 6$, $p < 0,001$), as well as experimental group (Friedman ANOVA $\chi^2 = 23,14$, $df = 6$, $p < 0,001$). Nevertheless, the effect of treatment was more pronounced in the experimental group with the temperature events significantly lower than those of control group at the end of treatment (day 14., $p < 0,001$) and 7 days after the treatment (day 21., $p < 0,001$).

Palatal infection with CA

Comparison between experimental and control group showed no significant difference in candidal infection stage before the treatment ($p = 0,879$). In-



Slika 5. Usporedba inficiranosti nepca (izražena stupnjevima prema Olsenu) između ispitne i kontrolne skupine prije terapije i nakon nje. Točke predstavljaju medijane, a okomite crte interkvartilni raspon.

Figure 5. Comparison of palatal infection stage (graded according to Olsen) between experimental and control group before and after treatment. The points represent medians and the error bars denote interquartile range.

znatno smanjenje inficiranosti nepca nakon terapije i to dvadeset i prvi dan (za ispitnu skupinu $p < 0,001$, za kontrolnu skupinu $p < 0,05$). Ipak, nakon terapije u ispitnoj je skupini pronađena statistički znatno manja inficiranost nepca CA-om u odnosu prema kontrolnoj skupini ($p < 0,001$) (Slika 5.). Nakon terapije više od polovice (15) bolesnika iz ispitne skupine nije bilo inficirano, dok je većina kontrolnih ispitanika još bila inficirana, a samo kod tri bolesnika količina CA-a svedena je na nulti stupanj prema Olsenu tj. nisu bili inficirani.

Stanje stomatološkoga mobilnog nadomjestka

Prosječna starost protetskog nadomjestka ispitne skupine bila je 12,5 godina, a kontrolne 13,1. 77,3% pripadnika ispitne skupine i 86,4% iz kontrolne skupine redovito su prije terapije i noću nosili nadomjestak.

Prije terapije među ispitanicima ispitne skupine higijena nadomjestka bila je u 68,2% slučajeva loša, u 22,7% zadovoljavajuća, a u 9,1% dobra. Među ispitanicima kontrolne skupine 63,6% bolesnika loše je održavalo higijenu nadomjestka, 27,3% zadovoljavajuće i 9,1% dobro.

Nakon terapije, dvadeset i prvi dan, higijena nadomjestka poboljšana je kod 59,1% bolesnika ispitne skupine, a u kontrolnoj skupini nije bilo poboljšanja.

Rasprava

PP je prisutan kod 24 do 60% nositelja stomatoloških mobilnih gornjih potpunih i djelomičnih nadomjestaka (2), a terapija toga patološkog entiteta

fection stage of the palate was significantly lower in both groups after the treatment on the day 21 (the experimental group: $p < 0,001$; control group: $p < 0,05$). However, after the treatment, candidal infection stage in the experimental group was significantly lower compared to the controls ($p < 0,001$) (Figure 5). While more than a half of the subjects (15) in experimental group were not infected after the treatment, most of the control subjects still had infection present and only 3 subjects were not infected.

Dentures

Average age of the denture in the experimental group was 12.5 yrs, and in the control group 13.1 yrs, respectively. Prior to the treatment 77.3% of the participants in the experimental group as well as 86.4% in the control group wore dentures overnight on a regular basis. In all the participants denture hygiene was determined. In the experimental group denture hygiene was inadequate in 68.2%, satisfying in 22.7% and good in 9.1% participants.

In the control group, 63.6% participants had inadequate denture hygiene, 27.3% satisfying and 9.1% good.

After the treatment on the twenty-first day, denture hygiene was approved in 59,1% of participants in the experimental group, and in the control group no benefit was registered.

Discussion

The prevalence of DS in upper denture wearers is 24-60% (2), and due to its multifactorial and aetiology the therapy is complex. Furthermore, lit-

je, posljedično multifaktorijalnoj etiologiji, složena pa u literaturi pronalazimo opisane mnogobrojne terapijske mogućnosti. Idealne terapije još nema, a za liječenje se preporučuju antimikotici (3,9,10). Ovim ispitivanjem dokazana je upala visokog stupnja kod bolesnika s PP-om, koja je znatno smanjena kod ispitanika s individualnom udlagom kao nosačem protugljivičnog lijeka – 2-postotnog mikonazolskog gela u odnosu prema ispitanicima kontrolne skupine koji su se tim lijekom koristili klasično. Mnogi autori istaknuli su blagotvorno terapijsko djelovanje mikonazola primijenjenog kod bolesnika s PP-om. Rezultate ovog istraživanja moguće je usporediti samo u kontrolnoj skupini, jer se primjena individualne udlage kao nosača mikonazolskog gela prvi put opisuje u literaturi. U literaturi smo pronašli samo dva slična idejna rješenja, ali bez prostora – ampule koja sadržava lijek. Tako Wray (14) opisuje akrilatnu labijalnu udlagu kao pomoć u aplikaciji kortikosteroidnog lijeka i poboljšanju estetskog dojma kod bolesnika s deskvamativnim gingivitisom, a Brown (15) istu plastičnu udlagu opisuje kao pomoćno sredstvo u liječenju diskoidnog lupusa eritematodesa topikalnim steroidima.

Eritem sluznice, kao najvažniji klinički pokazatelj PP-a koji korelira sa stupnjem upale, pokazao je znatniju redukciju u ispitnoj skupini, a što pokazuje bolju efikasnost primjene lijeka udlagom.

To što se upala ustanovila mjerenjem temperature digitalnim termometrom, pokazalo je redukciju temperature u obje skupine. Znatno smanjenje temperaturnih vrijednosti pronađeno je u ispitnoj skupini u odnosu prema kontrolnoj, a što pokazuje da primjena mikonazola u individualnoj udlazi znatnije smanjuje upalu. Taj rezultat nije moguće usporediti s ispitivanjima drugih autora.

Također je u ispitnoj skupini zapažena i znatno bolja redukcija broja kolonija CA-a.

S obzirom na to da su svakodnevnu higijenu nadomjestka ispitanici obavljali u svojim domovima, postupak nije bio pod nadzorom osoba koje su obavljale istraživanje. Budući da je higijena nadomjestka ispitne skupine tijekom terapije jako poboljšana, što se nije dogodilo u kontrolnoj, pretpostavlja se da ispitivana metoda dodatno potiče bolesnika da slijedi upute o terapiji i higijeni.

Rezultati ove kliničke studije pokazuju da je cjelonoćna aplikacija udlagom učinkovitija u liječenju PP-a od dosadašnjega, klasičnog načina primjene 2-postotnog mikonazolskog gela. Klasično ordinirani mikonazolski gel slinom se razrjeđuje, a pokretljivost oralne muskulature dodatno smanjuje njegovu

temperature provides numerous therapeutic approaches. Ideal therapeutic approach for treatment of DS has not yet been discovered and so far antifungal drugs have been proposed for treating those patients (3,9,10). This study confirmed findings of intense inflammation in patients with DS, which was significantly reduced after application of antifungal drug – 2% miconazole gel in custom tray as a carrier when compared to control group with classically applied drug. Numerous authors reported beneficial therapeutic effects with use of miconazole in patients with DS (2-4, 9). The results of this study could be compared to other studies only in the control group, whereas custom tray as a drug carrier appliance for miconazole is a method reported for the first time in the literature. In the literature only two similar concepts could be found, but without the space – ampoule as drug container. Wray (14) reported acrylic labial veneers as help in delivering corticosteroids and improving aesthetics in patients with desquamative gingivitis, and Brown (15) reported the same plastic tray being helpful in steroid treatment of discoid lupus erythematosus.

Mucosal erythema, as the most prominent clinical sign of DS which correlates with inflammatory stage, showed more significant reduction in the experimental group, as a result of more efficient drug application with tray.

Measurement of inflammatory changes by use of digital thermometer showed thermal reduction in both tested groups. Significant temperature reduction was seen in experimental group when compared to controls, indicating that the treatment with miconazole gel being applied in the custom tray results in a more significant inflammation reduction. This result could not be compared to studies of other authors.

Also, in the experimental group, significant reduction of *Candida* colony count was noticed.

Denture hygiene in the experimental group was significantly better in comparison to controls, indicating that the investigated method might additionally motivate the patients in maintaining denture hygiene. The everyday hygiene was performed by the participants in their own homes and the procedures weren't controlled by the investigators.

The results of this study show that drug application by overnight use of tray is more effective than classically applied 2% miconazole gel. Classically applied miconazole gel is diluted with saliva, and movements of the oral musculature additionally reduce its presence in the oral cavity. CA is therefore

postojanost. CA je zato tijekom klasičnog tretmana prekratko izložen djelovanju terapijske koncentracije antimikotika, pa se ordinirani lijek mnogo brže eliminira iz usne šupljine, čime se skraćuje vrijeme njegova djelovanja, a time i učinak.

Klasična metoda liječenja zahtijeva četiri aplikacije tijekom dana, a terapijski postupak remeti dnevne aktivnosti i zato se smatra nepraktičnim. Ispitivana metoda, s aplikacijom lijeka tijekom cijele noći, bolesniku je zato praktičnija i ugodnija. Naime, zbog terapije PP-a potrebno je izvaditi mobilne stomatološke nadomjestke kako bi lijek bio u doticaju s mikroorganizmima, a ne prekriven protezom kao fizičkom zaprekom. U tom bi slučaju bolesnik bio veći dio dana bez zuba, što je često socijalno neprihvatljivo i indicira da je poželjna terapija tijekom noći.

Potrebno je istaknuti kako okluzijski zavoj od termoplastične folije ne može iz više razloga biti zamijenjen mobilnim nadomjestkom kao nosačem lijeka. Nadomjestak se ne smije nositi 6 do 8 sati tijekom dana zbog prevencije termičkih i mehaničkih iritacija. Veliki dio površine individualne udlage nije u kontaktu s nepčanom sluznicom, što onemogućuje mehanički iritativni učinak. Uporabom postojećeg nadomjestka ostao bi mehanički iritacijski učinak. Individualna žlica vrlo je tanka za razliku od gornjega mobilnog stomatološkog nadomjestka i tako ne djeluje termički kumulativno, a time i stimulativno u patogenezi PP-a. Bolje je protezu noću, nakon temeljitog četkanja, držati u nekoj od otopina jačeg antimikrobnog djelovanja kako bi se što bolje uklonio biofilm. U ovom smo se slučaju koristili 2-postotnim NaOCl-om koji bi, primijenjen intraoralno, mogao djelovati toksično. Iako djelotvoran na sluznici, sam mikonazol ne bi bio dostatan za temeljito skidanje biofilma s porozne protezne površine, što potvrđuje nova studija Lamfona i suradnika (16).

Ako bi mikonazolski gel bio apliciran postojećim stomatološkim nadomjestkom, ne bi djelovao na cijelu površinu proteze zbog ispiranja lijeka, pa bi CA na nekom dijelu nastavio egzistirati. Aplikacijom mikonazolskog gela u postojećem nadomjestku, zbog mišićnih kontrakcija čeljusti i jake adhezije, dogodilo bi se potpuno istiskivanje lijeka, budući da za njega ne postoji proširenje kao u okluzijskom zavoju, čime bi terapijski učinak bio prekinut.

Ispitivana metoda aplikacije mikonazolskog gela individualnim nosačem lijeka pokazala je svoje prednosti: lijek je tijekom terapijskog djelovanja zaštićen od razrjeđivanja slinom i ne uklanja se kret-

exposed too shortly to the therapeutical concentrations of antifungal drug, i.e. classically applied drug is quickly eliminated from the oral cavity which shortens the time of drug effect.

Classical application includes taking medication four times a day, which interferes with daily activities and therefore could be considered as inconvenient. Investigated method with overnight application of antifungal drug is therefore more practical and convenient for the patient. When treating DS dentures are removed from the oral cavity thus allowing the contact between drug and microbial agents, otherwise the denture acts as a physical barrier. As a result, patient would have to be without dentures during parts of the day which is socially unacceptable.

It is worth mentioning that occlusal splint made of thermoformed foil cannot be replaced with present denture as a drug carrier due to several reasons. The dentures are not to be worn 6-8 hours daily also to prevent thermal and mechanical irritation. The major part of the custom tray is not in contact with palatal mucosa, and therefore the possibility of mechanical irritation is eliminated. Irritational effect would obviously remain in case of miconazole delivered in dentures. Furthermore, custom splint is very thin in contrast to upper denture diminishing temperature build up. During the night the denture should be, after thorough brushing, kept in potent antimicrobial solution, suitable for biofilm removal. We have used 2% NaOCl which would be toxic if applied intraorally. These reasons underline the importance of overnight therapy. Although efficient on mucosal surfaces, miconazole itself is not able for thorough biofilm removal from denture porous surfaces, as confirmed by study of Lamfon et al (16).

Because of drug clearance by saliva, miconazole gel applied with existing denture could not reach whole denture bearing area, so candidal infection would always be present on some parts of the denture. When applied in the denture, miconazole gel would be extruded by jaw muscle contractions due to absence of the extended area as present in the custom splint, thus resulting in cessation of the therapeutic effect.

The investigated application of miconazole gel with custom tray serving as a drug carrier showed advantages: the drug is protected from salivary dilution and it is not displaced as a consequence of the movements of the jaw musculature; the patient can use the appliance without disruptions; this method might motivate patients in maintaining oral hygiene; less drug is needed, which justifies the price of custom splint.

njama oralne muskulature; bolesnik se danju može nesmetano koristiti stomatološkim nadomjestkom; ova metoda vjerojatno dodatno potiče bolesnika da održava higijenu; u odnosu prema klasičnoj metodi odlikuje se znatno manjom potrošnjom lijeka, čime se može opravdati i cijena individualne udlage.

Zaključci

Rezultati ovog istraživanja pokazali su visoku djelotvornost nove okluzijske tehnike za primjenu antimikotika u liječenju PP-a. Klinička slika bolesti jače je reducirana u skupini koja se koristila okluzijskom tehnikom individualne udlage. Dobivena je statistički znatna redukcija broja kolonija CA-a tijekom liječenja PP-a mikonazolom gelom primijenjenim u okluzijskom zavoju u odnosu prema redukciji klasično ordiniranim antimikotikom. Reducirani broj kolonija CA-a pridonosi smanjenju intenziteta upale, što je u ispitnoj skupini znatnije saniralo upalne promjene. Ispitivanom terapijskom metodom upalne promjene na sluznici nepca dulje su u neposrednom kontaktu s lijekom te se saniraju brže i potpunije. Metoda dodatno potiče bolesnika da slijedi upute o terapiji i higijeni nadomjestka i zato ju preporučujemo kao superioran pristup u liječenju navedenoga patološkog stanja, ako se upotrebljava lijek u obliku gela. Na temelju ovog istraživanja stvorena je osnova za uvođenje te metode u praksu.

Zahvala

Ova je studija obavljena i financirana u sklopu istraživačkog projekta "Oralne prekanceroze i paraneoplazije" (Br. 0065008) koji je odobrilo Ministarstvo znanosti i tehnologije Republike Hrvatske.

Conclusions

Results of this study show high efficacy of applying antifungals in custom trays in DS treatment. In the group of patients treated with occlusal technique, clinical findings of DS were significantly reduced. Significant reduction of *Candida* colony count with above mentioned technique was noted, compared to the conventionally applied antifungal therapy. *Candida* colony count reduction results in reduction of inflammation, as seen in the experimental group. By use of this method, in which palate is in longer direct contact with the medication, inflammatory changes heal faster and better. Additionally, this method probably motivates patients to adhere to recommended treatment and hygiene instructions, hence we recommend it as a superior device for DS treatment. Based on this study, its significance as a method of choice in clinical use has been proposed.

Acknowledgments

This study was performed and financed within the research project "Oral premalignant and paraneoplastic lesions" (No. 0065008) approved by the Ministry of Science and Technology of the Republic of Croatia.

Abstract

The aim of this study was to evaluate the effect of miconazole gel delivered on a custom thermoformed tray as an overnight drug holder appliance in denture stomatitis treatment, in comparison with classic application as recommended by manufacturer. The investigation included 44 upper denture wearers, diagnosed with denture stomatitis. The experimental group (n = 22) applied 2% miconazole gel in custom tray for overnight wear. The control group (n = 22) applied 2,5 ml of the same drug 4 times a day in their mouth. Intensity of inflammation and infection was evaluated. The clinical tests that were used were: inflammation intensity according to Newton, extent of palatal mucosal erythematous surface below denture, digital thermometry, and swabs for *Candida albicans* cultures. Oldness and hygiene status of dentures were recorded, as well as habit of overnight denture wearing. The investigation revealed that denture stomatitis healed faster and better in the experimental group compared to control group. Greater *Candida albicans* culture colony count reduction was observed in experimental group, which suggests more efficient elimination of *Candida albicans* from the mouth with novel method. This method motivates patients to adhere to treatment and appliance hygiene instructions. Custom splint as occlusive drug delivery showed to be more effective and more convenient for the patients than the same antimicrobial drug, classically delivered, which might be clinically relevant in treatment of denture stomatitis.

Received: July 17, 2006

Accepted: September 8, 2006

Address for correspondence

Danica Vidović Juras
University of Zagreb
School of Dental Medicine
Department of Oral Medicine
Gundulićeva 5, HR-10000 Zagreb, Croatia
djuras@sfzg.hr
Tel. +385-1-4802174
Fax +385-1-4830819

Key words

candidiasis; oral; stomatitis; denture; dentures; drug carriers; splint; miconazole

References

1. Dental School University of Milan. Denture related stomatitis [article on the Internet]. Milano: University of Milan, Dental School; 2005 [cited 2006 June 1]. Available from: <http://www.eaom.net/app/prvt/VediNotizia.d/Notizia-72>
2. Webb BC, Thomas CJ, Whittle T. A 2-year study of Candida-associated denture stomatitis treatment in aged care subjects. *Gerodontology*. 2005;22(3):168-76.
3. Scully C. *Oral and Maxillofacial Medicine - The Basis of Diagnosis and Treatment*. Edinburgh: Wright; 2004.
4. Newton AV. Denture sore mouth. *Br Dent J*. 1962;112:357-60.
5. Mravak-Stipetić M, Hemerich L, Jurčić I, Jerolimov V. Poticajni lokalni čimbenici u nastanku protetskog palatitisa. *Acta Stomatol Croat*. 2000;34(2):127-31.
6. Budtz-Jorgensen E. Oral mucosal lesions associated with the wearing of removable dentures. *J Oral Pathol*. 1981;10(2):65-80.
7. Abu-Elteen KH, Abu-Alteen RM. The prevalence of *Candida albicans* populations in the mouths of complete denture wearers. *New Microbiol*. 1998;21(1):41-8.
8. Barbeau J, Seguin J, Goulet JP, de Koninck L, Avon SL, Lalonde B, et al. Reassessing the presence of *Candida albicans* in denture-related stomatitis. *Oral Surg Oral Med Oral Pathol Oral Radiol Endod*. 2003;95(1):51-9.
9. Greenberg MS, Glick M, editors. *Burket's Oral Medicine: Diagnosis & Treatment*. New York: BC Decker Inc; 2003.
10. Tomerlin-Juzbašić R. *Vademecum*. Koprivnica: Belupo; 2003.
11. World Health Organization. *Application of the International Classification of Diseases to Dentistry and Stomatology ICD-DA*. Geneva: World Health Organization; 1994.
12. Jerolimov V. Totalna proteza kao uzrok patoloških promjena ležišta baze proteze [dissertation]. Zagreb: Stomatološki fakultet; 1983.
13. Olsen I. Occurrence and distribution of fungi. *Acta Odontol Scand* 1974;32(5):329-33.
14. Wray D, McCord JF. Labial veneers in the management of desquamative gingivitis. *Oral Surg Oral Med Oral Pathol*. 1987;64(1):41-2.
15. Brown RS, Flaitz CM, Hays GL, Trejo PM. The diagnosis and treatment of discoid lupus erythematosus with oral manifestations only: a case report. *Compendium*. 1994;15(6):724.
16. Lamfon H, Al-Karaawi Z, McCullough M, Porter SR, Pratten J. Composition of in vitro denture plaque biofilms and susceptibility to antifungals. *FEMS Microbiol Lett*. 2005;242(2):345-51.