

Technical Notes

A Conservative Method for Treating Severely Displaced Pediatric Mandibular Fractures: An Effective Alternative Technique

Sahand Samieirad¹, Saeedeh khajehahmadi², Elahe Tohidi³,
Meysam Pakravan⁴

¹Assistant Professor of Oral and Maxillofacial Surgery, Oral and Maxillofacial Diseases Research Center, Faculty of Dentistry, Mashhad University of Medical Sciences, Mashhad, Iran.

²Assistant Professor of Oral and Maxillofacial Pathology, Dental Research Center, Faculty of Dentistry, Mashhad University of Medical Sciences, Mashhad, Iran.

³Assistant Professor of Oral and Maxillofacial Radiology, Oral and Maxillofacial Diseases Research Center, Faculty of Dentistry, Mashhad University of Medical Sciences, Mashhad, Iran.

⁴Postgraduate Student of Oral and Maxillofacial Surgery, Faculty of Dentistry, Kerman University of Medical Sciences, Kerman, Iran

Received 1 February 2016 and Accepted 28 February 2016

Abstract

Pediatric mandibular fractures have been successfully managed in various ways. The use of a lingual splint is an option. This article presents a 4-year old boy who was treated by an alternative conservative method with a combination of an arch bar plus a lingual splint, circum-mandibular wiring and IMF for the reduction, stabilization and fixation of a severely displaced bilateral mandibular body fracture. This technique is a reliable, noninvasive procedure; it also limits the discomfort and morbidity associated with maxillomandibular fixation or open reduction and internal fixation in pediatric patients.

Key words: Lingual splint; Arch bar; Pediatric maxillomandibular fracture.

Introduction

Due to anatomical and environmental factors, maxillofacial fractures occur less frequently in children compared to adults and are responsible for approximately five percent of all maxillofacial fractures. About half of the pediatric maxillofacial fractures occur in the mandibular region and boys are usually more involved than girls (1-3).

Fractures in the mandibular region of pediatric patients most commonly involve condyles followed by symphysis, angle and body (4-6).

Although the clinical manifestations of these injuries are similar in adults and children, it is important to note that treatment protocols regarding maxillofacial fractures in pediatrics are challenging due to the physiologic, anatomic and developmental differences (7).

Considering the smaller jaw size of children, existence of active bone growth centers and follicles of unerupted permanent teeth, treatment of pediatric mandibular fracture can be a real challenge. Active bone growth centers play an important role in the future development and function of the mandible. Therefore, reduction and reconstruction of mandible after fracture is necessary both for immediate function and for normal ongoing craniofacial development (8).

In order to prevent the complications following open reduction and internal fixation techniques, especially

Samieirad S, khajehahmadi S, Tohidi E, Pakravan M. A Conservative Method for Treating Severely Displaced Pediatric Mandibular Fractures: An Effective Alternative Technique. J Dent Mater Tech 2016; 5(2): 53-8.

damage to the permanent tooth buds by screws and growth disturbances due to periosteal stripping in a growing jaw, most pediatric mandibular fractures such as condylar fractures or non-displaced mandibular fractures can be effectively treated by using conservative methods like arch bars, closed reductions and functional therapies as suggested in text books and literatures (9-14).

In pediatric mandibular fractures with significant displacement, intraoral open reduction and internal fixation techniques with resorbable plates can be useful. Although this technique has advantages such as direct vision, primary healing and shorter treatment period without any need for second operation for plate removal, there are some disadvantages for this method such as growth limitations due to periosteal stripping, higher cost of resorbable plates, probable damage to primary teeth and permanent tooth buds, pain and plate infection following the surgery (11, 15, 16). Therefore a conservative method for treating pediatric mandibular fractures with significant displacement is a valuable alternative.

This case report presents an alternative conservative method by combining the use of close reduction with arch bar plus a lingual splint and circum-mandibular wiring and IMF (intermaxillary fixation) for reduction and fixation of a bilateral body fracture with significant displacement in a 4-year old boy.

By presenting this case and review of articles we also show the value of simultaneous impression making of fractured mandible, model surgery and lingual splint preparation in operating room instead of plate and screw application for pediatric patients.

Technique and Patient

A 4-year old boy was referred to the Department of Maxillofacial Surgery, Bahonar Hospital in Kerman with head trauma due to motorcycle accident. The patient showed no sign of unconsciousness and was discharged from the Neurosurgery Service.

Based on the clinical examinations, there were signs of nose laceration, significant abrasions on the forehead and bilateral raccoon eyes in extra oral examination.

Intraoral examination showed sublingual ecchymosis in the floor of the mouth, a bilateral step deformity at the distal aspect of the mandibular right and left primary canine (H) with significant displacement in the anterior segment and tongue laceration. Malocclusion was also present. Panoramic radiography revealed bilateral mandibular body fractures with significant displacement (Fig.1).

The immediate intervention was suturing the nose and tongue lacerations and also airway management. After that, the clinical findings and diagnosis were explained to the patient's parents. As the parents could

not afford to buy resorbable plates and screws due to financial problems and also regarding the probability of airway emergency caused by mandibular collapse due to bilateral body fracture, we tried to apply closed reduction approach with some modifications for effective and immediate mandibular fracture treatment.

The patient was operated under general anesthesia and after nasotracheal intubation, fracture segments were manipulated and reduced using a bimanual maneuver and stabilized with bridal wire.

After that, impressions of the maxilla and mandible were taken using alginate impression material. Two teams were involved in the process; the first performed the model surgery and prepared the lingual splint and the second team simultaneously passed the wires in maxillary arch for arch bar placement in order to prevent waste of time.

Stone casts were prepared immediately; a simple lingual splint was constructed using self-cured acrylic material.

Holes were drilled in the splint at each interdental space to facilitate insertion of circumdental wires. The splint was polished and inserted on the lingual surface of the mandible.

Also arch bar was inserted on the buccal surface and secured using 25-gauge wires that passed through the splint holes to the corresponding interdental spaces, then around each tooth. Both the mandibular arch bar and lingual splint reduced and stabilized the mandibular segments effectively.

As we needed stronger stability of the lingual splint and mandibular arch bar without any dislodgment during the post-operative functional therapy with elastics, circum-mandibular wires passed bilaterally with an awl to retain and support the lingual splint and mandibular arch bar complex. Also in this case circum-mandibular wires pulled the mandibular segments vertically to align them with arch bars effectively (Fig.2).

Intermaxillary fixation was finally performed for the patient; at the end of the operation, occlusion was clinically perfect.

A postoperative panoramic radiograph was taken to confirm the satisfactory reduction of the bilateral mandibular body fracture (Fig .3).

The patient was observed every week, and on the second postoperative week, the IMF was removed and the elastics were applied instead.

Circum-mandibular wiring and lingual splint were removed one month later under local anesthesia. At that time, the occlusion of the patient was in an appropriate condition, and maximum mouth opening was normal without any deviation in function, which showed a successful clinical reduction. The patient had no complaints in follow up sessions after three and six

months and the left primary central incisor was exfoliated at the final follow up session (Fig.4).

The Panoramic and PA-mandibular view of the patient after 6 month verified the successful reduction and perfect osseous healing (Fig.5).

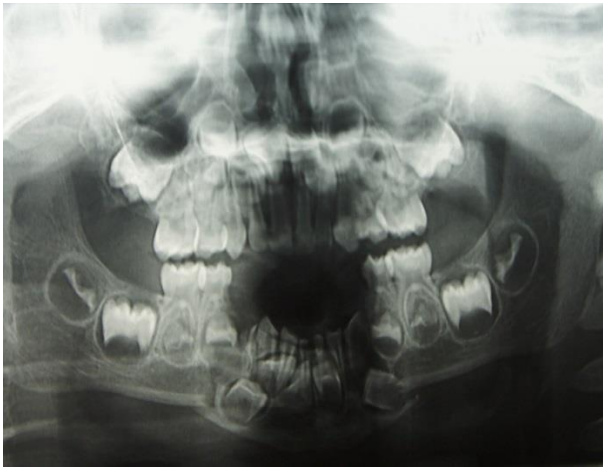

Figure 1. Panoramic view showed bilateral mandibular body fractures with significant displacement.

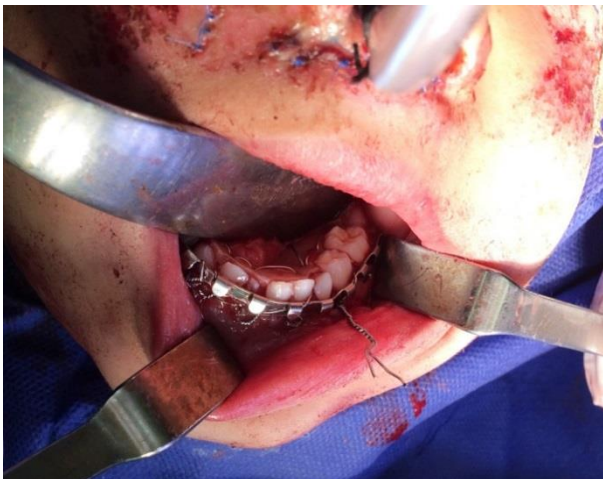

Figure 2. Circum-mandibular wiring to support the lingual splint and mandibular arch bar complex

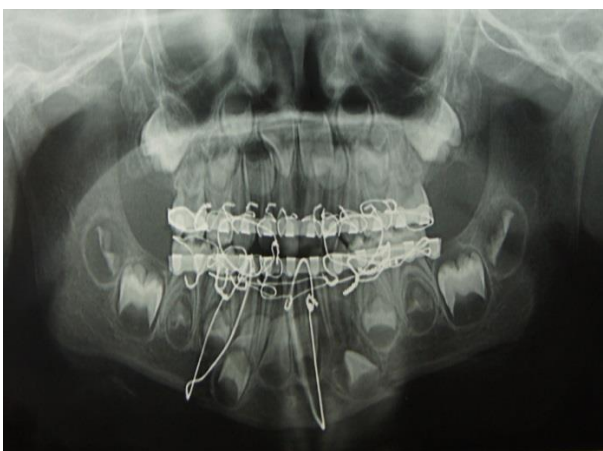


Figure 3. Postoperative panoramic radiography the day after operation, revealed satisfactory reduction of the bilateral mandibular body fractures.

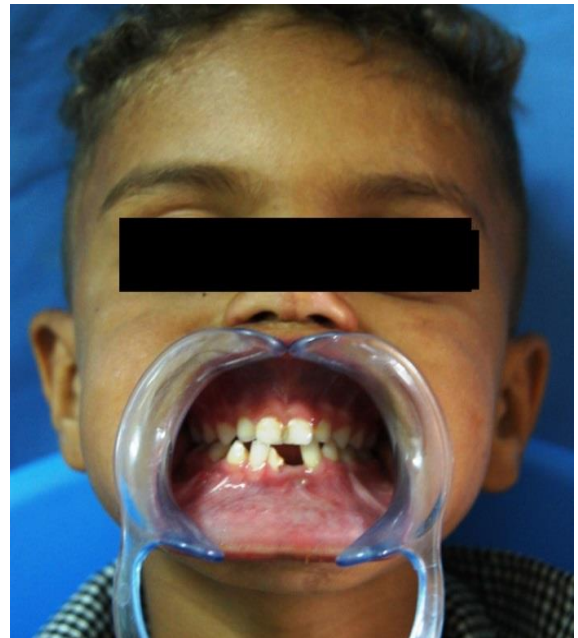

Figure 4. Patient postoperative clinical view after 6 months, with perfect occlusion

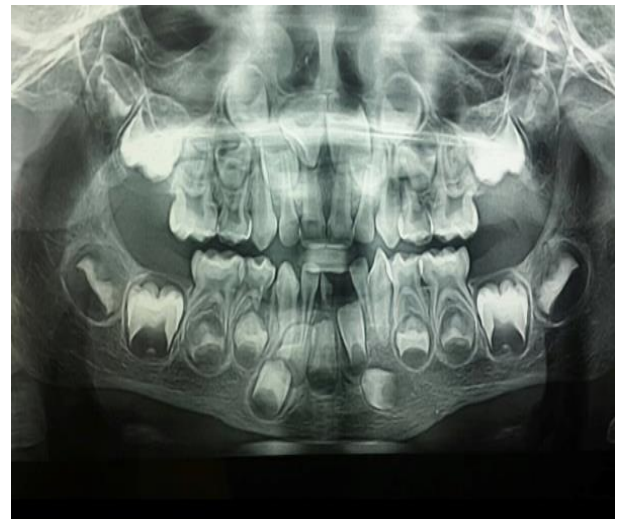

Figure 5. Patient postoperative clinical view after 6 months, Panoramic showed perfect osseous healing and reduction

Discussion

Pediatric mandibular fracture treatment plan differs from adults' because of the anatomic variations, growth rate and poor cooperation of children. Growth and healing rate in children is much faster than adults; therefore anatomic reduction and fixation should be conducted as soon as possible (17-21).

Mandibular growth and developing tooth germs are the main concerns for oral and maxillofacial surgeons in terms of treating pediatric mandibular fractures (22, 23).

Different techniques and methods have been explained and advocated for the treatment of mandibular fractures in children up to now with both advantages and disadvantages for each (6, 21).

For the minimal and non-displaced fractures without malocclusion, soft food regimen and observation and in some cases closed reduction may be effective (7, 14,23).

In case of significant displacement with segmental mobility and malocclusion, segmental reduction for keeping them in proper position is essential (24).

In pediatric fractures, open reduction and fixation (ORIF) with screws and plates have negative effects on both growth pattern and the unerupted teeth, even the surgery for fixation and then screw and plate removal, could be too hard for children to cope with (2, 8, 16).

The main disadvantages that limit the use of rigid fixations are the presence of developing dental follicles and soft bone in mandible and the interferences of ORIF with subsequent growth; possibility of allergic reaction and necessity of plate removal are other reported complications. Corrosion and leaching are sometimes the reason for plate removal. Therefore, ORIF procedure in children is indicated only in cases that closed procedures are impossible to be performed (23).

Absorbable plates and screws are thought to have less unwanted effects on growth for their resorbing nature, but the risk of injury to unerupted teeth still remains even when mono cortical screws are used(15, 16).

Recent studies on pediatric fractures emphasize on the lower risk of closed reduction of the body, angle and parasymphysis, against the higher risk of open reduction with miniplates. Also nonunion is significantly less likely to occur in closed reduction (13, 25).

Mandibular body periosteal destruction that occurs in an open treatment have uncertain effects on mandibular growth; therefore, if reduction is needed, a closed one would be more justifiable in children (23).

In pediatric mandibular fractures closed reduction with acrylic lingual splints have many advantages. Ellis *et al* found no occlusal complications in performing closed treatment with IMF in children (7, 11, 15, 26, 27).

Acrylic splints are easy to make, far more cost benefit and easily accepted by patients and they also can be used in mixed dentition. Besides, treatment can be done without open reduction and there is no need for GA in small fractures. The Stabilization of adjacent bone and tooth and minimum nonunion are among other benefits of this method. Lingual splints are more reliable than open reduction and relatively minimize the risk of morbidity and discomfort associated with open reduction. According to the above-mentioned issues and less traumatic nature of splints, some authors recommend the use of lingual splints in young patients with bone fractures (7, 10, 24).

Hofer described and introduced mandibular splint for the first time in 1939. In 1973 Hardin treated mandibular fractures using splints. In 1991 Irby reported

that lingual splints can be used without MMF (7).

Here are reviews of some of the successful managements of pediatric mandibular fractures with splints.

In 2007 Binahmed *et al.* reported treatment of a right mandibular body fracture in a 11 year old patient with lingual splints made after taking impression and model surgery of the maxilla and mandible in appropriate occlusion in laboratory before the main operation (7).

Srinivasan *et al.* Managed symphysis fracture in a 3-year-old child with a prefabricated acrylic splint and circum-mandibular wiring without arch bar in 2011(19).

Quader *et al* used the lateral compression splint as a guide for stabilization of mandibular arch in cases of dentoalveolar fracture of children in 2013(10).

Romeo *et al* reported treatment of a mandibular body fracture using lingual splints and circum-mandibular wiring under general anesthesia in 2013(24).

John *et al.* treated mandibular body fracture in a 4.5-year-old boy through closed reduction using open occlusal acrylic splint and circum-mandibular wiring in 2015 (23).

In most of the above cases, splints were fabricated before the surgical operation by first taking impression under sedation or local anesthesia and then performing model surgery and splint fabrication in laboratory; however, providing two operating teams in our case, resulted in impression taking, stone casting, model surgery and lingual splint preparation to be performed simultaneously with maxillary arch bar placement under GA in one session. This was different from what other previous researchers had done until then. The arch bar was placed in the buccal e and the acrylic splint in the lingual surface of fracture lines of mandible for the purpose of utilizing the advantage of reduction and stabilizing both buccal and lingual sides of mandible. The advantages of applying circum-mandibular wiring in our case were pulling the mandibular segments vertically to align the fractured segments with mandibular arch and to support lingual splint and mandibular arch bar complex to prevent dislodgment during functional therapy with elastics after MMF removal.

Conclusion

The simultaneous use of close reduction and placement of a lingual splint, buccal arch bar and circum-mandibular wiring, is a reliable, simple, safe and effective method for treating pediatric mandibular fractures that allows a more conservative and less invasive approach towards this type of mandibular fracture in children which, in turn, lessens the discomfort and morbidity associated with open reduction and internal fixation in pediatric patients.

References

1. Ferreira PC, Barbosa J, Braga JM, Rodrigues A, Silva AC, Amarante JM. Pediatric Facial Fractures: A Review of 2071 Fractures. *Annals of plastic surgery*. 2014.
2. Khatri A, Kalra N. A conservative approach to pediatric mandibular fracture management: outcome and advantages. *Indian journal of dental research : official publication of Indian Society for Dental Research*. 2011;22:873-6.
3. Maranoa R NPO. Mandibular fractures in children under 3 years: A rare case
4. report. *rev portestomatolmeddentcir maxilofac*. 2013;54:166-70.
5. Carroll MJ, Hill CM, Mason DA. Facial fractures in children. *British dental journal*. 1987;163:23-6.
6. Ferreira PC, Amarante JM, Silva AC, Pereira JM, Cardoso MA, Rodrigues JM. Etiology and patterns of pediatric mandibular fractures in Portugal: a retrospective study of 10 years. *The Journal of craniofacial surgery*. 2004;15:384-91.
7. Laster Z, Muska EA, Nagler R. Pediatric mandibular fractures: introduction of a novel therapeutic modality. *The Journal of trauma*. 2008;64:225-9.
8. Binahmed A, Sansalone C, Garbedian J, Sandor GK. The lingual splint: an often forgotten method for fixating pediatric mandibular fractures. *Journal (Canadian Dental Association)*. 2007;73:521-4.
9. Aizenbud D, Hazan-Molina H, Emodi O, Rachmiel A. The management of mandibular body fractures in young children. *Dental traumatology : official publication of International Association for Dental Traumatology*. 2009;25:565-70.
10. Posnick JC, Wells M, Pron GE. Pediatric facial fractures: evolving patterns of treatment. *Journal of oral and maxillofacial surgery : official journal of the American Association of Oral and Maxillofacial Surgeons*. 1993;51:836-44; discussion 44-5.
11. Shahriar Quader SM SM, Gofur a, Fatema S, Rahman MA. Lateral compression splint, a guide for stabilization of mandibular arch in case of dentoalveolar fracture of children. *Update Dent Coll J*. 2013;3:55-60.
12. Yaman F AS, Erol B. Malpractice in a child with mandibular fracture: a case report. *biotechnology and biotechnological Equipment*. 2014;20:185-7.
13. Christiano JG, Dorafshar AH, Tufaro AP, Manson PN. Closed reduction of laterally displaced fracture/dislocation of the mandibular condylar process in a child. *The Journal of craniofacial surgery*. 2011;22:1504-6.
14. Hu M, Wang Y, Zhang L, Yao J. [Comparative effectiveness of surgical and non-surgical treatment for pediatric mandibular condylar fractures]. *Zhongguo xiu fu chong jian wai ke za zhi = Zhongguo xiufu chongjian waikexue zazhi = Chinese journal of reparative and reconstructive surgery*. 2010;24:1440-3.
15. Aizenbud D, Emodi O, Rachmiel A. Nonsurgical orthodontic splinting of mandibular fracture in a young child: 10-year follow-up. *Journal of oral and maxillofacial surgery : official journal of the American Association of Oral and Maxillofacial Surgeons*. 2008;66:575-7.
16. Yaman F AS, Erol B. Malpractice in a child with mandibular fracture: A case report. *Biotechnology & Biotechnological Equipment*. 2006;20:185-7.
17. Eppley BL. Use of resorbable plates and screws in pediatric facial fractures. *Journal of oral and maxillofacial surgery : official journal of the American Association of Oral and Maxillofacial Surgeons*. 2005;63:385-91.
18. Namdev R, Jindal A, Bhargava S, Dutta S, Singhal P, Grewal P. Patterns of mandible fracture in children under 12 years in a district trauma center in India. *Dental traumatology : official publication of International Association for Dental Traumatology*. 2015.
19. Agarwal RM, Yeluri R, Singh C, Chaudhry K, Munshi AK. Management of pediatric mandibular fracture: a case series. *Compendium of continuing education in dentistry (Jamesburg, NJ : 1995)*. 2014;35:578-82.

20. Srinivasan I, Kumar MN, Kumaran PS, Bhandari A, Udhy J. Management of symphysis fracture in a 3-year-old child with prefabricated acrylic splint and circum-mandibular wiring. *Journal of dentistry for children* (Chicago, Ill). 2013;80:36-40.
21. Kambalimath HV, Agarwal SM, Kambalimath DH, Singh M, Jain N, Michael P. Maxillofacial Injuries in Children: A 10 year Retrospective Study. *Journal of maxillofacial and oral surgery*. 2013;12:140-4.
22. Singh G, Mohammad S, Pal US, Hariram, Malkunje LR, Singh N. Pediatric facial injuries: It's management. *National journal of maxillofacial surgery*. 2011;2:156-62.
23. Karim T, Khan AH, Ahmed SS. Trauma of facial skeleton in children: An indian perspective. *The Indian journal of surgery*. 2010;72:232-5.
24. John B, John RR, Stalin A, Elango I. Management of mandibular body fractures in pediatric patients: a case report with review of literature. *Contemporary clinical dentistry*. 2010;1:291-6.
25. Romeo GP, Davies S, Costello BJ. A method for direct fabrication of a lingual splint for management of pediatric mandibular fractures. *Plastic and reconstructive surgery Global open*. 2013;1:e51.
26. Imahara SD, Hopper RA, Wang J, Rivara FP, Klein MB. Patterns and outcomes of pediatric facial fractures in the United States: a survey of the National Trauma Data Bank. *Journal of the American College of Surgeons*. 2008;207:710-6.
27. Maliska MC, Lima Junior SM, Gil JN. Analysis of 185 maxillofacial fractures in the state of Santa Catarina, Brazil. *Brazilian oral research*. 2009;23:268-74.
28. Kim JH, Nam DH. Closed reduction of displaced or dislocated mandibular condyle fractures in children using threaded Kirschner wire and external rubber traction. *International journal of oral and maxillofacial surgery*. 2015.

Corresponding Author:

Meysam Pakravan
 Faculty of Dentistry, Kerman University
 Medical Sciences, Kerman, Iran
 Email: Mpakravanomfs@Gmail.Com
 Tel: +989131031604