

See discussions, stats, and author profiles for this publication at: <https://www.researchgate.net/publication/283241417>

Anti-vascular Endothelial Growth Factor for Choroidal Neovascularization Associated with Toxoplasmosis: A Case...

Article · January 2015

DOI: 10.4172/2155-9570.1000463

CITATIONS

0

READS

12

3 authors, including:



[Afsaneh Naderi Beni](#)

Shahrekord University of Medical Sciences

23 PUBLICATIONS 70 CITATIONS

SEE PROFILE

Anti-vascular Endothelial Growth Factor for Choroidal Neovascularization Associated with Toxoplasmosis: A Case Series

Farzan Kianersi¹, Zahra Naderi Beni², Afsaneh Naderi Beni^{2*}, Heshmatollah Ghanbari¹ and Mostafa Ahmadi²

¹Department of Ophthalmology, Isfahan University of Medical Science, Isfahan, Iran

²Shahrekord University of Medical Sciences, Shahrekord, Iran

*Corresponding author: Afsaneh Naderi Beni, Shahrekord University of Medical Sciences, Shahrekord, Iran, Tel: +98-381-2224400; E-mail: a_naderibeni@yahoo.com

Received date: June 17, 2015, Accepted date: August 21, 2015, Published date: August 31, 2015

Copyright: © 2015 Kianersi F, et al. This is an open-access article distributed under the terms of the Creative Commons Attribution License, which permits unrestricted use, distribution, and reproduction in any medium, provided the original author and source are credited.

Abstract

The purpose of the study was to evaluate the efficacy and safety of intravitreal anti-vascular endothelial growth factor (anti-VEGF) in treatment of choroidal neovascularization (CNV) secondary to toxoplasmic retinochoroiditis in five patients. After six months the CNV resolved as confirmed by fluorescein angiography and optical coherence tomography (OCT) in all patients. The visual acuity improved from mean 20/400 to 20/80 and Central Macular Thickness (CMT) decreased from 390 μ m to 253 μ m, which was maintained till the last follow-up visit.

Keywords: Anti-vascular endothelial growth factor; Choroidal neovascularization; Toxoplasmosis

Introduction

Treatment modalities for choroidal neovascularization (CNV) due to ocular toxoplasmosis include laser photocoagulation, surgery, corticosteroids, and verteporfin therapy. Intravitreal injection of Anti-vascular endothelial growth factor (anti-VEGF) in the treatment of CNV due to other conditions appears to be an effective and safe therapeutic option. We report 5 cases of successful treatment with anti-VEGF for symptomatic CNV due to ocular toxoplasmosis.

Methods

The Isfahan University Medical Center approved this study. Our study population consisted of 5 patients with CNV due to ocular toxoplasmosis (3 women, 2 men) with a mean (SD) age of 27.2 (7.1) years, all with documented notes suggested of clinical and serological diagnosis of toxoplasmosis retinichoroiditis and had been treated with oral sulfadiazine and pyrimethamine, along with systemic steroids at least 6 months before referral to our clinic.

All patients received a complete ophthalmologic evaluation. The anterior chamber and vitreous cavity were quiet in all patients. No signs suggestive of age-related macular degeneration were found. Fluorescein (FA) criteria included evidence of leakage caused by CNV (100% classic without an occult component) secondary to ocular toxoplasmosis and presence of intraretinal or subretinal fluid documented by optical coherence tomography (OCT). Intravitreal anti-VEGF treatment was recommended for all patients (bevacizumab, 1.25 mg for 4 eyes and ranibizumab 0.5 mg for one eye).

Results

CNV was inactive in all eyes after Intravitreal anti-VEGF treatments with an absence of leakage demonstrated by fluorescein angiography, complete disappearance of exudative signs and reduction of retinal thickness shown by OCT (Figure 1).

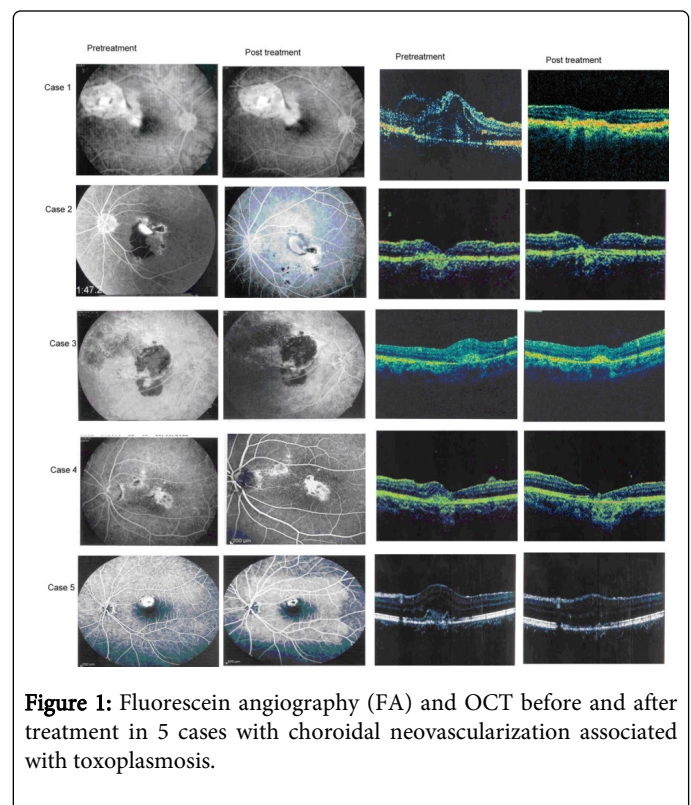


Figure 1: Fluorescein angiography (FA) and OCT before and after treatment in 5 cases with choroidal neovascularization associated with toxoplasmosis.

The mean follow-up was 14.4 months (range 6–24 months). Pre-injection visual acuity measured 20/250 or worse in all eyes. According to the last follow-up examination, visual acuity measured 20/30, 20/200, 20/200, 20/100 and 20/100 in eyes (Table 1). Mean Central macular thickness (CMT) at baseline was 399 μ m (380–410 μ m). At the last check, mean CMT reduction was 149 μ m (65–175 μ m), with a mean thickness of 253 μ m (range, 215–300 μ m) ($p=0.0002$).

No injection or drug-related complications, including endophthalmitis, cataract, retinal detachment, glaucoma, or uveitis, were observed.

| Patient | sex | Age | Initial VA (Before treatment) | Final VA | eye | Follow-up (mo) | Injection | MT Pretreatment | MT Posttreatment | Investigation(s) | Serology status |
|---------|-----|-----|-------------------------------|----------|-----|----------------|-------------|-----------------|------------------|------------------|------------------------------|
| 1 | F | 27 | 0.08 | 20/30 | OD | 24 m | Avastin | 395 | 300 | FA, OCT | IgG, positive; IgM, negative |
| 2 | F | 32 | 0.07 | 20/200 | OS | 6 m | Avastin | 410 | 250 | FA, OCT | IgG, positive; IgM, negative |
| 3 | M | 24 | 0.06 | 20/200 | OD | 12 m | Avastin | 380 | 215 | FA, OCT | IgG, positive; IgM, negative |
| 4 | M | 16 | 0.05 | 20/100 | OS | 15 m | Avastin | 400 | 250 | FA, OCT | IgG, positive; IgM, negative |
| 5 | F | 37 | 0.07 | 20/100 | OS | 15 m | ranibizumab | 410 | 235 | FA, OCT | IgG, positive; IgM, negative |

Table 1: Demographic and clinical characteristics of the patients in the study.

Discussion

CNV formation secondary to toxoplasmosis retinochoroiditis is a rare event with a poor visual prognosis. Treatment modalities for CNV secondary to toxoplasma retinochoroiditis include laser photocoagulation, submacular surgery, PDT, and anti-VEGF agents [1].

Because of the young age of our patients and occurrence of permanent scotoma or a blind spot in the central visual field with laser photocoagulation, this technique is not suitable for treatment. Surgery can have its own complications and does not prevent recurrences.

Photodynamic therapy appears to be effective. Although, an early recovery of visual acuity has been observed with PDT, multiple treatments have been required [2].

In our small series of patients at 6- to 25-month follow up, leakage diminished in all patients. A reduction of CMT was recorded in all subjects. This change of retinal morphology is likely to be the result of a combined antiexudative effect due to the decrease of vessel permeability and the antiproliferative effect due to the inhibition of further CNV growth following the VEGF blockage [1]. These anatomical improvements were associated with concomitant increases in VA. The mechanism of this outcome remains uncertain.

A previous case reports of CNV due to toxoplasmosis treated with IVB show an improvement of the patient's BCVA [3-5]. In our patients, VA increased to normal levels and was preserved until the end of follow-up. Unlike the repeated injections generally needed in

patients of CNV secondary to age-related macular degeneration [1] in our study only one injection was required to achieve a good visual outcome.

Our data seem to confirm the efficacy and safety of anti-VEGF therapy in eyes with CNV secondary to ocular toxoplasmosis, although we realize that the present study has some limitations, including the limited number of patients and the absence of a standard protocol for follow-up and treatment.

References

1. Kianersi F, Naderi Beni A, Naderi Beni Z, Ghanbari H (2015) Intravitreal bevacizumab for treatment of choroidal neovascularization secondary to toxoplasmic retinochoroiditis: a case series. *Semin Ophthalmol* 30: 181-187.
2. Oliveira LB, Reis PA (2004) Photodynamic therapy-treated choroidal neovascular membrane secondary to toxoplasmic retinochoroiditis. *Graefes Arch Clin Exp Ophthalmol* 242: 1028-1030.
3. Guthoff R, Goebel W (2009) Intravitreal bevacizumab for choroidal neovascularization in toxoplasmosis. *Acta Ophthalmol* 87: 688-690.
4. Ben Yahia S, Herbort CP, Jenzeri S, Hmidi K, Attia S, et al. (2008) Intravitreal bevacizumab (Avastin) as primary and rescue treatment for choroidal neovascularization secondary to ocular toxoplasmosis. *International Ophthalmol* 28: 311-316.
5. Lin CJ, Chen SN, Hwang JF, Hu PS (2011) Successful treatment of toxoplasmosis-associated choroidal neovascular lesions with bevacizumab and antiparasitic therapy. *Retin Cases Brief Rep* 5: 348-351.