

<http://www.ijapbr.com/>

International journal of Applied Pharmaceutical and Biological Research, 2017; 2(3):18-23



Research Article

ISSN : 2456-0189

MOLECULAR IMAGING USING BY DIFFUSION-WEIGHTED IMAGING OF BRAIN TUMOR THROUGH SIGNAL INTENSITY: PROGRESS IN MOLECULAR CANCER IMAGING

Sam Mirfendereski¹, Arash Shabani², Ayoob Rostamzadeh³, Daryoush Fatehi^{4*}

¹Department of Radiology, Faculty of Medicine, Shahrekord University of Medical Sciences, Shahrekord, Iran.

²Medical Imaging Physicist, Department of Radiology Technology, Faculty of Allied Medical Sciences, Shahid Beheshti University of Medical Sciences, Tehran, Iran

³Department of Anatomy and Neuroscience, Faculty of Medicine, Shahrekord University of Medical Sciences, Shahrekord, Iran.

⁴Department of Medical Physics, Faculty of Medicine, Shahrekord University of Medical Sciences, Shahrekord, Iran.

ABSTRACT

Introduction: Characterizing the variations of the brain tumors has the significant effect in the treatment process of affected patients. Brain metastatic tumors are usually diagnosed following by the neurological symptoms in patients. The purpose of this thesis is the role of diffusion-weighted-magnetic resonance imaging (DW-MRI) and apparent diffusion coefficient (ADC) values in the evaluation of different benign and malignant brain mass lesions before surgery with histopathological correlation.

Materials and Methods: In this study MR examination of 54 patients who with brain metastatic tumor referring to 7th-Tir Hospital were randomly selected and imaged with T2W Multi-echo sequences and GRE-EPI (DWI) in addition to taking the routine sequence of the brain.

Results: In analyzing the data for ADCmin values were measured within the tumors and mean values were evaluated regarding statistical differences between groups. The ADCmin values of low-grade gliomas ($1.09 \pm 0.20 \times 10^{-3} \text{ mm}^2/\text{s}$) were significantly higher ($p < .001$) than those of other tumors. Generally, ADC value of 0.5613 ± 0.02580 indicates brain metastatic tumors with lung origin, ADC value of 1.009 ± 0.03820 tumors with liver and breast origin, and ADC value of 1.556 ± 0.03500 tumors with colon and prostate origin.

Conclusion: According to our results, Diffusion parameters during treatment were evaluated for early non-invasive biomarkers. The ADC changes from mid- to post-treatment suggest such a possible early non-invasive biomarker.

Keywords: Molecular Imaging, Apparent diffusion coefficient, Diffusion weighted imaging, Brain tumor.

INTRODUCTION

The incidence of CNS metastases has been estimated approximately 3.8 per 10,000 people annually^{1, 2}. Metastasis is a process in which malignant cells are broken and separated from a primary tumor, entered into the bloodstream or the lymphatic system, and disseminated in different organs of the body¹. Tumor metastasis is also known as an important factor in many causes of death in neoplastic malignant lesions³. Cancer in the chest, lungs, and ovaries can cause metastatic lesions in the brain^{3,4}. Diffusion-weighted magnetic resonance imaging (DW-MRI) is a specialized MRI technique that depends on the random movement of water molecules within the intracellular and among the extracellular spaces. Regions with restricted mobility of water molecules yield a greater DW-MRI signal and appear bright. In apparent diffusion coefficient (ADC) maps, regions that contain high water mobility appear bright^{1, 5}. Thus, far diffusion-weighted imaging (DWI) has been used primarily for the detection of acute cerebral infarction⁵. However, there are other applications in which DWI facilitates diagnostic insight. The role of DWI in differentiating the cerebral abscess from necrotic tumors and arachnoid cysts from epidermoid tumors is well established^{6,7}. DWI also plays an important role in the diagnosis of herpes encephalitis and other types of encephalitis^{8,9}. However, the usefulness of DWI in the differential diagnosis of brain tumors needs further evaluation^{10,11}. Likewise, ability of DWI to grade gliomas is not well established yet^{10,12}. Further studies are needed to find out whether DWI would be useful in the differentiation of gliomas and metastasis from lymphomas and abscess^{13,14}. The current study would help to describe features of intracranial lesions on DWI. Moreover, the imaging features of these lesions on DWI would be compared with ADC and T2 FLAIR images to help differentiate among them. Numerous studies have underscored the importance of DWI in addition to the information obtained by conventional MRI sequences^{15,16}. This is important, as an intervention in stroke must be done within the first few hours. DWI helps characterize the disease load in multiple sclerosis better than conventional methods like T1 and FLAIR images^{17,18}. DWI helps differentiate toxoplasmosis from lymphomas, as the former shows significantly greater diffusion¹⁹. Enhancing lesions of the brain include abscesses and tumors. The center of abscesses show restricted diffusion and thus high signal intensity on DWI in comparison to tumors which reveal low signal intensity²⁰. Arachnoid cysts and epidermoid tumors have similar images on T1 and T2 weighted MRI images. DWI differentiates between these two, as arachnoid cysts have low signal intensity in comparison to the epidermoid tumors²¹. The DWI can provide an objective measure of hypoxic-ischemic injury to the brain in neonates, when one used it with the ADC maps²². Although several studies have described the ability of DWI to help differentiate various brain tumors and to help gliomas grading, further studies needed to define these features clearly²³. The aim of current study was to identify the origin of a BMT by the ADC values obtained from DW-MRI techniques and correlation with histologic analysis.

MATERIALS AND METHODS

The source of data for this study was 54 patients with BMT, referred to the radiotherapy and neurology departments of the 7th-Tir Hospital, Tehran, Iran, from October 2012 to June 2015. The inclusion criterion was having any type of intracranial lesions on the brain MRI including infective condition and tumor. The experiments were performed by MRI 1.5 Tesla (Siemens Avanto model, Germany). For brain MRI, the brain coil quadrature was used. Special holder pads used to prevent spam and random movements of the patient. Initial and the final analysis of the images were performed applying MRI- and SPIN software, respectively. Firstly, MRI test which includes routine sequences and the desired sequences of this study was performed on the patients with brain tumors. Then, the following techniques were taken: sagittal T1, axial T2 FLAIR, and diffusion weighted images with ADC maps. The ADC maps were generated based on diffusion-weighted echo planar sequences. Six high b-value images (1000 mm²/s) and one low b-value image (3 mm²/s) were acquired for each of the 23 axial slices. The following parameters were used: TR=10 s, TE=104 ms, diffusion encoding gradients=45 ms, 128×128 matrix size, FOV=24 cm, slice thickness of 24.5 mm with 1mm spacing, one signal average. Region of interest (ROI) were drawn from the solid enhancing regions of the tumor, peritumoral edema, and contralateral normal appearing white matter. Images were assessed by an experimented radiologist and a MRI scanning physicist. After that, the intensity of the obtained signals through SPIN software were analyzed with the obtained results from Pathology (tumor center (TC), tumor

contact tissue (TCT), and tumor type) previously specified by Pathologist. The results were available for a neurosurgeon to determine appropriate treatment for the patients. Pairwise post-hoc comparison of mean ADC values between groups were performed using Tukey's HSD and using one-way Analysis of Variance (ANOVA) test at the $p < 0.01$ level of significance. The statistical analysis was performed using GraphPadPrism 5.0 (GraphPad Software, Inc., San Diego, CA).

RESULTS

In our study, applying the capabilities of SPIN software and using two sequences sensitive to the change of content and water diffusion of a tissue, some features and variables were investigated among which relaxation time feature T2 and ADC are obtained from the analysis of T2 Multi-echo and DWI sequences, respectively. There was no significant difference among ADC values of the TTC in different tumor types, and they were almost in a numerical range. A sample of the images of a patient with BMT with lung origin is shown in figure 1, where several ROIs drawn on the image indicate the ADC-values. A significant relation was seen between the signal intensity of the TC and the TCTs ($P=0.013$). Furthermore, a significant relation was found between TC and TCT for the BMT with an origin of the lung ($P=0.0018$), liver- breast ($P=0.0063$), and or colon-prostate ($P=0.017$). However, there was a significant difference between signal intensity of the center of the tumor and the TCT. Moreover, there was a significant difference of the signal intensity at the TC from tumors with different origins. In this study we found that the signal intensity of 899.3 ± 33.87 indicates BMT with lung origin, the signal intensity of 621.3 ± 24.53 for tumors with liver and breast origin, and signal intensity of 416.1 ± 23.51 for tumors with colon and prostate origin (table 1). In analyzing the data for ADC parameter, there was a significant relationship between ADC value at the TC and TCT ($p < 0.05$) and also ADC values of BMT with lung, liver- breast and colon-prostate origins. Furthermore, there was no significant difference between ADC values TCT in different groups and they are almost within a numerical range. It is observed in the curve related to the ADC parameter; low grade types of the tumors had a higher ADC than those of the high grade. Also, metastatic tumor with lung origin had a lower ADC in TC than its tumors with low grade. This could be probably due to the high mass effect of this tumor and its malignity. The ADC value was higher than 1.3×10^{-3} mm²/s in tumors with colon origin (the cystic component showed the ADC values 2.4×10^{-3} to 3.1×10^{-3} mm²/s and the solid enhanced component showed the ADC values of 1.3×10^{-3} to 2.08×10^{-3} mm²/s); while in BMT with lung origin, the ADC values ranged between 0.55×10^{-3} and 0.9×10^{-3} mm²/s. The found ADC value of 0.5613 ± 0.0258 indicated BMT with lung origin, the value of 1.009 ± 0.0382 illustrated BMT with liver and breast origin, and the value of 1.556 ± 0.035 exhibited BMT with colon and prostate origin (table 1 and Figure 2).

Table 1: Results of the statistical test for the functional parameters

Tumor origin		
Lung	Signal intensity	899.3±33.87
	ADC values	0.5613±0.02580
Liver-Breast	Signal intensity	621.3±24.53
	ADC values	1.009±0.03820
Colon- Prostate	Signal intensity	416.1±23.51
	ADC values	1.556±0.03500

DISCUSSION

In our study, brain intra-axial tumors were investigated applying SPIN software. The results indicate that useful findings on the origin of a BMT can be achieved by MRI, using some optimized sequences sensitive to the record of molecular diffusion and employing advanced software analyses. We hope that the results of this study open a new door to answer the questions regarding origin of a BMT. In this study, applying capabilities of SPIN software and using two sequences sensitive to the change of content and water diffusion of a tissue,

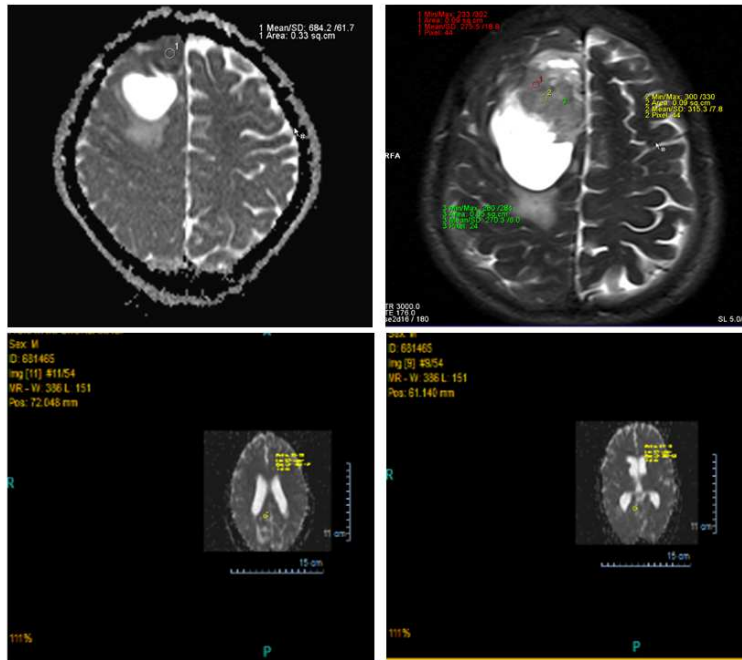


Figure 1. Image of patient with metastatic brain tumors originating from lung. As you can see, some ROIs are drawn on the image indicating the ADC-VALU in the original analysis.

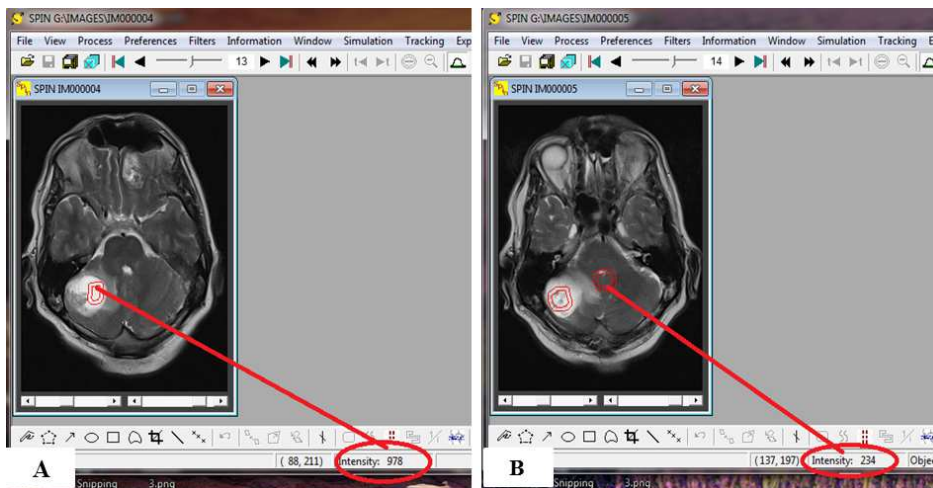


Figure 2. The signal intensity of TC (A) and the TCT (B) in the patient with metastatic brain tumor with lung origin

Some features and variables were investigated among which relaxation time feature T2 and ADC are respectively obtained from the analysis of T2 Multi-echo and DWI sequences²⁴. Generally, four major variables can impact DWI signal intensity: 1) time between application of the two gradients, 2) strength of the applied gradient pulse, 3) duration of the applied gradient pulse, and 4) the diffusion coefficient^{24,25}. It makes sense intuitively that signal intensity decreases as the amount of time between applications of the two gradient pulses increases, because water molecules are allowed more time to diffuse. Consequently, the phase refocusing pulse is less exact due to a larger displacement distribution of spins, which translates as signal attenuation. Signal intensity also varies proportionally with the strength and duration of the applied gradient pulse²⁵. These effects reflecting diffusion sensitization are summarized by the b-value²⁵. Finally, the signal intensity varies according to the intrinsic rate of diffusion in tissues represented mathematically by the diffusion constant. Simply stated, faster diffusion results in larger phase shift and greater signal loss. The study of Kono *et al.* suggests that tumor with low grade has ADC value more than tumors with high grade²⁶. Thus, this part of the findings from their study is similar to our results. In the present study the numerical values of ADC parameter as well as the origin of the tumor and type of the tumor are not implied. However, the obtained results indicate a particular connection between the origin of the tumor and type of the tumor; where, statistical analysis confirm it ^{27,28}.

Based on the findings of the present study we would like to suggest that tumor with low grades has ADC value more than those with high grade. According to the results of the present study, one can easily identify the origin of the BMT by analyzing the obtained ADC values. It could prevent additional MRI and CT scan examinations as well as biopsy from other parts of the body in order to determine the origin of the tumor. Thus, it would be useful for the patients and physicians; in terms of time, financial, and choosing the most appropriate treatment procedure.

Ethical Clearance

This project approved by Shahid Beheshti University of Medical Sciences Ethics Committee (Code no.IR.SBMU.REC.1393.18).

Source of funding

Supported by deputy of research of the Brain Medical Research Center in 7th-Tir Hospital; Tehran, Iran.

Conflict of Interest

No conflict of interest has been done.

REFERENCES

- 1) Mukherji SK, Chenevert TL, Castillo M. Diffusion-weighted magnetic resonance imaging. *Journal of neuro-ophthalmology*. **2002**; 22(2):118-22.
- 2) Fatehi D, Naleini F, Salehi MG, Gharib A, Farzizadeh M, Rostamzadeh A. Evaluation of multiple sclerosis patients through structural biomarkers of diffusion tensor magnetic imaging and correlation with clinical features. *Journal of Chemical and Pharmaceutical Sciences*. **2016**;9(2):830-7.
- 3) Stadnik TW, Demaerel P, Luypaert RR, Chaskis C, Van Rompaey KL, Michotte A, et al. Imaging Tutorial: Differential Diagnosis of Bright Lesions on Diffusion-weighted MR Images 1. *Radiographics*. **2003**;23(1):e7-e.
- 4) Fatehi D, Naleini F, Salehi MG, Gharib A, Rostamzadeh A. A rare case with basilar invagination anomaly in craniocervical junction: Role of CT & MRI. *Journal of Chemical and Pharmaceutical Sciences*. **2016**;9(2):838-43.
- 5) Masoumi H, Naleini F, Salehi MG, Gharib A, Rostamzadeh A. Idiopathic generalized epilepsies and efficiency of advanced magnetic resonance imaging techniques in present era; perspectives in future. *Journal of Chemical and Pharmaceutical Sciences*. **2016**;9(3):1381-5.
- 6) Patil S, Melkundi SS. EVALUATION OF INTRACRANIAL LESIONS BY DIFFUSION WEIGHTED IMAGING.
- 7) Rostamzadeh A, Naleini F, Gharib A, Fatehi D. Two rare cases with aortic dissection: Future prospective in imaging. *Journal of Chemical and Pharmaceutical Sciences*. **2016**;9(1):54-8.

- 8) Ledley RS, Ayers WR. Computerized Medical Imaging and Graphics. **1995**.
- 9) Salehi MG, Masoumi H, Tanha RR, Naleini F, Gharib A, Rostamzadeh A. Role of diffusion tensor imaging as an imaging biomarker and theranostic tool in structural imaging of traumatic brain injury. *Journal of Chemical and Pharmaceutical Sciences*. **2016**;9(2):854-64.
- 10) Mascalchi M, Filippi M, Floris R, Fonda C, Gasparotti R, Villari N. Diffusion-weighted MR of the brain: methodology and clinical application. *La Radiologia Medica*. **2005**;109(3):155-97.
- 11) Salehi MG, Rostamzadeh A, Gharib A, Masoumi H. Role of magnetic nanoparticles in targeted drug delivery for central nervous system. *Journal of Chemical and Pharmaceutical Sciences*. **2016**;9(3):1419-23.
- 12) Taheri A, Masoumi H, Rostamzadeh A, Gharib A, Fatehi D. Changing the paradigm of multiple sclerosis characteristics: Fact or fiction; Role of non-conventional MRI techniques in screening, prognosis, diagnosis, and following. *Journal of Chemical and Pharmaceutical Sciences*. **2016**;9(3):1413-8.
- 13) Tadeusz W, Cristo C, Alex M, Wael M, Katrijn V, Robert L. Diffusion weighted MR images of intracerebral masses-comparison with conventional MR. *AJNR*. **2001**;22:969-76.
- 14) Taheri A, Rostamzadeh A, Gharib A, Fatehi D. Efficacy of multidetector-row computed tomography as a practical tool in comparison to invasive procedures for visualization of the biliary obstruction. *Acta Informatica Medica*. **2016**;24(4):257-60.
- 15) Warach S, Gaa J, Siewert B, Wielopolski P, Edelman RR. Acute human stroke studied by whole brain echo planar diffusion-weighted magnetic resonance imaging. *Annals of neurology*. **1995**;37(2):231-41.
- 16) Taheri A, Rostamzadeh A, Gharib A, Fatehi D. Radioprotective effects of Silymarin, a natural medical herb, in modulation and prevention of radiation induced damages. *Der Pharmacia Lettre*. **2016**;8(9):146-50.
- 17) Camacho DL, Smith JK, Castillo M. Differentiation of toxoplasmosis and lymphoma in AIDS patients by using apparent diffusion coefficients. *American journal of neuroradiology*. **2003**;24(4):633-7.
- 18) Tanha RR, Ghaderi O, Gharib A, Anzab MA, Ahmadi R, Mahmoodi A, et al. Increasing prevalence of multiple sclerosis: Biomarkers theranostic strategy from bench to bedside- a review. *Journal of Chemical and Pharmaceutical Sciences*. **2016**;9(2):753-64.
- 19) Atlas SW. *Magnetic resonance imaging of the brain and spine: Lippincott Williams & Wilkins*; **2009**.
- 20) Brem S, Panatier JG. An era of rapid advancement: diagnosis and treatment of metastatic brain cancer. *Neurosurgery*. **2005**;57(5):S4-5.
- 21) Li J, Yen C, Liaw D, Podsypanina K, Bose S, Wang SI, et al. PTEN, a putative protein tyrosine phosphatase gene mutated in human brain, breast, and prostate cancer. *science*. **1997**;275(5308):1943-7.
- 22) Di Chiro G, Oldfield E, Wright DC, De Michele D, Katz DA, Patronas NJ, et al. Cerebral necrosis after radiotherapy and/or intraarterial chemotherapy for brain tumors: PET and neuropathologic studies. *American Journal of Roentgenology*. **1988**;150(1):189-97.
- 23) Provenzale JM, Mukundan S, Barboriak DP. Diffusion-weighted and Perfusion MR Imaging for Brain Tumor Characterization and Assessment of Treatment Response 1. *Radiology*. **2006**;239(3):632-49.
- 24) Nemeth A, Henson J, Mullins M, Gonzalez R, Schaefer P. Improved detection of skull metastasis with diffusion-weighted MR imaging. *American journal of neuroradiology*. **2007**;28(6):1088-92.
- 25) Tung GA, Evangelista P, Rogg JM, Duncan III JA. Diffusion-weighted MR imaging of rim-enhancing brain masses: is markedly decreased water diffusion specific for brain abscess? *American Journal of Roentgenology*. **2001**;177(3):709-12.
- 26) Kono K, Inoue Y, Nakayama K, Shakudo M, Morino M, Ohata K, et al. The role of diffusion-weighted imaging in patients with brain tumors. *American Journal of Neuroradiology*. **2001**;22(6):1081-8.
- 27) Guo AC, Cummings TJ, Dash RC, Provenzale JM. Lymphomas and High-Grade Astrocytomas: Comparison of Water Diffusibility and Histologic Characteristics 1. *Radiology*. **2002**;224(1):177-83.
- 28) Cruz LCH, Sorensen AG. Diffusion tensor magnetic resonance imaging of brain tumors. *Magnetic resonance imaging clinics of North America*. **2006**;14(2):183-202.