

Comparison of protective effects of omega3 fish oil and aqueous extract of *Glycyrrhiza glabra* root on biochemical factors and liver tissue changes induced by thioacetamide in male rats

Davood Moghadamnia^{1,2}, Mokhtar Mokhtari^{3*}, Saeed Khatamsaz³

¹Biology Dept., Fars Science and Research Branch, Islamic Azad University, Fars, I.R. Iran; ²Biology Dept., Shiraz Branch, Islamic Azad University, Shiraz, I.R. Iran; ³Biology Dept., Kazerun Branch, Islamic Azad University, Kazerun, I.R. Iran.

Received: 9/Feb/2016 Accepted: 25/Apr/2016

ABSTRACT

Background and aims: Thioacetamide can lead to liver cirrhosis and hepatocarcinoma. This study was aimed to evaluate the ability of omega3 fish oil and *Glycyrrhiza glabra* aqueous extract to attenuate biochemical factors and liver tissue changes induced by thioacetamide.

Methods: In this experimental study, 63 wistar male rats were divided into 9 groups. Control group, Sham group received 0.4ml olive oil orally per day for 3 months. Thioacetamide group received 150 mg/kg of TAA intraperitoneally in a single dose for 3 months. Experimental groups 1, 2, 3, 4, 5 and 6 received 100, 200, 300 mg/kg of omega3 fish oil and aqueous extract of *Glycyrrhiza glabra* root orally per day for 3 months and 150 mg/kg of TAA intraperitoneally in a single dose for 3 months. The provided blood samples were tested for serum levels of bilirubin, albumin, and total protein. The pathological examination of hepatic tissue samples was done after hematoxylin and eosin staining.

Results: Treatment with 100 mg/kg of omega3 fish oil (0.06 ± 0.013) significant reduced the serum level of bilirubin comparing with thioacetamide group (0.38 ± 0.015). Treatment with the aqueous extract of *Glycyrrhiza glabra* root at all doses (0.37 ± 0.034) (0.34 ± 0.027) (0.15 ± 0.028) showed no significant difference in the serum level of bilirubin comparing with thioacetamide group (0.38 ± 0.015). Treatment with the omega3 fish oil (4.40 ± 0.02) (4.32 ± 0.10) (4.34 ± 0.10) and aqueous extract of *Glycyrrhiza glabra* root at all doses (4.33 ± 0.06) (4.31 ± 0.5) (4.20 ± 0.07) significant reduced the serum level of albumin comparing with thioacetamide group (4.70 ± 0.00). The mean levels of total protein showed no significant difference in the experimental groups (8.77 ± 0.31) (8.53 ± 0.20) (8.63 ± 0.24) (8.58 ± 0.05) (8.57 ± 0.10) (7.92 ± 0.21) comparing with thioacetamide group (8.56 ± 0.08). In all experimental groups, the hepatic tissue changes induced by thioacetamide improved which were dose dependent ($P < 0.05$).

Conclusion: The study suggests that biochemical factors and liver tissue changes induced by thioacetamide in male rats can be ameliorated by oral administration of aqueous extract of *Glycyrrhiza glabra* root and omega3 fish oil.

Keywords: *Glycyrrhiza glabra* root, Omega3 fish oil, Thioacetamide, Biochemical factors, Rat.

*Corresponding author: Mokhtar Mokhtari, Biology Dept., Kazerun Branch, Islamic Azad University, Kazerun, I.R. Iran, Tel: 00989171811963, E-mail: m.mokhtari246@yahoo.com

INTRODUCTION

Liver plays a crucial role in the metabolic elimination of most drugs and foreign compounds. Thus, it makes an important target for toxicities. Liver diseases such as hepatocellular carcinoma, viral and alcoholic hepatitis and non-alcoholic steatosis are the most common liver-associated and prevalent diseases in the world which are closely associated with jaundice.¹ TAA is known to be hepatotoxic and carcinogenic compound in animals and most likely in humans.

The cirrhosis model induced by TAA in rats produces histopathological changes that are similar to those found in humans and animals.² The toxicity of TAA results from its bioactivity by mixed-function oxidase system, particularly CYP2E1 and FAD monooxygenase.²⁻⁴ Metabolic activation of TAA then leads to the formation of reactive metabolites that are represented by radicals derived from thioacetamide-s-oxide and by reactive oxygen species (ROS) generated as intermediates.⁵

The omega3 fatty acids has beneficial effects in preventing atherosclerotic diseases and insulin resistances in adipose tissue.⁶ Omega3 fatty acid treatment may have beneficial effects in regulating hepatic lipid metabolism, adipose tissue function. Omega3 fatty acids may be useful in the treatment of nonalcoholic steatohepatitis.⁷ Eicosapentaenoic acid improves glycemic control in elderly bedridden patients with type2 diabetes.⁸

Omega3 improves cardiovascular disorders⁹, psychiatric disease^{10,11}, inflammatory bowel disease¹² and cystic fibrosis.¹³⁻¹⁵ Omega 3 fatty acids were shown to attenuate growth and induce apoptosis in a variety of human cancer lines derived from colonic, pancreatic prostate, and breast cancer.¹⁶ According to Li et al. consumption of diet containing fish oil can reduce systemic

inflammation and liver damage induced by infection through up-regulation of the peroxisome proliferator-activated receptor gamma-mediated pathway (PPAR) in septic mice.¹⁷ Also, Jangale et al. determined that fish oil and flax seed oil can alleviate inflammation in diabetic mice induced by streptozotocin-nicotinamide.¹⁸ Kim et al. showed that diet containing Omega-3 can attenuate hepatic damage caused by ischemia and tissue reperfusion via reduction of NF-Kb activity.¹⁹

Glycyrrhiza glabra is one of the most widely used herbs from the ancient medical history of Ayurveda, both as a medicine herb. It is a sweet, moist, soothing herb that detoxifies and protects the liver and is also a powerful anti-inflammatory, and is used in conditions as varied, arthritis and mouth ulcers. Root of *Glycyrrhiza glabra* contained glycyrrhizin, flavonoid rich fraction include liquirtin, isoliquirtigenin²⁰ and other constituents such as coumarins, pectin, tanins, phytosterols, choline and various other substance.²¹

Many biological activities such as antitumor promote activity, and antimicrobial effects.^{22,23} The combination of *Silybum marianum* (silymarin) and *Glycyrrhiza glabra* (Glycyrrhizin) in different doses has protective effect against oxidative stress in the liver.²⁴ The saponins from the root of *Glycyrrhiza inflata* have protective impacts on hepatic cells of rats intoxicated by D-galactosamine through reducing the levels of ALT and AST liver enzymes.²⁵

Regarding the anti-inflammatory and antioxidant effects of omega3 fish oil and *Glycyrrhiza glabra* root and its long use for the treatment of liver disorders, the protective effect of omega3 fish oil and aqueous extract of *Glycyrrhiza glabra* root on biochemical factors and liver tissue changes induced by thioacetamide in male rats.

METHODS

In this experimental study, 63 adult male wistar rats in a weight range of 200 ± 10 g and the age range of 2.5 ± 3 months were used. Animals were randomly divided in 9 groups of seven, and kept under standard conditions of 20-22 °C and light cycle of 12 h and 12 h dark. They had easy access to food and water, and all ethical considerations and animal rights were ensured.

Animals were divided into 9 equal groups and were treated as follow: the control group which was left untreated and subjected to no stress; the sham which daily received 0.4ml/kg olive oil as a solvent fish oil omega3; the thioacetamide group which received a single dose of 150 mg/kg thioacetamide; the experimental groups 1, 2 and 3 received a daily dose of 100, 200 and 300 mg/kg fish oil omega-3, respectively followed by a single dose of 150 mg/kg thioacetamide. Experimental group 4: animals in this group received 100 mg/kg of *Glycyrrhiza glabra* root aqueous extract orally for 3 months and a single intraperitoneal injection of thioacetamide at a dose of 150 mg/kg at the end of 3 months. The experimental group 5: animals in this group received 200 mg/kg of *Glycyrrhiza glabra* root aqueous extract daily orally for 3 months and a single intraperitoneal injection of thioacetamide at a dose of 150 mg/kg at the end of 3 months. The experimental group 6: animals in this group daily received 300 mg/kg of *Glycyrrhiza glabra* root aqueous extract orally for 3 months and a single intraperitoneal injection of thioacetamide at a dose of 150 mg/kg at the end of the 3 months period. Fish oil omega3 and *Glycyrrhiza glabra* root aqueous extract was administered orally for 3 months, and thioacetamide was injected interperitonally at the end of treating period.

48 hours after the last injection, animals were anesthetized with ether, and blood samples were taken from the heart. These

samples were kept under laboratory conditions for 20 minutes; then, centrifuged at 5000 RPM for 15 minutes.^{26,27}

As the effects of toxic thioacetamide usually become apparent about 2 days after injection, 48 h after the last injection all animals were anesthetized with ether (Merck, Germany), and their blood samples were directly taken from the heart.

The obtained blood samples were kept under laboratory conditions for 20min and then were centrifuged at 5000 rounds per minute for 15 min (Hettich, Germany).^{28,29}

To measure bilirubin, azo DVD reagents (sulfanilic acid sodium nitrite) were used; they react with bilirubin, producing azo, which is red in alkaline PH. After production, direct bilirubin has a pink color, but after addition of accelerating solution, total bilirubin turns green in alkaline PH. To measure the total protein biuret reaction end point (by Diasys, Germany) was used in which in an alkaline environment proteins reacted with copper ions and tartrate and formed azure color whose density was proportional to the amount of total protein in the sample. For measuring albumin, bromocresol green method (Diasys, Germany) was used in which, albumin with bromocresol produced a colored complex whose color intensity was proportional to the amount of albumin in the sample.³⁰

After removal, livers were fixed separately in 10% neutral formalin buffer. Following histological tissue preparation and producing specimen blocks, 4-5 micron thick sections were prepared. Using hematoxylin-eosin method was stained and studied by light microscope.

SPSS software (version 18, Chicago, IL, USA) was used for data analysis. The ANOVA test was performed on the data. Tukey test was used to evaluate the significant differences of the data (Tukey-HSD) and all

the differences were considered as significant at $P \leq 0.05$. The plasma concentration of total protein, albumin and bilirubin were presented as mean \pm SE.³¹

RESULTS

In addition, the serum concentration mean of bilirubin rose significantly in the thioacetamide group (0.38 ± 0.015) compared to control and sham groups (0.12 ± 0.015) (0.23 ± 0.029) while it showed no significant change in all experimental groups receiving omega3 fish oil (0.06 ± 0.013) (0.010 ± 0.017) (0.14 ± 0.026) compared to control and sham groups (0.12 ± 0.015) (0.23 ± 0.029), but a significant decline was seen between all three experimental groups receiving omega3 fish oil (0.06 ± 0.013) (0.010 ± 0.017) (0.14 ± 0.026),

and the group receiving thioacetamide (0.38 ± 0.015) ($P \leq 0.05$). (Figure 1).

The average concentration of bilirubin in all experimental groups which received aqueous extract of *Glycyrrhiza glabra* root and thioacetamide (0.37 ± 0.034) (0.34 ± 0.027) (0.15 ± 0.028) showed a significant decrease when it was compared to that in the group which received thioacetamide (0.38 ± 0.015), and it was not significant yet. The average concentration of serum bilirubin in the experimental groups receiving 200, 300 mg/kg of aqueous extract of *Glycyrrhiza glabra* root and thioacetamide) (0.34 ± 0.027) (0.15 ± 0.028) had a significant increase when it was compared to the control and sham groups (0.12 ± 0.015) (0.23 ± 0.029) ($P \leq 0.05$). (Figure 1).

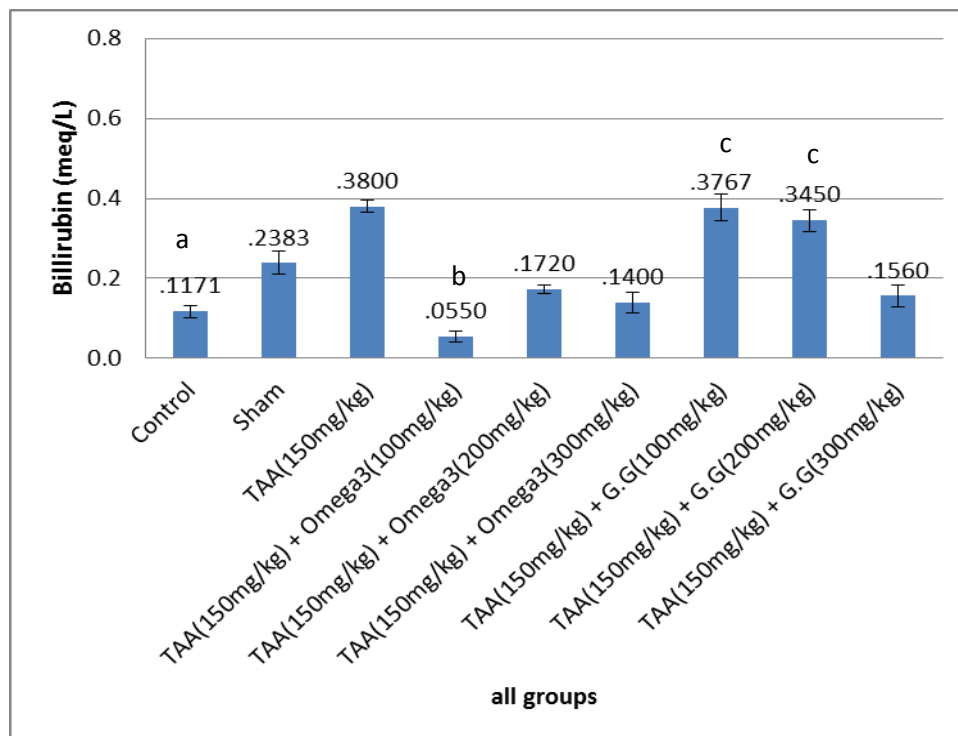


Figure 1: Effects of different doses of omega3 fish oil and aqueous extract of *Glycyrrhiza glabra* root on serum levels of bilirubin

Letter a represents significant differences between group receiving thioacetamide alone, and control and sham groups at the level of $P < 0.05$. Letter b represents significant differences between thioacetamide group, and various experimental groups at the level of $P < 0.05$; and letter c represents significant differences among different experimental groups, and control and sham groups at the level of $P < 0.05$.

Also, in regard to concentrations of total proteins, no significant change was observed between group receiving thioacetamide, and control and sham groups (8.56±0.08) (8.88±0.5) (8.56±0.08) as well as between various experimental groups receiving omega3 fish oil (8.77±0.31) (8.53±0.20) (8.63±0.24), and control, sham and thioacetamide groups (8.88±0.5) (8.56±0.08) (8.56±0.08) (P≤0.05) (Figure 2).

The average concentration of total protein in all experimental groups which

received *Glycyrrhiza glabra* root aqueous extract and thioacetamide (8.58±0.05) (8.57±0.10) (7.92±0.21) showed no significant change compared to the group receiving thioacetamide (8.56±0.08). The mean total protein concentration in the experimental group receiving 300mg/kg of the aqueous extract of *Glycyrrhiza glabra* root and thioacetamide (7.92±0.21) decreased significantly when compared to the control and sham groups (8.88±0.5) (8.56±0.08) (P≤0.05) (Figure 2).

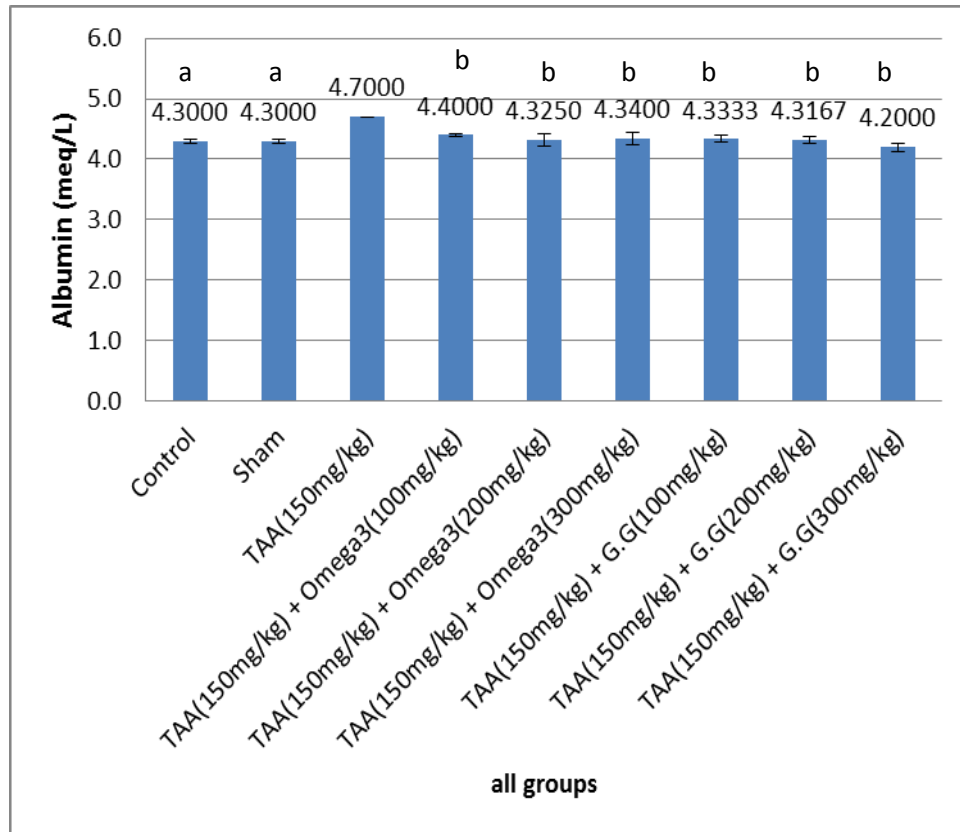


Figure 2: Effects of different doses of omega3 fish oil and aqueous extract of *Glycyrrhiza glabra* root on serum levels of albumin

Letter a represents significant differences between group receiving thioacetamide alone, and control and sham groups at the level of P<0.05; letter b represents significant differences between thioacetamide group, and various experimental groups at the level of P<0.05.

The mean levels of albumen increased significantly in group receiving

thioacetamide (4.70±0.00) compared with control and sham groups (4.30±0.04)

(4.30 ± 0.03), whereas it showed no significant change in all experimental groups receiving omega3 fish oil (4.40 ± 0.02) (4.32 ± 0.10) (4.34 ± 0.10) relative to control and sham groups (4.30 ± 0.04) (4.30 ± 0.03), but a significant decline was seen between all three experimental groups receiving omega3 fish oil (4.40 ± 0.02) (4.32 ± 0.10) (4.34 ± 0.10), and the group

receiving thioacetamide (4.70 ± 0.00) ($P \leq 0.05$) (Figure 3).

The average concentration of albumin in all experimental groups which received aqueous extract of *Glycyrrhiza glabra* root and thioacetamide (4.33 ± 0.06) (4.31 ± 0.5) (4.20 ± 0.07) showed a significant decrease when it was compared to the thioacetamide group (4.70 ± 0.00) ($P \leq 0.05$) (Figure 3).

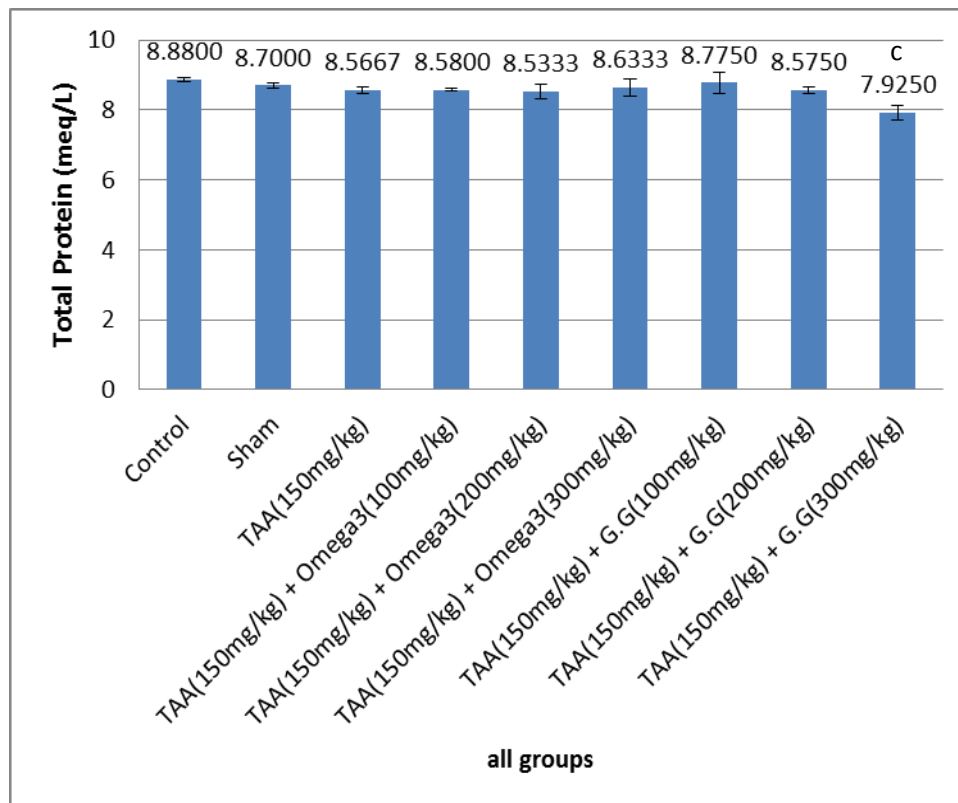


Figure 3: Effects of different doses of omega3 fish oil and aqueous extract of *Glycyrrhiza glabra* root on serum levels of total protein

Letter a Represents significant differences between group receiving thioacetamide alone, and control and sham groups at the level of $P < 0.05$.

Histological studies of hepatic samples showed normal hepatocytes with protected cytoplasm and marked nuclei in control and sham groups (Figures 4-A and 4-B). In contrast, tissue sections in thioacetamide group in comparison with the control and sham groups indicated hepatocyte necrosis, increase in mitosis, cell death, abnormal mitotic inflammation in portal space and large

nuclei (Figure 4-C). Although tissue samples of the experimental groups 1 and 2 (receiving 100 and 200 mg/kg omega3 fish oil and thioacetamide) showed no hepatocyte mitosis, apoptosis and necrosis, they had large nuclei (Figures 4-D and 4-E), whereas the experimental group 3 (recipient of 300 mg/kg omega3 fish oil and thioacetamide) showed normal liver tissue (Figure 4-F).

In the experimental groups 4 and 5 which received 100 and 200 mg/kg of aqueous extract of *Glycyrrhiza glabra* root and thioacetamide cell, necrosis had stopped but the nucleus was still large with no

apoptosis (Figure 4-G and 4-H). The experimental group 6 receiving 300 mg/kg of aqueous extract of *Glycyrrhiza glabra* root and thioacetamide revealed a normal liver tissue. (Figure 4-I).

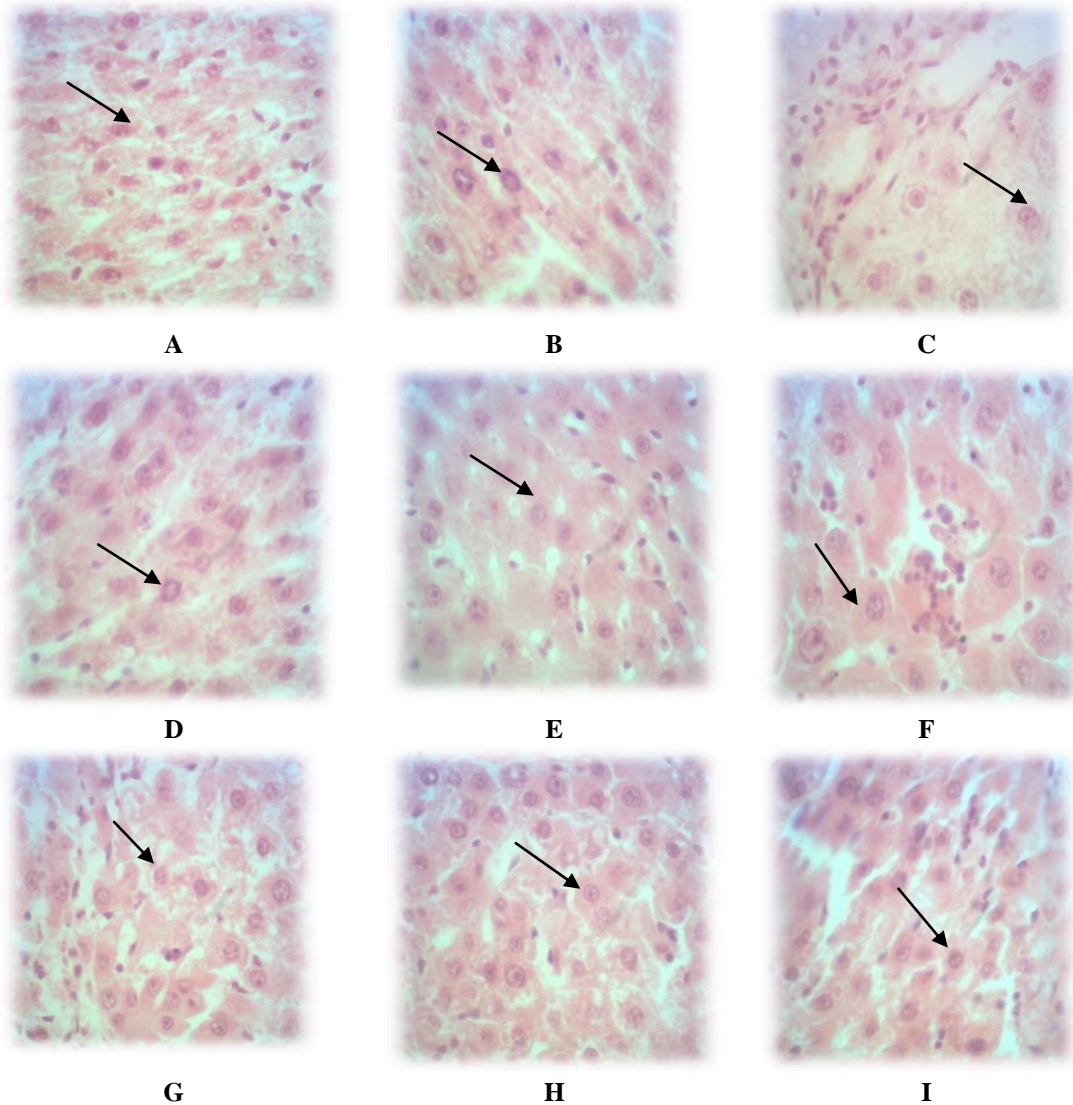


Figure 4: Photomicrograph of liver tissue in different groups (Magnification X40)

A: Control group; B: Sham group; C: Thioacetamide group (receiving thioacetamide); D: Experimental group 1 (receiving 100 mg/kg omega3 fish oil and thioacetamide); E: Experimental group 2 (receiving 200 mg/kg omega3 fish oil and thioacetamide); F: Experimental group 3 (receiving 300 mg/kg omega3 fish oil and thioacetamide); G: Experimental group 4 (receiving 100 mg/kg of aqueous extract of *Glycyrrhiza glabra* root and thioacetamide); H: Experimental group 5 (receiving 200 mg/kg of aqueous extract of *Glycyrrhiza glabra* root and thioacetamide); I: Experimental group 6 (receiving 300 mg/kg aqueous extract of *Glycyrrhiza glabra* root and thioacetamide).

Figure A shows normal hepatocytes with protected cytoplasm, and marked nuclei. Figure B shows normal hepatocytes with protected cytoplasm and marked nuclei. In figure C it shows hepatocyte necrosis, increase in mitosis, cell death, abnormal mitotic inflammation in portal space and large nuclei. Figure D shows no hepatocyte mitosis, apoptosis and necrosis, but still have large nuclei, and figure E shows no hepatocyte mitosis, apoptosis and necrosis, but still have large nuclei. Figure F also shows regeneration of liver tissue to natural state, hepatocytes have normal size nuclei, and mitosis and apoptosis are not seen. Figure G shows no hepatocyte mitosis, apoptosis and necrosis, but still have large nuclei. Figure H shows no hepatocyte mitosis, apoptosis and necrosis, but still have large nuclei. Figure I showing regeneration of liver tissue to natural state, hepatocytes have normal size nuclei, and mitosis and apoptosis are not seen.

DISCUSSION

Thioacetamide (TAA) was reported as a hepatotoxic agent by fitzhugh and nelson. A single dose of this toxin in animals can produce centrilobular necrosis with a subsequent regenerative response.^{32,33} Chronic administration can lead to liver cirrhosis and hepatocarcinoma.³⁴⁻³⁶ TAA induces hepatocyte damage following its metabolism to thioacetamide sulphene and sulphone via a critical pathway involving cytochrome P450-mediated biotransformation.³³ These metabolites are highly reactive and thus lead to denaturation of cellular biomolecules such as lipids, resulting in lipid peroxidation.³⁷

According to the results of this study, the values of albumin and bilirubin in groups treated with thioacetamide increased significantly compared to the control and sham groups. The mean serum albumin concentration in all experimental groups

receiving fish oil omega3 and thioacetamide significantly decreased compared to the thioacetamide group. The average concentration of bilirubin in the experimental groups which received 100mg/kg of fish oil omega3 and thioacetamide showed a significant decrease compared to the group receiving thioacetamide ($P < 0.05$). This means that the fish oil omega-3 had protective effects on liver cells against damage caused by thioacetamide. The histopathological studies also confirmed these results.

Omega3 with their antioxidant properties reduces the toxicity of thioacetamide. The antioxidant and anti-inflammatory effects of omega3 for scavenging of free radicals and inhibiting lipid peroxidation have been reported previously.³⁸

The anti-inflammatory action of omega3 is achieved by reducing the pro-inflammatory cytokines like interleukin-1 and tumor necrosis factor alpha³⁹ and it has effects on transcription factor that regulate inflammatory gene expression (Nuclear factor kappa).⁴⁰

Omega3 fatty acids may also inhibit product of inflammatory and fibrotic mediators including C-reactive protein (CRP), interleukins (IL), tumor necrosis factor alpha (TNF-a), metalloproteina (MMP) 2,9 and tissue inhibition of metalloproteinases.⁴¹ Omega3 fatty acids regulate the TNF-a response to lipopolysaccharide insult. It would be seen in sepsis and this may have a direct role in hepatoprotection⁴². Omega3 fatty acids protection of paracetamol induced liver damage by omega3 fatty acids includes membrane stabilizing action on the hepatocytes.²⁷ Omega3 fatty acids could ameliorate the toxic effects of diethylnitrosamine toxic in part by means of free radical scavenging activity and may be with therapeutic value in the protection of liver against toxic effects of diethylnitrosamine.⁴³

Omega3 polyunsaturated fatty acid may prevent acute liver failure and promotes liver regeneration after 90% hepatectomy in rats. Omega3 polyunsaturated fatty acid significantly increased interleukin-4 and interleukin-10 levels, whereas interleukin-6 and tumor necrosis factor- α levels dramatically decreased.⁴⁴ Administration of omega3 fatty acids may reduce infection rate and improves liver function recovery in HBV-associated hepatocellular carcinoma patient after hepatectomy. This improvement is associated with suppressed production of proinflammatory cytokines in these patients.⁴⁵

In general, the results of this study are in line with the results of other studies. It seems that the oral administration of fish oil omega-3 supplement has protective effect on thioacetamide induced liver toxicity by neutralizing free radicals, stimulating the activity of antioxidant enzymes, and reducing the production of inflammatory cytokinin.

The mean serum albumin concentration in all experimental groups receiving aqueous extract of *Glycyrrhiza glabra* root and thioacetamide significantly decreased compared to the thioacetamide group ($P < 0.05$). This means that the extract had protective effects on liver cells against damage caused by thioacetamide. The histopathological studies also confirmed these results.

Mitsuton Kimura et al reported that In vivo glycyrrhizin accelerates liver regeneration and rapidly lowers serum transaminase activities in 70% partially hepatectomized rats.⁴⁶ Mitsutoshi Kimura et al. reported that glycyrrhizin and some analogues are primary hepatocyte mitogens that bind to EGF receptors and subsequently stimulate the receptor tyrosine kinase/mitogen-activated protein kinase pathway to induced hepatocyte DNA synthesis and proliferation.⁴⁷ Glycyrrhetic

acid decreases ALT by inhibits the enzymatic (11 Beta-hydroxy steroid dehydrogenase) conversion of cortisol to cortisone and increases cortisol levels. Glycyrrhizin inhibit lipopolysaccharide and D-galactosamin-induced liver injury through preventing inflammatory responses and IL-18 production. Glycyrrhizin prevents IL-18-mediated inflammation in liver injury.⁴⁸ Tripathi et al reported that glycyrrhizic acid modulated t-BHP induced apoptosis in primary rat hepatocytes.⁴⁹ Jong Rok Lee et al. reported that licorice extract has hepatoprotective effects by inhibited Bad translocation.⁵⁰ Young Woo Kim et al. reported that liquiritigenin prevent acute liver injuries in rat induced by actaminophen with and without buthionine sulfoximine.⁵¹ Young Mil Kim et al. reported that isoliquirtigenin (ILQ) of *Glycyrrhiza glabra* inhibited oxidative stress as indicated by decreasing iNOS, COX2 induction and nitrotyrosinylation. ILQ protects hepatocyte from oxidative injury infected by fat accumulation.⁵² Kaku Nakagwa et al. reported that licorice flavonoid oil concentration solution has a significant inhibitory effect on liver carcinogenesis.⁵³ Glycyrrhizinic acid, the major component of *Glycyrrhiza glabra* shows hepatoprotective effects by preventing changes in cell membrane permeability and increasing survival rate of hepatocyte.⁵⁴ Extract of *Glycyrrhiza glabra* showed a novel hepatoprotective effects against diclofenac-induced hepatotoxicity in rats.⁵⁵ Glycyrrhetic acid blocks the bioactivity of CCL4 by inhibiting the activity of P4502E1 thereby preventing the hepatoperoxidation.⁵⁶ Glycyrrhizin is a potent chemopreventive compound against lead acetate mediated hepatic oxidative stress toxicity and tumor promotion related responses in rats.⁵⁷ It seems that the oral administration of aqueous extract of *Glycyrrhiza glabra* root has protective

effect on thioacetamide induced biochemical factors and liver tissue by neutralizing free radicals, stimulating the activity of antioxidant enzymes, and reducing the production of inflammatory cytokinin.

CONCLUSION

In general, the results of present study showed that omega3 fish oil and *Glycyrrhiza glabra* aqueous extract could act on liver as potential antioxidant to prevent from biochemical factors and liver tissue changes induced by thioacetamide in male rats.

Thus, if it is supported by more experiments, it is possible to add omega-3 fish oil and *Glycyrrhiza glabra* aqueous extract to the diet of patients with biochemical factors and liver tissue changes.

CONFLICT OF INTEREST

The authors declare that they have no conflict of interest.

ACKNOWLEDGMENTS

Hereby the authors state their deep appreciation for the sincere cooperation devoted to them by the Research Deputy of Shiraz Azad University to conduct this research. The results described in this paper are part of a PhD thesis.

REFERENCES

1. Akanitapichat P, Phraibung K, Nuchklang K, Prompitakkul S. Antioxidant and hepatoprotective activities of five eggplant varieties. *Food Chem Toxicol.* 2010; 48(10): 3017-21.
2. Zaragoza A, Andres D, Sarrion D, Cascales M. Potentiation of thioacetamide hepatotoxicity by phenobarbital pretreatment in rats. Inducibility of FAD monooxygenase system and age effect. *Chem Biol Interact.* 2000; 124(2): 87-101.

3. Sanz N, Diez-Fernandez C, Andres D, Cascales M. Hepatotoxicity and aging: endogenous antioxidant systems in hepatocytes from 2, 6, 12, 18 and 30-month-old rats following a necrogenic dose of thioacetamide. *Biochim Biophys Acta.* 2002; 1587(1): 12-20.
4. Chilakapati J, Korrapati MC, Hill RA, Warbritton A, Latendresse JR, Mehendale HM. Toxicokinetics and toxicity of thioacetamide sulfoxide: a metabolite of thioacetamide. *Toxicology.* 2007; 230(2-3): 105-16.
5. Andres D, Sanchez-Reus I, Bautista M, Cascales M. Depletion of Kupffer cell function by gadolinium chloride attenuates thioacetamide-induced hepatotoxicity. *Biochem Pharmacol.* 2003; 66(6): 917-26.
6. Kusunoki C, Yang L, Yoshizaki T, Nakagawa F, Ishikado A, Kondo M, et al. Omega3 polyunsaturated fatty acid has an antioxidant effects via the Nrf/HO-1 pathway in 3T3-L1 adipocytes. *Biochem Biophys Res Commun.* 2013; 430(1): 225-30.
7. Scorletti E, Byrne CD. Omega-3 fatty acids, hepatic lipid metabolism, and nonalcoholic fatty liver disease. *Annu Rev Nutr.* 2013; 33: 231-48.
8. Ogawa S, Abe T, Nako K, Okamura M, Senda M, Sakamoto T, et al. Eicosapentaenoic acid improves glycemic control in elderly bedridden patients with type 2 diabetes. *Tohoku J Exp Med.* 2013; 231(1): 63-74.
9. Abeywardena MY, Patten GS. Role of omega3 long-chain polyunsaturated fatty acids in reducing cardio-metabolic risk factors. *Endocr Metab Immune Disord Drug Targets.* 2011; 11(3): 232-46.
10. Su KP, Huang SY, Chiu CC, Shen WW. Omega-3 fatty acids in major depressive disorder. A preliminary double-blind, placebo-controlled trial. *Eur Neuropsychopharmacol.* 2003; 13(4): 267-71.

11. Freeman MP. Omega-3 fatty acids in psychiatry: A review. *Ann Clin Psychiatry*. 2000; 12(3): 159-65.
12. Simopoulos AP. Omega3 fatty acids in inflammation and autoimmune diseases. *J Am Coll Nutr*. 2002; 21(6): 495-505.
13. De Vizia B, Raia V, Spano C, Pavlidis C, Coruzzo A, Alessio M. Effect of an 8-month treatment with omega-3 fatty acids (eicosapentaenoic and docosahexaenoic) in patients with cystic fibrosis. *JPEN J Parenter Enteral Nutr*. 2003; 27(1): 52-7.
14. Serhan CN, Chiang N. Endogenous pro-resolving and anti-inflammatory lipid mediators: a new pharmacologic genus. *Br J Pharmacol*. 2008; 153 Suppl 1: S200-15.
15. Akahoshi T, Hashizume M, Tanoue K, Shimabukuro R, Gotoh N, Tomikawa M, et al. Role of the spleen in liver fibrosis in rats may be mediated by transforming growth factor beta-1. *J Gastroenterol Hepatol*. 2002; 17(1): 59-65.
16. Wendel M, Heller AR. Anticancer actions of omega-3 fatty acids-current state and future perspectives. *Anticancer Agents Med Chem*. 2009; 9(4): 457-70.
17. Li CC, Yang HT, Hou YC, Chiu YS, Chiu WC. Dietary fish oil reduces systemic inflammation and ameliorates sepsis-induced liver injury by up-regulating the peroxisome proliferator-activated receptor gamma-mediated pathway in septic mice. *J Nutr Biochem*. 2014; 25(1): 19-25.
18. Jangale NM, Devarshi PP, Dubal AA, Ghule AE, Koppikar SJ, Bodhankar SL, et al. Dietary flaxseed oil and fish oil modulates expression of antioxidant and inflammatory genes with alleviation of protein glycation status and inflammation in liver of streptozotocin-nicotinamide induced diabetic rats. *Food Chem*. 2013; 141(1): 187-95.
19. Kim K, Jung N, Lee K, Choi J, Kim S, Jun J, et al. Dietary omega3 polyunsaturated fatty acids attenuate hepatic ischemia/reperfusion injury in rats by modulating toll-like receptor recruitment into lipid rafts. *Clin Nutr*. 2013; 32(5): 855-62.
20. Rastogi R, Mehrotra B. *Compendium of Indian Medicinal Plants* published by Central Drug Research Institute. Lucknow and National Institute of Sciences Communication and Information Resources: New Delhi. 1994: 395-8.
21. Fukai T, Baosheng C, Maruno K, Migakawa Y, Konoshi M. An isopernylated flavonone from *Glycyrrhiza glabra* and re-assay of liquoric phenols. *Phytochemistry*. 1998; 49(1): 2005-13.
22. Kaur R, Arora S. Chemical constituents and biological activities of *Chukrasia tabularis* A. Juss: A review. *J Med Plants Res*. 2009; 3(4): 196-216.
23. Huo HZ, Wang B, Liang YK, Bao YY, Gu Y. Hepatoprotective and antioxidant effects of licorice extract against CCl(4)-induced oxidative damage in rats. *Int J Mol Sci*. 2011; 12(10): 6529-43.
24. Rasool M, Iqbal J, Malik A, Ramzan HS, Qureshi MS, Asif M, et al. Hepatoprotective Effects of *Silybum marianum* (Silymarin) and *Glycyrrhiza glabra* (Glycyrrhizin) in Combination: A Possible Synergy. *Evid Based Complement Alternat Med*. 2014; 2014: 641597.
25. Zheng YF, Wei JH, Fang SQ, Tang YP, Cheng HB, Wang TL, et al. Hepatoprotective triterpene saponins from the roots of *Glycyrrhiza inflata*. *Molecules*. 2015; 20(4): 6273-83.
26. Sirag HM. Biochemical studies on thioacetamide toxicity in male albino rats and the role of tomato juice as an antioxidant. *Mansoura J Forensic Med Clin Toxicol*. 2007; 15: 90-114.
27. Meganathan M, Madhana Gopal K, Sasikala P, Mohan J, Gowdhaman N, Balamurugan K, et al. Evaluation of hepatoprotective effect of omega3-Fatty acid

against paracetamol induced liver in albino rats. *Global J Pharmacol.* 2011; 5(1): 50-3.

28. Renjie L, Shidi S, Changsen S. Protective effect of *Glycyrrhiza glabra* polysaccharides against tetrachloride-induced liver injury in rats. *Afr J Microbiol Res.* 2010; 4(16): 1784-7.

29. Bastway Ahmed M, Hasona N, Selemain A. Protective effects of extract from dates (*Phoenix dactylifera* L.) and ascorbic acid on thioacetamide-induced hepatotoxicity in rats. *Iran J Pharm Res.* 2010; 193-201.

30. Al Bayaty F, Abdulla M, Hassan MA, Masud M. Wound healing potential by hyaluronate gel in streptozotocin-induced diabetic rats. *Sci Res Essays.* 2010; 5(18): 2756-60.

31. Kabiri N, Setorki M, Darabi MA. Protective effects of kombucha tea and silimarin against thioacetamide induced hepatic injuries in wistar rats. *World Appl Sci J.* 2013; 27(4): 524-32.

32. Mangipudy RS, Chanda S, Mehendale HM. Tissue repair response as a function of dose in thioacetamide hepatotoxicity. *Environ Health Perspect.* 1995; 103(3): 260-7.

33. Okuyama H, Nakamura H, Shimahara Y, Araya S, Kawada N, Yamaoka Y, et al. Overexpression of thioredoxin prevents acute hepatitis caused by thioacetamide or lipopolysaccharide in mice. *Hepatology.* 2003; 37(5): 1015-25.

34. Low TY, Leow CK, Salto-Tellez M, Chung MC. A proteomic analysis of thioacetamide-induced hepatotoxicity and cirrhosis in rat livers. *Proteomics.* 2004; 4(12): 3960-74.

35. Moreira E, Fontana L, Periago JL, Sanchez De Medina F, Gil A. Changes in fatty acid composition of plasma, liver microsomes, and erythrocytes in liver cirrhosis induced by oral intake of thioacetamide in rats. *Hepatology.* 1995; 21(1): 199-206.

36. Natarajan SK, Thomas S, Ramamoorthy P, Basivireddy J, Pulimood AB,

Ramachandran A, et al. Oxidative stress in the development of liver cirrhosis: A comparison of two different experimental models. *J Gastroenterol Hepatol.* 2006; 21(6): 947-57.

37. Wang CH, Chen YJ, Lee TH, Chen YS, Jawan B, Hung KS, et al. Protective effect of MDL28170 against thioacetamide-induced acute liver failure in mice. *J Biomed Sci.* 2004; 11(5): 571-8.

38. Ernest KJP, Magdalena K. Fatty acid facts. Part III cardiovascular disease or a fish diet in not fishy. *Drug News Perspect.* 2008; 21(10): 552.

39. Wardle EN. Ways of treating IgA nephropathies. *Saudi J Kidney Dis Transpl.* 2000; 11(3): 325-33.

40. Calder PC. Polyunsaturated fatty acids and inflammatory processes: New twists in an old tale. *Biochimie.* 2009; 91(6): 791-5.

41. Curfs JH, Meis JF, Hoogkamp-Korstanje JA. A primer on cytokines; sources, receptors, effects, and inducers. *Clin Microbiol Rev.* 1997; 10: 742-80.

42. Babcock T, Helton WS, Espat NJ. Eicosapentaenoic acid (EPA): An antiinflammatory omega-3 fat with potential clinical applications. *Nutrition.* 2000; 16(11-12): 1116-8.

43. Atakisi O, Atakisi E, Ozcan A, Karapehlivan M, Kart A. Protective effect of omega-3 fatty acids on diethylnitrosamine toxicity in rats. *Eur Rev Med Pharmacol Sci.* 2013; 17(4): 467-71.

44. Qiu YD, Wang S, Yang Y, Yan XP. Omega3 polyunsaturated fatty acids promote liver regeneration after 90% hepatectomy in rats. *World J Gastroenterol.* 2012; 18(25): 3288-95.

45. Wu Z, Qin J, Pu L. Omega-3 fatty acid improves the clinical outcome of hepatectomized patients with hepatitis B virus (HBV)-associated hepatocellular carcinoma. *J Biomed Res.* 2012; 26(6): 395-9.

46. Kimura M, Moro T, Motegi H, Maruyama H, Sekine M, Okamoto H, et al. In vivo glycyrrhizin accelerates liver regeneration and rapidly lowers serum transaminase activities in 70% partially hepatectomized rats. *Eur J Pharmacol.* 2008; 579(1-3): 357-64.
47. Kimura M, Inoue H, Hirabayashi K, Natsume H, Ogihara M. Glycyrrhizin and some analogues induce growth of primary cultured adult rat hepatocytes via epidermal growth factor receptors. *Eur J Pharmacol.* 2001; 431(2): 151-61.
48. Yoshida T, Abe K, Ikeda T, Matsushita T, Wake K, Sato T, et al. Inhibitory effect of glycyrrhizin on lipopolysaccharide and d-galactosamine-induced mouse liver injury. *Eur J Pharmacol.* 2007; 576(1-3): 136-42.
49. Tripathi M, Singh BK, Kakkar P. Glycyrrhizic acid modulates t-BHP induced apoptosis in primary rat hepatocytes. *Food Chem Toxicol.* 2009; 47(2): 339-47.
50. Lee JR, Park SJ, Lee HS, Jee SY, Seo J, Kwon YK, et al. Hepatoprotective activity of licorice water extract against cadmium-induced toxicity in rats. *Evid Based Complement Alternat Med.* 2009; 6(2): 195-201.
51. Kim YM, Kim TH, Kim YW, Yang YM, Ryu DH, Hwang SJ, et al. Inhibition of liver X receptor-alpha-dependent hepatic steatosis by isoliquiritigenin, a licorice antioxidant flavonoid, as mediated by JNK1 inhibition. *Free Radic Biol Med.* 2010; 49(11): 1722-34.
52. Kim YW, Ki SH, Lee JR, Lee SJ, Kim CW, Kim SC, et al. Liquiritigenin, an aglycone of liquiritin in *Glycyrrhizae radix*, prevents acute liver injuries in rats induced by acetaminophen with or without buthionine sulfoximine. *Chem Biol Interact.* 2006; 161(2): 125-38.
53. Nakagawa K, Hosoe K, Hidaka T, Nabae K, Kawabe M, Kitano M. Inhibition by licorice flavonoid oil of glutathione S-transferase-positive foci in the medium-term rat hepatocarcinogenesis bioassay. *Nutr Res.* 2010; 30(1): 74-81.
54. Maurya SK, Raj K, Srivastava AK. Antidyslipidaemic activity of *Glycyrrhiza glabra* in high fructose diet induced dyslipidaemic Syrian golden hamsters. *Indian J Clin Biochem.* 2009; 24(4): 404-9.
55. Hamza AA. *Curcuma longa*, *Glycyrrhiza glabra*, and *Moringa oleifera* ameliorate diclofenac-induced hepatotoxicity in rats. *Am J Pharmacol Toxicol.* 2007; 2(2): 80-8.
56. Jeong HG, You HJ, Park SJ, Moon AR, Chung YC, Kang SK, et al. Hepatoprotective effects of 18 beta-glycyrrhetic acid on carbon tetrachloride-induced liver injury: inhibition of cytochrome P450 2E1 expression. *Pharmacol Res.* 2002; 46(3): 221-7.
57. Rahman S, Sultana S. Chemopreventive activity of glycyrrhizin on lead acetate mediated hepatic oxidative stress and its hyperproliferative activity in wistar rats. *Chem Biol Interact.* 2006; 160(1): 61-9.

How to cite the article: Moghadamnia D, Mokhtari M, Khatamsaz S. Comparison of protective effects of omega3 fish oil and aqueous extract of *Glycyrrhiza glabra* root on biochemical factors and liver tissue changes induced by thioacetamide in male rats. *Adv Herb Med.* 2016; 2(1): 7-19.