

Prevention of diagnostic errors in position of conus medullaris in adult patients

Ayoob Rostamzadeh¹, Masoud Amiri², Mohammad Taghi Joghataei³, Mohammad Farzizadeh⁴, Daryoush Fatehi^{5*}

¹Anatomical Sciences Dept., Shahrekord University of Medical Sciences, Shahrekord, I.R. Iran; ²Social Health Determinants Research Center, Shahrekord University of Medical Sciences, Shahrekord, I.R. Iran; ³Cellular and Molecular Research Center, Anatomy and Neuroscience Dept., Iran University of Medical Sciences, Tehran, I.R. Iran; ⁴Radiology Dept., Kermanshah University of Medical Sciences, Kermanshah, I.R. Iran; ⁵Medical Physics Dept., Shahrekord University of Medical Sciences, Shahrekord, I.R. Iran.

Received: 15/Apr/2015 Accepted: 28/Aug/2015

ABSTRACT

Background and aims: Finding the safe location of spinal cord for cerebrospinal fluid (CSF) during surgical procedures is very important due to its various nature for each patient as well as its potential peripheral nervous system hazards. The aim of this study was to find the relationship between the location of conus medullaris (CM) and gender, age and body mass index (BMI) in order to minimize the potential diagnostic errors.

Methods: Magnetic resonance imaging (MRI) with T1-weighted sagittal spin echo sequences of the lumbar spine was studied in 350 patients older than 20 years old, whom had been referred for imaging in order to assess the potential causes of low back pain of the lumbar spine, and were referred to Shahid Chamran MRI center in Sanandaj, located in the west of Iran, this study was done in 2014. The results were compared with international standards to reveal the potential errors.

Results: In different age groups, the mean position was varied ranging from T12-L1 intervertebral disc to upper part of L1 middle third, not clinically significant. The inter canal position of the spinal cord was toward dorsal. No significant relationship was found between CM and gender, age as well as BMI. Similar relationship was found for the spinal cord position in spinal column.

Conclusion: There is a safe region of 2-4 vertebral bodies and intervertebral spaces during spinal block. It means that the variation of CM position and its end level could be a guidance to realize that why neurological symptoms may vary in different patients.

Keywords: Diagnostic errors, Conus medullaris, Anatomic variations, Imaging modalities.

INTRODUCTION

It is believed that spinal anesthesia is safe and harmless; however, the incidence of side effects ranges from 3 to 45%.¹⁻⁷ Conus medullaris (CM) is the most distal point of the spinal cord and dura that could be visualized on the sagittal sequence. CM location follows

a normal distribution, from the lower third of L1 (ranging from the middle third of T12 to the upper third of L3).⁸ It is important to know the level of the lumbar spine to have a safe spinal block after an intervertebral injection. Counting the intervertebral spaces before

* **Corresponding author:** Daryoush Fatehi, Medical Physics Dept., Shahrekord University of Medical Sciences, Shahrekord, I.R. Iran, Tel: 00983833335652, E-mail: d.fatehi@yahoo.com

spinal block is an important way to evade damage to the spinal cord. In two thirds of the patients; however, finding the intervertebral space with palpation fails to give us the right location. In fact, using a safe location for spinal block (a form of regional anesthesia involving injection of a local anesthetic into the subarachnoid space, generally through a fine needle, usually 9 cm long) during surgical procedures is very important. Moreover, the neurological structures at the level of the thoracolumbar spine are critical for lower-extremity motor, sensory function, as well as bowel, bladder, and sexual functions.⁹ The lumbar sympathetic, sacral parasympathetic and sacral somatic nerves originate within the CM and they are carried within the nerve roots of the cauda equine.^{10,11} The cauda equina is an anatomical region, where the only remnant of the spinal cord is the filum terminal and the neurological structures include the lumbar and sacral nerve roots.¹² There are different imaging methods for spinal column and spinal cord; such as radiography, computed tomography (CT) scan and magnetic resonance imaging (MRI)¹³ (Figure 1).

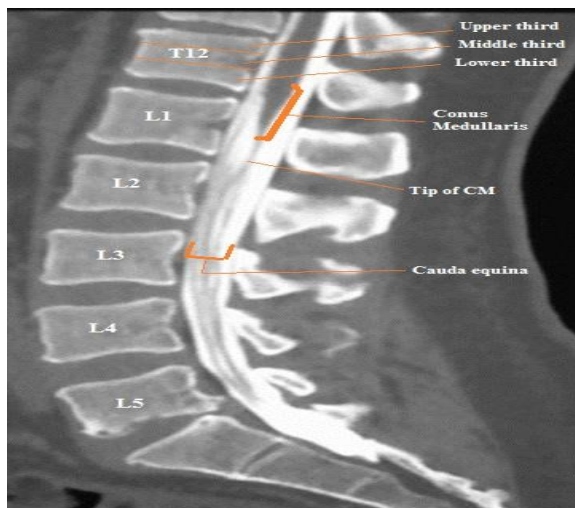


Figure 1: Coronal CT scan of the lumbar spine shows spinal column and vertebrae. Note to position of conus medullaris and cauda equina in spinal canal.

Due to optimal assessment of bone anatomy and degree of canal occlusion, CT scan has a variety of applications of the imaging of spinal region. Nonetheless, CT scanning has a limited capacity for visualizing the precise size of a traumatic disc herniation, presence of epidural or subdural hematomas, nature and degree of ligamentous disruption, or the changes in the spinal cord parenchyma. However, MRI has improved our ability to visualize and comprehend the degree of soft-tissue ligamentous injury, intervertebral disc disruption and herniation, spinal cord parenchymal edema, and hemorrhage or disruption following spinal injury. Furthermore, MRI is a noninvasive and nonionizing modality that allows improved visualization of the spinal cord parenchyma and adjacent soft-tissue structures.^{13,14}

Unfortunately, MRI has a few drawbacks. It may not be available in all institutions, it requires more time to obtain a full complement of images, and patients with claustrophobia or patients with specific ferromagnetic implants cannot undergo MR imaging.¹⁵

Due to raising costs and potential dangers, lumbar radiograph and MRI are not appropriate for routine use to check the conus position and lumbar spinal level in every spinal block procedure.¹⁶ Purpose of this study was to find the relationship between the location of CM and spinal position in adult patients, with age, gender, and body mass index (BMI).

METHODS

This cross-sectional study was conducted on patients referring to Shahid Chamran MRI center in Sanandaj, West of Iran in 2014. All the procedures were done in accordance with the ethical standards of the responsible committee on human experimentation institutional. Informed consent was obtained from all patients for attending in the study.

The study population were patients older than 20 years of age during which final growth of the skeletal system and final position of the CM in spinal column occurred. Exclusion criteria included spinal operation, kyphoscoliosis, congenital anomalies such as syringomyelia or dural cyst, and abnormality of the vertebrae or cord. For this study, 350 eligible patients (199 males and 151 females) were selected during May to December 2014. T1-weighted sagittal spin echo MRI sequences of the lumbar spine with the patient in the supine position were studied to evaluate the location of CM. The patients' height and weight were measured by a trained medical technician. Images were obtained by 1.5 Tesla MR Scanner (Siemens, Symphony, Germany) with slice thickness of 4-5mm and slice interval of 1mm. A line vertical to the long axis of the cord and the dura was extended to the adjacent vertebra, and the position was defined in relation to the vertebra. Each vertebra and intervertebral space was divided to four sections. Additionally, vertebral body was divided to three identical parts: upper, middle, and lower thirds (Figure 2).¹⁷

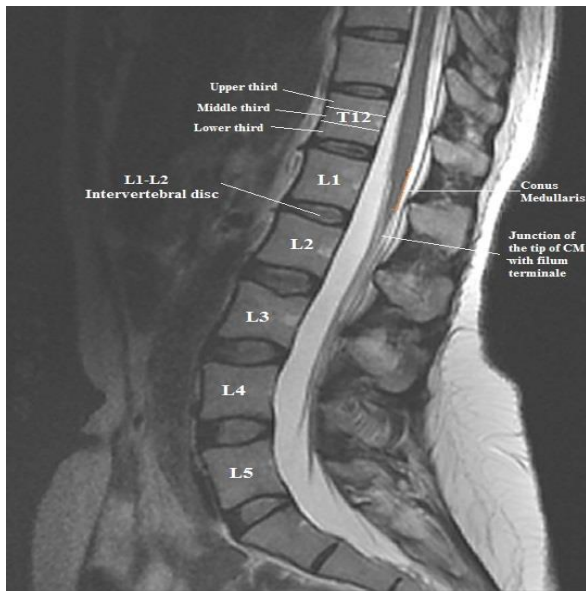


Figure 2: T2-weighted sagittal MRI showing spinal cord, conus medullaris position and its boundaries.

A horizontal line was drawn from the most distal part of the spinal cord on midsagittal image perpendicular to the longitudinal axis of the spine. The position of the CM was defined as the vertebral segment or intervertebral disc space that was determined by the line. In addition, the shape of the CM in those imaged was investigated by three types: type A was defined as the tip of the conus bevel deviated to ventral, type B to central, and type C to dorsal (Figure 3).¹⁸

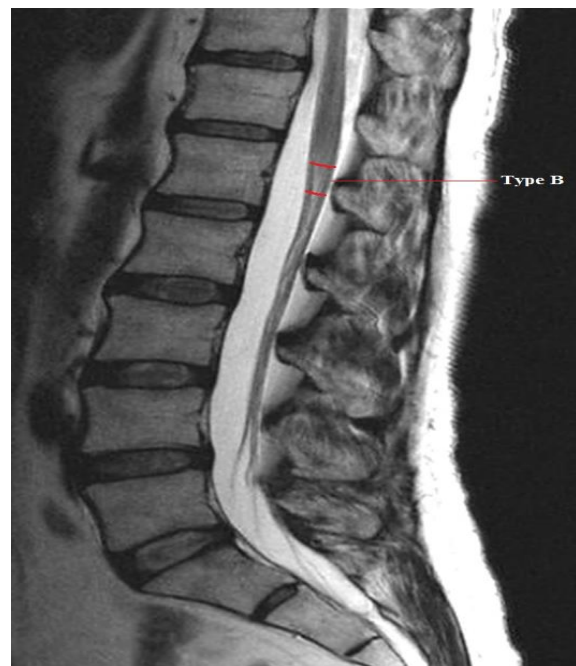


Figure 3: The position of the conus medullaris in spinal canal. Type B was defined as the tip of the conus to the central.

The vertebral body was determined by counting downward from Lower third of T11 (as the highest level) to middle third of L4; lowest (as the lowest level). This method was used for uniformity of the procedure. The tip of the lowest level of spinal cord was accepted as the CM in sagittal MRI. The procedure was conducted by a radiologist, blinded to the study purpose. The recorded data were: age, gender, BMI, positions of the CM, and spinal position. SPSS (version 20) was applied for

the statistical analysis using Chi-Square, Kruskal Wallis Test, and ANOVA. The Kolmogorov-Smirnov test was performed to determine the variability in the tip of the conus level. Since based on the Kolmogorov-Smirnov analysis, there was no difference between the BMI and CM in male patients; ANOVA test was also applied. The two-sample Kolmogorov-Smirnov test was performed to determine the differences between genders. The p-values were significant at level of less than 0.05.

RESULTS

Table 1 summarizes the main characteristics of the study population. There was no significant difference between men and women with regards to the characteristics of weight, height, CM and age.

Table 1: Main characteristics of study population

Characteristics	Gender	
	Male	Female
	Mean ± SD	Mean ± SD
Weight	72.39 ± 8.8	73.29 ± 8.03
Height	177.83 ± 5.65	173.52 ± 3.7
CM	10.54 ± 3.64	11.35 ± 3.59
Age	39.51 ± 10.76	40.78 ± 10.92

The position of the CM was between T12 upper third and L2 middle third with a mean of L1 upper third. The conus was located from T12 upper third to L2 upper third (mean: L1 upper third) in males and from T12 upper third to L2 middle third (mean: L1 middle third) in females. This difference was not statistically significant. In different age groups, the mean position was varied ranging from T12-L1 intervertebral disc to upper part of L1 middle third and did not seem to be clinically significant (Figure 4).

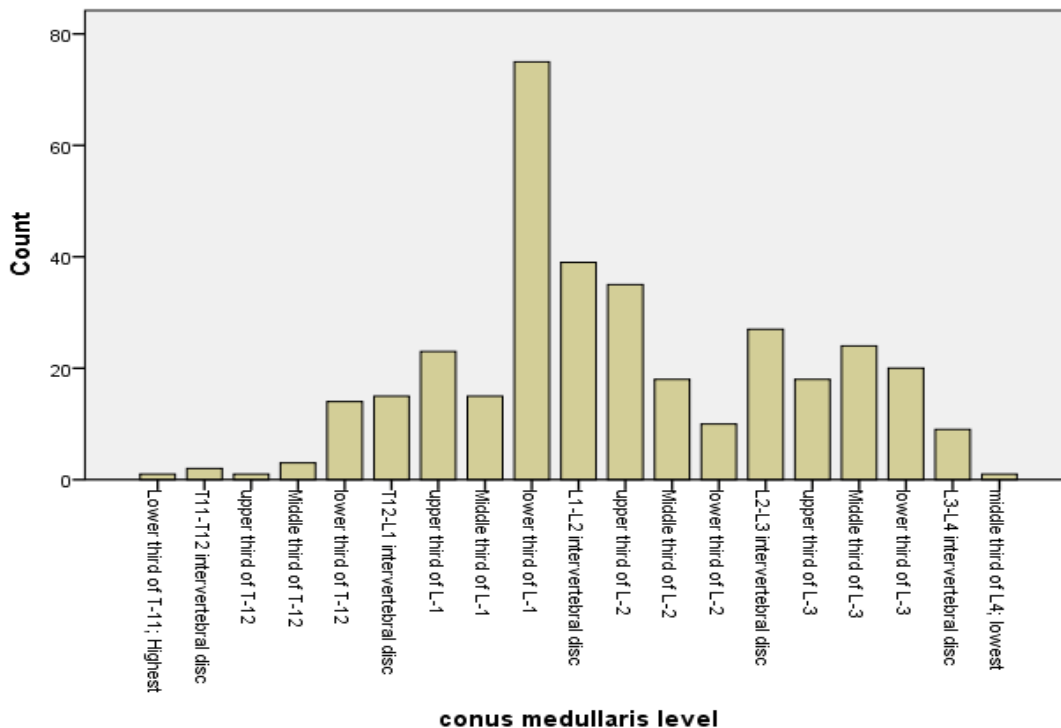


Figure 4: Distribution of the conus medullaris level in the patients of this study. The comparison of the conus medullaris had no significant relationships with gender

Images from 350 patients were assessed for the study. There were no significant

discrepancy between the position of CM and spinal position, physical parameters such as

age, gender and BMI. The results also showed that the inter canal position of the spinal cord was toward dorsal (Table 2) (Figure 5).

Table 2: The position of the spinal cord's tip in the spinal canal

Position	Gender		Total
	Male	Female	
	No. (%)	No. (%)	
Dorsal	42 (21.1%)	116 (76.8%)	158 (45.1%)
Central	119 (59.8%)	24 (15.9%)	143 (40.9%)
Ventral	38 (19.1%)	11 (7.3%)	49 (14.0%)
Total	199 (100%)	151 (100%)	350 (100%)

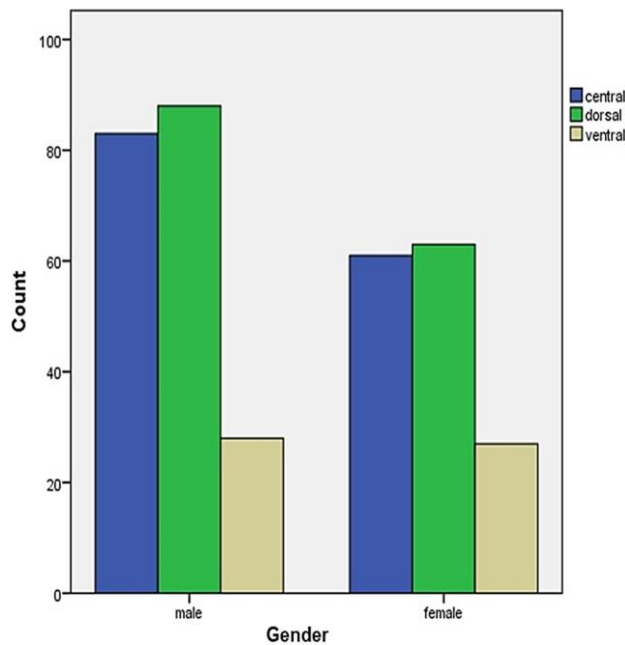


Figure 5: The inter canal position of the spinal cord in the study patients showing that the position is toward dorsal.

DISCUSSION

Large variations in CM position were found in normally developed adults; with extensive data available for cadaveric and live populations. The study showed that in different age groups, the mean position varied with no clinically significant result. The inter canal position of the spinal cord was also toward dorsal. There was no significant relationship

between CM and spinal cord position in spinal column with gender, age as well as BMI.

Previous studies suggested that CM could reach the adult's position by 2 years of age and lies at an average position of L1 to L2. Up to now, the position of CM has been reported in different articles which were conducted on cadaver. For example, Thomson found that the position of the conus between 5 mm above the lower margin of T12 and upper margin of L3 among 198 adult cadavers, lower in women than in men.¹⁹ In the present study, there was no statistical difference in males and females regarding the position of CM. Similarly, Cotter 20 with 234 cases reported that there was no relationship between cord length and vertebral column. In his series the level of the CM varied between the middle of T12 and the lower border of L2, but in 77% of white males cord termination level was between the upper border of L1 and L2.²⁰ These findings supported the results of present study.

However, in an examination of 240 adult cadavers, Needles reported that the cord termination was between the middle third of T12 and the lower third of L3; and in 49% of his series, the CM level was between the lower third of L1 and the upper third of L2.²¹ There was a significant statistical difference in CM level between male and female groups in the studies of Needles.²¹ In contrast, no difference was found in distribution of conus position between males and females in our study.

Reiman and Anson studied 129 consecutive adult specimens. They explained the mean conus position to be at L1- L2, ranging between the lower third of T12 and the middle third of L3.²² Malas and colleagues reported that CM was at L4 level in 14 out of 25 fetuses, at L2 level in 10 out of 25 neonates; whereas, CM was at L1-L2 level in 11 out of 25 adults.²³ Nowadays, MRI has made it possible to determine the distribution of CM level in the living population. In addition, in the study of Kim et al.²⁴ it was

stated that the CM was most frequently located at the level of lower third of L1 and then L1-L2. In a study, with 504 adult cases without spinal deformity, found that the tip of the conus was between middle third of T12 and upper third of L3 with a mean position at the lower third of L1.²⁵ They found that conus position was slightly lower in males than in females without any statistical significance. The results of this study are congruent with our study. Although, they did not evaluate racial differences and they did not find any change in the conus location with increasing age. However, we considered other factors like gender, age and BMI in the present study. Demiryürek et al. studied 639 patients and noticed that the conus tip was from T11-T12 intervertebral disc space to the upper third of L3.⁸ The conus were near one vertebra lower in females (mostly at L1-L2 disc) than in males (mostly at T12-L1 disc). They found no difference in the conus level related to increasing age, which agree with the results of the present study. Soleiman and colleagues assessed 635 patients and reported the mean conus termination at L1 middle third.²⁶ They also reported a difference between females (mean L1 middle third) and males (mean L1 lower third). In contrast to the findings of Saifuddin, the results of the current study did not show a significant difference between CM position in males and female.²⁵ Another study suggests that because older patients with osteoporosis or age-related vertebral deformity usually have a reduced height of the vertebral body, the segmental position of the conus could be lower.²⁷ This result is not approved by the present study.

In general, the positions of the CM and spinal position measured in the participants of the present study corresponded well to the results of previous studies. However, other studies did not include the relationship between CM and spinal position compared with BMI.²⁸ Thus, this feature of the present study could be an element that might be

emphasized in future studies with a larger sample size. Other studies found age as an element that could change the position of CM; this was incongruent with the current study.²⁴

In conclusion, the results of the present study could be also helpful for the following specialists: anesthetists, neurosurgeons, medical emergency specialists, and radiographers. An anesthetist should exactly know anatomical variations to achieve a minimum of spinal cord trauma during an anesthetic procedure. Moreover, a neurosurgeon needs the level of CM as well as its position during a lumbar puncture procedure. Additionally, as we showed in this study that the position of CM is mostly dorsal, it could be dangerous for patients undergo a CSF aspiration.

Furthermore, the variety of the position of the CM in patients might be dangerous when one face a patient in an emergency ward for triage and transferring him/her to imaging centre. Finally, the variation of the CM position and its end level could be a guidance that why neurological symptoms varies for different patients. The most common level of conus medullaris (CM) was the lower third of L1 both in males and females. One should consider that checking and marking the corresponding vertebral level may be helpful to select a safe intervertebral level. The present study showed that it would be practical to know the CM position in the same patient population; since lumbar radiograph and MRI cannot be routinely recommended for all patients scheduled for spinal block. The distribution of CM location in a large adult population was shown to range from the middle third of T12 to the upper third of L3 level. Our study which has a fairly large number of cases is suggested to help to determine the range of CM level in Kurdistan (Iran) people. It is important to consider the possible range of CM level when performing lumbar puncture and avoid complications for lumbar surgery. It is possible that the ethnic

differences in the samples may be relevant to the diverse findings of these studies. Therefore, it is recommended that further studies be conducted using different ethnicities. Although there is substantial number of researches in this area, there are still many issues for debate; for example, the effects of race, sport and nutrition.

CONFLICT OF INTEREST

The authors declare that they have no conflict of interests.

ACKNOWLEDGEMENT

The study was supported by the Research Council of the Kurdistan University of Medical Sciences.

REFERENCES

1. Suppa E, Valente A, Catarci S, Zanfini BA, Draisci G. A study of low-dose S-ketamine infusion as "preventive" pain treatment for cesarean section with spinal anesthesia: benefits and side effects. *Minerva Anesthesiol.* 2012; 78(7): 774-81.
2. Jiang YH, Jiang W, Jiang LM, Lin GX, Yang H, Tan Y, et al. Clinical efficacy of acupuncture on the morphine-related side effects in patients undergoing spinal-epidural anesthesia and analgesia. *Chin J Integr Med.* 2010; 16(1): 71-4.
3. Standl T, Stanek A, Burmeister MA, Gruschow S, Wahlen B, Muller K, et al. Spinal anesthesia performance conditions and side effects are comparable between the newly designed Ballpen and the Sprotte needle: results of a prospective comparative randomized multicenter study. *Anesth Analg.* 2004; 98(2): 512-7.
4. Mojica JL, Melendez HJ, Bautista LE. The timing of intravenous crystalloid administration and incidence of cardiovascular side effects during spinal anesthesia: the results from a randomized controlled trial. *Anesth Analg.* 2002; 94(2): 432-7.
5. Arndt JO, Bomer W, Krauth J, Marquardt B. Incidence and time course of cardiovascular side effects during spinal anesthesia after prophylactic administration of intravenous fluids or vasoconstrictors. *Anesth Analg.* 1998; 87(2): 347-54.
6. Viscomi CM, Hill K, Johnson J, Sites C. Spinal anesthesia versus intravenous sedation for transvaginal oocyte retrieval: reproductive outcome, side-effects and recovery profiles. *Int J Obstet Anesth.* 1997; 6(1): 49-51.
7. Carpenter RL, Caplan RA, Brown DL, Stephenson C, Wu R. Incidence and risk factors for side effects of spinal anesthesia. *Anesthesiology.* 1992; 76(6): 906-16.
8. Demiryurek D, Aydingoz U, Aksit MD, Yener N, Geyik PO. MR imaging determination of the normal level of conus medullaris. *Clin Imaging.* 2002; 26(6): 375-7.
9. Harkey HL, 3rd, White EA, Tibbs RE, Jr., Haines DE. A clinician's view of spinal cord injury. *Anatomical record Part B, New anatomist.* 2003; 271(1): 41-8.
10. Cramer GD, Darby SA. *Clinical anatomy of the spine, spinal cord, and ANS.* USA: Mosbey; 2013.
11. Lin N, Bebawy JF, Hua L, Wang BG. Is spinal anaesthesia at L2-L3 interspace safe in disorders of the vertebral column? A magnetic resonance imaging study. *Br J Anaesth.* 2010; 105(6): 857-62.
12. Kingwell SP, Curt A, Dvorak MF. Factors affecting neurological outcome in traumatic conus medullaris and cauda equina injuries. *Neurosurg Focus.* 2008; 25(5): E7.
13. Stroman PW, Wheeler-Kingshott C, Bacon M, Schwab JM, Bosma R, Brooks J, et al. The current state-of-the-art of spinal cord imaging: methods. *Neuroimage.* 2014; 84: 1070-81.
14. Archip N, Erard PJ, Egmont-Petersen M, Haefliger JM, Germond JF. A knowledge-based approach to automatic detection of the spinal cord in CT images. *IEEE Trans Med Imaging.* 2002; 21(12): 1504-16.

15. Norman D, Mills CM, Brant-Zawadzki M, Yeates A, Crooks LE, Kaufman L. Magnetic resonance imaging of the spinal cord and canal: potentials and limitations. *AJR Am J Roentgenol.* 1983; 141(6): 1147-52.
16. Parizel PM, van der Zijden T, Gaudino S, Spaepen M, Voormolen MH, Venstermans C, et al. Trauma of the spine and spinal cord: imaging strategies. *Eur Spine J.* 2010; 19 Suppl 1: S8-17.
17. Ba Z, Zhao W, Wu D, Huang Y, Kan H. MRI study of the position of the conus medullaris in patients with lumbar spinal stenosis. *Orthopedics.* 2012; 35(6): e899-902.
18. Arai Y, Shitoto K, Takahashi M, Kurosawa H. Magnetic resonance imaging observation of the conus medullaris. *Bull Hosp Jt Dis.* 2001; 60(1): 10-2.
19. Thomson A. Fifth annual report of the committee of collective investigation of the anatomical society of Great Britain and Ireland for the year 1893-94. *J Anat Physiol.* 1894; 29(Pt 1): 35-60.
20. McCotter RE. Regarding the length and extent of the human medulla spinalis. *Anat Rec.* 1916; 10(9): 559-64.
21. Needles JH. The caudal level of termination of the spinal cord in American whites and American negroes. *Anat Rec.* 1935; 63(4): 417-24.
22. Reimann AF, Anson BJ. Vertebral level of termination of the spinal cord with report of a case of sacral cord. *Anat Rec.* 1944; 88(1): 127-38.
23. Malas MA, Seker M, Salbacak A, Buyukmumcu M, Karabulut AK, Yardimci C. The relationship between the lumbosacral enlargement and the conus medullaris during the period of fetal development and adulthood. *Surg Radiol Anat.* 2000; 22(3-4): 163-8.
24. Kim JT, Bahk JH, Sung J. Influence of age and sex on the position of the conus medullaris and Tuffier's line in adults. *Anesthesiology.* 2003; 99(6): 1359-63.
25. Saifuddin A, Burnett SJ, White J. The variation of position of the conus medullaris in an adult population. A magnetic resonance imaging study. *Spine.* 1998; 23(13): 1452-6.
26. Soleiman J, Demaerel P, Rocher S, Maes F, Marchal G. Magnetic resonance imaging study of the level of termination of the conus medullaris and the thecal sac: influence of age and gender. *Spine.* 2005; 30(16):1875-80.
27. Belkoff SM, Mathis JM, Fenton DC, Scribner RM, Reiley ME, Talmadge K. An ex vivo biomechanical evaluation of an inflatable bone tamp used in the treatment of compression fracture. *Spine.* 2001; 26(2): 151-6.
28. Binokay F, Seydaoglu G, Erman T, akgül e, biçakci k. Relationship between the levels of normal conus medullaris and body mass index in the Turkish adult population. *Neurosurg Quart.* 2013; 23(2): 81-4.

How to cite the article: Rostamzadeh A, Amiri M, Joghataei MT, Farzizadeh M, Fatehi D. Prevention of diagnostic errors in position of conus medullaris in adult patients. *Int J Epidemiol Res.* 2015; 2(3): 118-125.