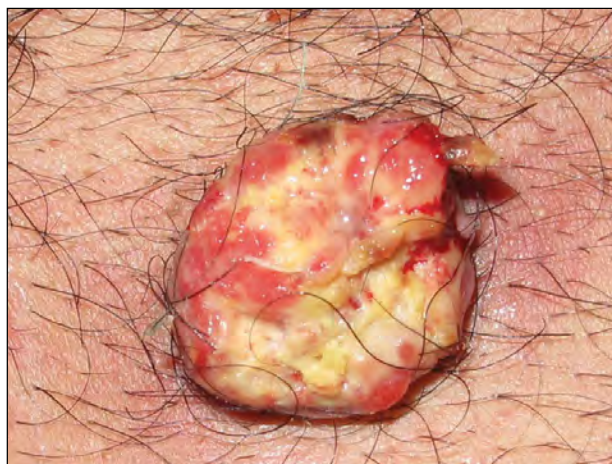
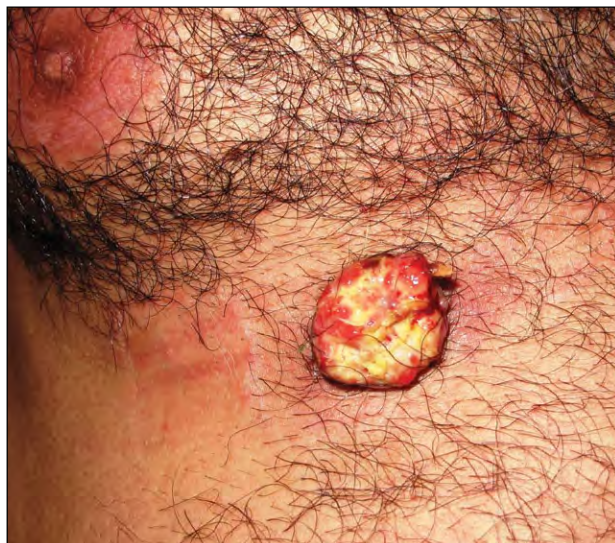
PHOTO QUIZ

What Is Your Diagnosis?



A 51-year-old man was referred to the dermatology department for a symptomless tumor below the right nipple that had a tendency to bleed. The patient reported that the lesion had started as a small papule that slowly enlarged over 4 months. He had no history of cutaneous trauma, excessive sun exposure, immunodeficiency, or radiation treatment in early childhood. Physical examination revealed a firm, ulcerated, yellow to red, dome-shaped, nodular mass overlying the chest below the right nipple, measuring 2.5 cm in diameter. A cutaneous biopsy specimen was obtained from the tumor and sent for histologic analysis.

PLEASE TURN TO PAGE 175 FOR DISCUSSION

Mohammad Ali Mapar, MD; Amir Feily, MD; Mehdi Saboktakin, MD; Mohsen Azar-Beig, MD; Nepton Emad-Mostofi, MD; Maryam Saboktakin, MS

Drs. Mapar, Azar-Beig, and Emad-Mostofi are from Jundishapur University of Medical Sciences, Ahvaz, Iran. Drs. Mapar and Azar-Beig are from the Department of Dermatology, and Dr. Emad-Mostofi is from the Department of Pathology. Dr. Feily is from the Department of Dermatology, Jahrom University of Medical Sciences, Iran. Dr. Saboktakin and Ms. Saboktakin are from Shahrekord University of Medical Sciences, Iran. Dr. Saboktakin is from the Department of Dermatology and Ms. Saboktakin is from the Department of Nutrition.

The authors report no conflict of interest.

Correspondence: Amir Feily, MD (dr.feily@yahoo.com).

The Diagnosis: Extraocular Sebaceous Carcinoma

Sebaceous carcinoma (SC) of the skin is rare, especially extraocular SC. Although SC typically occurs on the eyelids, it can occur on any part of the body that contains sebaceous glands, including the skin, major salivary glands, larynx, or pharynx.¹ Sebaceous carcinoma, an unusual and aggressive malignant tumor derived from holocrine adnexal components of the skin, represents 0.2% of all skin cancers.^{2,3} Tumors may exhibit a variety of histologic growth patterns and different clinical presentations; therefore, diagnosis often is delayed for months to years.³ Despite the widespread anatomic distribution of sebaceous glands, extraocular SC is particularly rare, comprising approximately 25% of reported cases.⁴ Interestingly, the Asian population seems to experience a higher incidence of SC, with equal distribution among male and female patients and a mean age of 63 years at presentation.⁵

The diagnosis of SC often can be difficult, both clinically and histopathologically.⁶ The clinical appearance of extraocular SC is not distinctive; lesions usually are pink to red-yellow. Bleeding is reported in approximately one-third of patients⁵ and was observed in our patient (Figure 1).

The clinical differential diagnoses include pilomatrixoma, chalazion, nodular hidradenoma (eccrine acrospiroma), syringocystadenoma papilliferum, eccrine poroma and eccrine spiradenoma, and eccrine porocarcinoma.⁶ It also may occur in Muir-Torre syndrome, characterized by the occurrence of sebaceous tumors in association with visceral malignancies.⁷ Regardless of location, a sebaceous malignancy must be considered an aggressive neoplasm with the potential for regional and distant metastasis.³ Although extraocular SC is considered aggressive, it is associated with a far better prognosis than ocular localization.⁸ Some have argued against this contention, stating that tumor-related deaths from distant metastases are just as common in cases of extraocular SC.^{9,10}

Surgery with wide margins is the standard treatment of SC. In cases of regional lymph node or systemic metastasis, radiotherapy used alone or associated with neoadjuvant chemotherapy may limit morbidity.^{2,11} Histologically, SC usually demonstrates lobules and cords of tumor cells separated by a fibrovascular stroma, with various degrees of sebaceous differentiation demonstrated by vacuolated or foamy cytoplasm.⁶ The undifferentiated cells are moderate in size with round, centrally

placed nuclei and basophilic cytoplasm, and they tend to group in masses of a multilobular configuration. Mitotic figures, including atypical forms, are common.¹⁰

In our patient, samples from affected skin showed proliferation of irregular lobules of vacuolated or foamy cytoplasm cells separated by a fibrovascular stroma with various degrees of sebaceous differentiation. Marked nuclear polymorphism, moderate numbers of mitotic figures, and foci of necrosis were identified (Figure 2). These changes were interpreted as an SC. The tumor was completely excised under local anesthesia with 6-mm

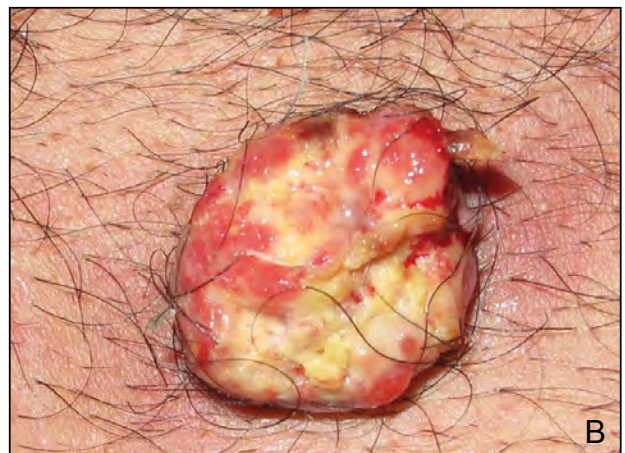
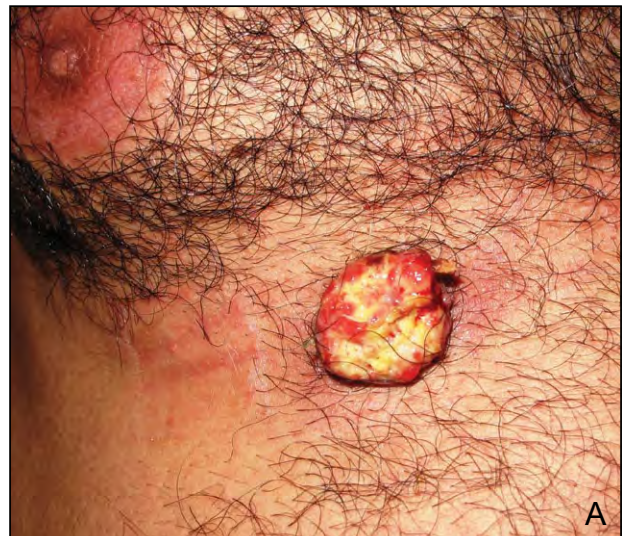
Figure 1. A firm, ulcerated, yellow to red, dome-shaped, nodular mass overlying the chest below the right nipple, measuring 2.5 cm in diameter (A and B).

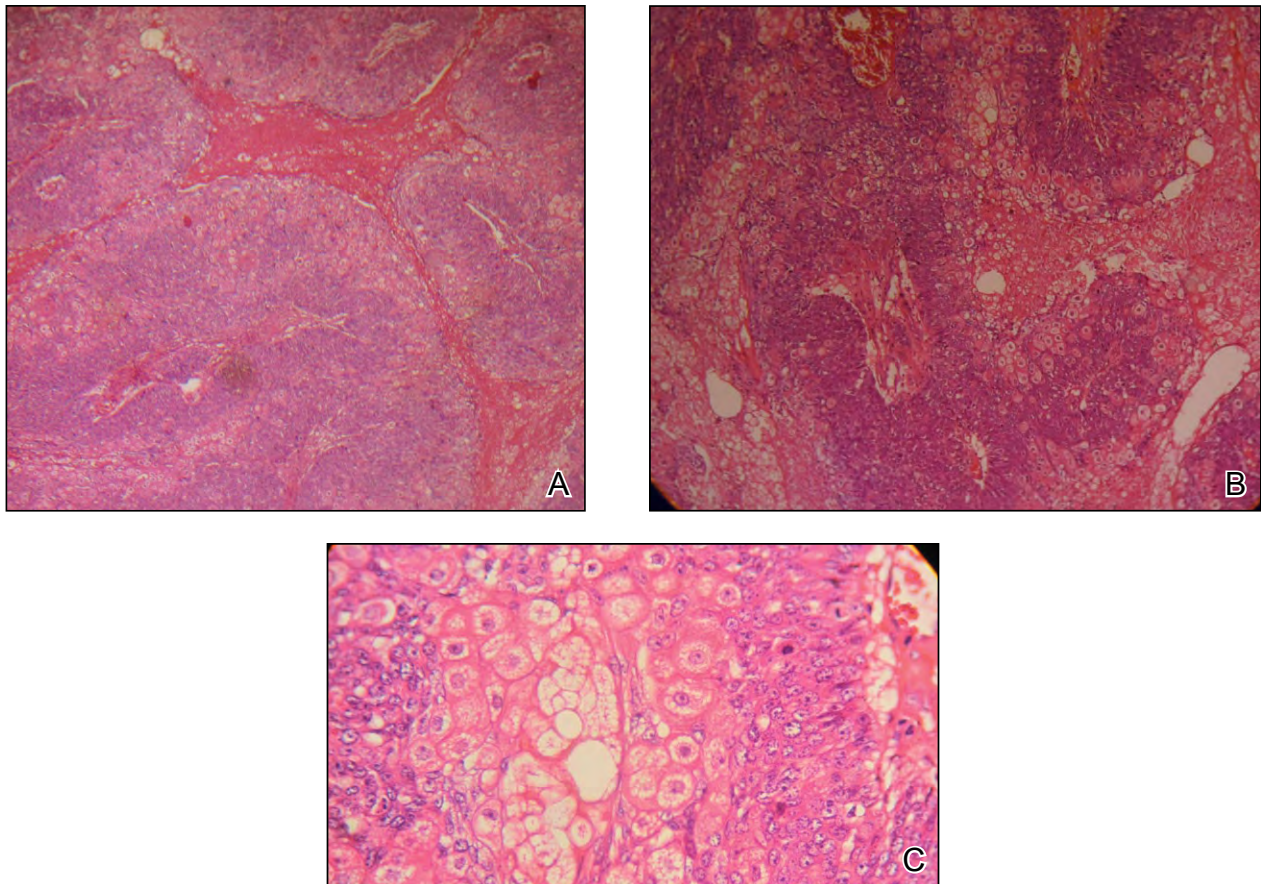


Figure 2. Histologic examination showed proliferation of irregular lobules of vacuolated or foamy cytoplasm cells separated by a fibrovascular stroma with various degrees of sebaceous differentiation. Marked nuclear polymorphism, moderate numbers of mitotic figures, and foci of necrosis were identified (A, B, and C)(H&E; original magnifications $\times 10$, $\times 20$, and $\times 40$, respectively).

margins. The surgical defect was reconstructed using a simple suture. There was no evidence of recurrence or metastasis after a 6-month follow-up period. Magnetic resonance imaging did not reveal any evidence suggestive of a visceral carcinoma.

REFERENCES

1. de Giorgi V, Massi D, Brunasso G, et al. Sebaceous carcinoma arising from nevus sebaceus: a case report. *Dermatol Surg.* 2003;29:105-107.
2. Mebazaa A, Boussofara L, Trabelsi A, et al. Undifferentiated sebaceous carcinoma: an unusual childhood cancer. *Pediatr Dermatol.* 2007;24:501-504.
3. Innocenzi D, Balzani A, Lupi F, et al. Morpheaform extra-ocular sebaceous carcinoma. *J Surg Oncol.* 2005;92:344-346.
4. Ghosh SK, Bandyopadhyay D, Gupta S, et al. Rapidly growing extraocular sebaceous carcinoma occurring during pregnancy: a case report. *Dermatol Online J.* 2008;14:8.
5. Nelson BR, Hamlet KR, Gillard M, et al. Sebaceous carcinoma. *J Am Acad Dermatol.* 1995;33:1-15; quiz 16-18.
6. Callahan EF, Appert DL, Roenigk RK, et al. Sebaceous carcinoma of the eyelid: a review of 14 cases. *Dermatol Surg.* 2004;30:1164-1168.
7. Graham RM, McKee PH, McGibbon D. Sebaceous carcinoma. *Clin Exp Dermatol.* 1984;9:466-471.
8. Audisio RA, Lodeville D, Quagliuolo V, et al. Sebaceous carcinoma arising from the eyelid and from extraocular sites. *Tumori.* 1987;73:531-535.
9. Moreno C, Jacyk WK, Judd MJ, et al. Highly aggressive extraocular sebaceous carcinoma. *Am J Dermatopathol.* 2001;23:450-455.
10. Hernández-Pérez E, Baños E. Sebaceous carcinoma. report of two cases with metastasis. *Dermatologica.* 1978;156:184-188.
11. Shields JA, Demirci H, Marr BP, et al. Sebaceous carcinoma of the ocular region: a review. *Surv Ophthalmol.* 2005;50:103-122.