

# Kartagener Syndrome With Focal Segmental Glomerulosclerosis

Ali Momeni,<sup>1</sup> Behzad Doroushi,<sup>2</sup> Nadia Taheri<sup>3</sup>

<sup>1</sup>Division of Nephrology,  
Department of Internal  
Medicine, Shahrekord  
University of Medical Sciences,  
Shahrekord, Iran

<sup>2</sup>Division of Rheumatology,  
Department of Internal  
Medicine, Shahrekord  
University of Medical Sciences,  
Shahrekord, Iran

<sup>3</sup>Department of Pathology,  
Isfahan University of Medical  
Sciences, Isfahan, Iran

**Keywords.** Kartagener  
syndrome, focal segmental  
glomerulosclerosis, hematuria

Primary ciliary dyskinesia is characterized by congenital impairment of mucociliary clearance. Kartagener syndrome (KS) is a clinical variant of primary ciliary dyskinesia which is involved in situs inversus associated with chronic respiratory infections. In addition, glomerular disease in KS syndrome is rare and reported cases are limited. We had a 27-year-old female patient with KS who presented with proteinuria, hematuria, normal kidney function, and a family history of systemic lupus erythematosus. Kidney biopsy showed segmental scar with adhesion to Bowman capsule, which was indicative of focal segmental glomerulosclerosis.

IJKD 2013;7:499-501  
[www.ijkd.org](http://www.ijkd.org)

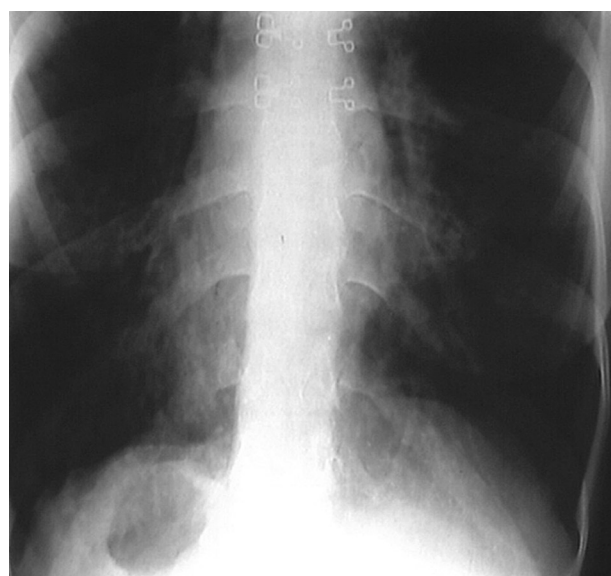
## INTRODUCTION

Primary ciliary dyskinesia, a genetic disorder, is characterized by congenital impairment of mucociliary clearance.<sup>1,2</sup> Kartagener syndrome (KS) is a clinical variant of primary ciliary dyskinesia, which is involved in situs inversus associated with chronic respiratory infections.<sup>3,4</sup> The prevalence of KS is about 1 in 20 000 to 40 000 births.<sup>5</sup> Clinical manifestations of KS may include chronic cough, chronic rhinitis, and chronic sinusitis. In addition, in high-resolution computed tomography, almost all of the adults and half of the children may have bronchiectasis.<sup>6</sup> Glomerular disease in KS syndrome is rare and reported cases are limited. To our knowledge, there is no relationship between KS and focal segmental glomerulosclerosis (FSGS). We report a case of KS with glomerular hematuria, proteinuria, and FSGS.

## CASE REPORT

A 27-year-old woman, a known case of KS, was referred to the nephrology clinic for evaluation of microscopic hematuria, in February 2012. She had a history of frequent admissions due to pulmonary infection. There was also a family history of systemic lupus erythematosus in her sister. In previous

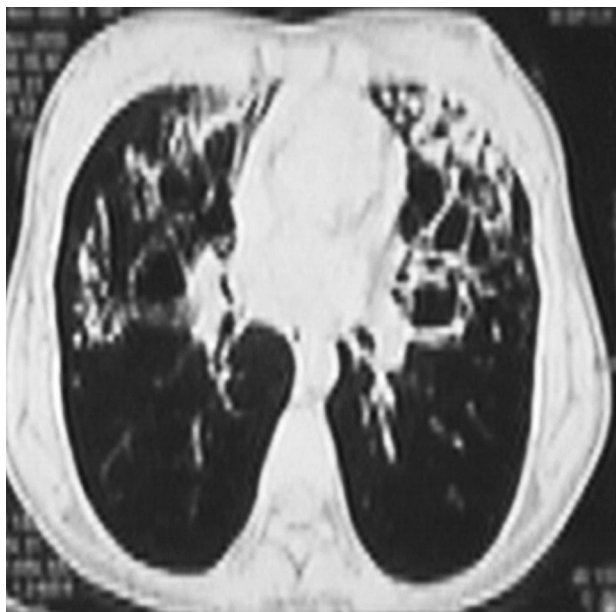
evaluation, microscopic hematuria and proteinuria had been found. She was cachectic with a body weight of 43 kg and a body mass index of 17.7 kg/m<sup>2</sup>. On physical examination, the heart sound was heard in the right hemithorax with a loud P2 (Figure 1). Furthermore, coarse crackle was found bilateral with more severity in the basal area of



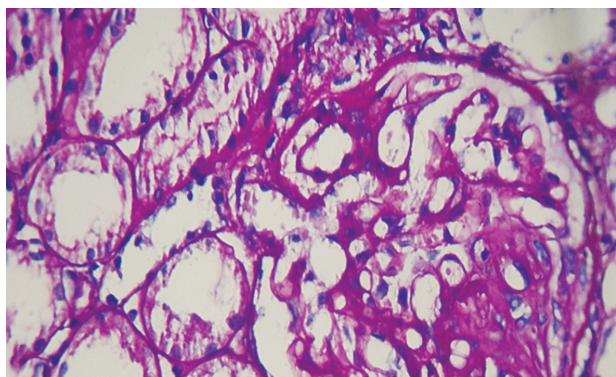
**Figure 1.** Chest radiography of the patient shows dextrocardia and gastric air in the right subdiaphragm.

the lungs (Figure 2). There was also peripheral cyanosis and clubbing of the digits.

Laboratory data of the patients are summarized in the Table. Serology tests were negative for hepatitis B surface antigen, hepatitis C virus antibody, and human immunodeficiency virus antibody. Urinalysis revealed blood (1+) in urine (erythrocyte, 10 to 12 per high-power field), a leukocyte count of 1 to 2 per high-power field, and protein (1+). Moreover, urinary sediment showed glomerular hematuria with dysmorphic erythrocytes, acanthocyte, and erythrocyte cast. The 24-hour urine collection showed 520 mg protein excretion. For evaluation of proteinuria and glomerular hematuria, serologic study was done (Table).



**Figure 2.** Chest computed tomography scan of the patient shows bilateral bronchiectasis.



**Figure 3.** One glomerulus shows a sclerotic segment with adhesion to the Bowman capsule (periodic acid–Schiff, × 400).

Laboratory Data of the Patient

Parameter	Value
Blood urea nitrogen, mg/dL	7
Serum creatinine, mg/dL	0.7
24-hour urine protein, mg	520
Serum uric acid, mg/dL	4
Complement C3, mg/L	120
Complement C4, mg/L	130
Complement CH50, mg/L	110
Alanine aminotransferase, U/L	22
Aspartat aminotransferase, U/L	23
Antinuclear antibody, U/mL	16
Anti-double stranded DNA, U/mL	1.5
Anti RO, U/mL	4

Kidney biopsy was done, and light microscopy evaluation in 24 glomeruli showed that one of the glomeruli was globally sclerotic and two of them showed segmental scar with adhesion to the Bowman capsule, and the remaining glomeruli had mildly increased mesangial cellularity (Figure 3). The interstitium showed focal trivial fibrosis (< 5%) with patchy trivial mononuclear inflammatory cells infiltration, and in tubules, there were focal trivial atrophy and some showed mild dilatation. Small and medium-sized arteries were normal. Immunofluorescent studies performed on frozen sections with two glomeruli revealed no significant staining with immunoglobulin (Ig) G, IgA, and IgM; complements C3, C4, and C1q; and fibrinogen. In addition, the light and immunofluorescent microscopic findings were diagnostic for FSGS.

The patient was started on treatment with losartan, 25 mg twice per day, a bronchodilator, and an antibiotic during the respiratory infection.

## DISCUSSION

One of the most common primary glomerulonephritis in adults is FSGS.<sup>7</sup> We reported a rare case of KS with glomerulopathy consistent with FSGS. Chronic hypoxia is mentioned as a cause of secondary FSGS. Also cyanotic heart disease may be relationship with FSGS as reported by Flanagan,<sup>8</sup> the probable cause of which could be hyperfiltration of the glomerulus.

Duration of cyanosis may be associated with initiation and severity of glomerulopathy in the patients with cyanotic heart disease, but not with a linear correlation.<sup>9</sup> Hida and colleagues reported a case of congenital heart disease with FSGS.<sup>10</sup> A case of KS and polycystic kidney disease was

reported by Sayarlioglu and colleagues.<sup>11</sup> A case of KS and renal cell carcinoma was also reported by Treiger and coworkers.<sup>12</sup> Krishnamurthy and colleagues reported a 11-year-old girl with acute glomerulonephritis in the form of mesangioproliferative glomerulonephritis.<sup>13</sup> To our knowledge, this is the first time of report of association of KS and FSGS. In our case, other causes of secondary FSGS, such as severe obesity, viral hepatitis, human immunodeficiency virus infection were not considered, and glomerulopathy may be due to chronic hypoxia or primary FSGS.

### CONFLICT OF INTEREST

None declared.

### REFERENCES

- Geremek M, Schoenmaker F, Zietkiewicz E, et al. Sequence analysis of 21 genes located in the Kartagener syndrome linkage region on chromosome 15q. *Eur J Hum Genet.* 2008;16:688-95.
- Guichard C, Harricane MC, Lafitte JJ, et al. Axonemal dynein intermediate-chain gene (DNAI1) mutations result in situs inversus and primary ciliary dyskinesia (Kartagener syndrome). *Am J Hum Genet.* 2001;68:1030-5.
- Bush A, Cole P, Hariri M, et al. Primary ciliary dyskinesia: diagnosis and standards of care. *Eur Respir J.* 1998;12:982-8.
- Zariwala MA, Knowles MR, Omran H. Genetic defects in ciliary structure and function. *Annu Rev Physiol.* 2007;69:423-50.
- Afzelius BA, Stenram U. Prevalence and genetics of immotile-cilia syndrome and left-handedness. *Int J Dev Biol.* 2006;50:571-3.
- Kennedy MP, Noone PG, Leigh MW, et al. High-resolution CT of patients with primary ciliary dyskinesia. *AJR Am J Roentgenol.* 2007;188:1232-8.
- Monfared A, Khosravi M, Lebad M, et al. Distribution of renal histopathology in Guilan: a single-center report. *Iran J Kidney Dis.* 2012;6:173-7.
- Flanagan MF, Hourihan M, Keane JF. Incidence of renal dysfunction in adults with cyanotic congenital heart disease. *Am J Cardiol.* 1991;68:403-6.
- Perloff JK. Congenital heart disease in adults. A new cardiovascular subspecialty. *Circulation.* 1991;84:1881-90.
- Hida K, Wada J, Yamasaki H, et al. Cyanotic congenital heart disease associated with glomerulomegaly and focal segmental glomerulosclerosis: remission of nephrotic syndrome with angiotensin converting enzyme inhibitor. *Nephrol Dial Transplant.* 2002;17.
- Sayarlioglu H EDC, Dogan E, Sayarlioglu M, Koksall N. Kartagener's syndrome and polycystic kidney disease. *Clin Kid Jour.* 2009;2:189-90.
- Treiger BF, Khazan R, Goldman SM, Marshall FF. Renal cell carcinoma with situs inversus totalis. *Urology.* 1993;41:455-7.
- Krishnamurthy S, Choudhary B, Rajesh NG, Ramesh A, Srinivasan S. Kartagener syndrome associated with mesangioproliferative glomerulonephritis. *Paediatr Int Child Health.* 2012;32:116-8.

Correspondence to:

Ali Momeni, MD

Division of Nephrology, Department of Internal Medicine, Shahrekord University of Medical Sciences, Shahrekord, Iran  
E-mail: ali.momeni@yahoo.com

Received August 2012

Revised February 2013

Accepted February 2013