

Protective Effects of Hydroalcoholic Extract of *Ferulago Angulata* Against Gentamicin-induced Nephrotoxicity in Rats

Parisa Valipour,¹ Esfandiar Heidarian,² Abolfazl Khoshdel,³
Mostafa Gholami-Arjenaki⁴

¹Student's Research Committee, Shahrekord University of Medical Sciences, Shahrekord, Iran

²Clinical Biochemistry Research Center, Shahrekord University of Medical Sciences, Shahrekord, Iran

³Cellular and Molecular Research Center, Shahrekord University of Medical Sciences, Shahrekord, Iran

⁴Medical Plants Research Center, Shahrekord University of Medical Sciences, Shahrekord, Iran

Keywords. *Ferulago angulata*, gentamicin, nephrotoxicity, oxidative stress, kidney failure

Introduction. Gentamicin can lead to acute tubular injury and kidney dysfunction. This study aimed to evaluate the effect of *Ferulago angulata* on kidney function and other markers in rats with gentamicin-induced nephrotoxicity.

Materials and Methods. Forty-eight male Wistar rats were divided into the following groups: group 1, the controls; group 2, rats receiving gentamicin (120 mg/kg body weight per day, intraperitoneal) for 7 days without treatment; groups 3, 4 and 5, rats receiving gentamicin for 7 days and oral treatment with 200 mg/kg, 400 mg/kg, and 800 mg/kg body weight per day of *Ferulago angulata* extract, respectively. Measurements included serum levels of creatinine, urea, uric acid, lipids, ferric-reducing antioxidant power, and protein carbonyl; kidney and serum levels of malondialdehyde; and serum and renal levels of tumor necrosis factor- α . Histopathology of kidney tissue was examined as well as renal catalase, superoxide dismutase, and vitamin C.

Results. Compared to treatment with gentamicin only, treatment with *Ferulago angulata* resulted in a significantly higher high-density lipoprotein cholesterol, ferric-reducing antioxidant plasma, renal catalase, superoxide dismutase, and vitamin C levels. It was also associated with significantly lower serum levels of creatinine, urea, uric acid, malondialdehyde, protein carbonyl, tumor necrosis factor- α , total cholesterol, triglyceride, low-density lipoprotein cholesterol, and very low-density lipoprotein cholesterol. *Ferulago angulata* was linked with a lower renal gene expression of tumor necrosis factor- α .

Conclusions. The present study suggests that *Ferulago angulata* extract has protective effects against nephrotoxicity due to gentamicin.

IJKD 2016;10:189-96
www.ijkd.org

INTRODUCTION

Several drugs and toxic xenobiotics or chemicals cause toxic damage to the kidneys. Gentamicin is widely used in the treatment of gram-negative bacterial infections.^{1,2} Most studies have shown that excessive dose of gentamicin can lead to acute tubular injury and kidney dysfunction,³ due to its accumulation in the renal proximal convoluted tubules and its accumulation, resulting in brush

border network injury, decreased glomerular filtration rate, and kidney dysfunction.⁴ Several studies have demonstrated that gentamicin induces dose-dependent nephrotoxicity in 10% to 25% of the recipients. Treatment with gentamicin has been identified as one of the most common causes of acute kidney failure, which leads to restriction of its use.^{5,6} In addition, gentamicin stimulates formation of reactive oxygen species (ROS) in the

kidney and causes renal oxidative stress, renal inflammation, elevation of the lipid peroxidation, and the activity reduction of antioxidant enzymes.⁷⁻¹⁰ Therefore, a therapeutic approach to protect or reverse gentamicin-induced renal injury would have significant clinical value.

Nowadays, herbal medicine development against the noncommunicable disease is one of the reliable areas of research for finding natural compounds with renal protective effects.¹¹ *Ferulago angulate* (*F. angulate*) is found in high altitude areas of several Asian countries such as Iran, Iraq, and Turkey. Previous studies have demonstrated antioxidant, anti-inflammatory, and antimicrobial properties of this plant.¹² Therefore, this study was undertaken for evaluating the effect of *F. angulata* extract against gentamicin-induced renal toxicity in rats.

MATERIALS AND METHODS

Chemicals and Reagents

The SYBR Green polymerase chain reaction master mix was prepared from Qiagen (Düsseldorf, Germany). Plasma levels of total cholesterol, triglyceride, high-density lipoprotein cholesterol (HDL), low-density lipoprotein cholesterol (LDL), creatinine, urea, glutamate-oxaloacetate transaminase, and glutamate-pyruvate transaminase were measured using Pars Azmun (Tehran, Iran). Gentamicin was purchased from Darugostar (Tehran, Iran). All other chemicals used were of analytical grade.

Plant Material and Extraction

F. angulata was collected from Shahrekord, Chaharmahal-e-Bakhtiari Province, Iran (altitude 2035 m, 32°19'31"N-50°51'50"E) in March 2014. The botanical identification was done at the Herbarium of the Medical Plants Research Center in Shahrekord University of Medical Sciences, Iran, and a voucher specimen was deposited (Voucher No 324). Then, *F. angulata* was air-dried and ground, and the ethanol:water (70:30, v/v) extract was prepared.

Total Phenol and Antioxidant Capacity

The total phenols and antioxidant activity of *F. angulata* extract were determined as described elsewhere.^{13,14}

Animals and Experimental Design

Forty-eight male Wistar rats (weight, 200 ± 20 g)

were housed under standard laboratory conditions. The rats were randomly divided into 5 experimental groups (n = 8 per group) as follows: group 1 (control) was treated with intraperitoneal injection of normal saline daily for 7 consecutive days; group 2 (gentamicin) received daily intraperitoneal injection of gentamicin (120 mg/kg body weight) for 7 consecutive days; groups 3 to 5 were orally treated with *F. angulata* extract (200 mg/kg, 400 mg/kg, and 800 mg/kg body weight, respectively) and intraperitoneal injection of gentamicin (120 mg/kg body weight) at an interval of 1 hour for 7 days, consecutively.

After 7 consecutive days, fasted animals were anesthetized and plasma and serum specimens were prepared. Also, a specimen of the kidney was removed for determining kidney catalase activity, tumor necrosis factor- α (TNF- α) gene expression, and histopathological studies. All procedures were approved by the Ethics Committee of Shahrekord University of Medical Sciences.

Biochemical Analysis

The profile of serum lipids, creatinine, urea, glutamate-oxaloacetate transaminase, and glutamate-pyruvate transaminase levels were determined by enzymatic method (Pars Azmun, Iran) using autoanalyzer (BT 3000, France). Serum tumor necrosis factor- α (TNF- α) was assessed using an enzyme-linked immunosorbent assay (BT-Laboratory, China) according to the manufacturers' instructions. Very low-density lipoprotein cholesterol (VLDL) was calculated with Friedewald formula.¹⁵

Serum and Renal Tissue Malondialdehyde

Serum and renal tissue malondialdehyde levels were assessed using high-performance liquid chromatography (Agilent, USA) method with thiobarbituric acid as described by Agarwal and Chase.¹⁶

Ferric-reducing Ability of Plasma

Plasma antioxidant capacity was measured as described previously.¹⁷

Renal Catalase and Superoxide Dismutase Activity

The kidney catalase activity of experimental groups was estimated as described previously.¹⁸ Kidney superoxide dismutase (SOD) activity of

different experimental groups was assayed by method of Beauchamp and Fridivich.¹⁹

Renal Tissue Vitamin C

Kidney tissue vitamin C level in the experimental groups were measured by 2,4-dinitrophenyl hydrazine reagent as described by Omaye.²⁰

Serum Protein Carbonyl Content

Protein carbonyl content of the serum was assayed by Reznick and Packer²¹ procedure using 6 M guanidine hydrochloride.

Real-time Quantitative Polymerase Chain Reaction for Tumor Necrosis Factor- α

Total mRNA (100 mg kidney tissue of each rat) was extracted using a commercial Biozol kit (Bioer, China) reagent. Reverse transcription of cDNA was done using PrimeScript reagent kit (Takara Bio Inc). Then, cDNA amplified by real-time quantitative polymerase chain reaction using SYBR Green PCR Master Mix (Qiagen, Germany) in the presence of specific primers for *TNF- α* (forward: 5'-CTGGCGTGTTCATCCGTTTC-3', reverse: 5' GGCTCTGAGGAGTAGACGATAA -3') and *18s* (forward: 5'CGCAAATTACCCACTCCCGAC-3', reverse: 5'GCGTTTAATGGGTGAGGGCTG-3') genes. Amplification involved a first denaturation at 95°C for 10 minutes and real-time quantitative polymerase chain reaction was done for 40 cycles in a 3-step program (including 15 seconds at 95°C, 20 seconds at 62°C, and 25 seconds at 72°C). A housekeeping gene, *18s* rRNA, was used as an endogenous control for mRNA expression and normalizing data.

Histopathological Studies

Immediately after sacrificing the rats, the kidneys were dissected out and fixed in 20% formaldehyde solution. After paraffin embedding, 5- μ m sections were taken and stained with hematoxylin-eosin²² for photomicroscopic observation, including inflammatory activity and stage of damage.

Statistical Analysis

The results were expressed as mean \pm standard deviation. All statistical analyses were performed using the 1-way analysis of variance. The SPSS software (Statistical Package for the Social Sciences, version 20.0, SPSS Inc, Chicago, IL, USA) was used for the analyses. Mean values of the groups were compared using the Tukey post hoc test for multiple comparisons. A *P* value less than .05 was considered significant.

RESULTS

Total Phenol and Antioxidant Capacity of *Ferulago Angulata*

The total phenolic content of *F. angulata* extract was 4.2 ± 0.13 mg of gallic acid equivalent/g dried extract. The antioxidant activity of *F. angulata* extract was 18.46 ± 1.32 μ g/mL.

Effect of *Ferulago Angulata* on Biochemical Parameters

In group 2 (gentamicin administered without treatment), serum levels of total cholesterol, LDLC, VLDLC, triglyceride, uric acid, urea, and creatinine significantly increased compared to those in the control group (Table 1). In treated groups with *F. angulata*, total cholesterol, LDLC,

Table 1. Laboratory Parameters in Rats Receiving Gentamicin With and Without *Ferulago Angulata* Extract*

Parameters	Group 1	Group 2	Group 3	Group 4	Group 5
Triglyceride, mg/dL	60.00 \pm 4.20	104.37 \pm 9.10 [†]	69.75 \pm 5.14 ^{†‡}	61.37 \pm 5.90 [‡]	51.12 \pm 4.76 ^{†\$#}
Total cholesterol, mg/dL	57.62 \pm 3.33	91.00 \pm 5.34 [†]	74.37 \pm 5.15 ^{†‡}	71.12 \pm 4.29 ^{†‡}	58.12 \pm 1.35 ^{†\$#}
High-density lipoprotein, mg/dL	35.33 \pm 1.90	29.03 \pm 1.28 [†]	28.42 \pm 1.82 [†]	29.57 \pm 1.88 [†]	33.93 \pm 2.16 ^{†\$#}
Low-density lipoprotein, mg/dL	15.05 \pm 0.91	24.78 \pm 1.25 [†]	20.82 \pm 1.21 ^{†‡}	19.00 \pm 0.60 ^{†‡}	15.75 \pm 0.84 ^{†\$#}
Very low-density lipoprotein, mg/dL	10.82 \pm 1.58	38.89 \pm 5.93 [†]	26.24 \pm 4.58 ^{†‡}	24.39 \pm 3.38 ^{†‡}	11.76 \pm 1.36 ^{†\$#}
Uric acid, mg/dL	1.48 \pm 0.11	3.70 \pm 0.37 [†]	2.77 \pm 0.16 ^{†‡}	2.05 \pm 0.16 ^{†‡\$}	1.82 \pm 0.12 ^{†\$}
Urea, mg/dL	49.75 \pm 3.45	130.75 \pm 7.42 [†]	86.87 \pm 4.64 ^{†‡}	80.37 \pm 6.45 ^{†‡}	69.75 \pm 3.84 ^{†‡\$#}
Creatinine, mg/dL	0.47 \pm 0.08	2.78 \pm 0.42 [†]	2.25 \pm 0.25 [†]	1.82 \pm 0.23 ^{†‡}	1.65 \pm 0.17 ^{†‡\$}

*Group 1 was the control; group 2, receiving gentamicin; and groups 3 to 5, rats receiving gentamicin and *F. angulata* extract at the doses of 200 mg/kg, 400 mg/kg, and 800 mg/kg, respectively.

[†]*P* < .05 compared with group 1

[‡]*P* < .05 compared with group 2

^{\$}*P* < .05 compared with group 3

[#]*P* < .05 compared with group 4

VLDLC, triglyceride, uric acid, and urea showed a significant reduction compared to those in group 2. A reduction of serum HDLC was seen in group 2 compared to the control group.

Effect of *Ferulago Angulata* on Renal Catalase Activity, Superoxide Dismutase, and Vitamin C

The kidney tissue of the gentamicin-intoxicated rats without treatment showed a significant decrease in the tissue vitamin C, activity of catalase, and SOD when compared with the control group (Figures 1 and 2). In groups receiving *F angulata*; however, a significant elevation of catalase activity in renal tissue of gentamicin-intoxicated rats when compared with group 2, in a dose-dependent manner. On the

other hand, in groups 4 and 5 (400 mg/kg and 800 mg/kg of *F angulata* extract, respectively), SOD and vitamin C were significantly elevated compared to those in groups 2 and 3.

Serum Level of Protein Carbonyl

Figure 2 shows that administration of gentamicin resulted in a significant elevation in the level of the serum protein carbonyl content in group 2 compared to that of group 1 (control). In groups 4 and 5 (400 mg/kg and 800 mg/kg of *F angulata*, respectively), the serum level of protein carbonyl significantly decreased compared to that of group 2 in a dose-dependent manner.

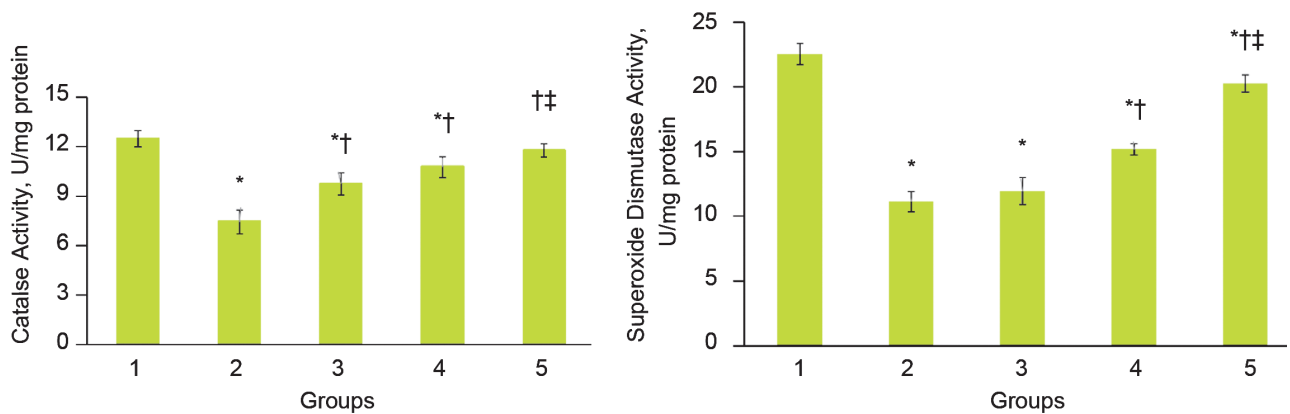


Figure 1. Effect of *Ferulago angulata* extract on catalase and superoxide dismutase activities. Group 1 is the controls; group 2, receiving gentamicin; and groups 3 to 5, rats receiving gentamicin and *F angulata* extract at the doses of 200 mg/kg, 400 mg/kg, and 800 mg/kg, respectively.

* $P < .05$ compared with group 1
 † $P < .05$ compared with group 2
 ‡ $P < .05$ compared with group 3

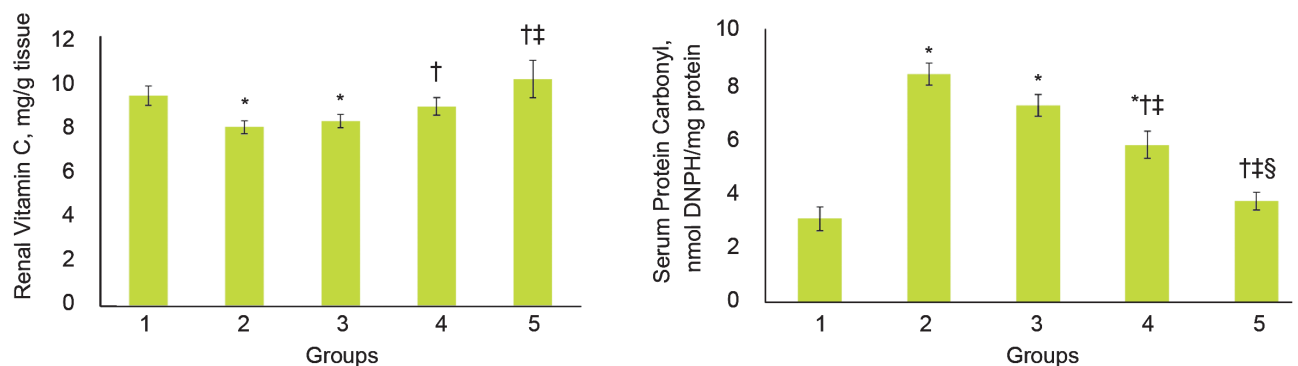


Figure 2. Effect of *Ferulago angulata* extract on serum protein carbonyl and renal vitamin C. Group 1 is the controls; group 2, receiving gentamicin; and groups 3 to 5, rats receiving gentamicin and *F angulata* extract at the doses of 200 mg/kg, 400 mg/kg, and 800 mg/kg, respectively.

* $P < .05$ compared with group 1
 † $P < .05$ compared with group 2
 ‡ $P < .05$ compared with group 3
 § $P < .05$ compared with group 4

Effect of *Ferulago Angulata* on Malondialdehyde and Ferric-reducing Ability of Plasma

Table 2 shows that in group 2, gentamicin resulted in a significant increase in serum and renal malondialdehyde levels compared to the control group. Animals treated with the extract of *F. angulata* showed a significant decrease in the serum and tissue malondialdehyde levels in a dose-dependent manner compared to those in group 2. In the treated groups with *F. angulata*, a significant elevation was seen in the ferric-reducing ability of plasma as opposed to that in group 2, in a dose-dependent manner.

Effect of *Ferulago Angulata* on Tumor Necrosis Factor- α and Relative Expression of Renal *TNF- α*

Figure 3 shows that gentamicin administration in group 2 led to a significant elevation in serum level of *TNF- α* and renal expression of *TNF- α* compared to the control group. The level of the

serum *TNF- α* decreased significantly in groups treated with *F. angulata* extract compared to group 2. Relative expression of renal *TNF- α* was also significantly reduced in *F. angulata* treated groups in contrast to that in group 2.

Histopathological Examination

Light microscopic examination of the kidney tissue in group 2 displayed infiltration of mononuclear cells, hemorrhage, and histological changes compared to the control group (Figure 4). Renal sections from both groups treated with *F. angulata* extract at doses of 200 mg/kg and 400 mg/kg along with gentamicin showed moderate tubular degeneration and mild infiltration of inflammatory cells (Figure 4). Administration of *F. angulata* extract at a dose of 800 mg/kg markedly decreased the level of degeneration changes (Figure 4) compared to that in group 2.

DISCUSSION

Nowadays, medicinal plants play an important

Table 2. Serum and Tissue Renal Malondialdehyde and Serum Ferric-reducing Ability of Plasma (FRAP) in Rats Receiving Gentamicin With and Without *Ferulago Angulata* Extract*

Parameters	Group 1	Group 2	Group 3	Group 4	Group 5
Serum FRAP, μM	299.75 \pm 18.43	129.87 \pm 14.83 [†]	211.50 \pm 24.01 ^{†‡}	289.00 \pm 28.54 [‡]	356.87 \pm 30.31 ^{†‡\$#}
Serum malondialdehyde, μM	0.87 \pm 0.11	4.14 \pm 0.41 [†]	1.84 \pm 0.13 ^{†‡}	1.62 \pm 0.19 ^{†‡}	0.92 \pm 0.05 ^{†\$#}
Tissue malondialdehyde, μM	0.42 \pm 0.08	1.50 \pm 0.20 [†]	0.66 \pm 0.15 ^{†‡}	0.38 \pm 0.01 ^{‡\$}	0.37 \pm 0.04 ^{‡\$}

*Group 1 is the controls; group 2, receiving gentamicin; and groups 3 to 5, rats receiving gentamicin and *F. angulata* extract at the doses of 200 mg/kg, 400 mg/kg, and 800 mg/kg, respectively.

[†] $P < .05$ compared with group 1

[‡] $P < .05$ compared with group 2

^{\$} $P < .05$ compared with group 3

[#] $P < .05$ compared with group 4

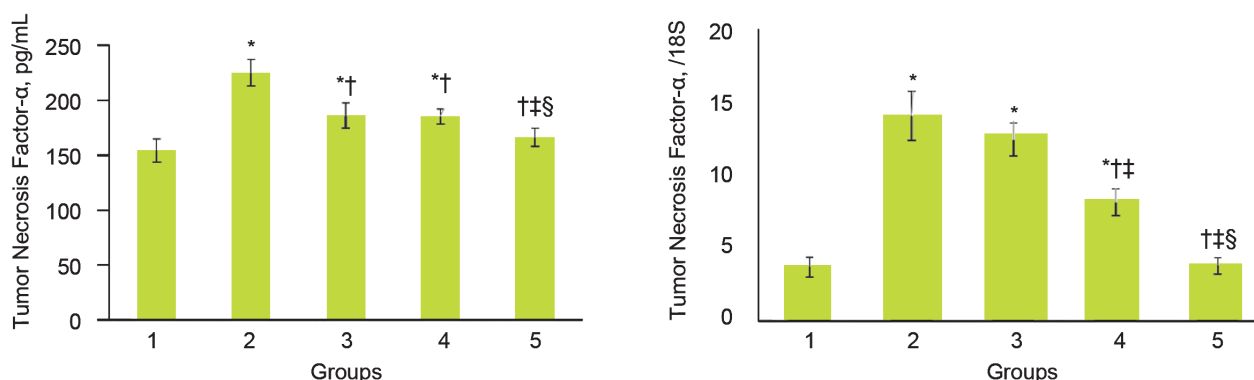


Figure 3. Effect of *Ferulago angulata* extract on serum level of tumor necrosis factor- α and the relative expression of renal *TNF- α* .

Group 1 is the controls; group 2, receiving gentamicin; and groups 3 to 5, rats receiving gentamicin and *F. angulata* extract at the doses of 200 mg/kg, 400 mg/kg, and 800 mg/kg, respectively.

* $P < .05$ compared with group 1

[†] $P < .05$ compared with group 2

[‡] $P < .05$ compared with group 3

^{\$} $P < .05$ compared with group 4

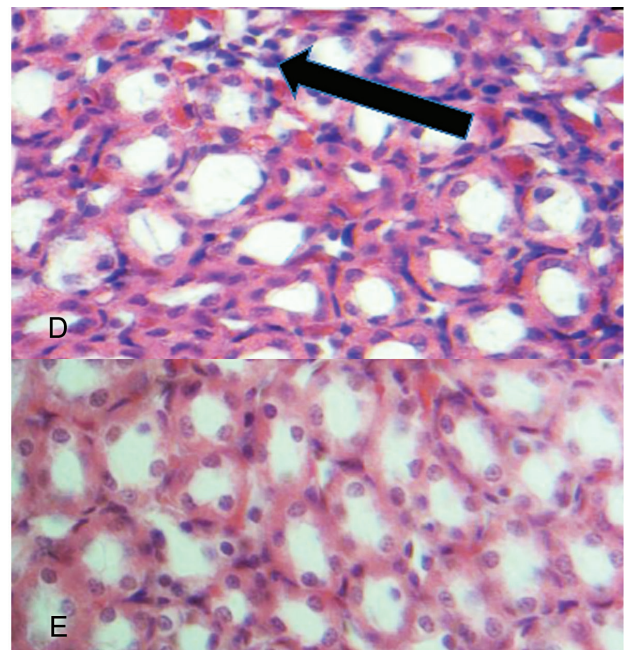
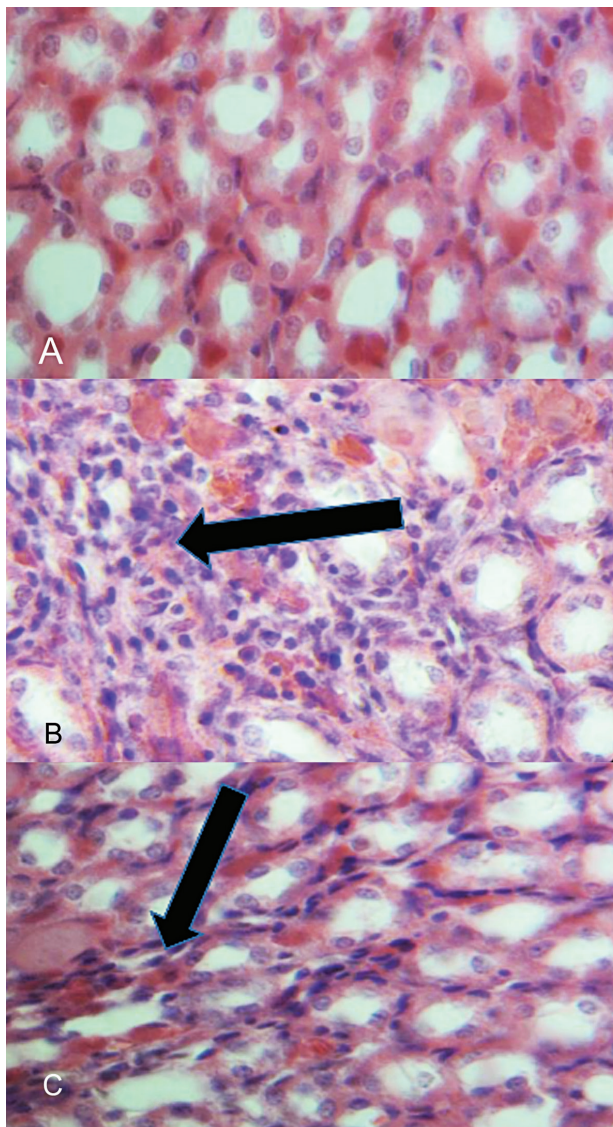


Figure 4. Effect of *Ferulago angulata* extract on pathological changes in the renal tubules of the experimental groups. A, Control group (group 1); B, gentamicin-administered rats without treatment (group 2); C, D, and E (groups 3 to 5) gentamicin-administered rats supplemented with 200 mg/kg, 400 mg/kg, and 800 mg/kg body weight of the extract of *F. angulata* extract, respectively. The kidney of the gentamicin-administered rat developed pathological changes in the tubules such as lymphocytic infiltration (arrow mark). Treatment with *F. angulata* extract markedly reduced these pathological changes of the tubular nephrons. The arrows show lymphocyte infiltration in tubules and degeneration in tubular wall.

role in the treatment and prevention of kidney diseases.²³ A few studies have been done on the importance of the therapeutic properties of *F. angulata*.¹² In our study, the serum triglyceride, total cholesterol, LDLC, and VLDL significantly increased in group 2 when compared to the control group of rats whereas the serum HDLC was found to be significantly decreased (Table 1), which is accordance with earlier reports.^{5,24} On the other hand, treatment with *F. angulata* decreased the profile of serum lipids when compared to group 2 of rats with gentamicin only (Table 1), whereas *F. angulata* led to considerable increase in HDLC levels in the treated groups. Several reports have demonstrated that natural agents can reduce hyperlipidemia, which are in agreement with our

results.^{25,26} In this study, *F. angulata* extract analysis showed a potent antioxidant property. Therefore, the reduction of the serum lipid levels resulted from the antioxidant property of *F. angulata* extract.

In our current study, the levels of urea, creatinine, and uric acid increased in gentamicin-treated rats, as a manifestation of kidney dysfunction, which is in accordance with previous findings.¹⁻²⁷ Treatment with *F. angulata* extract restored the elevated values of urea, creatinine, and uric acid near to normal levels (Table 1). On the other hand, this renal protective effects of *F. angulata* extract may be, at least in part, due to its stabilizing effects on plasma membrane and proteins against ROS.²⁸

There is growing evidence that in mammalian system, especially human, direct damage to

proteins and lipids during oxidative stress can give rise to the elevation of the protein carbonyl and malondialdehyde, respectively,^{29, 30} which is in line with our study (Table 2 and Figure 2). Nevertheless, administration of *F angulata* extract led to not only an elevation of ferric-reducing ability of plasma in the treated groups compared to group 2, but also a reduction of the serum malondialdehyde, protein carbonyl, and the kidney tissue malondialdehyde in a dose-dependent manner. These effects may be produced, at least in part, due to *F angulata* extract antioxidant properties. In our study, the administration of *F angulata* extract retarded the progression of functional and morphological changes in the kidney of the treated groups (Figure 4) compared to group 2, due to its antioxidant properties. Therefore, in our study, *F angulata* extract antioxidant activity may produce, at least in part, the renal protective effects by neutralizing the effects of free radical species.

The results of the present study demonstrated that administration of *F angulata* extract led to an elevation of vitamin C in the treated groups, compared to group 2. Thus, the elevation of vitamin C can be considered an additional reason for reducing ROS in *F angulata* extract-treated groups and retarded the renal progression of functional and morphological changes. The observations from our study are in line with previous reported studies.^{1, 31} Also, in the present study, the level of kidney tissue antioxidant enzymes such as catalase and SOD significantly decreased after receiving gentamicin in comparison with the control group. In the groups treated with *F angulata*, a significant increase was observed in the renal activity of catalase and SOD. Therefore, the elevation of renal catalase and SOD activities due to *F angulata* administration can be considered, at least in part, an additional reason for reducing renal structural pathological abnormalities, the serum malondialdehyde, the kidney tissue malondialdehyde, and protein carbonyl in groups treated with *F angulata*.

Several studies have demonstrated that gentamicin-induced nephrotoxicity is structurally associated with inflammation and considerably increasing TNF- α ,^{8, 32} which is in line with the present study. Our results showed a significant elevation in both the serum level and relative renal expression of TNF- α associated with gentamicin use. Activation and nuclear translocation of TNF- α

can be a key factor in the renal inflammatory process due to oxidative stress, which in turn, is involved in regulating basal gene expression of cytokines, chemokines, and adhesion molecules.³³ However, in our study, treatment with the extract of *F angulata* significantly decreased serum level of TNF- α . The results also indicated that TNF- α was significantly downregulated following *F angulata* treatment, which is in accordance with earlier studies.^{1, 34} Thus, the reduction of serum level of TNF- α and TNF- α expression are another piece of evidence confirming the renal protective effect of *F angulata* extract.

In this study, we did not evaluate the effect of *F angulata* extract on renal tubular apoptosis/necrosis, pro-apoptotic characters such as p53, or downregulation of the activities of some anti-apoptotic proteins such as Bcl-2. These factors can influence cell apoptosis and survival. Therefore, we suggest that future studies focus on the anti-apoptosis effects of *F angulata* extract.

CONCLUSIONS

Our finding indicate that *F angulata* extract has renal protective potential. The nephroprotective effects of *F angulata* extract against gentamicin-induced renal toxicity may be due to its antioxidant properties on the reduction of the renal TNF- α expression, kidney malondialdehyde, and protein carbonyl plus the elevation of renal catalase and SOD activities.

ACKNOWLEDGMENTS

We would like to express our gratitude to those who have helped us in Clinical Biochemistry Research Center of Shahrekord University of Medical Sciences.

CONFLICT OF INTEREST

None declared.

REFERENCES

1. Sahu BD, Tatireddy S, Koneru M, et al. Naringin ameliorates gentamicin-induced nephrotoxicity and associated mitochondrial dysfunction, apoptosis and inflammation in rats: possible mechanism of nephroprotection. *Toxicol Appl Pharmacol*. 2014;277:8-20.
2. Pazhayattil GS, Shirali AC. Drug-induced impairment of renal function. *Int J Nephrol Renovasc Dis*. 2014;7:457-68.
3. Moreira MA, Nascimento MA, Bozzo TA, et al. Ascorbic acid reduces gentamicin-induced nephrotoxicity in rats

- through the control of reactive oxygen species. *Clin Nutr*. 2014;33:296-301.
4. Derakhshanfar A, Sadeghian MH, Abbasabadi N, et al. Histopathologic and biochemical study of the effect of saffron extract on gentamicin-induced nephrotoxicity in rats. *Comp Clin Path*. 2015;24:1-5.
 5. Tavafi M. Protection of renal tubules against gentamicin induced nephrotoxicity. *J Ren Inj Prev*. 2012;2:5-6.
 6. He L, Peng X, Zhu J, et al. Protective effects of curcumin on acute gentamicin-induced nephrotoxicity in rats. *Can J Physiol Pharmacol*. 2015; 93:275-82.
 7. Bae EH, Kim IJ, Joo SY, et al. Renoprotective effects of the direct renin inhibitor aliskiren on gentamicin-induced nephrotoxicity in rats. *J Renin Angiotensin Aldosterone Syst*. 2014;15:348-61.
 8. Balakumar P, Rohilla A, Thangathirupathi A. Gentamicin-induced nephrotoxicity: do we have a promising therapeutic approach to blunt it? *Pharmacol Res*. 2010;62:179-86.
 9. Lee I-C, Kim S-H, Lee S-M, et al. Melatonin attenuates gentamicin-induced nephrotoxicity and oxidative stress in rats. *Arch Toxicol*. 2012;86:1527-36.
 10. Yaman I, Balikci E. Protective effects of nigella sativa against gentamicin-induced nephrotoxicity in rats. *Exp Toxicol Pathol*. 2010;62:183-90.
 11. Rezaei A, Heidarian E. Co-administration of trientine and flaxseed oil on oxidative stress, serum lipids and heart structure in diabetic rats. *Indian J Exp Biol*. 2013;51:646-52.
 12. Rafeian-kopaei M, Shahinfard N, Rouhi-Boroujeni H, et al. Effects of *Ferulago angulata* extract on serum lipids and lipid peroxidation. *Evid Based Complement Alternat Med*. 2014; 680856.
 13. Chang CC, Yang MH, Wen HM, et al. Estimation of total flavonoid content in propolis by two complementary colorimetric methods. *J Food Drug Analysis*. 2002; 10: 178-82.
 14. McDonald S, Prenzler PD, Antolovich M, et al. Phenolic content and antioxidant activity of olive extracts. *Food Chem*. 2001;73:73-84.
 15. Friedewald WT, Levy RI, Fredrickson DS. Estimation of the concentration of low-density lipoprotein cholesterol in plasma, without use of the preparative ultracentrifuge. *Clin Chem*. 1972;18:499-502.
 16. Agarwal R, Chase SD. Rapid, fluorimetric-liquid chromatographic determination of malondialdehyde in biological samples. *J Chromatogr B Analyt Technol Biomed Life Sci*. 2002;775:121-6.
 17. Heidarian E, Soofiniya Y. Hypolipidemic and hypoglycemic effects of aerial part of *Cynara scolymus* in streptozotocin-induced diabetic rats. *J Med Plant Res*. 2011;5:2717-23.
 18. Heidarian E, Saffari J, Jafari-Dehkordi E. Hepatoprotective action of *Echinophora platyloba* DC leaves against acute toxicity of acetaminophen in Rats. *J Diet Suppl*. 2014; 11:53-63.
 19. Beauchamp C, Fridovich I. Superoxide dismutase: Improved assays and an assay applicable to acrylamide gels. *Anal Biochem*. 1971;44:276-87
 20. Omaye ST, Turnbull JD, Sauberlich HE. Selected methods for the determination of ascorbic acid in animal cells, tissues, and fluids. *Methods Enzymol*. 1979;62:3-11.
 21. Reznick AZ, Packer L. Oxidative damage to proteins: Spectrophotometric method for carbonyl assay. *Methods Enzymol*. 1994;233:357-63.
 22. Drury R, Wallington E. Carleton's histological technique. Toronto: Oxford University Press; 1980.
 23. Shalaby M, Hammouda A. Nephroprotective, diuretic and antioxidant effects of some medicinal herbs in gentamicin-nephrotoxic rats. *J Intercult Ethnopharmacol*. 2014;3:1-8.
 24. Tavafi M. Inhibition of gentamicin-induced renal tubular cell necrosis. *J Nephropathol*. 2012;1:83-86.
 25. Heidarian E, Jafari-Dehkordi E, Seidkhani-Nahal A. Lipid-lowering effect of artichoke on liver phosphatidate phosphohydrolase and plasma lipids in hyperlipidemic rats. *J Med Plant Res*. 2011;5:4918-24.
 26. Heidarian E, Rafeian-Kopaei M, Khoshdel A, et al. Metabolic effects of berberine on liver phosphatidate phosphohydrolase in rats fed on high lipogenic diet: an additional mechanism for the hypolipidemic effects of berberine. *Asian Pac J Trop Biomed*. 2014;4:S429-35.
 27. Sardana A, Kalra S, Khanna D, et al. Nephroprotective effect of catechin on gentamicin-induced experimental nephrotoxicity. *Clin Exp Nephrol*. 2015;19:178-84.
 28. Selvaraj S, Krishnaswamy S, Devashya V, et al. Influence of membrane lipid composition on flavonoid-membrane interactions: Implications on their biological activity. *Prog Lipid Res*. 2015;58:1-13.
 29. Wang J, Schipper HM, Velly AM, et al. Salivary biomarkers of oxidative stress: A critical review. *Free Radic Biol Med*. 2015;85:95-104.
 30. Weidinger A, Kozlov AV. Biological activities of reactive oxygen and nitrogen species: Oxidative stress versus signal transduction. *Biomolecules*. 2015;5:472-84.
 31. El-Ashker M, Abdelhamid F, Risha E, et al. Vitamin C Ameliorates Gentamicin-Induced Acute Kidney Injury in Equines: An Experimental Study. *J Equine Vet Sci*. 2015;35:238-43.
 32. Stojiljkovic N, Veljkovic S, Mihailovic D, et al. Protective effects of pentoxifylline treatment on gentamicin-induced nephrotoxicity in rats. *Ren Fail*. 2009;31:54-61.
 33. Donate-Correa J, Martín-Núñez E, Muros-de-Fuentes M, et al. Inflammatory Cytokines in Diabetic Nephropathy. *J Diabetes Res*. 2015; 948417.
 34. Stojiljkovic N, Stojiljkovic M, Randjelovic P, et al. Cytoprotective effect of vitamin C against gentamicin-induced acute kidney injury in rats. *Exp Toxicol Pathol*. 2012;64:69-74.
- Correspondence to:
Esfandiar Heidarian, MD
Clinical Biochemistry Research Center, Shahrekord University of Medical Sciences, Shahrekord, Iran
Tel: +98 383 334 6720
E-mail: heidarian_e@skums.ac.ir
- Received December 2016
Revised March 2016
Accepted April 2016