

# Limb Lengthening Using the PRECICE™ Nail System: Complications and Results

Ulrich Wiebking,<sup>1,\*</sup> Emmanouil Liodakis,<sup>1</sup> Mohamed Kenaway,<sup>2</sup> and Christian Krettek<sup>1</sup>

<sup>1</sup>Department of Trauma, Medical School Hannover, Hannover, Germany

<sup>2</sup>Department of Orthopedic Surgery, Sohag University, Sohag, Egypt

\*Corresponding author: Ulrich Wiebking, Department of Trauma, Medical School Hannover, Hannover, Germany. Tel: +49-5115322050, Fax: +49-5115325877, E-mail: U.Wiebking@t-online.de

Received 2016 January 15; Revised 2016 July 20; Accepted 2016 August 03.

## Abstract

**Background:** Three types of telescopic nails are mainly used for intramedullary limb lengthening nowadays. Despite some important advantages of this new technology (e.g. controlled distraction rate, not restricted availability, possibility to perform accordion maneuvers), few articles exist on clinical results and complications after lengthening with the PRECICE™ nail (Ellipse, USA).

**Objectives:** The aim of the current study was to describe and analyze the complications associated with lengthening with the PRECICE™ nail. Are the problems preventable when using the PRECICE, related to the distraction rate control, the lengthening goals and technique and handling?

**Methods:** We retrospectively reviewed the charts of 9 patients operated between 2012 and 2013 with a PRECICE™ nail for a leg length discrepancy (LLD). The mean age of the patients was 32 years (range, 17 - 48 years). There were 5 femoral and 4 tibial procedures. The causes of LLD were posttraumatic (n = 5) and congenital (n = 4). The mean LLD was  $36.4 \pm 11.4$  mm. The minimum follow-ups were 2 months (average, 5 months; range, 2 - 9 months).

**Results:** The mean distraction rate was  $0.5 \pm 0.1$  mm/day. We observed in 7 patients differences in achieving the lengthening goals (average, 1.6 mm; range, -20.0 - 5.0 mm). Average lengthening was  $34.7 \pm 10.7$  mm. All patients reached normal alignment and normal joint orientation. An unintentional loss of the achieved length during the consolidation phase was noticed in patients with delayed bone healing in two cases. In the first case (loss of 20mm distraction) the nail could be redistracted and the goal length was achieved. In the second case (loss of 10mm distraction) the nail broke shortly after the diagnosis and the nail was exchanged.

**Conclusions:** We report of loss of achieved length after lengthening with a telescopic nail. Weight bearing before complete consolidation of the regenerate might be a risk factor for that. Thorough examination of the limb length and careful evaluation of the radiographs are required in the follow-up period. The PRECICE nail system requires the same vigilance like the other intramedullary systems too.

**Keywords:** Leg Length Discrepancy, Femur, Intramedullary Limb Lengthening, Complication

## 1. Background

In recent years, the use of fully implantable systems for limb lengthening helped to overcome many problems associated with the use of external fixator devices such as pin tract infections, muscle transfixion and malalignment. In addition, patient comfort and joint mobility have increased (1-6). On the other hand, the general risk of incomplete bone regeneration and pseudoarthrosis with the associated risk of material failure and falling short of the lengthening goal persists. Secondary surgical procedures to achieve healing and/or the lengthening goal again put the advantages of the internal implantation into perspective (6, 7).

Three types of telescopic nails are mainly used nowadays: mechanically activated nails (ISKD, Albizzia), motor-

ized nails (Fitbone) and the new magnetically driven nails (Phenix, Precice) (3, 4, 8-13). The intramedullary skeletal kinetic distractor (ISKD) nail (ISKD; Orthofix Inc., Lewisville, Texas) was the most commonly used intramedullary distractor. Due to problems with the control of distraction rate (e.g. runaway nails and nondistracting nails), the marketing of this nail was temporarily revoked in USA (1, 4, 14-16). Difficulties and pain with the distraction mechanism and the risk of distraction stop are important problems reported for the Albizzia nail (DePuy, Villeurbanne, France) (17, 18).

The Fitbone nail (Wittenstein Intens, Igersheim, Germany) is a motorized system, which is associated with isolated cases of shortening after the planned distraction length has been reached and functional impairments as

well as corrosion problems (2, 6). Moreover, its availability is limited (restricted number of licenses per country).

The Phenix nail (Phenix Medical, France) achieves the elongation with electromagnetic field acting between springs positioned within the nail and magnets acting from the outside. No movements by the patient are required to activate it. Indeed, the principle of these magnetically driven lengthening systems has been successfully used for the surgical correction of pediatric scoliosis for some time (19, 20). Problems handling the magnet and limitations of its use with excessive soft tissue bulk of the limb have been described with the Phenix nail (6, 21).

The PRECICE nail (Ellipse Tech., Irvine, USA) like the Phenix nail is based on magnetically controlled distractors. The PRECICE nail was FDA approved in 2011 and has been available in USA since then. In Europe, it was first used in 2012. This nail can be used for limb lengthening and shortening. This technology has already been used in spine surgery to correct scoliosis (MAGECTM, MAGnetic Expansion Control) (19).

## 2. Objectives

Despite some important advantages (e.g. controlled distraction rate, availability, possibility to perform accordion maneuvers), few articles exist on clinical results and complications after lengthening with the PRECICE™ nail. The aim of the study was to describe and analyze the complications associated with lengthening with the PRECICE nail, taking into consideration the control of the distraction rate, the achievement of the distraction goal, and the complications and the impact on the outcome.

## 3. Methods

### 3.1. Data Extraction

The present study was approved by our local Institutional Review Board (2164 - 2014). We retrospectively reviewed the charts of all patients who underwent intramedullary femoral lengthening procedures with the PRECICE nail at our institution between October 2012 and December 2013.

### 3.2. Patient Selection

Nine patients (5 femora, 4 tibiae) with LLD  $\geq$  20mm were eligible for inclusion in the study. Mean age at the time of the procedure was 32 years (range, 17 - 48 years). All nails were inserted in an antegrade fashion. The LLD was posttraumatic in 5 cases and congenital in 4 cases. Contraindications for the use of intramedullary lengthening

nail included open growth plates, active infection, irregular or overly narrow medullary cavities, and a femur or tibia too short for the existing nail sizes. One patient lost follow-up after one month. As a result, the shortest follow-up was 2 months after healing, with an average of 6 months and a range of 2 - 11 months.

The reason for the reduced length was posttraumatic in 5 cases and congenital in 4 cases. Four patients with length discrepancies of more than 80mm had staged lengthening. In three cases with femoral shortening, first stage lengthening with an ISKD nail had been performed and it was exchanged with a PRECICE nail for the second stage. In one patient, the LLD was partially corrected on the femoral side using an ISKD and the remaining deficit was subsequently adjusted on the tibia using the PRECICE nail. Of the 9 patients, one patient had knee arthrodesis and two patients had ankle arthrodesis. One patient had a concomitant recurvatum deformity at the distal femur of 8°.

The average diameter of the used nails was  $11.3 \pm 0.9$  mm (10.7 - 12.5) with a length ranging from a minimum of 255 to a maximum of 330 mm. None of our patients was a smoker.

The follow-up examinations did not follow a previously defined schedule for this study. All data were acquired secondarily from the available medical records and X-ray images. Details regarding LLD, achieved lengthening, time to bone healing, full weight-bearing and time elapsed since the nail implantation were documented.

The preoperative planning included LLD measurements and limb alignment assessments based on full-length radiographs of the lower extremities in standing position. The film focus distance was 1.5 meters. A calibrated digital radiography system was used (picture archiving and communication system [PACS]; Centricity, General Electric, USA). In addition to that, LLDs were clinically evaluated with blocks of a defined height that were placed under the foot of the shorter side until a neutral pelvic tilt was reached and the reliability of the length and axis measurement was hence improved. Regular digital measurements of the X-ray images were conducted and included the leg length difference, deviation of the mechanical axis and the joint orientation angles. The pre-operative distraction goal was defined by the leg length difference measured by means of the X-ray images (22). As recommended by the manufacturer, the nail length was selected such that 2 to 3 cm of the thicker part of the nail were positioned at the end of the distraction within the distracted bone segment (23).

### 3.3. Surgery and Aftercare

The surgery was conducted in lateral decubitus position for the femur and in supine position for the tibia. The first step was the implantation of two 5 mm Schanz screws in the proximal and distal part of the femur or tibia to maintain control of rotation. Transverse osteotomy in the shaft was conducted in accordance with the preoperative plans using the multiple drill hole technique. This was followed by intramedullary reaming 2 mm more than the nail diameter. The nail was then inserted and locked proximally and distally. Postoperatively mobilization with partial weight-bearing of 15 kg using underarm crutches was permitted following one day of bed rest. The lengthening phase started between day 5 and 7 after the surgery, at a distraction rate or index of 1 mm per day for the femur and 0.5 mm for the tibia. The distraction index was calculated from the length of the radiographic distraction gap divided by the time between beginnings to the end of the distraction (3). After being briefed thoroughly, patients took the external remote controller (ERC) home with them. During the distraction phase, all patients were followed up weekly and then every 6 weeks during the consolidation phase. X-ray images were obtained and the distraction length was measured according to Kirane et al. during the distraction phase (24). Distraction problems and insufficient bone regeneration were particularly captured. Patients were additionally seen between and after the intervals as needed. The scores according to Karlstrom-Olerud and according to Paley were recorded as clinical scores (22, 25).

We identified all patients who had complications during the distraction and/or consolidation phase. Complications were classified as minor, moderate or major according to Dahl et al. (26). Minor complications neither had an impact on the outcome nor did they require a prolonged intervention. Brief major complications or persistent minor complications were classified as moderate complications. Major complications were ones that led to unplanned, additional surgery or to permanent consequential damages. LLDs > 10mm at the end of the procedure was classified as major complications (27). We used the same definitions formulated earlier to evaluate insufficient bone regeneration (14, 28).

### 3.4. Data Analysis

All required statistical analyses were performed using the SPSS software (IBM SPSS® Statistics 21.0; SPSS Inc., Chicago, IL, USA). To analyze the data, descriptive statistics was also used. Continuous variables are presented as mean  $\pm$  standard deviation (SD). Since no groups were compared in this post-marketing surveillance study, no power analysis was conducted. In accordance with the guidelines by

Kirane et al. (24), we calculated the accuracy and the precision of the measurements relating to the distraction and elongation by means of standard equations.

## 4. Results

### 4.1. Control of the Distraction Rate

The average distraction rate was  $0.39 \pm 0.88$  mm/day and the average consolidation index  $33.45 \pm 10.31$  days/cm. No runaway (unintentional distraction rate > 1.5 mm/day) or nondistracting nails were recorded. Two cases of shortening after achieving the desired length were reported (see complications).

Knee and ankle ranges of motion (ROM) were not affected. One patient with 8° of recurvatum deformity of the distal femur was acutely corrected through the lengthening osteotomy.

### 4.2. Achievement of the Distraction Goal

The average planned length after the correction was  $36.4 \pm 11.4$  mm, with a range of 20 to 50 mm and a median of 35 mm. The average difference between the achieved length at the end of the correction and the planned length was  $-1.18 \pm 5.15$  mm (range, 12.7 mm shortening to 5.1 mm lengthening). Three patients consequently had over lengthening compared to the target length, three had still some shortening and one patient a considerable shortening with breakage of the nail (see complications). One patient achieved the planned length exactly and one patient was lost to follow-up.

The combined arithmetic mean of the achieved total lengthening for all patients was 35 mm (range: 21-52 mm). The reliability of the PRECICE was 8/9 nails overall, 4/4 tibial nails and 4/5 femoral nails. The accuracy of the distraction was  $78.0\% \pm 10.7\%$  and the precision was 61%.

### 4.3. Complications

Two patients experienced complications; one moderate and one severe combined with type I regenerate failure (26, 28). In both cases, the nails recoiled after the end of distraction resulting in loss of the achieved length.

In the first case (No. 3 in Table 1), the target length of 50 mm was reached as planned three months after the surgery, with a distraction index of 0.5 mm/day. As there was evidence of callus, partial weight-bearing with rapid increase to full weight-bearing was permitted after the 4th postoperative month. The loss of the achieved length reduction was noticed at the 6th postoperative month and the nail was redistracted again without any further operations until full consolidation (Figure 1). The distraction

**Table 1.** Patients and Results

Patient No	Gender/Age	Etiology	Bone Included	Nail Size, mm	Limb Length Ob-tained/Projected, mm	Distraction Index (mm/Day)	Follow-Up (Month)	Failure Details
1	m/17	Congenital	femur	10.7 × 330	52/50	0.7	4	none
2 <sup>a</sup>	f/19	Congenital	tibia	10.7 × 305	21/25	0.4	7	none
3 <sup>b</sup>	f/46	Congenital	tibia	10.7 × 305	30/50	0.4	7	Shortening after reaching the distraction length
4	m/19	Trauma	tibia	10.7 × 330	35/35	0.5	Lost to follow-up	none
5	f/44	Trauma	femur	12.5 × 255	33/38	0.5	6	none
6 <sup>c,d</sup>	m/26	Trauma	femur	12.5 × 265	52/50	0.6	9	Breakage of nail after nonunion. Breakage likely due to fall
7 <sup>d</sup>	m/40	Trauma	femur	12.5 × 255	30/30	0.5	2	none
8 <sup>d</sup>	m/31	Trauma	femur	10.7 × 260	35/30	0.7	3	none
9	f/48	Congenital	tibia	10.7 × 255	25/20	0.6	2	none
μ	32	-	-	-	35/36	0.5	5	-

<sup>a</sup>Previous lengthening with ISKD in the femur.

<sup>b</sup>Uneventfully second lengthening with the same nail.

<sup>c</sup>Required additional operation for nonunion repair, PRECICE replaced by standard intramedullary nail and autologous bone grafting

<sup>d</sup>Previous lengthening with ISKD in the same bone

index was again 0.5 mm/day. The achieved length was 47 mm.

The second patient (No. 6 in Table 1) suffered from 90 mm posttraumatic femoral shortening as a result of femoral shaft fracture. An initial femoral lengthening of 30 mm by means of an ISKD nail was achieved without complications. Once the consolidation had been complete, the PRECICE was implanted with a planned target lengthening of 50 mm. The distraction index was 1 mm/day. The lengthening was complete in three months after the surgery. Starting from the 4th month, partial weight-bearing was allowed and unnoticed increasing loss of achieved length with concurrent type I regenerate failure emerged. The nail broke at the 10th month after the surgery (Figure 2). The patient underwent an unplanned surgery with reamed exchange nailing using cannulated femoral nail (CFN) and autologous bone grafting.

None of the patients had deep infection. No significant pain associated with lengthening was reported. One patient was lost to the follow-up after the surgery, because he was residing abroad. As a result, we were unable to calculate the distraction and consolidation index (missing values in Table 1).

#### 4.4. Outcome

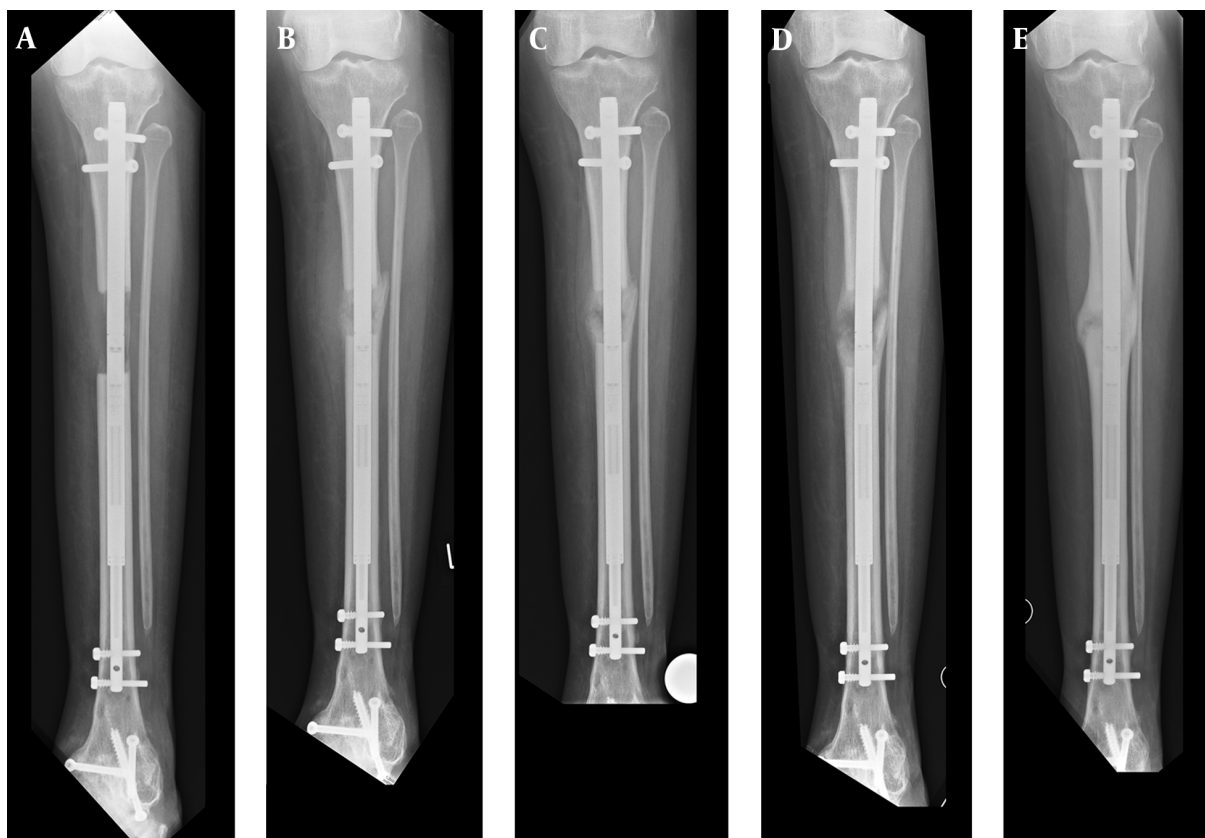
Eight patients achieved full weight-bearing after an average of 12 weeks (6 - 28 weeks).

An average improvement by 3 points was attained in the score according to Karlstrom and Olerud, from 26 (moderate) before the surgery to 29 (satisfactory) after the surgery. At the last follow-up, 5 of 8 patients had a good or satisfactory result, moderate (n=2) and poor (n=1). The average postoperative score according to Paley after the completion of the distraction and achievement of full weight-bearing was  $86.0 \pm 7.3$ , corresponding to excellent results (n=2) and good outcome (n=6).

## 5. Discussion

Preliminary results from North America and Europe show that the PRECICE nail system allows a reliable and PRECICE correction of LLDs (24, 29-31). In particular, the mechanical problems reported with other lengthening nails such as “runaway” phenomena or nondistracting nails requiring manipulations under anesthesia or revision surgery have not been described so far. We would report our results and two serious complications with the use of PRECICE nail.

Patients were not randomized and only descriptive statistical analyses were conducted. As this is a case series involving the description of two particular complications, it is impossible to say whether the rate of complications was greater or smaller than bone lengthening with conventional methods.

**Figure 1.** A-E, A 46-Year Old Woman, Patient No. 3

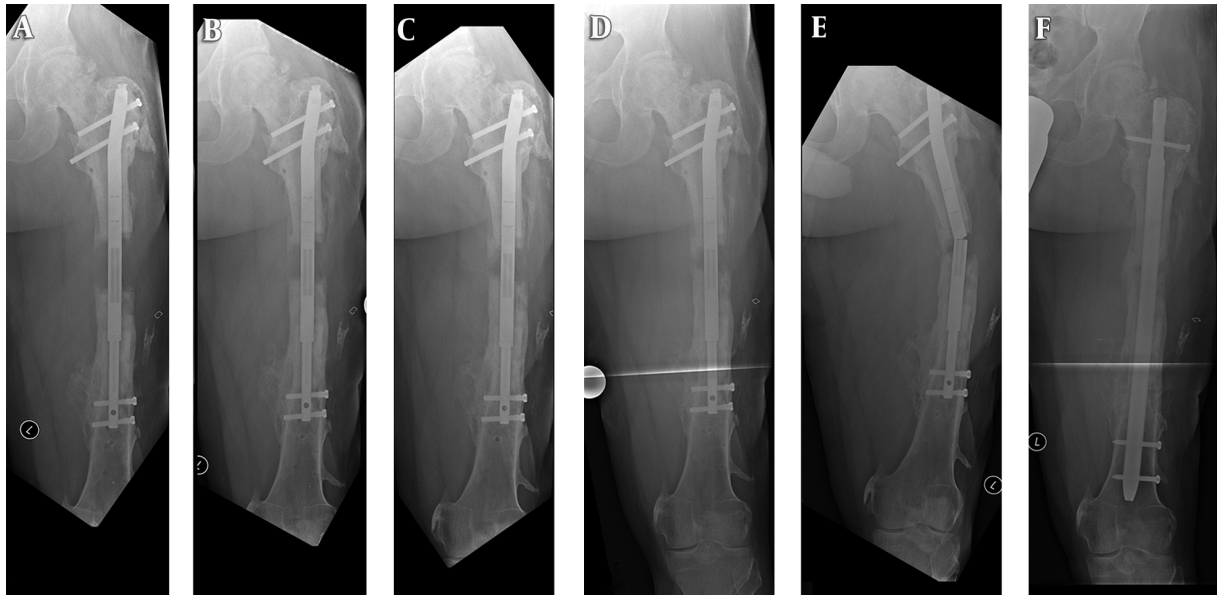
(A-C), shortening about 20 mm after reaching the distraction length 3 months after the surgery with PRECICE nail; (D-E), redistraction and bone consolidation 12 months later.

One of the obvious advantages of the PRECICE nail is the externally triggered control of the lengthening mechanism and the control of the distraction rate (29, 31). In accordance with our results, Schiedel et al. reported a discrepancy between the radiologically measured length and the length shown on the monitor of the external remote controller (ERC). This phenomenon occurred in 10 of 23 cases and the bone regenerate was on average 10% shorter than expected. An inadvertent displacement of the ERC during the lengthening procedure and the performance of the lengthening in an outpatient setting by the patient without the presence of the clinician is said to be a possible reason for this. In addition, the PRECICE system should not be used in patients with a BMI of  $> 35$ , because the thicker surrounding soft tissue increases the distance from the ERC to the nail. This may interfere with the nail rotations through the magnet (31). In our study, the bone regenerate was on average 4% shorter than initially planned. Although, these differences were not clinically relevant, we believe that patient training regarding the appropriate use

of the ERC and regular follow-ups during the lengthening phase are essential for the success of the procedure.

Two complications graded as serious according to the classification by Dahl were encountered (26). The complications were likely due to nail-related as well as nail-unrelated reasons. Patient No. 3 experienced loss of the achieved lengthening with transition from partial to full weight bearing. The shortening was 20 mm and we were able to equalize it again by reactivating the ERC, since the bone regenerate was still flexible enough to be stretched. The subsequent healing process was complication free and the difference to the planned target length was 5 mm.

Patient No. 6 had a posttraumatic LLD of 90 mm. A 2-stage procedure was performed. In the first stage the femur was lengthened 40mm without any complications. At the second stage, the patient developed a partial regenerate insufficiency with 10 mm shortening in the consolidation phase and breakage of the nail. It is known that prior surgeries increase the probability of poor bone regeneration. This can result in delayed bone healing and

**Figure 2.** 2A-F, A 26-Year-Old Man, Patient No. 6

(A-D), AP radiographs show delayed consolidation and shortening of the femur; (E), Breakage of nail after nonunion 10 months after PRECICE implantation; (F), after removal, bone graft and CFN with 1 cm LLD.



**Figure 3.** A, B, Nail Breakage in the Middle of the Nail in the PRECICE Nail in the Patient Shown in [Figure 2](#)

a prolonged consolidation phase (14, 16, 30). In addition, the weight bearing was likely increased rapidly in this case. Schiedel et al. reported 2 cases of nail breakage during the consolidation in their study of 24 patients. They explained it with increased tension in the nail with the starting consolidation of the bone regenerate or accidental shortening (31).

The PRECICE device was designed to be modular. This modularity provided a novel way to customize the implant to any approach the surgeon might need. While

this novel feature was a convenience for inventory management and flexibility, it presented a potential weak point when stressed. According to the manufacturer, the modularity was removed in the second generation of the PRECICE to improve the strength of the device by making the outer tube one complete piece. Any welds on the “motor” section of the implant were removed.

Another change in the PRECICE II implant was the implementation of a “keeper”. In rare occasions an active patient could move their leg to cause a loss of distraction in the nail. This is what likely happened to the second patient with the shortening. The addition of the “keeper” would eliminate the possibility that the nail might lose distraction by unwinding. Baumgart and Thaller described a similar problem for the Fitbone nails (6, 8).

The two complication-related acute problems were treated nonsurgically in case No. 3 and with a renewed surgical intervention in case No. 6. The treatment duration increased significantly in both cases and full weight bearing was only possible at 28 and 30 weeks, respectively. In both cases, the planned lengthening goal was not fully reached. Lascombes et al. (7) are the only authors who include the therapy duration as an additional criterion in the classification of complications. In doing so, the time of full weight bearing is relevant when bones are lengthened with nail systems. Accordingly, this concerns grade IIIb complications.

Despite the complications, patient satisfaction in terms of comfort and ease of using the device was generally positive. We did not record any infections or nerve damages. Knee and ankle ranges of motion were not affected. Only 1 patient reported worsening of the Karlström-Olerud score compared to the preoperative score. This was patient No. 6, who required revision surgery to treat the complication. Nevertheless, he achieved a favorable Paley score. From a subjective point of view, patients appeared to have been satisfied with the treatment.

The accuracy and precision were 78% and 61%, respectively and they were lower in our study compared to other studies (24, 31). The two complications in a small number of cases caused these low rates. In contrast, the reliability was 0.8 (8 of 9 implanted nails), and is hence comparable with other studies investigating the PRECICE with 0.9 and the ISKD with 0.8 (5, 31).

The present study has some limitations. First, small sample size is a universal problem for studies investigating uncommon procedures, such as intramedullary limb lengthening. Second, we did not consider long-term outcomes. Finally, we did not compare this new technology with other lengthening techniques (e.g. lengthening over nail, lengthening with other intramedullary distractors). This study should be considered a preliminary report.

The new generation nail is said to have remedied the described problems with the PRECICE nail we used. When ensuring proper instruction of the patients and regular monitoring of the ratio of measured and indicated lengthening, the PRECICE nail is a safe and convenient system for the correction of leg length discrepancies. Irrespective of the nail, healing delays in existing healed bone regeneration should be expected in connection with renewed callus distractions. Post-marketing surveillance is very important to see if the new technology in PRECICE II Nail is safe or not and to improve the precision and accuracy of the distraction.

## Acknowledgments

We thank the Ellipse Technologies sales representatives and engineers for technical guidance.

## Footnote

**Authors' Contribution:** Ulrich Wiebking and Emmanouil Liodakis conceived the study and performed the operations and follow-ups. Ulrich Wiebking assembled and analyzed the data and made the radiographic measurements and arranged data. Emmanouil Liodakis and Mohamed Kenawey made substantial changes to

the manuscript. Christian Krettek revised the entire manuscript.

## References

- Burghardt RD, Herzenberg JE, Specht SC, Paley D. Mechanical failure of the Intramedullary Skeletal Kinetic Distractor in limb lengthening. *J Bone Joint Surg Br.* 2011;**93**(5):639–43. doi: [10.1302/0301-620X.93B5.25986](https://doi.org/10.1302/0301-620X.93B5.25986). [PubMed: [21511930](https://pubmed.ncbi.nlm.nih.gov/21511930/)].
- Dincyurek H, Kocaoglu M, Eralp IL, Bilen FE, Dikmen G, Eren I. Functional results of lower extremity lengthening by motorized intramedullary nails. *Acta Orthop Traumatol Turc.* 2012;**46**(1):42–9. [PubMed: [22441451](https://pubmed.ncbi.nlm.nih.gov/22441451/)].
- Hankemeier S, Gosling T, Pape HC, Wiebking U, Krettek C. Limb lengthening with the Intramedullary Skeletal Kinetic Distractor (ISKD). *Oper Orthop Traumatol.* 2005;**17**(1):79–101. doi: [10.1007/s00064-005-1123-5](https://doi.org/10.1007/s00064-005-1123-5). [PubMed: [16007380](https://pubmed.ncbi.nlm.nih.gov/16007380/)].
- Kenawey M, Krettek C, Liodakis E, Wiebking U, Hankemeier S. Leg lengthening using intramedullary skeletal kinetic distractor: results of 57 consecutive applications. *Injury.* 2011;**42**(2):150–5. doi: [10.1016/j.injury.2010.06.016](https://doi.org/10.1016/j.injury.2010.06.016). [PubMed: [20638660](https://pubmed.ncbi.nlm.nih.gov/20638660/)].
- Schiedel FM, Pip S, Wacker S, Popping J, Tretow H, Leidinger B, et al. Intramedullary limb lengthening with the Intramedullary Skeletal Kinetic Distractor in the lower limb. *J Bone Joint Surg Br.* 2011;**93**(6):788–92. doi: [10.1302/0301-620X.93B6.25581](https://doi.org/10.1302/0301-620X.93B6.25581). [PubMed: [21586778](https://pubmed.ncbi.nlm.nih.gov/21586778/)].
- Thaller PH, Furmetz J, Wolf F, Eilers T, Mutschler W. Limb lengthening with fully implantable magnetically actuated mechanical nails (PHENIX((R)))—preliminary results. *Injury.* 2014;**45** Suppl 1:60–5. doi: [10.1016/j.injury.2013.10.029](https://doi.org/10.1016/j.injury.2013.10.029). [PubMed: [24321414](https://pubmed.ncbi.nlm.nih.gov/24321414/)].
- Lascombes P, Popkov D, Huber H, Haumont T, Journeau P. Classification of complications after progressive long bone lengthening: proposal for a new classification. *Orthop Traumatol Surg Res.* 2012;**98**(6):629–37. doi: [10.1016/j.otsr.2012.05.010](https://doi.org/10.1016/j.otsr.2012.05.010). [PubMed: [22981643](https://pubmed.ncbi.nlm.nih.gov/22981643/)].
- Baumgart R, Betz A, Schweiberer L. A fully implantable motorized intramedullary nail for limb lengthening and bone transport. *Clin Orthop Relat Res.* 1997(343):135–43. [PubMed: [9345218](https://pubmed.ncbi.nlm.nih.gov/9345218/)].
- Cole JD, Justin D, Kasparis T, DeVlught D, Knobloch C. The intramedullary skeletal kinetic distractor (ISKD): first clinical results of a new intramedullary nail for lengthening of the femur and tibia. *Injury.* 2001;**32** Suppl 4:129–39. [PubMed: [11812486](https://pubmed.ncbi.nlm.nih.gov/11812486/)].
- Guichet JM, Casar RS. Mechanical characterization of a totally intramedullary gradual elongation nail. *Clin Orthop Relat Res.* 1997(337):281–90. [PubMed: [9137201](https://pubmed.ncbi.nlm.nih.gov/9137201/)].
- Horn J, Grimssrud O, Dagsgard AH, Huhnstock S, Steen H. Femoral lengthening with a motorized intramedullary nail. A matched-pair comparison with external ring fixator lengthening in 30 cases. *Acta Orthopaedica.* 2014;**85**(6):1–9.
- Krieg AH, Lenze U, Speth BM, Hasler CC. Intramedullary leg lengthening with a motorized nail. *Acta Orthop.* 2011;**82**(3):344–50. doi: [10.3109/17453674.2011.584209](https://doi.org/10.3109/17453674.2011.584209). [PubMed: [21561309](https://pubmed.ncbi.nlm.nih.gov/21561309/)].
- Simpson AH, Shalaby H, Keenan G. Femoral lengthening with the Intramedullary Skeletal Kinetic Distractor. *J Bone Joint Surg Br.* 2009;**91**(7):955–61. doi: [10.1302/0301-620X.91B7.21466](https://doi.org/10.1302/0301-620X.91B7.21466). [PubMed: [19567863](https://pubmed.ncbi.nlm.nih.gov/19567863/)].
- Kenawey M, Krettek C, Liodakis E, Meller R, Hankemeier S. Insufficient bone regenerate after intramedullary femoral lengthening: risk factors and classification system. *Clin Orthop Relat Res.* 2011;**469**(1):264–73. doi: [10.1007/s11999-010-1332-6](https://doi.org/10.1007/s11999-010-1332-6). [PubMed: [20361281](https://pubmed.ncbi.nlm.nih.gov/20361281/)].
- Papanna MC, Monga P, Al-Hadithy N, Wilkes RA. Promises and difficulties with the use of femoral intra-medullary lengthening nails to treat limb length discrepancies. *Acta Orthop Belg.* 2011;**77**(6):788–94. [PubMed: [22308625](https://pubmed.ncbi.nlm.nih.gov/22308625/)].

16. Wang K, Edwards E. Intramedullary skeletal kinetic distractor in the treatment of leg length discrepancy—a review of 16 cases and analysis of complications. *J Orthop Trauma*. 2012;**26**(9):138–44. doi: [10.1097/BOT.0b013e318238b5b1](https://doi.org/10.1097/BOT.0b013e318238b5b1). [PubMed: [22377509](https://pubmed.ncbi.nlm.nih.gov/22377509/)].
17. Garcia-Cimbrello E, Curto de la Mano A, Garcia-Rey E, Cordero J, Marti-Ciruelos R. The intramedullary elongation nail for femoral lengthening. *J Bone Joint Surg Br*. 2002;**84**(7):971–7. [PubMed: [12358388](https://pubmed.ncbi.nlm.nih.gov/12358388/)].
18. Mazeau P, Assi C, Louahem D, L’Kaissi M, Delpont M, Cottalorda J. Complications of Albizzia femoral lengthening nail: an analysis of 36 cases. *J Pediatr Orthop B*. 2012;**21**(5):394–9. doi: [10.1097/BPB.0b013e328354b029](https://doi.org/10.1097/BPB.0b013e328354b029). [PubMed: [22643127](https://pubmed.ncbi.nlm.nih.gov/22643127/)].
19. Cheung KM, Cheung JP, Samartzis D, Mak KC, Wong YW, Cheung WY, et al. Magnetically controlled growing rods for severe spinal curvature in young children: a prospective case series. *Lancet*. 2012;**379**(9830):1967–74. doi: [10.1016/S0140-6736\(12\)60112-3](https://doi.org/10.1016/S0140-6736(12)60112-3). [PubMed: [22520264](https://pubmed.ncbi.nlm.nih.gov/22520264/)].
20. Wick JM, Konze J. A magnetic approach to treating progressive early-onset scoliosis. *AORN J*. 2012;**96**(2):163–73. doi: [10.1016/j.aorn.2012.05.008](https://doi.org/10.1016/j.aorn.2012.05.008). [PubMed: [22840505](https://pubmed.ncbi.nlm.nih.gov/22840505/)].
21. Konofaos P, Kashyap A, Neel MD, Ver Halen JP. A novel device for long bone osteodistraction: description of device and case series. *Plast Reconstr Surg*. 2012;**130**(3):418–22. doi: [10.1097/PRS.0b013e31825dc069](https://doi.org/10.1097/PRS.0b013e31825dc069). [PubMed: [22929265](https://pubmed.ncbi.nlm.nih.gov/22929265/)].
22. Paley D, Herzenberg JE, Paremian G, Bhave A. Femoral lengthening over an intramedullary nail. A matched-case comparison with Ilizarov femoral lengthening. *J Bone Joint Surg Am*. 1997;**79**(10):1464–80. [PubMed: [9378732](https://pubmed.ncbi.nlm.nih.gov/9378732/)].
23. Ellipse Technologies Inc . PRECICE Nail System: Ellipse Technologies [cited 2012]. Available from: <http://www.ellipse-tech.com/?q=ip>.
24. Kirane YM, Fragomen AT, Rozbruch SR. Precision of the PRECICE internal bone lengthening nail. *Clin Orthop Relat Res*. 2014;**472**(12):3869–78. doi: [10.1007/s11999-014-3575-0](https://doi.org/10.1007/s11999-014-3575-0). [PubMed: [24682741](https://pubmed.ncbi.nlm.nih.gov/24682741/)].
25. Karlstrom G, Olerud S. Ipsilateral fracture of the femur and tibia. *J Bone Joint Surg Am*. 1977;**59**(2):240–3. [PubMed: [845210](https://pubmed.ncbi.nlm.nih.gov/845210/)].
26. Dahl MT, Gulli B, Berg T. Complications of limb lengthening. A learning curve. *Clin Orthop Relat Res*. 1994(301):10–8. [PubMed: [8156659](https://pubmed.ncbi.nlm.nih.gov/8156659/)].
27. Paley D. Problems, obstacles, and complications of limb lengthening by the Ilizarov technique. *Clin Orthop Relat Res*. 1990(250):81–104. [PubMed: [2403498](https://pubmed.ncbi.nlm.nih.gov/2403498/)].
28. Li R, Saleh M, Yang L, Coulton L. Radiographic classification of osteogenesis during bone distraction. *J Orthop Res*. 2006;**24**(3):339–47. doi: [10.1002/jor.20026](https://doi.org/10.1002/jor.20026). [PubMed: [16479566](https://pubmed.ncbi.nlm.nih.gov/16479566/)].
29. Rozbruch SR, Birch JG, Dahl MT, Herzenberg JE. Motorized intramedullary nail for management of limb-length discrepancy and deformity. *J Am Acad Orthop Surg*. 2014;**22**(7):403–9. doi: [10.5435/JAAOS-22-07-403](https://doi.org/10.5435/JAAOS-22-07-403). [PubMed: [24966246](https://pubmed.ncbi.nlm.nih.gov/24966246/)].
30. Shabtai L, Specht SC, Standard SC, Herzenberg JE. Internal lengthening device for congenital femoral deficiency and fibular hemimelia. *Clin Orthop Relat Res*. 2014;**472**(12):3860–8. doi: [10.1007/s11999-014-3572-3](https://doi.org/10.1007/s11999-014-3572-3). [PubMed: [24664194](https://pubmed.ncbi.nlm.nih.gov/24664194/)].
31. Schiedel FM, Vogt B, Tretow HL, Schuhknecht B, Gosheger G, Horter MJ, et al. How precise is the PRECICE compared to the ISKD in intramedullary limb lengthening? Reliability and safety in 26 procedures. *Acta Orthop*. 2014;**85**(3):293–8. doi: [10.3109/17453674.2014.913955](https://doi.org/10.3109/17453674.2014.913955). [PubMed: [24758320](https://pubmed.ncbi.nlm.nih.gov/24758320/)].