

PATIENT MANAGEMENT

A 49-Year-Old Woman with Chronic Skin Lesions, Acute Mental Status Changes and New Pulmonary Infiltrate: Case Discussion from the University of Louisville Hospital

Bhavani Puskur, Youssef Khafateh, Srikant Ramachandrani, Veronica Corcino, Mark Burns, Forest W. Arnold[†]

DOI: 10.18297/jri/vol1/iss3/11

Website: <https://ir.library.louisville.edu/jri>

© 2017, The Author(s).

Affiliations:

Division of Infectious Diseases, Department of Medicine, School of Medicine, University of Louisville, Louisville, KY (BP, SR, VC, MB, FWA)
Department of Pathology, School of Medicine, University of Louisville, Louisville, KY (YK)



1 Presentation of Case

Dr. Bhavani Puskur (Infectious Diseases): A 49-year-old white female with a history of diabetes and a motor vehicle crash six years prior causing serious injuries including aortic trauma requiring surgical repair presented to an outlying hospital with a headache and was admitted with poor responsiveness. She was transferred to this hospital for a higher acuity of care. She initially complained of a headache six days prior to admission, however she refused to seek medical care. Her family stated she had chills the day prior to admission and was also having generalized weakness. The next day her headache had progressed, and by the end of the day her mental status worsened per family with confusion and inappropriate responses. She was taken by her family to the local emergency department where she was admitted.

Six years prior to admission, the patient was involved in a motor vehicle crash with injuries to her aorta requiring repair with a graft, and to her intestine with subsequent short gut syndrome and chronic diarrhea. Nine months prior to admission, the patient was treated by her primary care physician for non-healing ulcers on her extremities. She had two deep ulcers on her upper extremities, and shallow ulcers on her lower extremities for which she was treated with multiple courses of trimethoprim/sulfamethoxazole followed later in the year with multiple courses of levofloxacin with no improvement. She saw a local dermatologist who performed a skin biopsy that was suspicious for bullous pemphigoid prompting treatment with prednisone. Cyclosporine was added a couple of months later due to an inadequate response to prednisone.

Six weeks prior to admission, the patient was evaluated at an academic medical center in a neighboring state with another skin biopsy. The sample was only sent to pathology which concluded, that it was a dermatofibrosis.

On the day of admission to the outlying hospital, her temperature was 99.1°F, blood pressure was 130/80 mm Hg, pulse was 130 beats/minute, and respiratory rate was 22 breaths/minute. Her oxygen saturation was 97% on ambient air. She was admitted to the ICU where she was mechanically intubated and ventilated for airway protection.

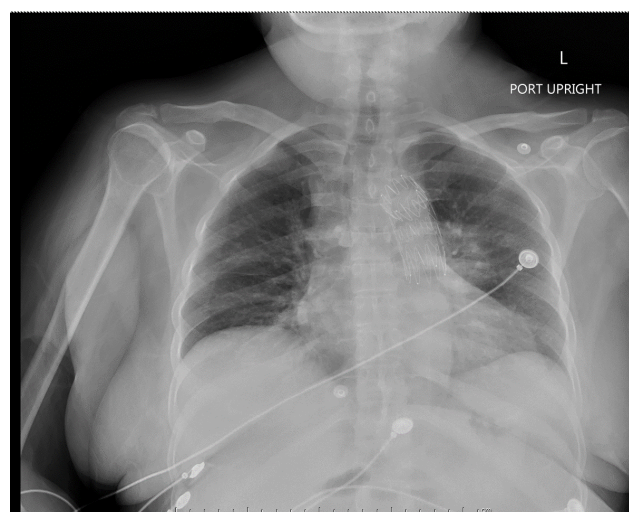


Fig. 1 Chest radiograph obtained during admission to outlying hospital with a left hilar opacity. Aortic graft also visible.

[†]Correspondence To:

Forest Arnold, DO, MSc
501 E. Broadway Suite 140B
Louisville, KY 40202
Email: f.arnold@louisville.edu

Admission laboratory tests, including blood cultures, were collected. (Table 1) A Lumbar Puncture (LP) was performed, as well as a chest radiograph. (Figure 1) In her cerebrospinal fluid (CSF), she had 75 white blood cells, (95% neutrophils, 2% lym-

phocytes), protein 61 (mg/dL) and glucose 61 (mg/dL). The Gram's stain showed no white blood cells or organisms and the culture was negative for bacterial growth. She was diagnosed with influenza using a rapid influenza diagnostic test from a nasopharyngeal sample, and was started on oseltamivir. A computerized tomography (CT) of her head was followed by a magnetic resonance imaging (MRI) of her brain, which showed multiple ring-enhancing lesions with central diffusion restriction throughout the brain without hemorrhagic conversion or mass effect. On her sixth day of hospitalization, she was transferred to our facility. Initial laboratory tests (Table 1) and an MRI of her brain (Figure 2) were performed.

Physical examination was significant for coarse breath sounds on auscultation, and skin ulcers on her extremities. A 3 cm ulcer was on the posterior aspect of her right upper arm with a depth of 6 mm. There was no surrounding edema, bleeding, or discharge. The base was clean with beefy red granulation tissue. A similar, smaller ulcer was more medial, and another was on her left forearm, but was pale in appearance. (Figure 3) Admission laboratory tests were obtained. (Table 1)

2 Diagnostic Approach

Dr. Srikanth Ramachandrani (fellow): My approach to this case is for us to determine the nature of the illness - whether it is acute, subacute or chronic. A second issue is whether the patient is immunocompetent or immunosuppressed. A third issue is whether we can connect the three dots, which are skin, lung and brain.

The patient seems to have developed symptoms over the last few weeks prior to admission, which places her into a subacute category. The skin lesions were present about a year ago, and were initially thought to be bullous pemphigoid, but the pathology was not clearly conclusive. Nevertheless, the patient received high-dose steroids for the last several months, which would make her more vulnerable to opportunistic infections.

Psittacosis would be unlikely with this kind of brain lesion, but still a possibility if the patient did have parrots as pets. Anaerobic lung infections with propionibacterium can sometimes be seen in the brain as well, but it is unlikely given that there was no neurological surgery in this patient. Other acute or chronic infection such as a streptococcal or staphylococcal pneumonia with subsequent bacteremia and embolization to the brain is also a possibility.

Dr. Mark Burns (fellow): The changes on MRI could be from Gram-positive bacteria including Streptococci contiguously spreading from soft tissue in the throat or oral cavity, or Staphylococci hematogenously spreading from an endovascular infection or endocarditis. Also this could be from a Gram-negative organism, such as *E. coli*, *Klebsiella* or *Pseudomonas* spreading contiguously from an ear infection. Based on the lab and imaging studies, I felt it was extremely important to know her human immunodeficiency virus (HIV)/acquired immune deficiency syndrome (AIDS) status. If she was HIV positive then the abnormalities on MRI could be from toxoplasmosis, or lymphoma. Progressive multi-

focal leukoencephalopathy would be less likely because this patient's brain involves mainly gray matter and not white matter. Regardless of whether or not she had HIV, she is diabetic and on prednisone and cyclosporine, and thus is immunosuppressed predisposing her to infection with a fungus (*Histoplasma*, *Blastomyces*, *Cryptococcus*), a higher bacteria like *Nocardia* or tuberculosis.

Dr. Veronica Corcino (fellow): This case depicts a 49 year-old diabetic female presenting with headache, generalized weakness, and worsening mental status. The patient was intubated upon arrival from an outlying hospital and transferred to the medical ICU; her chest x-ray revealed hilar opacities. Of note, the patient had been on intermittent courses of prednisone and cyclosporine for skin lesions on both upper and lower extremities for the past nine months. A previous dermatological evaluation was suggestive of bullous pemphigoid.

Infectious diseases, autoimmune diseases and malignancies may cause a clinical syndrome compatible with this patient's clinical presentation. Some elements of the history and physical exam may lead us to favor either an infectious or non-infectious process. For example, the presence of weight loss and a distinct pulmonary mass may be more suggestive of a pulmonary malignancy.

The patient's immune status, underlying comorbidities and geographical exposure are all important considerations in generating a differential diagnosis. For example, the previous empiric steroid use for bullous pemphigoid may have contributed to iatrogenic immunosuppression. Furthermore, if the patient is HIV positive, it would make some infections such as *Nocardia*, *Toxoplasma*, *Histoplasma*, *Mycobacterium tuberculosis* and *Cryptococcus* more likely.

During the initial evaluation of a patient with the mentioned symptoms, it is of utmost importance to identify the cause of possible acute meningeal inflammation promptly. The most common cause of meningeal inflammation that should not be overlooked is bacterial meningitis. However, the timing and findings of multiple small lesions on MRI would not be consistent with bacterial meningitis. On the other hand, these MRI findings could represent a more chronic type of infection including a tuberculoma, pyogenic abscess or disseminated fungal infection.

In order to establish a definitive diagnosis it is imperative to perform an LP and send CSF for cell count, protein, glucose and cultures for fungi, aerobic and anaerobic bacteria and acid fast bacilli (AFB).

In summary, there are two possibilities: either the infectious process stemmed from inoculation of the skin subsequently disseminating to the bloodstream, or the infectious process had a primary focus in the lungs or blood stream with subsequent systemic dissemination (including to the skin). Disseminated systemic diseases that explain the clinical picture include *Aspergillus*, but she was not wheezing and I do not know what the eosinophil level was. Such a disease could also be explained by tuberculosis, nocardiosis, histoplasmosis, cryptococcosis or blastomycosis.

Table 1 Laboratory values obtained at admission to each facility.

Variable	Reference Range	6 Days before this evaluation, Other Hospital	On evaluation, This Hospital
White Cell Count (cells/mm ³)	4,500-10,800	23,900	11,000
Neutrophils (%)	34-69	86	87
Hemoglobin (g/dL)	11-15.7	8.5	9
Hematocrit (%)	34-44	33	30
Platelet Count (cells/mm ³)	140,000-370,000	357,000	258,000
Sodium (mg/dL)	135-143	133	148
Potassium (mg/dL)	3.5-4.8	3.2	3.0
Blood Urea Nitrogen (mg/dL)	6-20	16	31
Creatinine (mg/dL)	0.44-1.03	0.80	1.83
Glucose (mg/dL)	65-110	89	97
AST (U/L)	8-34		12
ALT (U/L)	10-50		22
Alkaline Phosphatase (U/L)	25-105		62
Procalcitonin (ng/mL)	*	0.15	0.44
Lactic Acid (mmol/L)	0.5-2.2	2.2	1.1
CRP (mg/L)	<10		3.0
Albumin (g/dL)	3.3-4.5		2.3

AST - Aspartate aminotransferase; ALT - Alanine aminotransferase; CRP - C-reactive Protein

* <0.5 local bacterial infection possible, 0.5-2 systemic infection possible, 2-10 systemic infection likely, >10 almost exclusively due to severe bacterial sepsis or shock

Dr. Julio Ramirez (Chief of Infectious Diseases): The approach I would take is completely different. Is this one disease or multiple? We prefer to explain everything together, but if someone has HIV/AIDS, for example, having multiple diseases is more common. Here, we are dealing with chronic ulcers, lung disease and central nervous system involvement. If I consider them one at a time then I would produce a long differential as you all have done. If you say endocarditis then you have to explain it as a result of a pathogen that causes ulcers for nine months. We were told that she had aortic surgery, which means that she was on a heart-bypass machine for a time, and now she has a symptom, in this case a headache. So, we know that she is at risk for *Mycobacterium chimaera*, but my approach does not lead me there because *M. chimaera* does not cause chronic ulcers. Your approach should not lead you to say *Staphylococcus aureus* or *Chlamydomytila psittaci* for the same reason. What are the most likely organisms in your assessment causing chronic skin ulcers?

Dr. Burns: *Cryptococcus neoformans*, *Blastomyces dermatitidis*.

Dr. Corcino: *Mycobacterium tuberculosis*. It is rare for *Nocardia asteroides* to produce an ulcer, but possible.

Dr. Ramachandruni: If the skin lesions are considered to be part of this conundrum then this is a chronic illness of infectious etiology which is invading skin, lungs and brain. The differential would be a fungus such as *Histoplasma*, *Blastomyces*, *Aspergillus*, or *Coccidioides*. *Mucor*, *Rhizopus*, and *Fusarium* should also be considered. Other pathogens include tuberculosis, non-tuberculous mycobacteria, and *Nocardia*. All these organisms can invade skin, lung and brain and are highly neurotropic.

Dr. Ramirez: Fungi, yes, but the classic skin lesion of *C. neoformans* is umbilicated papules. Mucormycosis does not produce a chronic condition. *Aspergillus* was mentioned earlier, but dismissed because there was a lack of wheezing. That would be associated with acute bronchopulmonary aspergillus, which is not relevant here. Mycobacteria, yes, but what kind of Mycobacteria? Not *M. marinum* or *M. ulcerans* because those are localized infections while *M. tuberculosis* should be considered because it is

a systemic disease, which this woman has. In my mind, I categorize the etiology of chronic skin ulcers the same way I do fever of unknown origin. (Box)

Considering what pathogen causes chronic skin ulcers and is part of a systemic infection is an approach that narrows the differential considerably. The chronology of events is such that the ulcers preceded the immunosuppressives she was given. They changed the natural course of her disease. The biopsies have essentially ruled out cancer.

Dr. Anupama Raghuram (ID faculty): Determining the timing of events is important in this case. In my mind, there are three groups in which these events could be categorized. First, if we consider the skin lesions, lung lesions and brain lesions as part of the same continuum, there are not many infectious agents that would cause all three components together in a nine-month span. We have already mentioned histoplasmosis, blastomycosis, aspergillosis and nocardiosis. Another presentation that would explain a more acute/subacute onset of concomitant skin, lung and brain lesions would be endocarditis with metastatic foci of infection. Rarely, one could consider central nervous system toxoplasmosis as an explanation for the patient's ring-enhancing brain lesions; however, lung and skin involvement with *Toxoplasma* is unusual. Second, if we consider that the original skin lesions were related to a non-infectious etiology, such as an autoimmune etiology or malignancy, and that the patient then became immunosuppressed due to that underlying condition in addition to being on immunosuppressant medications, then we would need to think of infectious agents that would cause only lung and brain lesions in the immunocompromised host. Some considerations would include tuberculosis, aspergillosis, mucormycosis, cryptococcosis, and nocardiosis. Third, her chronic condition could be unrelated to her acute worsening status. She could have acquired an acute viral syndrome (e.g. influenza, herpes simplex virus encephalitis) responsible for her acute decompensation.

Dr. Barbara Wojda (ID faculty): Pyoderma gangrenosum usually begins as a pustule, then spreads concentrically undermin-

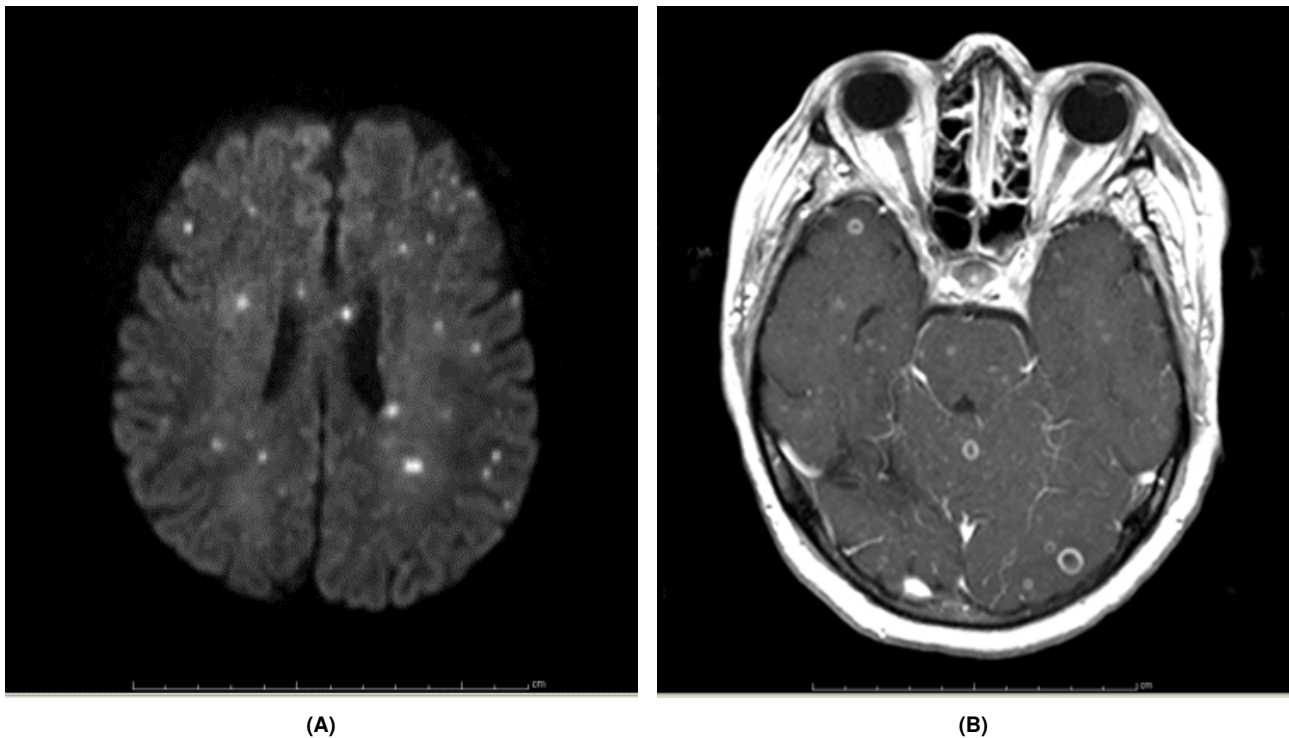


Fig. 2 MRI of the brain on hospital day No. 4 showing too numerous to count post-contrast, ring-enhancing lesions with axial diffusion weighted imaging (**Panel A**), and T1 with contrast enhancement (**Panel B**) throughout the supratentorial and infratentorial brain.

ing healthy skin, and then the lesion ulcerates. The edges are violaceous with margins of erythema. The center of the lesion has necrotic tissue with blood and exudate. It is associated with inflammatory bowel disease, but also can be triggered by trauma. It is very painful. I remember two cases, one presented from a wound care center and another after breast reconstruction surgery. Both were triggered by trauma, and both patients had pain out of proportion to what was expected after surgical intervention. It is important to note that surgery is contraindicated. The patient from the wound care center healed on topical steroids, while the patient with breast reconstruction was more complex and healed only after referral to UofL Dermatology where she was treated with systemic immunosuppression.

Bullous pemphigoid lesions are associated with antibodies that form against basement membrane. It is seen in patients who are elderly or have an autoimmune disorder. Typically, it consists of tense vesicles and bullae on normal appearing or slightly erythematous skin. It is not tender but might be associated with pruritus. As lesions evolve, the tense blisters tend to rupture forming flaccid lesions or erosions with or without a crust. About one third of patients might have oral mucosal lesions. The lesions usually heal without scarring, unless they are surgically altered. They have a predilection for the lower abdomen, groin, and flexor surface of the extremities.

Dr. Ramirez: So this infection seems to have started in the lung and manifested in the skin. She was immunosuppressed and it moved to her brain; if it is a single disease. If it is multiple diseases then anything is possible. The work-up should focus on the

areas involved; CSF and blood. Ultimately, we need tissue - brain biopsy, bone marrow biopsy, bronchoscopy with biopsy. Typical empiric treatment will not likely cover the offending pathogen in this case.

Dr. Puskur: The admission chest X-ray performed at the other facility showed an ill-defined area of increased density around the left hilum with clear periphery. The heart size was normal with a graft noted in the descending aortic artery. The chest CT scan on the day of transfer showed airspace opacities scattered throughout the lungs consistent with pulmonary edema. (**Figure 4**)

Dr. Ramirez: The critical imaging is the first chest image, only a chest X-ray in this case, which shows a left hilar mass. The CT scan was taken on the 6th day of hospitalization. By this time, it may be showing a hospital-acquired pneumonia covering up the original opacity, but if you focus on the hilum we see something and we don't know if it is acute or chronic.

Dr. Puskur: Dermatology was consulted to perform punch biopsies from the left forearm. Neurosurgery was consulted to evaluate the patient for a brain biopsy. Ophthalmology was asked to see the patient by neurosurgery pending brain biopsy since the LP yielded an elevated opening pressure of 28 mm Hg. Wound cultures from right shoulder returned as *Stenotrophomonas maltophilia*.

Dr. Ramirez: Does this explain anything? What do you think? Considering that this is a chronic infection, the *Stenotrophomonas* does not explain anything. You said that oph-

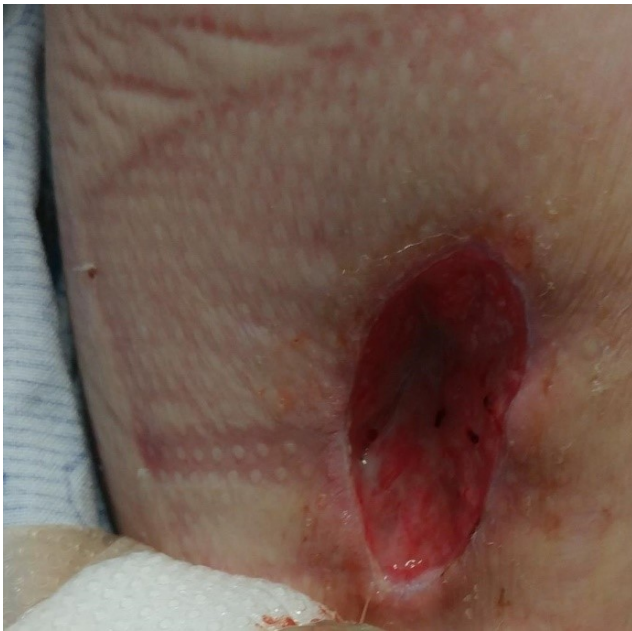

Fig. 3 Chronic ulcer on the medial aspect of the patient's upper right arm.

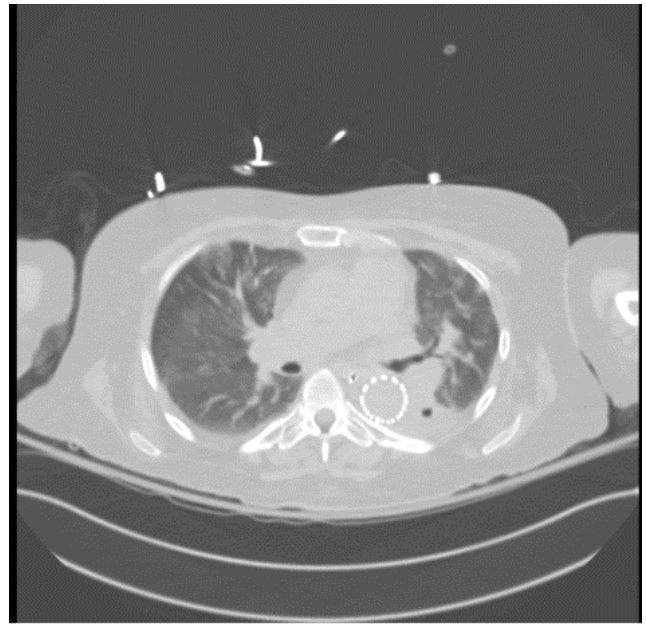


Fig. 4 Chest CT obtained on day of admission to this hospital showing a cavitary lesion in left lung with infiltrate and an effusion, and a minimal right lung effusion.

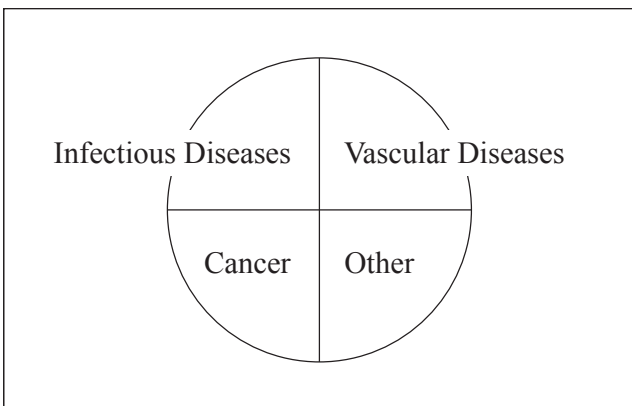
thalmology was called by neurosurgery prior to performing a brain biopsy. Why was that?

Dr. Puskur: To ensure that there was no papilledema or increased CSF pressure present prior to doing a brain biopsy.

Dr. Ramirez: Did she not just have an LP? Is having increased CSF pressure a contra-indication to performing a LP?

Dr. Ramachandrani: Yes, because herniation of the brain may occur.

Dr. Ramirez: No, if there is an imbalance in the pressure then an LP should not be performed. Papilledema in one eye tells you that the pressures are different inside the head and herniation is possible. On the other hand, consider the CSF pressure in a patient with cryptococcal meningitis. It is increased, perhaps 50 mm Hg, and the indication is to do an LP because the pressure is evenly distributed.



Box

3 Clinical Diagnosis

A single infection, such as *Nocardia asteroides* or *Blastomycosis dermatitidis*, causing lung, brain and skin lesions.

4 Hospital Course

Dr. Puskur: The patient was not found to have evidence of papilledema, but was noted to have multiple, small ½ to ¼ disc diameter shaped lesions throughout the periphery and posterior poles of both eyes (right > left). (Figure 5) There was also a large, elevated subretinal mass with surrounding hemorrhage. Ophthalmology obtained vitreous samples of both eyes for bacterial, fungal and AFB cultures, which returned negative. The patient had two LPs at our facility showing quite different total white blood cell values; 858 cells (82% neutrophils) and 38 cells (38% neutrophils), respectively. The other values were similar; glucose ~70 mg/dL, protein ~90 mg/dL. A panel was ordered for several pathogens for PCR in CSF. (Table 2)

A bronchoscopy with bronchoalveolar lavage showed pink, cloudy fluid with 151 white blood cells (64% neutrophils, 26% lymphocytes, 10% monocytes). The Gram's stain did not show any white blood cells or organisms. Fungal smear and AFB stain were both negative. Three additional AFB stains from tracheal aspirates were negative as well.

Neurosurgery performed a stereotactic needle biopsy of two brain lesions in the right parietal lobe. Blood was negative for HIV antibody/antigen, toxoplasma antibodies and an interferon gamma-related assay. Urine was negative for pneumococcal, *Histoplasma* and *Legionella* antigens.

Table 2 Panel of pathogens tested in cerebrospinal fluid by PCR.

Pathogen	Result
Cytomegalovirus	negative
<i>Cryptococcus neoformans/gatti</i>	negative
Enterovirus	negative
<i>Escherichia coli</i>	negative
Herpes simplex virus 1, 2	negative
Human herpesvirus 6	negative
<i>Listeria monocytogenes</i>	negative
<i>Neisseria meningitidis</i>	negative
Parechovirus	negative
<i>Streptococcus agalactiae</i>	negative
<i>Streptococcus pneumoniae</i>	negative
Varicella-zoster virus	negative

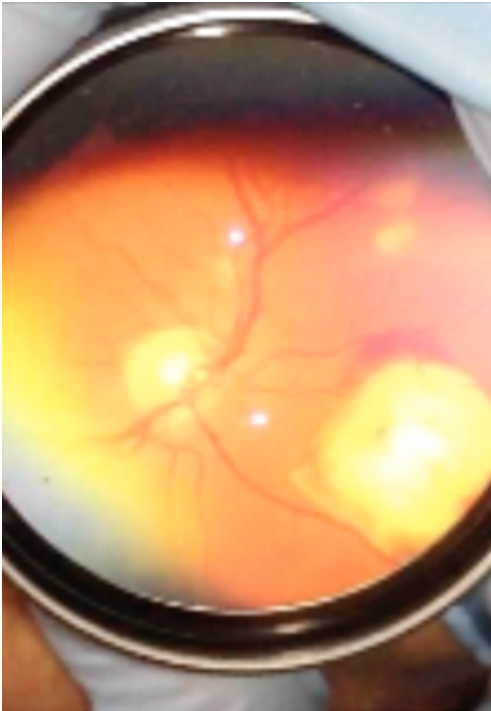


Fig. 5 View of retina with multiple lesions throughout the periphery and posterior pole of the right eye.

5 Additional Discussion

Dr. Carmen Sciortino (microbiologist): This patient underwent a traumatic experience, a car accident, and has undergone several surgeries due to that event. Since she is immunocompromised, there are a number of fungi from hyaline to black molds that could have been introduced during this experience, and thus cause chronic skin ulcers with dissemination to the brain and lung, resulting in the ulcerations seen in the radiographs. Of the hyaline molds, *Sporothrix* complex is one that is common to this area and can produce non-healing cutaneous ulcerations, with similar lesions in the brain and the lung.¹⁻³ *Fusarium*, and *Trichoderma* can have similar pathophysiology.¹⁻³ Of the black molds that cause chromoblastomycosis, the most common ones in this area are *Scedosporium*, *Ramichloridium* and *Cladophialophora* sp.^{1,2,4-7} Rarely the black molds, *Fonsecaea pedrosoi* and *Ochroconis gallopava*^{4,5,8}, may also invade the skin and lungs, but infrequently cause brain abscess^{1,3}. Pathological examination of the

biopsy from the cutaneous ulcer, in most cases would have revealed fungal mycelia. In the absence of this finding, this would decrease the likelihood of one of these molds as causing the patient's disease. Remember, *Sporothrix* is dimorphic, being a yeast at body temperature and a mold at room temperature in our laboratory.

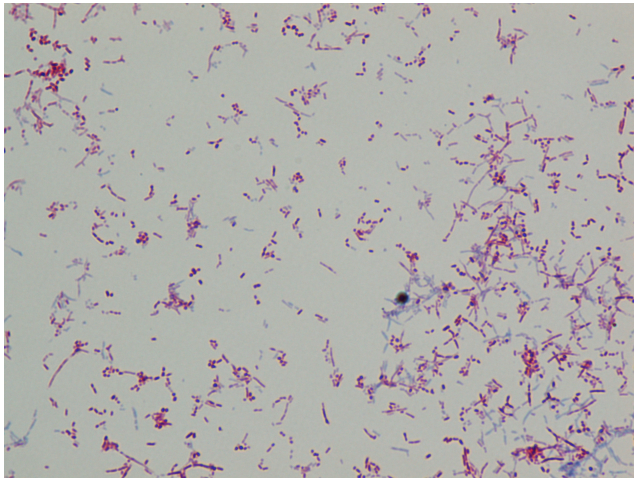
Fungal infectious disease differentials often fail to consider a fungal source other than the endemic *Aspergillus*, *Histoplasma*, *Cryptococcus*, and *Blastomyces*.³ In a similar type of pathogenesis as those fungi, the above mentioned fungal spores can be inhaled, causing pulmonary involvement first, followed by dissemination to the brain and cutaneous regions. Most medical texts in their description of pathogenesis of these fungi, begin with direct cutaneous inoculation then dissemination, but spore inhalation is a rare, but evident source of disease acquisition. In this scenario, which came first inoculation or inhalation? It is my belief that the source of inoculation and disease progression may depend upon the historic source of patient exposure and the immunocompetency of the individual.

Dr. Ramachandrani: Given that 1,3 β -D glucan test, galactomannan assay, cryptococcal antigen, interferon gamma-release assay, *Blastomyces* antibody and urine *S. pneumoniae*, *Legionella* and *Histoplasma* antigens were negative – *Nocardia* seems to be highly likely given the patient's immunocompromised state and subacute to chronic indolent course of infection.

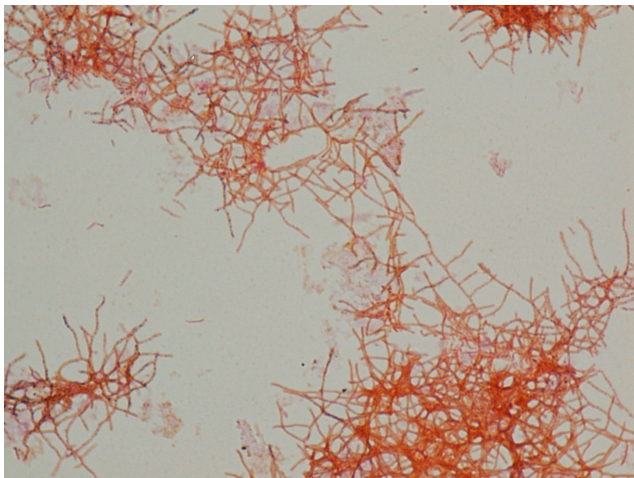
6 Microbiological and Pathological discussion

Dr. Puskur: The skin biopsy was consistent with scar tissue. There was focal perivascular inflammatory infiltrate that was predominantly lymphoplasmacytic with no sign of blistering disease. An independent dermatopathological evaluation of the left forearm was nonspecific. It noted features within both the epidermis and dermis that were compatible with tissue repair changes expected to be adjacent to an ulcerative process.

The immediate Gram's stain from the brain biopsy had no white blood cells or organisms, but growth at 48 hours showed Gram-positive rods that were weakly acid-fast positive with Kinyoun stain. (**Figure 6**) Growth from the culture plate showed a branching morphology with Gram's stain, which were ultimately *Nocardia farcinica*. (**Figure 6**) Fungal smear and culture were negative.



(A)



(B)

Fig. 6 Growth of brain biopsy at 48 hours showing Gram-positive rods that are weakly acid fast positive with Kinyoun (acid-fast) stain. **(Panel A)** Normal tissue is usually blue, but the pink is the result of the presence of a partially acid fast organism. Growth from the culture plate showing branching Gram-positive rods with an over-decolorized Gram's stain. **(Panel B)**

Examination of histological sections showed numerous branching filamentous organisms and weakly acid-fast organisms that were morphologically compatible with *Nocardia* organisms. (Figure 7) It also showed reactive astrocytes. (Figure 7)

Pathology of bronchoalveolar lavage was negative for malignant cells, and showed benign bronchial cells with degenerative changes and pulmonary macrophages. Growth from the tracheal aspirate done on the second hospital day was identified a month later as *Nocardia farcinica*.

7 Discussion of Management

Dr. Puskur: The patient was immunocompromised and considered to have life threatening severe nocardiosis with disseminated disease including central nervous system involvement, pulmonary lesions, skin lesions as well as chorioretinitis, therefore she was given a three-drug antimicrobial regimen.⁹ It included trimethoprim/sulfamethoxazole, imipenem and intravenous amikacin. She also received an intravitreal injection of amikacin bilaterally. The susceptibility results to *Nocardia farcinica* returned a month later showing sensitivity to trimethoprim/sulfamethoxazole and amikacin, but intermediate susceptibility to imipenem, hence imipenem was substituted with amoxicillin/clavulanate to complete six weeks. At that time her mental status and MRI improved markedly. The plan is to continue trimethoprim/sulfamethoxazole for at least six to twelve months.

8 Anatomical Diagnosis

Nocardiosis due to *Nocardia farcinica*

This case was presented at the University of Louisville Division of Infectious Diseases Patient Management Conference.

Acknowledgements: The authors would like to thank Sidharth Puri, MD and Amir Hadayer, MD from the Kentucky Lions Eye Center, University of Louisville, Louisville, KY for their contribution for their image and accompanying text.

References

- 1 J. B. Varkey and J. R. Perfect, "Rare and emerging fungal pulmonary infections," in *Seminars in respiratory and critical care medicine*, vol. 29, no. 02. © Thieme Medical Publishers, 2008, pp. 121–131.
- 2 T. Walsh, A. Groll, J. Hiemenz, R. Fleming, E. Roilides, and E. Anaissie, "Infections due to emerging and uncommon medically important fungal pathogens," *Clinical Microbiology and Infection*, vol. 10, no. s1, pp. 48–66, 2004.
- 3 R. J. Hamill, "Fungal infections of the central nervous system," in *Clinical Mycology*, E. J. Anaissie, Ed. Edinburgh, Scotland: Elsevier Inc., 2009, ch. 28, pp. 591–607.
- 4 F. Queiroz-Telles, S. de Hoog, D. W. C. Santos, C. G. Salgado, V. A. Vicente, A. Bonifaz, E. Roilides, L. Xi, C. d. M. P. e Silva, M. B. da Silva *et al.*, "Chromoblastomycosis," *Clinical Microbiology Reviews*, vol. 30, no. 1, pp. 233–276, 2017. [Online]. Available: <https://doi.org/10.1128/CMR.00032-16>
- 5 S. G. Revankar, D. A. Sutton, and M. G. Rinaldi, "Primary

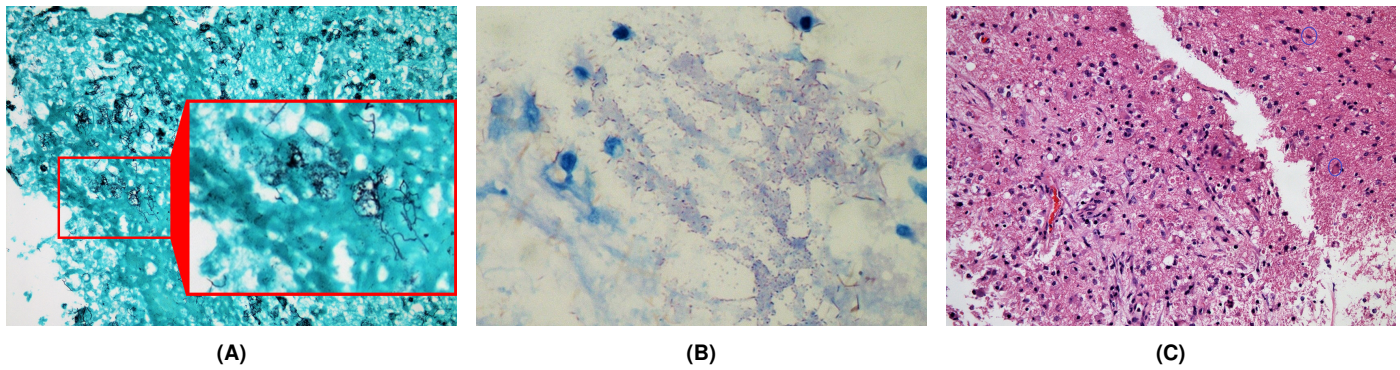


Fig. 7 Gomori Methenamine Silver (GMS) stain of brain biopsy with numerous branching filamentous organisms. (surrounded by a red rectangle in **Panel A**) The acid-fast stain is weakly positive for thin, beaded and slightly branching rods. (**Panel B**) Fragments of brain white matter that show necrotic debris and inflammatory cell infiltration; predominantly macrophages, with scattered reactive glial cells with some reactive astrocytes as well. (40x) (circled in **Panel C**)

- central nervous system phaeohyphomycosis: a review of 101 cases,” *Clinical Infectious Diseases*, vol. 38, no. 2, pp. 206–216, 2004.
- 6 A. Fothergill, “Identification of dematiaceous fungi and their role in human disease,” *Clinical infectious diseases*, vol. 22, no. Supplement 2, pp. S179–S184, 1996.
 - 7 T. P. Levin, D. E. Baty, T. Fekete, A. L. Truant, and B. Suh, “Cladophialophora bantiana brain abscess in a solid-organ transplant recipient: case report and review of the literature,” *Journal of clinical microbiology*, vol. 42, no. 9, pp. 4374–4378, 2004.
 - 8 A. L. Santos, V. F. Palmeira, S. Rozental, L. F. Kneipp, L. Nimrichter, D. S. Alviano, M. L. Rodrigues, and C. S. Alviano, “Biology and pathogenesis of *fonsecaea pedrosoi*, the major etiologic agent of chromoblastomycosis,” *FEMS microbiology reviews*, vol. 31, no. 5, pp. 570–591, 2007.
 - 9 B. A. Brown-Elliott, J. M. Brown, P. S. Conville, and R. J. Wallace, “Clinical and laboratory features of the nocardia spp. based on current molecular taxonomy,” *Clinical Microbiology Reviews*, vol. 19, no. 2, pp. 259–282, 2006.