

University of Louisville

## ThinkIR: The University of Louisville's Institutional Repository

---

Electronic Theses and Dissertations

---

12-2006

### Implant esthetics using a Nobel Replace Standard implant vs. Nobel Perfect Scalloped implant placed in immediate extraction sockets in the esthetic zone of the maxilla.

John W. McGehee  
*University of Louisville*

Follow this and additional works at: <https://ir.library.louisville.edu/etd>

---

#### Recommended Citation

McGehee, John W., "Implant esthetics using a Nobel Replace Standard implant vs. Nobel Perfect Scalloped implant placed in immediate extraction sockets in the esthetic zone of the maxilla." (2006). *Electronic Theses and Dissertations*. Paper 949.  
<https://doi.org/10.18297/etd/949>

This Master's Thesis is brought to you for free and open access by ThinkIR: The University of Louisville's Institutional Repository. It has been accepted for inclusion in Electronic Theses and Dissertations by an authorized administrator of ThinkIR: The University of Louisville's Institutional Repository. This title appears here courtesy of the author, who has retained all other copyrights. For more information, please contact [thinkir@louisville.edu](mailto:thinkir@louisville.edu).

**IMPLANT ESTHETICS USING A NOBEL REPLACE STANDARD IMPLANT  
VS. NOBEL PERFECT SCALLOPED IMPLANT PLACED IN IMMEDIATE  
EXTRACTION SOCKETS IN THE ESTHETIC ZONE OF THE MAXILLA**

By

John W. McGehee, Jr.  
DMD, University of Mississippi, 2003

A Thesis  
Submitted to the Faculty of the  
Graduate School of the University of Louisville  
in Partial Fulfillment of the Requirements  
for the Degree of

Master of Science

Program in Oral Biology  
School of Dentistry  
University of Louisville  
Louisville, Kentucky

December 2006



IMPLANT ESTHETICS USING A NOBEL REPLACE STANDARD IMPLANT VS.  
NOBEL PERFECT SCALLOPED IMPLANT PLACED IN IMMEDIATE  
EXTRACTION SOCKETS IN THE ESTHETIC ZONE OF THE MAXILLA

By

John W. McGehee, Jr.

D.M.D., University of Mississippi, 2003

A Thesis Approved on

August 30, 2006

By the following Thesis Committee:

---

Thesis Director

---

---

---

---

## **DEDICATION**

This manuscript is dedicated to all of the people who have supported and encouraged me throughout my life. To my mom and late father, I am eternally grateful for the sacrifices that you both endured to allow me to pursue my goals. None of this would have been possible without your guidance, love, and support. Thanks to Julie, Donovan, and Emma Grace for your unconditional love and encouragement. To Melissa, thank you for your never-ending love and support and for the joy that you bring to each day of my life. I love each and every one of you and am eternally grateful to have such a wonderful family.

## ACKNOWLEDGEMENTS

I would like to express my sincere gratitude to the following individuals:

Dr. Henry Greenwell, Program Director of Graduate Periodontics, for his unending dedication to making the most of my training experience, the long hours he dedicated in preparing this thesis, and the guidance that he has and I am sure will continue to give me.

Dr. Margaret Hill, Assistant Program Director, for her unrelenting support of the other residents and myself, and the kindness that she and Regan have shown to Melissa and me.

Dr. James Scheetz, Ph.D., Statistician, for his dedication to the field of statistics and assistance with the analysis of the data from this study.

I would also like to thank the following people for the contribution that each of them made in the restorative aspects of this study: Dr. Jack Edge, Dr. David Jones, Chris Morris CDT, Dr. John Olson, Dr. Melinda Paris, and Dr. Robert Zeena.

## **ABSTRACT**

### **IMPLANT ESTHETICS USING A NOBEL REPLACE STANDARD IMPLANT VS. NOBEL PERFECT SCALLOPED IMPLANT PLACED IN IMMEDIATE EXTRACTION SOCKETS IN THE ESTHETIC ZONE OF THE MAXILLA**

John W. McGehee, Jr. , DMD

August 30, 2006

**Aims.** The primary aim of this study was to compare esthetic outcomes for the Nobel Replace Standard implant vs. the Nobel Perfect Scalloped implant as determined by hard and soft tissue measurements and objective and subjective esthetic indices.

**Methods.** 18 patients with a tooth in the maxillary esthetic zone scheduled for replacement with an immediate implant who had at least one adjacent tooth were included in the study. Nine test patients received a Nobel Perfect scalloped platform implant and 9 positive control patients received a Nobel Replace 2-stage flat platform implant. Prior to suturing a fixture level impression was taken to allow provisional fabrication by a laboratory. Implant uncovering and provisionalization occurred at 2 months after fixture placement. Final impressions were taken at 4 months and the final crown was placed at 6 months.

**Results.** Implants platforms were placed a mean of 2.5 to 3.0 mm apical to the facial gingival margin, a mean of about 1.5 mm coronal to the facial osseous margin, and

a mean of about 2.0 mm from the adjacent tooth. There was a statistically significant mean loss of osseous height on adjacent teeth of about 1.5 mm ( $p < 0.05$ ). with no significant differences between scalloped and standard groups ( $p > 0.05$ ). The osseous crest to contact distance was a mean of about 5.5 to 6.0 mm at crown placement with no significant differences between groups ( $p > 0.05$ ). There was minimal facial recession of about 0.3 mm at the time of crown placement and the gingival margin was harmonious with adjacent teeth 78% of the time for both scalloped and standard groups. A papilla completely filled the embrasure space in 11 of 17 sites for the scalloped group and in only 2 of 18 sites for the standard group. Thus there was papilla harmony with adjacent teeth 67% of the time for the scalloped group and only 33% of the time for the standard group. Subjective visual analog scores by the patient ranged from 98 to 99 for the scalloped group and from 93 to 94 for the standard group.

**Conclusions.** Adjacent tooth interproximal bone loss and crest to contact distance were more than desirable but similar for both the scalloped and the standard groups. Despite this finding there was a substantially higher incidence of complete papilla formation and papilla harmony for the scalloped group. Subjective patient determined visual analog scores were consistently higher for the scalloped group. Thus there was a trend toward better esthetics with the scalloped implant at the time of crown placement.



## TABLE OF CONTENTS

	PAGE
ACKNOWLEDGEMENTS .....	iv
ABSTRACT .....	v
LIST OF TABLES .....	ix
LIST OF FIGURES .....	x
CHAPTER	
I. LITERATURE REVIEW	
Introduction .....	1
Compromises in Esthetic Implant Placement .....	2
Kois's Diagnostic Keys to Implant Esthetics .....	3
Implant Biologic Width .....	10
Scalloped Implant Rationale .....	11
Incision/Access Techniques .....	12
Papilla Reconstruction Techniques .....	17
Biotype Enhancement .....	21
Emergence Profile .....	22
Platform Switching .....	24
Platform Selection .....	24
Implant Provisionalization Effect on Papilla Preservation .....	26
Timing of Final Restoration Placement .....	31
Objective Evaluation of Esthetics .....	33
Subjective Evaluation of Implant Success .....	40
Conclusion .....	43
II. MATERIALS AND METHODS	
Study Design .....	48
Patient Selection: Inclusion and Exclusion Criteria .....	50
Post-Surgical Exclusion .....	50
Pre-surgical Management .....	51
Clinical Measurements .....	51
Radiographic Measurements .....	51
Pre-Surgical Measurements at the Tooth to be Replaced .....	52

Surgical treatment.....	52
Surgical Implant Site Measurements.....	54
Restorative Treatment .....	55
Restorative Measurements .....	56
Esthetic Measurements.....	57
Statistical analysis .....	57
III. RESULTS .....	58
IV. DISCUSSION.....	70
V. CONCLUSIONS.....	75
REFERENCES .....	79
APPENDICES .....	85
CURRICULUM VITAE.....	96

## LIST OF TABLES

TABLE	PAGE
1. Jemt Papilla Index Scoring System.....	2
2. Nordland and Tarnow Papilla Classification System .....	3
3. Effect of Distance from Crest to Contact Point on Interdental Papilla Presence.....	4
4. Crest to Contact Distance and Papilla Presence for Implants with Adjacent Teeth .	5
5. Vertical and Horizontal Distances and Papilla Presence for Implants and Teeth.....	6
6. Critical Osseous Crest to Contact Distances for Implants, Teeth and Pontics .....	7
7. Facial and Interproximal Osseous Crest Position .....	10
8. Crestal Loss for Papilla Preserving vs. Non-Papilla Preserving Incisions .....	16
9. Gingival Recession Around Implants up to 1 Year after Uncovering.....	31
10. Site Distribution for Implant Recession up to 1 Year after Uncovering .....	32
11. Mean Recession Around Standard and Wide Diameter Implants Over Time .....	33
12. Levin's Esthetic Examination .....	34
13. Levin's Esthetic Success Ratings.....	35
14. Pink Esthetic Score.....	36
15. Implant Esthetic Score.....	38
16. Implant Crown Esthetic Score.....	39
17. Apicocoronal Placement of Immediate Implant Platform with Flap vs. No Flap ....	45
18. Buccolingual Placement of Immediate Implants.....	46
19. Implant Placement Data .....	62
20. Bone Loss on Adjacent Teeth .....	63
21. Emergence Profile Dimensions, Facial Recession, and Black Triangle .....	64
22. Important Dimensions for Papilla Presence .....	65
23. Objective and Subjective Esthetic Evaluations .....	66
24. Jemt Papilla Index Stratified by $\geq 50\%$ or $< 50\%$ Papilla.....	67
25. Papilla and Gingival Margin Harmony Prevalence.....	68
26. Clinical Indices and Keratinized Tissue at Final Restoration Placement.....	69
27. Jemt Papilla Index Data from Previous Studies .....	76

## LIST OF FIGURES

FIGURE	PAGE
1. Study Design.....	49
2. Scalloped Implant: Pre-op and Final Restoration.....	77
3. Standard Implant : Pre-op and Final Restoration.....	78

## **CHAPTER I**

### **LITERATURE REVIEW**

The primary objective of implant therapy has traditionally been to achieve osseointegration and improve function. Many studies have demonstrated the predictability and success rates of implant therapy. In an analysis of five different two-stage implant systems, Rosenberg et al. (1998) showed an overall success rate of 93% with a range from 85% to 95% between different systems. Immediate implants have been shown to have similar rates of success while decreasing the amount of time required between tooth loss and implant restoration (Gelb 1993; Schwartz-Arad et al. 2000; Gomez-Roman et al. 2001). Even though osseointegration and improved function remain a priority in contemporary implant therapy, there is an increasing demand for harmony between the peri-implant gingiva and adjacent teeth. Unfortunately, bone resorption is common following tooth removal, compromising the site for the eventual implant supported restoration. The osseointegration of dental implants has become a predictable procedure, but an implant that is osseointegrated does not always translate to esthetic success. Loss of interdental papillary height and facial recession is often the sequella of implant placement. This loss creates cosmetic concerns for patients. When placing implants in the esthetic zone, preserving facial tissue and interproximal papilla to produce a harmonious gingival contour has proven to be a formidable challenge.

## Compromises in Esthetic Implant Placement

When Goodacre et al. (1999) assessed long term complications with anterior single tooth implants, gingival recession was the most common factor associated with anterior single tooth implants. The occurrence of recession around implants can result in restorations that appear too long or, in extreme cases, visibility of the metal surface of the abutment or implant. Another complication that can occur, especially when there are adjacent implants, is loss of papilla height. This results in an empty space apical to the contact point commonly referred to as a “black triangle” which can severely compromise a patient’s esthetics. In order resolve the black triangle, restorative dentists commonly resort to increasing the length of the contact point. This causes asymmetry in the appearance of the teeth and papilla that is easily visible, even to the untrained eye.

Over recent years much attention has been paid to understanding factors that affect the occurrence of recession and loss of papilla height around implants. In an effort to allow for a more objective evaluation of papilla loss, Jemt (1997) published a papilla index scoring system. The scoring criteria are explained in Table 1.

**Table 1: Jemt Papilla Index Scoring System**

Score 0	No papilla is present
Score 1	Less than half of the papilla is present
Score 2	At least half of the papilla is present but the papilla tip does not extend to the interproximal contact point
Score 3	Papilla completely fills the embrasure space and is harmonious with the adjacent papillae
Score 4	The papilla is overfilling the embrasure and covering the adjacent crown

\* Jemt (1997)

Nordland & Tarnow (1998) also described a classification system for loss of papillary height which is explained in Table 2.

**Table 2: Nordland and Tarnow Papilla Classification System**

Class I Papilla	The papilla tip is located between the interproximal contact point and the most coronal aspect of the interproximal CEJ.
Class II Papilla	The papilla tip is located at or apical to the interproximal CEJ but coronal to the “apical extent of the facial CEJ”
Class III Papilla	The papilla tip lies at the same level or apical to the facial CEJ

\* Nordland & Tarnow (1998)

### **Kois’s Diagnostic Keys to Implant Esthetic**

As a result of the focus that has been paid to implant esthetics, a greater understanding of the parameters affecting esthetic outcomes has been attained and predictability has improved. In an attempt to present a simplified approach to identifying sites that were at risk for the occurrence of papilla loss and recession, Kois (2001) outlined 5 diagnostic keys for single tooth implant esthetics.

The first key that Kois (2001) described was relative tooth position, which refers to evaluation of the tooth in 3-dimensions relative to the adjacent teeth and surrounding periodontium. Replacement of labioverted teeth can result in unfavorable esthetics due to the likelihood of the presence of a dehiscence defect covering the radicular surface of the tooth. Implant placement in a site with this type of facial defect may result exposure of the coronal portion of the implant due to a loss of facial plate height and width. A lingually displaced tooth, on the other hand, would be a more predictable option due to the possibility of a thicker and more coronally located buccal plate.

Another factor important in evaluating potential sites for implant placement is the location of the desired interproximal contact point relative to the interproximal crest. Tarnow et al. (1992) were the first to identify a relationship between the distance from contact point to alveolar crest and the presence or absence of a papilla. In a prospective clinical study of natural teeth in periodontitis patients, Tarnow et al. (1992) demonstrated that when the distance from contact point to crest, as determined by sounding, was 3 to 5 mm, the papilla was present approximately 99% of the time. When this distance increased to 6 mm, papilla presence decreased to 56% and the presence dropped to  $\leq 27\%$  when this distance was 7 mm to 10 mm (Table 3).

**Table 3: Effect of Distance from Contact Point to Crest  
on Interdental Papilla Presence**

<b>Distance from contact point to crest (mm)</b>	<b>3</b>	<b>4</b>	<b>5</b>	<b>6</b>	<b>7</b>	<b>8</b>	<b>9</b>	<b>10</b>
Percent of time papilla was present (%)	100	100	98	56	27	10	25	0
Number of Sites	2	11	73	112	63	21	4	2

\*Tarnow et al. (1992)

Choquet et al. (2001) analyzed the contact point to crest relationship for implants adjacent to natural teeth. In clinical and radiographic study, Choquet et al. (2001) determined that when the distance from contact point to crest was  $\leq 4$  mm the papilla was present 100% of the time. When the distance was 5 mm, the papilla was present 88% of the time. When the distance was 6 to 10 mm the incidence of papilla ranged from 50% to 75%.



**Table 4: Effect of Distance from Contact Point to Crest on Peri-implant Papilla Presence Adjacent to Natural Teeth**

<b>Distance from contact point to crest (mm)</b>	<b>&lt; 3</b>	<b>3</b>	<b>4</b>	<b>5</b>	<b>6</b>	<b>7</b>	<b>8</b>	<b>9</b>	<b>10</b>
Percent of time papilla was present (%)	100	100	100	88	50	75	50	50	75
Number of Sites	1	5	7	17	8	4	4	2	4

\*Choquet et al. (2001)

Gastaldo et al. (2004) evaluated implants adjacent to natural teeth and reported a papilla incidence of 100%, when the contact point to crest distance was 3 mm to 4 mm, and an incidence of 80% when the distance was 5 mm. When the contact point to crest distance was 6 mm to 10 mm the papilla incidence ranged from 25% to 40%. (Table 5).

Tarnow et al. (2000) in a landmark study evaluated peri-implant bone loss that occurred after placement of adjacent implants. Radiographic measurements of adjacent implants 1 to 3 years post-placement demonstrated 1.34 and 1.40 mm of lateral bone loss from the implant shoulder. The most significant finding of this study was that when the implants were < 3 mm were apart, lateral bone loss overlapped causing a mean crestal loss of 1.04 mm. When the implants were > 3 mm apart only 0.45 mm of mean crestal loss occurred.

Gastaldo et al. (2004) also reported that with adjacent implants, the papilla incidence was 0% when the inter-implant spacing was 2 to 2.5 mm, and 80% when this distance was 5 mm. When the inter-implant distance was 4 mm the papilla incidence was about 71%, and at 4.5 mm it was 48%.

**Table 5: Effect of Vertical and Horizontal Distances Between Implants and Adjacent Teeth on Presence of Papilla**

Vertical Distance from Contact Point to Crest			Horizontal Distance from Implant to Tooth		
Distance (mm)	% Present	# of Sites	Distance (mm)	% Present	# of Sites
3	100	7	2.0	0	10
4	100	24	2.5	0	16
5	80	8	3.0	88	18
6	40	12	3.5	83	18
7	40	16	4.0	75	10
8	40	9	4.5	57	8
10	25	4			

\*Gastaldo et al. (2004)

Other groups have performed similar analysis with similar results. Salama & Salama (2005) have presented their unpublished data of vertical and horizontal distances between implants, teeth and pontics required for papilla presence (Table 6).

**Table 6: Critical Osseous Crest to Contact Distance for Implants, Teeth and Pontics for Esthetic Implant Placement and Restoration to maintain a Normal Papilla-Contact Relationship**

	<b>Interproximal bone horizontal dimension</b>	<b>Interproximal bone to contact vertical distance</b>
Tooth to tooth	1.0 mm	5.0 mm
Tooth to pontic	N/A	6.5 mm
Tooth to implant	1.5 mm	4.5 mm
Implant to implant	3.0 mm	3.5 mm
Implant to pontic	N/A	5.5 mm
Pontic to pontic	N/A	6.0 mm

\*Salama & Salama (2005)

From these studies several conclusions can be drawn. First, the presence or absence of a papilla is determined by the distance from contact point to bone. However, an interaction exists between horizontal and vertical distances. This distance is established by whether the adjacent structure is a tooth, implant or pontic.

The second key that Kois (2001) outlined was form of the periodontium. Ochsenein & Ross (1969) first classified the periodontium as being flat or pronounced scalloped. Eventually "scalloped" became included in this classification scheme to describe those biotypes that were in not flat or pronounced scalloped. Becker et al. (1997) evaluated the maxillary anterior segment in Caucasian skulls and categorized them by morphotype. The mean distance from the interdental bone to the midbuccal alveolar crest

among the three osseous morphotypes was 2.1 mm for the flat morphotype, 2.8 mm for the scalloped morphotype, and 4.1 mm for pronounced scalloped.

The significance of this grouping relates to Kois's third and fourth keys which were periodontal biotype and tooth shape. The periodontium is generally considered to be thick or thin. Weisgold (1977) considered the thin periodontium to be susceptible to facial recession and interproximal papilla loss and the thick biotype more susceptible to pocket formation due to apical migration of the junctional epithelium. Teeth have 3 shapes: square, ovoid, and triangular or tapered. Tooth shape influences soft tissue in two ways. Coronal to the gingival margin, tooth shape determines the interproximal embrasure space and contact length. Square teeth tend to have short embrasures and long contact points that extend more apically. On the other hand, triangular shaped teeth tend to have long embrasure spaces due to short contact points located more coronally. Apical to the gingival margin, tooth shape influences the interproximal septum width and papilla support. The root surfaces of triangular teeth are frequently located farther apart than those associated with square teeth.

Olsson et al. (1993) examined the relationship between periodontal form, biotype and tooth shape in Swedish teenagers. After correcting for incisal wear, the subjects with the 10 highest and 10 lowest crown width to length ratios were assigned as having short-wide and long-narrow crown form, respectively. Individuals with a long-narrow crown form were found to have a more pronounced scalloped periodontal form with shallower probing depths than patients with short-wide crowns. No difference in gingival thickness was detected when measured with a disposable syringe inserted through the tissue at the probed pocket depth at the mid-facial of the tooth.

In a case series, Kan et al. (2003) evaluated mucosal dimensions determined by sounding around maxillary single implants placed in edentulous sites. Only central incisors, lateral incisors and canines were included. Implants had been in function for a mean of 32.5 months with a range of 12 to 78 months. Of the 45 implants analyzed, the peri-implant biotype was categorized as thick for 28 of the implants and thin for 17. For teeth adjacent to the implant, the mean proximal sounding measurements were 4.20 mm mesially and distally. For the implants, the mean sounding measurement was 6.16 mm on the mesial, 5.93 mm on the distal and 3.63 mm for the mid-facial. When sounding measurements were stratified with regard to biotype, a significant difference in mucosal dimensions for thick versus thin biotypes was detected. For teeth mesial to the implant, the mean proximal sounding measurement for thick biotypes was 4.46 and in thin biotypes a mean of 3.76 mm was recorded. For teeth distal to the implant, the mean sounding measurement for thick biotypes was 4.45 mm, while in thin biotypes it was 3.79 mm. From this the authors concluded that for thick biotypes, papilla can be maintained or reestablished when the papilla tip is 4.5 mm or less from the underlying bone. In thin biotypes, the papilla will seldom be recreated beyond 4 mm.

The fifth and last of Kois's keys was the position of the osseous crest. Kois (2001) identified 3 variations in the facial osseous crest position relative to the gingival margin in 100 periodontally healthy patients. A normal crest position was described as 3 mm from gingival margin to the facial crest, a high crest was  $< 3$  mm and a low crest was  $> 4$  mm. Interproximally Kois (2001) stated that a distance of 4 mm from the papilla tip to the interproximal crest on the adjacent tooth was normal. Whereas,  $< 4$  mm would be considered a high crest and  $> 4$  mm would be considered to be low (Table 7).

**Table 7: Facial and Interproximal Osseous Crest Position**

<b>Osseous Crest Position</b>	<b>Facial Measurements</b>	<b>Interproximal Measurement</b>
High Crest	< 3 mm from osseous crest to free gingival margin.	≤ 4mm from the osseous crest of the adjacent tooth to the papilla tip.
Normal Crest	3 mm from osseous crest to free gingival margin.	
Low Crest	> 4 mm from osseous crest to free gingival margin.	> 4 mm from the osseous crest of the adjacent tooth to the papilla tip.

\*Kois (2001)

Kois (2001) stated that the greater the distance from gingival margin to facial crest, the more likely that loss of tissue will occur after a surgical procedure resulting in unfavorable implant esthetics. He recommended that orthodontic extrusion be performed if the facial gingival margin locations were in harmony and a distance of 3 mm or greater was present prior to extraction and immediate implant placement. For interproximal distances greater than 4 mm, orthodontic extrusion of the adjacent tooth was recommended.

### **Implant Biologic Width**

Histologic differences in the physiologic architecture of implants and natural teeth result in differences in biologic width dimensions. Listgarten (1966) used electron microscopy to determine that epithelial attachment to natural teeth was facilitated by hemidesmosomes in contact with basal lamina. Schroeder et al. (1981) observed functional hemidesmosomes and basal lamina on titanium-sprayed implants in monkeys. Schroeder (1981) also provided histologic evidence of fibrous connective tissue adherence to the surface of titanium plasma sprayed implants. Bauman et al. (1993)

revealed that in contrast to natural teeth, the collagen fibers associated with implants run parallel to the long axis of the implant.

Gargiulo et al. (1961) published the first study on what would later be termed by in a lecture by D. Walter Cohen (1961) as “biologic width.” In this cadaver study, mean measurements of 0.97 mm junctional epithelial and 1.07 mm connective tissue were reported for a mean biologic width of 2.04 mm. It was noted that a significant range in all three components occurred. When Cochran et al. (1997) did a similar analysis in animals, they showed that implant biologic width dimensions were similar to natural teeth, with 1.88 mm of junctional epithelium and 1.05 mm of connective tissue. These dimensions were proportional to natural teeth but were about 1 mm greater due to an increase in the length of the junctional epithelium.

### **Scalloped Implant Rational**

Implant manufacturers have developed new implant designs that favor preservation of interproximal bone. One such design is the Nobel Perfect produced by Nobel Biocare. The difference in the Nobel Perfect design from traditional flat platform implants is that it has a scalloped platform with the interproximal surface located more coronally than the buccal and palatal surfaces, similar to the CEJ of natural teeth.

The Nobel Perfect implant was designed to establish a similar distance from the implant-restoration junction to the bone circumferentially around the implant, which allows for a sub-marginal restorative margin placement without compromising the interproximal bone levels. By preserving interproximal bone levels, an adequate contact point to crest distance can be maintained to facilitate papilla regeneration. Although this hypothesis has not been proven by scientific studies, case reports have shown promising

results. Leziy et al. (2005) reported on an 18-year-old female who presented with multiple congenitally missing teeth. The patient was described as having a high smile line and thin biotype. She was treatment planned for adjacent implant placement in the areas of #6, 7 and # 10, 11. A flapless incision technique was performed during placement of 4.3 diameter Nobel Perfect (Nobel Biocare) immediate implants. The implant platforms were placed 1.5 mm below the facial gingival margin rather than the manufacturer's recommended 2 to 3 mm due to a smaller than normal contact point to crest distance. This placed the roughened surface and smooth collar junction at the bone crest. Connective tissue grafts were later placed over #6 and 10 implants to alter biotype. Post surgical provisionalization was accomplished with a tooth-born Essix splint. Fixture level impressions were taken at 10 weeks and a fixed provisional was placed 2 weeks later. Provisionals were left in place for a total of 3 months before delivery of the final restoration. Minor crestal remodeling was reported at radiographic evaluation 3 months after final restoration placement and no further changes were reported at 15 months. Clinical photographs showed that the papilla adjacent to and between the implants in the #6 and #7 position were maintained. The authors did not present any long term clinical photos of the implants placed in the #10 and #11 positions which were visible and appeared to be restored in a photo of the patient's smile line taken at the time of 15 month follow-up.

### **Incision/Access Techniques**

Flap access during implant placement increases a surgeon's ability to visualize the occurrence of fenestrations and dehiscences. The problem with flap reflection is disruption of blood supply. Wilderman et al. (1970) performed extensive histologic studies in



humans and animals of bone response to flap reflection and osseous resection. In general, an additional mean loss of 0.5 to 1.0 mm of alveolar crest height occurred, due to periodontal flap surgery and osseous surgery, respectively. Evian et al. (1985) published an early description of a retained papilla procedure for periodontal surgery. Similar procedures have been published including the curtain technique described first by Westcott (1965) and later by Frisch et al. (1967).

In an attempt to objectively evaluate the clinical effects of these procedures on esthetic outcomes, Michaelides & Wilson (1996) compared a papillary retention procedure with a full-thickness flap reflection procedure using internal mattress sutures in periodontitis patients. At reevaluation, no maxillary anterior sites showed greater than 2 mm of papillary height loss over the 1-year time period. Six or 23% of the 26 sites using a full-thickness flap procedure resulted in a 1 to 2 mm loss of papillary height. None of the sites using the papillary retention procedure resulted in a loss of papillary height. Eleven or 42% of the sites that were treated by papillary retention resulted in a 1 to 2 mm of gain of papillary height after 1 year. Similarly, 10 or 45% of the sites treated with full thickness flaps with internal mattress sutures resulted in a 1 to 2 mm gain in papillary height at the end of the 1 year. The authors concluded that the papillary retention technique showed less potential for papillary height loss and more potential for papillary height gain than full-thickness flap with internal mattress sutures.

In order to prevent the loss of hard and soft tissue that occur as a result of implant placement procedures, clinicians have incorporated papilla preservation into implant therapy. This is accomplished by making vertical incisions at the line angles of the tooth to be removed. Papilla preserving incisions allow for preservation of the blood supply to

the interdental papilla while allowing for access and visibility of the facial aspect of the implant site.

Another approach for preservation of peri-implant tissue is use of a flapless technique. Auty & Siddiqui (1999) described the punch technique without flap reflection for delayed placement of submerged or non-submerged implants in the esthetic zone. The authors recommend use of a tissue biopsy punch to incise through the site of desired implant placement. A curette or rongeur was used for removal of the tissue prior to site preparation. In order to detect apical perforation of the drill through the buccal plate, it was also recommended that firm finger pressure be placed on the labial and lingual aspects of the osteotomy site during drilling in order to detect vibration of the drill if contact with the cortical bone occurred (Auty & Siddiqui 1999). In the event that perforation occurred a semilunar or vestibular flap was performed to allow for guided bone regeneration (GBR) around the exposed implant surface.

Recently, Steigmann & Wang (2006) described a similar technique for use in immediate implant placement, which they described as the Esthetic Buccal Flap (EBF). The procedure involved 3 incisions, which included 2 vertically beveled releasing incisions placed in mucosa, and one horizontal incision used to connect the vertical incisions leaving the marginal gingival tissue intact. The horizontal incision was performed in attached gingival approximately 1 to 2 mm coronal to the MGJ but at least 3 mm from the gingival margin in order to ensure that the marginal tissue was not disturbed. After grafting materials were placed over the exposed implant surface, a periosteal releasing incision was made to allow for flap repositioning. The vertical

incisions were first sutured and then the horizontal incision was closed in a tension-free manner to prevent marginal tissue recession.

Several studies have been performed that have objectively evaluated the effect incision techniques on implant esthetic outcomes. Gomez-Roman (2001) compared flap reflection with papilla preserving incisions to flap reflection with non-papilla preserving incisions in 21 patients who received immediate and delayed implants. Seventeen of the implants were placed in the maxilla, while four were placed in the mandible. No patient smoking data was given. Standardized digital radiographs were taken immediately after implant placement, at delivery of the final restoration, and 1 year after crown placement. Interproximal crest height changes were measured radiographically with digital software that was accurate of 0.1 mm. For papilla preserving incisions, the mean interproximal bone loss was 0.29 mm at crown placement and unchanged at one year for a total loss of 0.29 mm. For non-papilla sparing incisions, the mean bone loss was 0.79 mm at crown placement and increased to 1.12 at 1 year after crown delivery. Papilla-preserving incisions resulted in a total of 0.83 mm less bone loss than sites with non-papilla preserving incisions. Weaknesses of this study were that it was: 1) not blinded, and 2) sites were included where the tooth-to-implant distance was less than 1.5 mm. This is in conflict with the protocol established by Tarnow et al. (2000) that stated that a distance of  $\geq 1.5$  mm is necessary between implants and adjacent teeth and  $\geq 3$  mm between adjacent implants to prevent loss of crestal height secondary to implant placement.

**Table 8: Interproximal Crest Loss of Papilla Preserving Incisions vs. Non-Papilla Preserving Incisions**

	<b>Papilla Preserving Incisions</b>	<b>Non-Papilla Preserving Incisions</b>
Mean crestal loss at crown placement	0.29 mm	0.79 mm
Mean crestal loss 1 year after crown placement	0.29 mm	1.12 mm

\* Gomez-Roman (2001)

Covani et al. (2004) reported on 15 immediate implants with a flapless procedure in maxillary and mandibular non-molar sites. Heavy smokers (> 10 cigarettes per day) were excluded. Implants displaying fenestrations, dehiscences, or an implant to bone horizontal defect width > 2 mm were excluded from the study. Six-months post-placement, measurements were repeated and definitive restorations were placed. Acrylic stents were used to detect changes in papilla height. Mean interproximal papilla level at baseline was  $6.24 \pm 0.28$  mm at baseline and  $6.79 \pm 0.30$  at 2nd stage surgery for a relative decrease of 0.55 mm. Width of keratinized tissue at baseline was  $3.57 \pm 0.26$  mm and  $3.54 \pm 0.28$  at 2nd stage surgery for a decrease of 0.03 mm. The mucogingival junction (MGJ) did not show any change with respect to the adjacent teeth. No peri-implant bone defects were detected by probing or radiographs at 6-month reevaluation. In fact, the authors stated that 4 of 15 implants had excessive bone growth over the implant cover screw at the time of uncovering. All implants were deemed successful at 12 months based on Albrektsson's criteria (Albrektsson et al. 1986).

In evaluating the success rate of implants placed with a flapless approach Campelo et al. (2002) performed a retrospective analysis of 770 implants placed in 359 patients over a 10-year period. The implants were placed in both completely and partially edentulous patients restored with both fixed and removable prosthesis. Implants were considered failures if they had mobility or pain, had to be removed or had more than 0.5 mm of bone loss per year and signs of active peri-implantitis. The cumulative success rate after 10 years was over 91%. Over the 10-year period, 49 of 770 implants failed (6%). The failure rate declined each year until it reached 0% in the last year of the study. This fact was attributed to learning curve and patient selection.

The previous studies demonstrate that even when a flapless approach to implant placement, 0.5 mm of bone loss still occurred. As evident from Campelo et al. (2002), a learning curve exists when using a flapless approach. Advantages of flapless implant placement include a reduction in compromise of blood supply delivered to vital structures such as the buccal alveolar plate and interproximal papilla, the potential for decreased time of the procedure, and less post-operative discomfort. Disadvantages include limited visibility of implant site, inability to graft at the time of implant placement, and undetected fenestration of the implant after placement.

### **Papilla Reconstruction Techniques**

Salama & Salama (1995) described the guided soft tissue augmentation technique during stage II surgery used in situations where a vertical soft tissue deficiency would result in a lack of tissue for interdental papilla formation. The procedure was described with multiple adjacent implant placement in an edentulous span. At stage II surgery, a palatal incision was utilized extending to the palatal and interproximal sulci of the

adjacent teeth. After full thickness flap reflection to the labial and partial thickness dissection, healing abutments were placed. The flap was re-approximated and sutured over the healing abutments in order to provide space maintenance. The blood clot that formed was eventually replaced with connective tissue. The authors presented a case in which they performed this procedure but it had not been restored at the time that this article was published.

Grunder et al. (1997) described an inlay graft technique to create papilla between implants at stage-2 surgery. The technique utilized harvesting of a full thickness soft tissue graft from the tuberosity that was placed in a soft tissue deficit that occurred at the time of healing abutment placement. This procedure resulted in an increase in that amount of tissue that could be shaped to the desired form by provisionalization and prevented formation of a soft tissue concavity. The author provides pictures of 2 cases of multiple maxillary implants where this procedure was used between the #8 and #9 positions.

Misch et al. (2004) described the “split-finger” approach for the promote/augment inter-implant papilla formation. A 2 to 3 mm sulcular incision was placed to the palatal side of each adjacent tooth with a loop design placed adjacent to the implant location. The incisions were then joined facially with a semicircular incision at the preplanned tissue margin of the implant crown creating a palatal “finger” of tissue at least 2 to 2.5 mm in width over the implant site. The facial “fingers” were then elevated to the desired height for the papilla and the palatal “finger” was split and reflected to the mesial and distal sides. After placement of an ideally shaped and contoured provisional restoration, the buccal and palatal “fingers” were sutured using a figure-eight horizontal everting

mattress suture. With thin issue, one interproximal suture placed at the base of the papilla was suggested. Misch et al. (2004) stated that this procedure could be used at initial surgery or at stage-2 uncovering. It could also be used in conjunction with soft tissue grafts when more tissue volume is desired.

Misch et al. (2004) evaluated 39 Maestro maxillary implants (Biohorizons, Birmingham, AL: 3.5, 4, and 5 mm diameter) placed in 21 patients at 6 months and 1-year post-restoration. Sixteen of the implant-supported restorations were single units, while the others were multiple units. A total of 60 papillae (32 associated with single implants and 28 associated with multiple implants) were evaluated using the Jemt Papilla Index (Jemt 1997). Results demonstrated that no interproximal sites were classified as 0, 1 or 4. The average score for the 16 single implants and 32 papillae was 3 for mesial papilla and 2.82 for distal papilla. The average for the other implant papilla was 2.7. When an adjacent natural tooth was present, the mean score was 2.5. In the 10 multiple implant sites a mean score of 2.5 was recorded. The authors noted that the highest interimplant score (2.8) was recorded between maxillary central incisor implants for 5 restorations.

Nemcovsky et al. (2000) reported on papilla reconstruction in 32 Israeli patients presenting for second stage surgery 6 to 8 months after implant placement. Thirty-six single implants were exposed in the maxillary anterior and premolar region. The Jemt Papilla Index Score (PIS) was used to evaluate papilla pre- and post-surgery. The technique started with a U-shaped incision, open toward the buccal aspect of the implant site with slight divergent arms. Both sides of the incision were connected at approximately the palatal aspect of the implant cover screw. The outer edges of the

incision and approximal papilla were de-epithelialized. A full thickness flap was raised using blunt dissection. The cover screw was then retrieved and a healing abutment inserted. The flap was separated into mesial and distal parts. This incision was extended to the desired location of the buccal gingival margin of the future restoration. Each part of the flap was positioned over the de-epithelialized papilla and secured with vertical mattress sutures. Sutures were removed at 7 to 10 days and restorative procedures initiated one month post-surgery. Results demonstrated that in general a higher PIS was seen at the 6 months than pre-operatively. In no cases did the PIS worsen. Eleven percent remained the same, while 89% were improved. Of the sites analyzed, 51 (71%) increased by 1 PIS unit, while 13 (18%) increased by 2 PIS units. The mean preoperative PIS was 1.1. The corresponding post-operative value was 2.17 for an overall increase in the PIS of 1.07.

Grossberg (2001) described a technique in which a midline double pedicle flap was rotated to the midline or inter-implant space and carefully sutured into place during stage-2 surgery. Out of the 12 patients with adjacent missing maxillary incisors that were replaced with dental implants, none of the sites had been augmented prior to or during implant placement. Smokers were not excluded. From pre-operative and 12-month post-operative photographs, relative changes in inter-implant papilla height were made from a horizontal line connecting the free margin of the facial gingiva of teeth that were distal to the implant site. Results demonstrated that an increase in papilla height occurred in 4 of the 12 (0.4 to 2.3 mm) patients. One of the sites showed no change, while the remaining 7 lost papilla height (-0.4 to -2.0 mm). The mean change in papilla height was - 0.4 mm with a range of + 2.3 mm to - 2.0 mm.



El-Salam el-Askary (2000) described the use of a titanium papillary insert for the development of a papilla between adjacent implants. The polished titanium was pyramidal in shape and was retained by a screw in a 5 mm deep osteotomy. Sites receiving the implant required > 3 mm of interimplant distance. The procedure appeared to provide favorable results, but no long-term data has been published.

### **Biotype Enhancement**

Shibli et al. (2004) reported the use of a connective tissue graft to correct recession after immediate implant placement in the maxillary anterior. The patient presented with the 3 mm of recession over an implant in the position of #9. Interproximally there appeared to be some loss of mesial and distal papillae. The papillae appeared to be a Nordland & Tarnow (1998) Class II with the papilla tip located at or apical to the interproximal CEJ but coronal to the facial CEJ. Clinical evaluation revealed that the implant platform was 4 mm apical to the CEJ of the adjacent central incisor. Once a fixture level impression was performed, it was discovered that the implant was angled 15-degrees to the labial. After placement of an angled abutment and a provisional restoration, a “combined” full and partial-thickness flap with two vertical releasing incisions was elevated, and the mesial and distal papillae were deepithelialized. After harvesting of a connective tissue graft from the palate, the graft was stabilized with 2 interproximal and 1 apical resorbable 4-0 sutures. The flap was then coronally positioned, fully covering the graft, and sutured with interrupted sutures taking care to avoid excess tension. Six weeks after surgery a new provisional restoration was prepared to develop a new emergence profile. Sixteen weeks after surgery, a custom angled abutment and the

final restoration were placed. Photos from the 18-month reevaluation demonstrated a good esthetic result with symmetry of the marginal tissues of # 8 and # 9.

Azzi et al. (2002) described a technique for reconstruction of papillae around single and adjacent implants by way of a tunnel procedure in order to allow for placement of a connective tissue graft. The author emphasized that blood supply to the graft was key to success of the technique and necessitated the need for complete submergence of the graft. Vertical incisions were avoided in order to maintain the blood supply from the flap to the connective tissue graft. Adequate flap release was accomplished by extending dissection past the MGJ of the buccal flap and undermining the papilla on the palatal as well as the buccal aspect. Four-year follow-up pictures were provided revealing thickening of the tissue over the facial of the implant and thickening of the buccal aspect of the papilla. An increase in the height of the mesial and distal papillae was visible in 1 of the 3 cases.

### **Emergence Profile**

Emergence profile is the distance from implant platform to the crest of the surrounding soft tissue that allows for transition from implant fixture to implant abutment/crown. Thick tissue prevents show-through of the dark metal of the implant or abutment resulting in darkening of the gingiva. It is commonly stated that positioning of the platform should be related to the location of the facial CEJ of the adjacent teeth. This positioning is appropriate in the presence of periodontal health when the gingival margin is in close approximation to the CEJ. But this is often not the case. Albandar et al. (1999) evaluated a sub-sample of 9689 dentate Americans 30 to 90 years old. Fifty eight percent of patients 30 years and older had at least 1 mm of recession and 23% had > 3 mm of

recession. The breakdown of > 3 mm recession by age cohort was: age 30-39 10%; age 40-49 18%; age 50-59 30%; age 60-69 40%; age 70-79 46%; and age 80-90 60%. Results demonstrated that recession was present even in young populations and that prevalence increased steadily with patient age. Therefore, establishing the CEJ as the landmark for all patients is a fundamental error.

Davarpanah et al. (2001) described a 3-stage approach to developing emergence profile which first began with selection of the appropriate sized implant and ideal 3-dimensional placement. The second stage was selection of the appropriate healing abutment at the time of uncovering. An abutment approximately the same size as the cervical diameter of the tooth to be replaced and approximately 2 mm higher than the level of the adjacent soft tissue was recommended. The third stage of their approach included placement of the final abutment and a provisional restoration with ideal emergence constructed from a fixture level impression taken at the time of stage-2 surgery. The authors emphasized that with use of this approach ideal esthetics were possible.

There are differences in opinion regarding the ideal distance necessary to establish proper emergence. An overview of the literature will find 2 to 4 mm recommended from implant platform to the desired gingival margin location. In patients with a thin scalloped biotype, typically associated with ovoid or triangular teeth, a greater emergence profile distance is desired to prevent visibility of the facial implant margin. However, placing the implant platform more apically increases the likelihood that the V-shaped bone loss occurring secondary to implant placement which could result in loss of papilla height. Determination of the distance for proper emergence profile development

should be done on a patient-by-patient basis. When calculating emergence profile, it should be remembered that Small & Tarnow (2000) showed a mean of 1 mm of recession at 1 year after healing abutment placement. Failure of including this in an emergence profile calculation could result in esthetic failure.

### **Platform Switching**

The scalloped implant-abutment design by Nobel Biocare was designed to reduce the amount of peri-implant implant bone loss by moving the implant-abutment interface or microgap coronal in relation to the bone. Platform switching is another approach to reduce implant bone loss by “medializing” the microgap. Although the effect of this concept on marginal bone levels has not been demonstrated in a scientific study, case reports show impressive results. No randomized clinical trials comparing platform switched sites to controls have been published. More studies are needed to determine the effects of platform switching.

### **Platform Selection**

Differences in opinion exist regarding the most appropriate platform dimension needed to establish an ideal emergence profile. In an article supporting the use of the expanded platform 3i implants, London (2001) recommended that platform diameter mimic the tooth to be replaced in order to provide adequate papilla support. In order to achieve optimal tissue support and a cleansable emergence, the platform selected should be the widest that can be contained within the contours of the tooth and still provide subtle flared emergence and an adequate distance between the implant and adjacent teeth. Based on tooth measurement averages, London recommended use of a 5 mm platform to replace central incisors, 3 mm platform for lateral incisors, 4 mm platform for canines

and premolars, and 6 mm platforms to replace molars. London (2001) included implant platform selection as the first of three steps in establishing predictable soft tissue support. Step two was to provide enough distance apicocoronally for transition from the round implant to a custom abutment similar in shape to the tooth being replaced. Finally, fabrication of a crown contoured to complete the transition from “root” to crown.

Davarpanah et al. (2001) included selection of the appropriate platform diameter as a significant factor in their keys to developing emergence profile. They described a 3-stage approach to developing an emergence profile beginning with the implant stage, which included ideal 3-dimensional implant placement. Like London (2001), the authors suggested that platform width selection in the esthetic region should be based on the average mesiodistal diameters of the tooth to be restored.

Small et al. (2001) performed a 3 to 5 year analysis of recession on wide diameter versus standard diameter 3i implants that should be considered when selecting implant platform size. Results showed that for 150 standard diameter implant (SDI, 3.75 mm diameter), 0.4 mm of recession occurred between uncovering and prosthesis insertion. At the time of prosthesis insertion, recession had occurred in 49% of the standard diameter sites. Nine percent of implants had coronal migration resulting in a reduction in recession and 42% of sites showed no difference. For 62 wide diameter implants (WDI, 5 and 6 mm diameter), 1.09 mm of mean recession was observed between uncovering and prosthesis insertion. Eighty-nine percent of the WDI sites, nearly twice as many as the SDI, showed recession, while none showed coronal migration, and 11% showed no change. At 4 to 5 year reevaluation after healing abutment placement recession was 0.57 mm for SDI and 1.58 mm for WDI.

If the diameter of the tooth to be replaced is used as a guide for platform selection to improve papilla support and develop proper emergence, it must be remembered that about 1 mm more recession may occur when wide diameter platforms are used instead of standard platforms.

### **Implant Site Provisionalization Effect on Papilla Preservation**

The effect of provisionalization on support of the interproximal papilla and facial marginal tissue has not been determined by randomized clinical trials. There is evidence that supports and disputes the need for provisionalization prior to final restoration placement.

Neale & Chee (1994) described development of implant soft tissue emergence profile by provisionalization. A fixture level impression was taken at the time implant placement for fabrication of provisional restoration. At the time of implant uncovering a full thickness flap was reflected and the provisional was delivered. After creating smooth contours by gingivoplasty of the lingual and palatal tissue corresponding to the papilla and gingival margins, the flaps were sutured. The author recommended 12 to 20 weeks of provisionalization for stabilization of the final gingival margin location, at which time a final impression could be made for fabrication of the definitive prosthesis. The authors warned that once the provisional restoration was removed, soft tissue collapse may occur in a short period of time.

Kan et al. (2003) described a technique for preservation of papilla between future adjacent maxillary anterior implant sites. In a case report 14 Nobel Replace implants were placed in 6 consecutive patients with “adequate gingival architecture with the surrounding dentition”. The teeth were also described as having “appropriate gingival to

underlying bone relationship (3 mm sounding facially and 4 to 6 mm interproximally)". Phase 1 of the technique began with atraumatic tooth extraction with periostomes (Nobel Biocare) without flap reflection. If no loss of integrity of the buccal plate was detected, osteotomy was performed in order to establish ideal implant positioning. Immediate provisionalization was performed to maintain cervical emergence of the extracted tooth. Phase 2 of the procedure was performed 6 months later with removal of the adjacent tooth and immediate implant placement with a minimum of 3 mm maintained between the implants. Provisionalization was performed by the same technique as just described. Final impression of both sites and delivery of the final restorations occurred 6 months later. Mean time for follow-up was 22.6 months (range 12-24 months). The authors reported that no radiographic bone loss > 1 mm was detected interproximally. Upon clinical evaluation, the mean Jemt PIS was 3 at reevaluation versus 2.75 at pretreatment. Less than 1 mm of facial recession was reported.

Kinzer & Kokich (2005) described that the main purpose of provisionalization as guiding the soft tissue prosthetically into its final position. Due to healing abutments being smaller in diameter than the replaced tooth, the architecture of the tissue surrounding healing abutments is not usually scalloped. By adding to the facial contour of the provisional, the scalloped architecture can be enhanced as a result of the facial tissue moving apically and a more ideal papillary form can be obtained by adding to the interproximal contour. The authors stated that 4 to 6 weeks is usually required for stabilization of the marginal tissue. They described the process of provisionalization as "prosthetically guided soft tissue management".

Kan (2001) published a case report on immediate provisionalization in order to preserve “gingival architecture” with a removable ovate pontic in conjunction with immediate implant placement. A 23 year-old with a thin scalloped periodontium presented with a failing central incisor. Prior to implant placement a removable ovate pontic was constructed from a diagnostic cast. The tooth to be replaced was first removed from the diagnostic cast without disturbing the existing gingival architecture. Once an ovate concavity with 2 to 3 mm concavity was created on buccal, a denture tooth was shaped to fit the void. After implant placement and delivery of the interim removable denture, the patient was instructed to only remove the appliance for cleaning and return it within 5 minutes of removal.

In their study of recession around standard diameter implants, Small & Tarnow (2000) evaluated the effect of provisional prosthesis type on recession. Of the 14 implants evaluated, one-half were treated with fixed provisional prosthesis while the others were treated with a removable prosthesis. When these sites were analyzed after healing abutment placement, a greater tendency for recession occurred in sites treated with fixed provisional restorations than removable prosthesis. However, this difference was not statistically significant. No analysis with regard to biotype was performed on these patients.

Some reports have been published in disagreement with the need for provisionalization. Jemt (1997) published a non-blinded retrospective study on “spontaneous papilla regeneration” in 25 two-stage implants placed in 21 patients. Follow-up was 1 to 3 years with a mean of 1.5. Restorative procedure included fixture level impressions at the time of healing abutment placement for fabrication of permanent



crowns after “adequate time for healing”. At the time of crown cementation, the papilla contours were evaluated from photographs by Jemt’s papilla index (1997). This was repeated at reevaluation. Comparison at crown delivery and 1 to 3 year follow-up showed that the size of the papilla increased in 40 sites, while no change occurred with the remaining 10 papillae. Recession occurred with 4 crowns resulting in a bluish/gray appearance of the gingival margin and exposure of the metal abutment in 2 cases. The author suggested that reasoning for regeneration of the papilla was the inflammatory responses of the papillary tissues to plaque formation after delivery of the implant restoration. As for the facial recession, the author stated that patient brushing habits might have contributed to this occurrence. No information was given with regard to patient biotype in this study.

Priest (2003) retrospectively evaluated photographs of 55 implants that were restored as part of his prosthodontic practice. Follow-up was 1 to 9 years with a mean of 3.5 years. Implants were placed with a 2-stage protocol. Final restorations were placed 4 to 8 weeks after healing abutment or provisional restoration placement. Of the 55 implants evaluated, only 3 were restored with provisional restorations prior to final impression. Using fixture level impressions, crowns were constructed to reproduce the contours and interproximal contacts of their contralateral counterparts. Interproximal embrasures of the final restorations were not modified to fill spaces void of soft tissue. Changes in soft tissue profiles were recorded photographically. The distance from the most coronal aspects of the mesial and distal papillae and facial gingival margin to a line connecting the incisal edges of the adjacent teeth were recorded to the nearest 0.1 mm. The author reported that coronal migration of the interproximal papilla occurred in 84%

of the sites with 75% demonstrating complete papilla fill. He also stated that many of the sites that did not gain height were sites where complete fill of the embrasure space was present at the time of final restoration placement. Mean 1 year change in relative papilla height showed a gain of 0.22 mm (range -1.4 to 1.4 mm) for the mesial and a gain 0.29 mm (range -1.0 to 3.0 mm) for the distal papilla. Corresponding 3.5-year data was a gain of 0.65 mm (range -1.2 to 2.6 mm) for the mesial and a gain 0.62 mm (range -0.6 to 2.9 mm) for the distal papilla. With regard to facial marginal tissue, recession was observed in association with 60% of the implants. One-year data was a loss -0.13 mm (range -0.9 to 0.8) at facial sites. Corresponding 3.5-year data demonstrated that the facial sites lost 0.06 mm (range -1.6 to 1.5 mm). The author concluded that papilla regeneration was predictable around single implant restorations. Weaknesses of this study include potential evaluator bias, non-standardized photographic technique, and that it was retrospective. The author stated that it was his belief that the use of a provisional restoration allows soft tissue development to occur more rapidly, but that long term results were likely to be similar to placement of a healing abutment.

From these articles it is evident that provisionalization allows the surgeon and/or restorative dentist to establish stability of the papillary and marginal soft tissues in preparation for final restoration fabrication. Jemt (1997) and Priest (2003) have shown that some regeneration of the papilla occurs after final restoration placement in sites without provisionalization. However, the authors also reported that recession occurred with up to 60% of their implant restorations.

### Timing of Final Restoration Placement

As mentioned previously, Small & Tarnow (2000) prospectively evaluated implants from 4 manufacturers (Nobel, Interpore, Stryker, ITI) placed in both one and two stage procedures in an attempt to find factors affecting implant recession. Exclusion criteria included > 10 cigarettes/day and grafting prior to or in conjunction with implant placement. Baseline measurements were obtained upon completion of stage-2 surgery. For 1-stage implants, baseline measurements were performed at implant placement and final restorations were placed at 7 months post-placement in the maxilla and 5 months in the mandible. For 2 stage implants, the final prosthesis was placed 1 to 4 months after uncovering. Recession was detected most commonly at buccal sites. Although buccal recession at 1 year was 0.88 mm, great variability existed. Of all the factors evaluated, time was the only factor that had an influence on the occurrence of recession (Table 9 & 10).

**Table 9: Gingival Recession Around Implants Over 1 Year**

<b>Time</b>	<b>Mesial Changes</b>	<b>Distal Changes</b>	<b>Buccal Changes</b>	<b>Lingual Changes</b>
1 week	-0.15	-0.05	-0.13	-0.12
1 month	0.36	0.50	0.52	0.25
3 months	0.48	0.72	0.75	0.47
6 months	0.44	0.75	0.85	0.45
9 months	0.46	0.77	0.88	0.45
1 year	0.47	0.78	0.88	0.53

\*Small, Tarnow (2000)

**Table 10: Gingival Recession Around Implants after 1 Year**

<b>Location</b>	<b>Mean Recession (mm)</b>	<b>Sites Showing Recession (%)</b>	<b>Sites Showing Growth (%)</b>	<b>Sites Showing No Change (%)</b>
Mesial	0.47	60	12	28
Distal	0.78	75	14	11
Buccal	0.88	82	6	12
Lingual	0.52	60	12	28

\*Small, Tarnow (2000)

As mentioned before, Small et al. (2001) published a 3 to 5 year analysis of recession of wide diameter implants. Baseline measurements of the buccal gingival margin relative to a fixed reference point on the implant shoulder were recorded with a periodontal probe following completion of stage-2 uncovering. Ninety-nine percent of the implants were surrounded by keratinized tissue at the time of uncovering. Prosthesis insertion occurred on average 8 months after abutment connection (Table 11).

**Table 11: Mean Recession Around Standard and Wide Diameter Implants Over Time**

<b>Time</b>	<b>Change in Recession</b>	<b>Cumulative Recession</b>	<b>Change in Recession</b>	<b>Cumulative Recession</b>
	<b>Standard Diameter Implants</b>		<b>Wide Diameter Implants</b>	
Prosthesis Insertion	0.40 mm	0.40	1.09 mm	1.09
3 months	0.10 mm	0.50	0.16 mm	1.25
6 months	0.03 mm	0.53	0.02 mm	1.27
1 year	0.02 mm	0.55	0.02 mm	1.29
18 months	0.00 mm	0.55	0.08 mm	1.37
2 years	-0.01 mm	0.54	-0.01 mm	1.36
3 years	0.09 mm	0.63	0.17 mm	1.53
4 years	0.02 mm	0.65	0.05 mm	1.58
5 years	0.08 mm	0.73		

\* Small, Tarnow, Cho (2001)

Review of the data revealed that most of the recession occurred within the first 3 months after healing abutment placement. The authors recommended waiting 3 months after healing abutment placement before taking the final impression or selecting an abutment.

**Objective Evaluation of Esthetics**

Albrektsson et al. (1986) established the most widely accepted criteria for implant success based on clinical and radiographic parameters. With success rates in the high 90% reported in the literature, clinicians have begun to look for more stringent ways to evaluate implants. Several authors have attempted to establish specific criteria with which to evaluate esthetic aspects of implants. Levin et al. (2005) described an examination system for esthetic success which was determined according to examiner's satisfaction

rating with regard to the 4 following parameters: interdental papilla shape, free gingival margin, attached gingival appearance, restoration harmony with regard to smile line (Table 12).

**Table 12: Levin’s Esthetic Examination**

<b>Categories</b>	<b>Definitions</b>
Failure	More than 2 esthetic parameters were unsatisfactory.
Fairly Good	2 esthetic parameters were unsatisfactory.
Good	1 esthetic parameter was unsatisfactory.
Perfect	<b>All esthetic parameters were satisfactory</b>

\* (Levin et al. 2005). Four esthetic parameters included interdental papilla shape, free gingival margin, attached gingival appearance, and smile line harmony.

Using this scoring system, Levin et al. (2005) evaluated 53 single implants in the maxillary anterior in 48 patients. Twenty-six (50%) immediate and 26 (50%) delayed implants placed 6 months or more after extraction were evaluated. The implants were either placed with a flapless procedure (n = 9) or with a traditional 2-stage procedure with primary-closure (n = 43). Follow-up averaged 37.5 months (range 1 to 9 years) after implant uncovering. Surgical success was present if the implant had survived and marginal bone loss was < 0.2 mm per year following the first year of function. Nine-year cumulative survival rate was 98.1% (1 implant failed before loading). Surgical success rate as determined by marginal bone loss was 96.1% (49/51). Cumulative surgical success rate was 92.6% at 9 years. The examiner’s esthetic satisfaction rate was 86.3% (44/51 implants). The average esthetic success rate was 82.4%. Papilla shape and attached gingival appearance were the most important parameters influencing esthetic success. However, esthetic satisfaction was primarily influenced by smile-line harmony

as determined by correlation coefficients. No relationship was detected between marginal bone loss and esthetic success. The authors to concluded that marginal bone loss might occur without influence or impairment of the esthetic result. The authors admitted that the effect of marginal bone loss on the esthetic result might have been obscured with implants placed in thick periodontal biotype, a variable that was not evaluated in this patient population (Table 13).

**Table 13: Levin’s Esthetic Success Ratings**

<b>Esthetic Parameter</b>	<b>Implants Fulfilling Criteria for Success</b>	<b>Esthetic Success Rate</b>
Interdental Papilla	43	84
Free Gingival Margin	38	74
Attached Gingiva Appearance	42	83
Smile Line Harmony	44	86
<b>Total</b>	<b>51</b>	<b>100</b>

\*Levin et al. (2005), 37.5 month mean follow-up

Furhauser et al. (2005) described the Pink Esthetic Score (PES), which was designed in order to increase objectivity of soft tissue esthetic outcomes after surgical and prosthodontic treatment. The PES included 7 variables: mesial papilla, distal papilla, soft-tissue level, soft tissue contour, alveolar process deficiency, soft tissue color and texture. Each variable was assessed with a score of 2, 1, or 0 with 2 being the best and 0 being the worst with the highest possible score attainable being 14 (score of 2 x 7 variables). The mesial and distal papillae were evaluated for completeness, incompleteness, or absence.

All other variables were assessed by comparison with a reference tooth (a corresponding or neighboring tooth).

Thirty maxillary anterior (including first premolars) implants were evaluated at 15 to 143 months post-placement. Photographs were taken at 2 time points, 4 weeks apart under magnification and judged with the PES by 5 practitioners including prosthodontists, oral surgeons, orthodontists, and 5 dental students. Less than ideal cases were included in the analysis. The mean PES assessment was 9.46 at the first time point and 9.24 at the second. This difference was not statistically significant. Implants with the highest and lowest PES scores showed the smallest standard deviations inferring that esthetically poor and esthetically good outcomes presented with less variance in evaluator assessment than those with intermediate outcome (Furhauser et al. 2005).

**Table 14: Pink Esthetic Score**

Variables	0	1	2
Mesial Papilla	Absent	Incomplete	Present
Distal Papilla	Absent	Incomplete	Present
Level of Soft Tissue Margin	Major Discrepancy > 2mm	Minor Discrepancy 1-2 mm	No Discrepancy < 1mm
Soft-Tissue Contour	Unnatural	Fairly Natural	Natural
Alveolar Process Deficiency	Obvious	Slight	None
Soft-Tissue Color	Obvious Difference	Moderate Difference	No Difference
Soft-Tissue Texture	Obvious Difference	Moderate Difference	No Difference

\*Furhauser et al. (2005)



Testori et al. (2005) described the Implant Esthetic Score based on 5 variables including mesiodistal papilla presence and stability, ridge stability buccopalatally, texture of peri-implant tissue, color of peri-implant tissue, and gingival color. All of these variables were assessed with scores of 0, 1, or 2 with 0 being the worst and 2 being the best except for ridge stability with 0 being loss of width and 1 being maintenance of width. The scores for each of the 5 criteria were combined to reach a final outcome (Table 15).

**Table 15: Implant Esthetic Score**

A. Presence and Stability of the Mesiodistal papilla	
0	No papilla
1	Does not fill the entire space but is esthetically acceptable in harmony with adjacent teeth
2	Total fill
B. Ridge Stability Buccopalatally	
0	Width with ridge loss
1	Width maintained
C. Texture of the Peri-implant Soft Tissue	
0	Complete loss of texture
1	Does not look like healthy tissue, but some texture still maintained
2	Looks like healthy gingival tissue around the natural teeth
D. Color of the Peri-implant Soft Tissue	
0	Completely different color from healthy tissue
1	Does not look like healthy tissue but still esthetically acceptable
2	Looks like healthy gingival tissues around the natural teeth
E. Gingival Contour	
0	Evident asymmetry from the accepted parameters of scalloping
1	Signs of asymmetry but esthetically acceptable
2	Harmonious gingival contour

\*(Testori et al. 2005). The sum of the scores from the 5 categories are assigned to one of the following categories: Perfect outcome = 9, Acceptable outcome = 4 to 8, Compromised outcome = 0 to 3

Meijer et al. (2005) reported a pilot study of the Implant Crown Esthetic Index which consisted of 9 parameters including: mesiodistal dimension of the crown, position of the incisal edge of the crown, labial convexity of the crown, color/translucency of the crown, surface texture of the crown, position of the buccal margin of the implant mucosa, position of the mucosa in the interproximal embrasures, contour of the labial surface of

the mucosa, color and presence of attached gingiva. In order to score each site, penalty points were given to each parameter not matching the ideal result: one point for minor (slight) deviations and 5 for major (gross) deviations (Table 16).

**Table 16: Implant Crown Esthetic Score**

Criteria	Penalty Points
Mesiodistal dimension of the crown.	Grossly undercontoured, slightly undercontoured, no deviation, slightly overcontoured, grossly overcontoured
Position of the incisal edge	Grossly undercontoured, slightly undercontoured, no deviation, grossly overcontoured
Labial convexity of the crown	Grossly undercontoured, slightly undercontoured, no deviation, grossly overcontoured
Color and translucency of the crown.	Gross mismatch, slight mismatch, no mismatch
Surface of the crown.	Gross mismatch, slight mismatch, no mismatch
Position of the labial margin of the peri-implant mucosa.	Deviation of 1.5 mm or more, deviation of less than 1.5 mm, no deviation
Position of the mucosa in the approximal embrasures	Deviation of 1.5 mm or more, deviation of less than 1.5 mm, no deviation
Contour of the labial surface of the mucosa	Grossly undercontoured, slightly undercontoured, no deviation, grossly overcontoured
Color and surface of the labial mucosa.	Gross mismatch, slight mismatch, no mismatch

\* Meijer et al. (2005)

The sum of the points resulted in a final score reflecting esthetics with 0 = excellent, 1 to 2 = satisfactory, 3 to 4 = moderate, and 5 or more = poor. The authors presented results of a study in which 24 implant supported single tooth restorations were evaluated using the Crown Esthetic Index by two oral surgeons and 2 prosthodontists. Intra-observer agreement between prosthodontists (both 0.7) was “good” and “moderate” agreement occurred between OFMS (0.49 and 0.56). The best inter-observed agreement was among prosthodontists (0.61, “good”).

## **Subjective Evaluation of Implant Success**

To date no criteria has been universally accepted to evaluate implant esthetic success. This is due in part to the fact that esthetics is highly subjective in its nature. In an attempt to objectively evaluate patient perceptions of esthetics and how it relates to the clinician's perceptions, Kokich et al. (1999) digitally altered photograph of smiles with 1 of 8 common anterior esthetic discrepancies including crown length, crown width, incisor crown angulation, midline, open gingival embrasure, gingival margin, incisal plane, and gingival to lip distance. Forty images were randomized in a questionnaire and rated according to attractiveness by 300 orthodontists, general dentists, and lay people. The rating system was a 50 mm visual analog scale labeled at both ends with the left border (i.e. near zero) being "least attractive" and the right border (i.e. near 50) being most attractive. Each rater marked a point along the VAS to express their perception of dental esthetics. Individual ratings were measured to the nearest millimeter by digital calipers. As expected, dental professionals were more sensitive than the lay group to minor dental disharmonies. Of the parameters evaluated, crown length and gingival margin discrepancies, two key aspects of a smile, were often not noticed by either dental professionals or lay people. When interpreting these results, consideration should be made for the fact that the digital alterations were done bilaterally resulting smiles that had discrepancies but were still symmetrical.

Chang et al. (1999) retrospectively evaluated 41 Branemark implants placed in 29 Swedish patients who received one implant in the maxillary canine and incisor region. Mean follow-up was 36 months with a range of 5 to 89 months. Of the 41 implants, 5 had recession resulting in exposure of the abutment (1 composed of metal, 4 composed of

ceramic). Patient esthetic assessment was determined using a visual analog scale (VAS) from 0 to 100 to evaluate crown form, crown color and appearance, harmony with the natural dentition, overall satisfaction with appearance, and overall satisfaction. Patients were also asked to assess the importance of abutment visibility. Five prosthodontists evaluated intraoral and extraoral photographs taken at maintenance appointments with a VAS to determine overall satisfaction with the appearance of smile, crown color (incisal half and cervical half), crown form, surface texture, contact point position, surrounding soft tissue appearance, and overall satisfaction. Results revealed that 94% of patients were highly satisfied with the appearance of their implant-supported restoration with mean VAS ranging from 92 to 96. No single factor had a statistically significant effect on the patient's overall satisfaction with the appearance of the implant supported restoration. The mean importance of abutment exposure was 67 with a range of 0 to 100. Only 72% of prosthodontists were satisfied with the overall appearance of the restorations with mean VAS scores ranging from 63 to 78. The two factors that had the greatest effect on the prosthodontist's overall satisfaction were the surrounding soft tissue appearance and crown form as determined by multiple regression analysis. Overall, it was concluded that clinicians were more critical than patients in evaluating the appearance of the implant supported crown. Factors that clinicians considered important were not as important to patients.

Levi et al. (2003) performed a cross-sectional study of Connecticut patients who had received at least one implant supported restoration placed by prosthodontic residents and faculty in the area of #4 through #13. A group of 123 eligible patients were sent a 24-item, self-administered, questionnaire evaluating the subject's overall satisfaction with

their treatment, their perception of various technical aspects of their implant restoration, and specific aspects of treatment and the definitive prosthesis. Subjects rated their satisfaction on a 4-point scale for each item (1 = “Highly Dissatisfied, 4 = “Highly Satisfied or 1 = “ Strongly Disagree”, 4 = “Strongly Agree”). Of the 78 subjects who responded to the questionnaire, 67 (88%) were “highly satisfied” with their implant restoration, 8 (10.5%) were "somewhat satisfied," and 1 (1.3%) was "somewhat dissatisfied." Five variables - implant position, definitive restoration shape, appearance, effect on speech, and chewing capacity - were strongly associated with overall satisfaction. Although 50% of the respondents reported dissatisfaction with the soft tissue related variables, soft tissue appearance around the implants was not significantly related to overall satisfaction. Patients that had an interim partial denture as their provisional restoration tended to be more highly satisfied with their implant restoration, although this was not statistically significant. This finding suggested that when patients have had a previous removable prosthesis experience to compare to their definitive implant restoration, they tend to be more accepting of the fixed restoration.

Ekfeld et al. (1994) reported on 93 maxillary and mandibular single tooth implants placed in 77 Swedish patients. At the time of patient evaluation, the implants had been in function for 3 to 46 months with a mean of 18 months. Sixty-nine percent rated their restoration very good, 19% as good, 10% as acceptable, and 2% as bad. The lead author who was a prosthodontist also evaluated the restorations and rated 46% of them as very good, 37% as good, and 17% as acceptable. None were judged as poor.

As part of the Toronto study, Avivi-Arber & Zarb (1996) provided questionnaires regarding restoration esthetics to 35 patients with 42 maxillary and mandibular single

tooth restorations. Implants were placed in a 2-stage procedure with the final prosthesis delivered 6 weeks after stage 2 surgery. When questioned with regard the appearance of their implant supported crown, 60% were extremely satisfied, 28.6% were somewhat dissatisfied, 8.6% had no feeling one way or the other, and 2.9% were somewhat satisfied. When asked to compare their implant supported crown to their natural teeth, 11.4% agreed that it was more attractive than their natural teeth, 77.1% said that it was about the same as their natural teeth, 8.6% felt that it was less attractive, and 2.9% responded that it was much less attractive. The authors added that most of the esthetic problems were related to poor restoration shade and shape, reflection of the abutment metal underneath the gingiva, or what the author described as a soft tissue deficiency at the crown-gingival junction.

From this review it is evident that the patient's perception of esthetics can be much different from that of the clinician's. The studies reviewed do not provided much insight into our understanding of the subjective part of implant esthetics. However, it does provide a basis by which we can compare the results of this study.

## **Conclusion**

Although no direct comparisons of changes in hard and soft tissues that occur after immediate implant placement with flap reflection vs. a flapless procedure have been reported, there is indirect evidence showing that less tissue loss occurs with a flapless approach. Covani et al. (2004) showed that 0.5 mm of bone loss occurred between flapless immediate implant placement and stage-2 surgery. Gomez-Roman (2001) detected approximately 1 mm of bone loss one year after crown placement with immediate implant placement with full thickness flap reflection without papilla

preservation. Only 0.3 mm of bone loss was detected at one-year re-evaluation when papilla-sparing incisions were performed. Although indirect, these studies suggest that about 2 to 3 times more tissue loss can occur when a flap is reflected with immediate implant placement when compared to no flap. Therefore, in the absence of a significant facial undercut and an intact buccal wall, a flapless approach should be performed. In the occurrence of an apical fenestration, a sub-marginal access procedure like the esthetic buccal flap as described by Steigmann & Wang (2006) should be executed to allow for access to the defect for GBR. If more access is required, full thickness flap reflection with papilla preserving incisions should be used.

When a dehiscence occurs, the location of the buccal plate should be considered relative to the desired emergence profile. Desired emergence profile dimensions should be based on the patient's biotype. Tarnow et al. (1996) stated that a 2 to 3 mm distance was desired at the time of restoration from the implant platform to the gingival margin. For thin biotypes 3 mm emergence would be more desirable and 2 mm in a thick biotype. Thinner tissue requires deeper platform placement in order to prevent darkening of the facial tissue and allow for the implant-restorative transition. The presence of a dehiscence in a thin biotype may not require that grafting of the facial wall in the vertical dimension since the platform will be placed more apically. In a thick biotype, grafting in the vertical dimension in conjunction with flap reflection may be necessary due to implant thread exposure.

When placing an immediate implant with a flapless approach, a distance of 2.5 mm from the implant platform to the anticipated facial restorative margin or gingival margins of the adjacent teeth is desired for a thick biotype and 3.5 mm for a thin biotype.



These distances were calculated by adding the desired emergence for the particular biotype (2 mm for a thick biotype and 3 mm for a thin biotype) to the anticipated 0.5 mm of tissue loss which Covani et al. (2004) demonstrated can be expected to occur after flapless implant surgery. When immediate implant placement is performed in conjunction with full thickness flap reflection, a distance of 3 mm from the implant platform to the anticipated facial restorative margin or gingival margin of the adjacent teeth is recommended for a thick biotype and 4 mm for a thin biotype. These distances were calculated by adding the desired emergence for the particular biotype (2 mm for a thick biotype and 3 mm for a thin biotype) added to the anticipated 1 mm of tissue height that Gomez-Roman (2001) predicted to occur after implant placement with flap reflection. A screw-retained restoration may be necessary when implant platform is placed more apically in order to compensate for a thin biotype and flap procedure (Table 17).

**Table 17: Apicocoronal Placement of Immediate Implant Platform Relative to Adjacent Gingival Margin with Flap and No Flap**

	<b>Thick Biotype</b>	<b>Thin Biotype</b>
<b>Flapless Procedure</b>	2.5 mm	3.5 mm
<b>Full Thickness Flap</b>	3 mm	4 mm

\*Distance from adjacent gingival margins to implant platform.

Interproximal crest loss on adjacent teeth can occur when implants are placed to far apically relative the interproximal crest (Buser et al. 2004). This is more likely to occur when attempting to place an implant in a thin biotype where apical placement is necessary to establish the proper emergence profile. In these cases it may be

advantageous to use an implant with a scalloped platform to prevent the implant platform from being located apical to the osseous margin.

With regard to mesiodistal implant placement and platform selection, a distance of at least 1.5 mm from implant to adjacent tooth is required for papilla formation (Tarnow et al. 2000). If the implant is less than 1.5 mm from adjacent teeth, the papilla may be lost. In these cases, a fixed partial denture may be a more esthetic option. If a distance of 1.5 to 2 mm from adjacent teeth exists, it is of the utmost importance that the implant be centered mesiodistally in order to provide space for the papilla. If 2 mm or more exist from the adjacent teeth, the implant may be “distalized” in incisor positions to create a distal zenith (Allen 1993). In cases where a minimal mesiodistal dimension exists (i.e. lateral incisors), use of the Nobel Perfect reduced diameter implant may not allow for adequate space for papilla formation due to a 4.3 mm platform diameter, the same as the regular diameter implant. The use of a wide platform implant should be avoided.

With regard to buccolingual placement in the incisor and canine positions in thick biotypes, the long axis of implant should be just palatal to the incisal edges or aligned with the cingulums of the adjacent teeth. When treating a thin biotype, incisal edge placement should be avoided and the implant should be placed more palatally in order to allow for ideal soft tissue profiles. Palatal placement increases the likelihood that grafting of the facial osseous wall can be performed by way of graft placement between the implant without requiring flap reflection. For premolars, long axis placement should be in line with the central groove of the adjacent premolar for thick biotype and central groove to palatal cusp for thin biotype. It should be noted that buccolingual placement

recommendations for thin biotypes could be applied to thick biotypes if so desired (Table 18).

**Table 18: Buccolingual Placement of Immediate Implants**

	<b>Incisors and Canines</b>	<b>Premolars</b>
<b>Thick Biotype</b>	Incisal Edge to Cingulum	Central Groove
<b>Thin Biotype</b>	Cingulum	Central Groove to Palatal Cusp

\* Describes long axis placement relative to the adjacent teeth.

When treatment planning esthetic immediate implant placement, biotype enhancement should be considered. It has been demonstrated in the literature that healing of the buccal plate after immediate implant placement occurs by way of horizontal resorption from its outer surface (Botticelli et. al, 2004). Even in the presence of thick biotypes, it may be necessary to perform some type of soft tissue grafting in order to compensate for this vertical and horizontal osseous resorption.

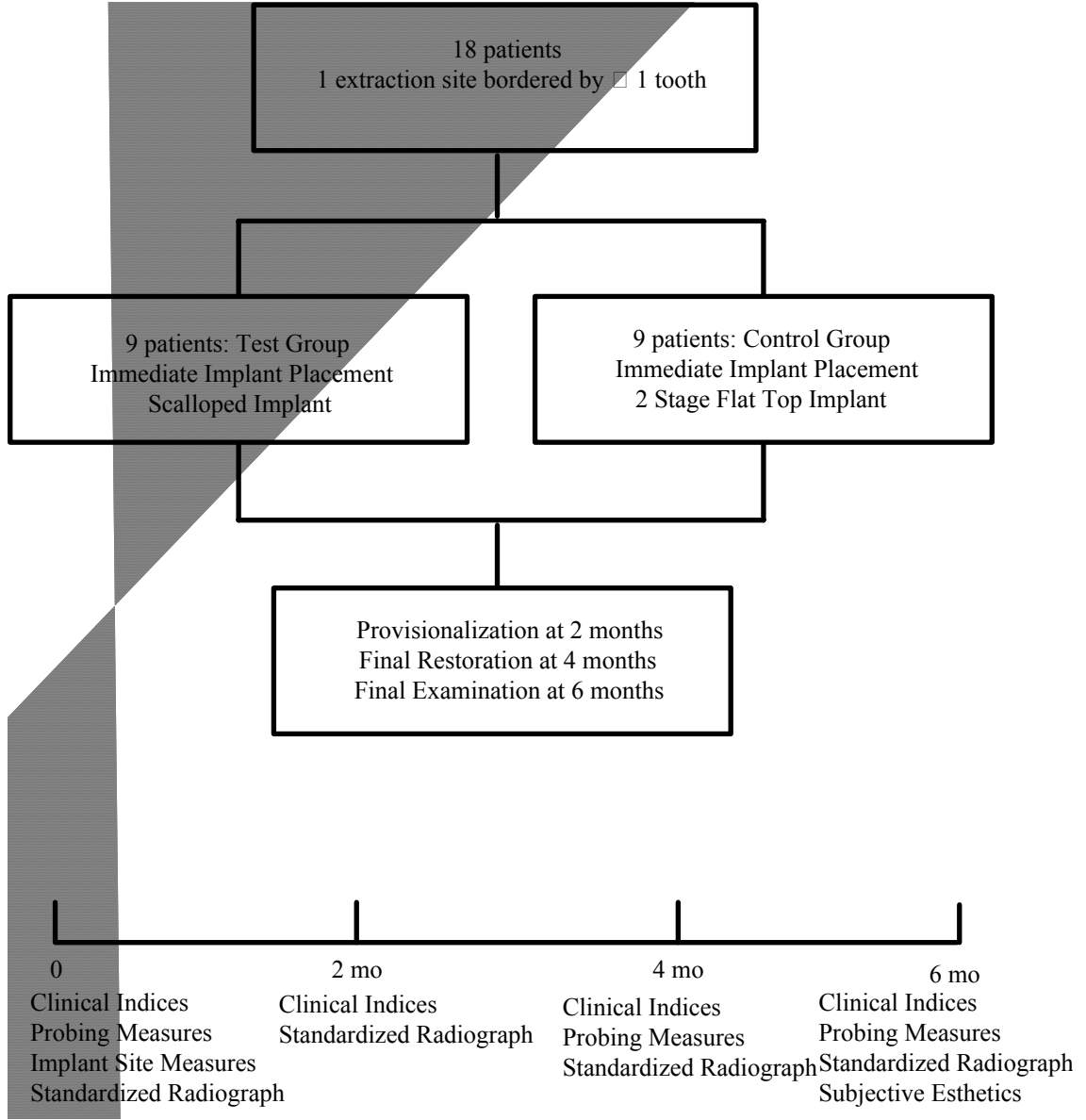
Some debate with regard to need for implant provisionalization exists (Neale et al. 1994, Kan 2003, Jemt 1997, Priest 2003). The magnitude of the difference that it has on the esthetic final outcome has yet to be determined. The advantages of implant provisionalization are that it allows the practitioner to achieve the gingival contours prior to fabrication and delivery of the final restoration and it allows the patient to give their input with regard to the desired esthetics of the restoration. However, it does require additional cost and time for both the patient and dentist. More research is needed in this area.

## CHAPTER II

### METHODS

**Study Design.** Eighteen patients who required immediate implant placement were invited to participate in this randomized, controlled, blinded clinical trial. By random selection, using a coin toss, 9 control patients were selected to receive a standard platform Nobel Replace implant. Nine test patients were selected to receive a scalloped platform Nobel Perfect implant. Fixture level impressions were taken at the time of implant placement for fabrication of provisional restorations which were placed at the time of implant uncovering at 2 months post-placement. Final impression and final prosthesis delivery were performed at 6 months.

**Figure 1**



## **Patient Selection**

### **Inclusion criteria**

- Patients requiring immediate implant placement in the maxillary esthetic zone with at least one adjacent tooth
- Patients 18 years of age or greater
- Informed consent approved by University of Louisville Human Studies

### **Exclusion Criteria**

- Patients with debilitating systemic diseases, or diseases that affect the periodontium
- Previous head and neck radiation therapy
- Patients with an allergy to any material or medication used in the study
- Smokers of > 1 pack per day
- Patients who need prophylactic antibiotics

### **Post-surgical Exclusion Criteria**

Any site excluded during the study was reported .

- Implant failure
- Unanticipated healing complications that would adversely affect treatment results
- Failure to comply with study protocol

## **Pre-surgical Management**

Each patient received a diagnostic work-up including standardized radiographs (Appendix D), study casts, clinical photographs, and a clinical examination of the teeth adjacent to the proposed extraction site. Baseline data was collected by a calibrated blinded examiner just before the surgical phase of the treatment.

## **Clinical measurements**

Measured at baseline and delivery of the final restoration.

1. Plaque index: Silness and Loe 1964 (Appendix A)
2. Gingival index: Loe 1967(Appendix B)
3. Probe depth: Measured from the gingival margin to apical penetration of the probe
4. Keratinized tissue: Measurement from the gingival margin to the mucogingival junction
5. Bleeding on probing: Present or absent
6. Clinical tooth mobility: Measured by using the modified Miller's index (Appendix C)
7. Clinical photographs: To be taken at baseline, post-fixture placement, provisionalization, final impression, and crown placement

## **Radiographic Measurements**

Measured at baseline, post-fixture placement, provisionalization, final impression, and crown placement.

1. Radiographic examination: Constructed using Triad light cured resin and a Rinn-

XCP on the patient model (Appendix D)

2. Radigraphic measurements:
  - a. Location of the interproximal contact
  - b. Vertical length of the interproximal contact
  - c. CEJ to osseous crest

### **Pre-Surgical Measurements at the Tooth to be Replaced**

1. Periodontal form: Flat, scalloped, or pronounced scallop (Appendix E)
2. Periodontal biotype: Thick, moderate, or thin (Appendix F)
3. Tooth shape: Square, ovoid, triangular
4. Relative tooth position: Buccal or lingual, incisal or coronal. mesial or distal
5. Recession: Measured on facial
6. Papilla tip-contact: Measured with probe
7. Gingival Scallop: Vertical distance from midfacial gingival margin to interproximal papilla tip
8. Papilla harmony: Yes or no
9. Black triangle: Yes or no. If yes, amount in millimeters
10. Osseous crest position: Distance from midfacial free gingival margin to osseous crest

**Surgical treatment.** Patients were anesthetized with 2% xylocaine containing epinephrine in both 1:100,000 and 1:50,000 concentrations as needed. A superficial split thickness flap was elevated on the buccal and a full thickness mucoperiosteal flap on the



palatal to expose the extraction site. Interproximal papilla were preserved and not included in the flap design. Teeth were atraumatically extracted with periostomes and forceps. The extraction socket was then curetted to remove all soft tissue. If a dehiscence or fenestration of the buccal plate was detected after extraction or during osteotomy preparation, the buccal periosteum was reflected apical to the defect.

During osteotomy preparation and implant placement, guidelines were followed to establish ideal restorative position. Buccolingually the long axis of the implant was aligned with the cingulums of the adjacent teeth for incisors and canines. Premolars were placed in line with the central groove of the adjacent premolars and/or molars. Implants were centered mesiodistally with a distance of  $\geq 1.5$  mm from the interproximal implant surface to the adjacent tooth or teeth when possible. Apicocoronally the implants were positioned so that the platform was 2 to 3 mm apical to the gingival margins of the adjacent teeth.

Fenestration or dehiscence defects were grafted with FDBA and a bovine collagen membrane (Ossix, ColBar LifeSciences Ltd., Herzliya, Isreal). Defects between the implant and extraction socket were grafted with FDBA and a calcium sulfate and a carboxymethylcellulose binding agent (Cal-Matrix, Lifecore, Chaska, MN). Flaps were replaced and sutured with 4-0 and 5-0 monofilament suture so that the facial gingival margin was 2 to 3 mm coronal to the implant platform. A barrier composed of calcium sulfate and hydroxypropylmethylcellulose (Cal-Forma, Lifecore, Chaska, MN) was placed in soft tissue defect previously occupied by the tooth.

Post-surgically patients were given naproxen 375 mg (Geneva Pharmaceuticals, Inc. Broomfield, CO), one tab q 12 h, doxycycline hyclate 50 mg (Warner Chilcott Inc.

Morris Planes, New Jersey) and analgesics as needed. Patients were seen on at 1, 3, 5 and 8 weeks post-surgery. Postoperative visits consisted of plaque removal, and oral hygiene reinforcement as needed. Any patient who developed any adverse reaction to the materials used, showed attachment loss  $\geq 2$  mm on teeth adjacent to the experimental site, or implant failure were exited from the study and received the appropriate treatment. Any adverse effects were reported.

### **Surgical Implant Site Measurements**

To be measured on mesial and distal.

#### Pre-extraction

1. Osseous crest to contact point

#### Post-extraction

2. Osseous crest to adjacent CEJ
3. Osseous scallop: The distance from the facial osseous margin to the crest of the interproximal septum

#### Post-implant Placement (Vertical Measurements)

4. Implant platform distance from:
  - Facial osseous margin
  - Interproximal osseous margin
  - Facial gingival margin
  - Interproximal gingival margin
  - Adjacent CEJ

#### Post-implant Placement (Horizontal Measurements)

5. Facial crest to implant platform

Subjective Measurements

6. Implant Position: To be evaluated in buccolingual, incisopalatal, and mesiodistal dimensions

**Restorative Treatment.** At the time of implant placement, fixture level impressions were taken. Laboratory fabricated provisional restorations composed of Integrity (Dentsply, Milford, DE), a composite resin, were temporarily cemented at the time of implant uncovering at 2 to 4 months after implant placement. Patients were seen on at 2 to 3 week intervals for modification of the provisional with flowable composite (EsthetX®flow; Dentsply, Milford, DE) in order to establish the desired marginal and papillary contours. At final impression, the provisional and temporary abutment were removed and attached to an implant analog. In order to reproduce the contours of the provisional, a small plastic cup was filled with Regisil (Dentsply, Milford, DE) bite registration paste and the analog with the temporary abutment and provisional attached was partially submerged. Once the Regisil had set, the provisional and the temporary abutment were removed and an impression coping was screwed into the analog. The shape of the provisional restoration was then recreated around the impression coping by adding DuraLay acrylic resin (Reliance Dental Mfg. Co, Chicago, IL) with a “salt and pepper” technique into the impression of the provisional. The impression coping and the attached DuraLay (Reliance Dental Mfg. Co, Chicago, IL) was then unscrewed from the impression coping and transferred to the mouth for an impression with Aquasil (3M ESPE Dental Professionals, St. Paul, MN) heavy and light body impression material. This

procedure registered the soft tissue emergence by replicating the subgingival contours of the provisional restoration. A shade was selected using a Vita shade guide and a digital photo was taken for the laboratory to use for crown characterization. Patients were seen approximately 1 week after delivery of the restorations for follow-up and esthetic evaluation.

### **Restorative Measurements**

To be measured at provisionalization and final restoration placement.

1. Location of interproximal contact mesial and distal: Incisal 1/3, junction of incisal and middle 1/3, incisal and middle 1/3, middle 1/3.
2. Vertical length of interproximal contact mesial and distal: Short, normal, long
3. Osseous crest to contact
4. Osseous crest to contact radiographic
5. Osseous crest to CEJ
6. Osseous crest to CEJ radiographic
7. Recession: Facial margin location relative to the margins of adjacent teeth
8. Emergence: Distance from implant platform to gingival margin
9. Gingival scallop: Vertical distance from midfacial gingival margin to interproximal papilla tip
10. Papilla harmony: Yes or no
11. Gingival margin harmony: Yes or no
12. Black triangle: Yes or no. If yes, amount in millimeters.
13. Restoration Form:

- a. Contact location: Ideal, incisal, or apical
- b. Contact length: Normal, long, or short
- c. Restorative margin: Good, overhung, or thin; and overextended or underextended
- d. Emergence profile: Good, overbulked, or underbulked

### **Esthetic Measurements**

To be measured at re-evaluation post-placement of the final restoration.

#### Objective

1. Pink Esthetic Score: 0 to 14 (Appendix G)
2. Jemt Papilla Index Score: 0 to 4 (Appendix H)

#### Subjective

1. Visual Analog Scale: 0 to 100 (Appendix I)

### **Statistical Analysis**

For the statistical analysis the two factor analysis of variance (ANOVA) was conducted with one between groups (scalloped vs. standard) factor and one with groups (time 1 vs. time 2) or repeated measures factor. The dependant measures were: adjacent tooth bone loss, osseous crest to contact point, implant top to gingival margin, recession, and black triangle.

An independant groups t-test was used to compare the scalloped groups for teh following: PES, Jemt papilla index, VAS, tooth to implant distance, and clinical indices.

## CHAPTER III

### RESULTS

**Implant Placement Data.** The facial aspect of the platform for the scalloped implant was located a mean distance of  $1.3 \pm 0.7$  mm coronal to the facial osseous margin. The platform for the standard platform implant was  $1.8 \pm 0.9$  mm coronal to the buccal plate. The difference was not statistically significant ( $p > 0.05$ ). The scalloped implant platform was coronal to the interproximal crests, while the interproximal portion of the standard platform was located apical to interproximal bone (Table 19).

The proximal platform surfaces of the standard implant were located more apical to the CEJ than the scalloped implant. The mean horizontal gap between the scalloped implant and the facial aspect of the extraction socket was  $2.4 \pm 0.9$  mm while the gap for the standard implant which was  $3.0 \pm 0.5$  mm. This difference was not statistically significant ( $p > 0.05$ ). Both implants were centered mesiodistally at the time of placement (Table 19).

Of the 9 scalloped implants placed 1 was an incisor, 1 was a canine, and 7 were premolars. Of the 9 standard implant placed 2 were an incisors, 1 was a canine and 6 were premolars.

**Bone Loss on Adjacent Teeth.** For the scalloped implant, the mean increase in CEJ to osseous crest distance as measured by sounding was  $1.5 \pm 0.7$  mm on the mesial

and  $1.8 \pm 1.6$  mm on the distal ( $p < 0.05$ ). For the standard implant the CEJ to osseous crest distance was  $1.1 \pm 0.7$  mm on the mesial and  $2.0 \pm 1.0$  mm on the distal ( $p > 0.05$ ). The difference between the groups was not significant ( $p > 0.05$ , Table 20).

**Emergence Profile Dimensions.** The facial emergence (implant to gingival margin) at time 6 was similar for both platform designs with  $1.8 \pm 0.8$  mm for the scalloped implant and  $1.8 \pm 0.5$  mm for the standard. A statistically significant difference was found in both groups between time 0 and time 6 for facial, mesial and distal emergence ( $p < 0.05$ ). The difference in facial emergence between the test and control groups was not statistically significant ( $p > 0.05$ ). The difference in mesial and distal emergence between test and control groups was statistically significant with the standard group having a greater mean implant to gingival margin distance ( $p < 0.05$ , Table 21).

**Facial Recession.** At baseline, mean facial recession was similar for the test and control groups at  $0.6 \pm 0.5$  mm and  $0.6 \pm 0.8$  mm respectively. This value decreased to  $0.3 \pm 0.5$  mm for the scalloped group and  $0.2 \pm 0.4$  for the standard group. The difference between groups was not statistically significant ( $p > 0.05$ , Table 21).

**Black Triangles.** Mean black triangles at time 2 provisionalization was  $1.5 \pm 0.5$  on the mesial and  $1.8 \pm 1.1$  mm on the distal of the scalloped platform and  $2.0 \pm 1.1$  mm on the mesial and  $1.9 \pm 1.1$  on the distal of the standard platform. The difference between groups was not statistically significant ( $p > 0.05$ ). Black triangles size decreased significantly between time 2 and time 6 for the mesial of the scalloped and standard implants but not for the distal of the standard group ( $p < 0.05$ , Table 21).

**Contact Point to Crest.** At time 2 provisionalization, the distance from crest to contact point was  $5.4 \pm 0.9$  mm for the mesial of the scalloped group and  $5.6 \pm 1.0$  mm on

the distal. For the standard group the crest to contact point distance was  $4.7 \pm 0.8$  mm on the mesial and  $5.5 \pm 1.2$  mm on the distal. The difference between groups was not statistically significant ( $p > 0.05$ ). At crown placement the distance from contact point to crest for the scalloped group was  $5.3 \pm 0.9$  mm for the mesial and  $5.9 \pm 0.6$  mm for the distal. For the standard group the distance was  $5.5 \pm 0.7$  mm for the mesial and  $6.2 \pm 0.7$  mm for the distal. The difference between groups was not statistically significant ( $p > 0.05$ , Table 21).

**Tooth to Implant Distance.** The distance from the proximal implant surface to the adjacent teeth measured at time 6 was approximately 2.1 mm for the scalloped implant and 1.9 mm from the standard implant. The difference between groups was not statistically significant ( $p > 0.05$ , Table 22).

**Objective Esthetic Evaluations.** The Pink Esthetic Score for the scalloped group was  $12.9 \pm 1.1$  out of a possible 14 and  $11.6 \pm 1.3$  for the standard group. The difference was statistically significant ( $p < 0.05$ ). The overall mean Jemt score was  $2.6 \pm 0.7$  for the scalloped group and  $1.9 \pm 0.6$  for the standard group (Table 23). A statistically significant difference in Jemt Papilla Index between groups was detected for the mesial papilla ( $p < 0.05$ ). The difference for the distal papilla was not statistically significant ( $p > 0.05$ ).

When the Jemt scores for both platform designs were evaluated as to the percentage of sites with  $\geq$  and  $<$  50% papilla, more scalloped sites than standard had  $\geq$  50% papilla and less scalloped sites had  $<$  50% papilla than standard. Sixty-five percent (11 of 17) of the scalloped group had complete fill of the embrasure by papilla, while the standard group had only 11% (2 of 18, Table 24).



**Subjective Esthetic Indices.** Visual analog scores for the scalloped group ranged from 98 to 99 and from 93 to 94 for the standard group. The difference in the overall visual analog scores between groups was statistically significant ( $p < 0.05$ , Table 23).

**Papilla Harmony.** Sixty-seven percent (6 of 9) of scalloped implants had papilla harmony after placement of the final restoration, while only 33% (3 of 9) of standard implants were harmonious (Table 25).

**Gingival Margin Harmony.** Both scalloped and standard implants had 78% (7 of 9) gingival margin harmony after delivery of the final restoration (Table 25).

**Clinical Indices and Keratinized Tissue.** Mean plaque index, gingival index, and bleeding on probing were low after crown placement. Gingival index was higher for the scalloped groups vs. standard ( $p < 0.05$ ). Mean keratinized tissue was  $3.7 \pm 1.1$  mm for the scalloped group and  $3.9 \pm 1.9$  mm for the standard group ( $p > 0.05$ , Table 26).

**Probe Depths.** At final restoration placement, mean probe depth for the scalloped group was  $3.7 \pm 0.5$ , while for the standard group mean probe depth was  $4.0 \pm 0.8$ .

**Patients Exited from Study.** During the course of this study, 3 implants failed. Three other implants were ailing and needed additional hard or soft tissue grafting. Of the 6 implants exited from the study 2 were scalloped platform and 4 were standard platform. One failure and two ailing implants occurred in smokers.

**Table 19**  
**Implant Placement Data**  
**Mean ± sd in mm**

	<b>Facial</b>	<b>Mesial</b>	<b>Distal</b>
<b><u>Scalloped</u></b>			
<b>Implant - Osseous Vertical</b>	1.3 ± 0.7	0.6 ± 1.5	1.2 ± 2.0
<b>Implant - CEJ Vertical</b>		-2.0 ± 1.3	-2.1 ± 1.5
<b>Implant - Facial Osseous</b>	2.4 ± 0.9		
<b>Horizontal</b>			
<b>Implant - Tooth Horizontal</b>		2.1 ± 0.8	2.1 ± 0.7
<b><u>Standard</u></b>			
<b>Implant - Osseous Vertical</b>	1.8 ± 0.9	-0.9 ± 1.7	-0.6 ± 1.8
<b>Implant - CEJ Vertical</b>		-3.6 ± 1.6	-2.9 ± 1.8
<b>Implant - Facial Osseous</b>	3.0 ± 0.5		
<b>Horizontal</b>			
<b>Implant - Tooth Horizontal</b>		1.9 ± 0.6	1.9 ± 0.7

\* = p < 0.05 between initial and 4-month values

**Table 20**  
**Bone Loss on Adjacent Teeth**  
**Mean ± sd in mm**

	<b>Time 0</b>	<b>Time 6</b>	<b>Change</b>
<b>Osseous Crest - CEJ</b>			
<b><u>Scalloped</u></b>			
<b>Mesial</b>	2.4 ± 0.4	3.9 ± 0.8	1.5 ± 0.7*
<b>Distal</b>	3.1 ± 0.6	4.8 ± 0.8	1.7 ± 1.6*
<b><u>Standard</u></b>			
<b>Mesial</b>	2.9 ± 0.7	4.1 ± 0.9	1.2 ± 0.7*
<b>Distal</b>	2.9 ± 0.7	4.8 ± 1.1	1.9 ± 1.0*

\* = p < 0.05 between 0 and 6-month values

**Table 21**

**Emergence Profile Dimensions , Facial Recession, and Black Triangle**

**Mean ± sd in mm**

	<b>Time 0</b>	<b>Time 2</b>	<b>Time 4</b>	<b>Time 6</b>
<b><u>Scalloped</u></b>				
<b>Implant- Gingival Margin M</b>	-2.6 ± 1.0	-1.1 ± 1.3	-1.9 ± 1.7	-2.2 ± 0.8*+
<b>Implant- Gingival Margin D</b>	-1.9 ± 1.6	-1.2 ± 1.2	-1.4 ± 1.6	-1.8 ± 1.4*+
<b>Implant- Gingival Margin F</b>	-2.8 ± 0.5	-1.6 ± 1.4	-1.2 ± 1.5	-1.8 ± 0.8*
<b>Recession Facial</b>	0.6 ± 0.5	0.3 ± 1.1	0.0 ± 0.0	0.3 ± 0.5
<b>Black Triangle Mesial</b>		1.5 ± 0.5	1.0 ± 1.1	0.9 ± 1.3*
<b>Black Triangle Distal</b>		1.8 ± 1.1	1.5 ± 1.3	1.4 ± 1.4
<b><u>Standard</u></b>				
<b>Implant- Gingival Margin M</b>	-4.1 ± 1.6	-2.6 ± 1.2	-3.6 ± 1.7	-3.7 ± 1.9*+
<b>Implant- Gingival Margin D</b>	-3.5 ± 1.9	-2.5 ± 1.3	-3.0 ± 1.7	-3.2 ± 1.5*+
<b>Implant- Gingival Margin F</b>	-2.7 ± 0.6	-2.5 ± 0.9	-1.9 ± 0.8	-1.8 ± 0.5*
<b>Recession Facial</b>	0.6 ± 0.8	-0.2 ± 1.2	0.2 ± 0.7	0.2 ± 0.4
<b>Black Triangle Mesial</b>		2.0 ± 1.1	1.4 ± 1.0	1.5 ± 0.9*
<b>Black Triangle Distal</b>		1.9 ± 1.1	1.4 ± 1.1	1.9 ± 1.3

\* = p < 0.05 between 2 and 6-month values

+ = p < 0.05 between scalloped and standard values

**Table 22**  
**Important Dimensions for Papilla Presence**  
**Mean ± sd in mm**

	<b>Time 2</b>	<b>Time 6</b>
<b><u>Scalloped</u></b>		
<b>Mesial</b>		
<b>Osseous Crest - Contact</b>	5.4 ± 0.9	5.3 ± 0.9
<b>Implant - Tooth</b>		2.1 ± 0.8
<b>Distal</b>		
<b>Osseous Crest - Contact</b>	5.6 ± 1.0	5.9 ± 0.6
<b>Implant - Tooth</b>		2.1 ± 0.7
<b><u>Standard</u></b>		
<b>Mesial</b>		
<b>Osseous Crest - Contact</b>	4.7 ± 0.8	5.5 ± 0.7
<b>Implant - Tooth</b>		1.9 ± 0.5
<b>Distal</b>		
<b>Osseous Crest - Contact</b>	5.5 ± 1.2	6.2 ± 0.7
<b>Implant - Tooth</b>		1.9 ± 0.7

\* = p < 0.05 between 2 and 6-month values

**Table 23**

**Objective and Subjective Esthetic Evaluations**

	<b>Scalloped</b>	<b>Standard</b>
<b>Pink Esthetic Score</b>	12.9 ± 1.1	11.6 ± 1.3+
<b>Jemt Papilla Index Mesial</b>	2.8 ± 0.4	1.9 ± 0.6+
<b>Jemt Papilla Index Distal</b>	2.3 ± 0.9	1.9 ± 0.6
<b>Visual Analog Tooth</b>	98.1 ± 3.8	94.2 ± 6.6
<b>Visual Analog Gingiva</b>	98.0 ± 4.0	93.4 ± 7.3
<b>Visual Analog Overall</b>	99.3 ± 2.0	94.9 ± 4.3+

+ = p < 0.05 between scalloped and standard values

**Table 24**

**Jemt Papilla Index Stratified by Complete Fill,  $\geq 50\%$  or  $< 50\%$  Papilla**

	<b>Mesial</b>	<b>Distal</b>
<b><u>Complete Papilla Fill</u></b>		
<b>Scalloped</b>	78	50
<b>Standard</b>	11	11
<b><u><math>\geq 50\%</math> Papilla</u></b>		
<b>Scalloped</b>	100	75
<b>Standard</b>	78	78
<b><u><math>&lt; 50\%</math> Papilla</u></b>		
<b>Scalloped</b>	0	25
<b>Standard</b>	22	22

**Table 25**

**Papilla and Gingival Margin Harmony Prevalence**

	<b>Scalloped</b>	<b>Standard</b>
	Yes	Yes
<b>Papilla Harmony</b>	67% (6 of 9)	33% (3 of 9)
<b>Gingival Margin Harmony</b>	78% (7 of 9)	78% (7 of 9)



**Table 26**

**Clinical Indices and Keratinized Tissue at Final Restoration Placement**

**Mean  $\pm$  sd in mm**

	<b>Scalloped</b>	<b>Standard</b>
<b>Plaque Index</b>	0.5 $\pm$ 0.3	0.5 $\pm$ 0.4
<b>Gingival Index</b>	0.5 $\pm$ 0.2	0.2 $\pm$ 0.2 <sup>+</sup>
<b>Bleeding on Probing</b>	0.4 $\pm$ 0.2	0.4 $\pm$ 0.1
<b>Keratinized Tissue</b>	3.7 $\pm$ 1.1	3.9 $\pm$ 1.9

<sup>+</sup> = p < 0.05 between scalloped and standard values

## **CHAPTER IV**

### **DISCUSSION**

This randomized, controlled, blinded clinical trial was designed to compare the esthetic results of a scalloped vs. a standard platform immediately placed implant in the maxillary anterior region. Papilla preservation incisions and a minimally traumatic extraction technique utilizing periostomes were used. Complete papilla fill and both subjective and objective esthetic scores were more favorable for the scalloped implant.

Both implants were placed so that the implant platform was approximately 3 mm apical to the facial gingival margin and 1.5 mm coronal to the osseous margin. The objective was to ensure that the restorative margin would be at least 2 mm apical to the gingival margin and that the implant collar would be coronal to bone to allow for soft tissue attachment. Mean facial gingival margin to implant platform distance was about 2.8 mm at placement for both the scalloped and standard implant while mean facial implant platform to osseous margin was 1.3 mm for the scalloped and 1.8 mm for the standard implant. This shows that apico-coronal placement guidelines were closely followed.

Planned implant to tooth distance was 2.0 mm but not less than 1.5 mm. Placement data showed that the mean mesial and distal horizontal distance was approximately 2.0 mm for both the scalloped and the standard implant.

Esthetic outcome was evaluated objectively using the Pink Esthetic Score (PES, Furhauser et al. 2005), the Jemt Papilla Index (JPI, Jemt 1997), and a dichotomous assessment of papilla harmony and gingival margin harmony. Briefly, the PES scores papilla, gingival margin level, soft tissue contour, color and texture. The JPI evaluates whether the papilla is absent, less than half, more than half or complete. All of these mean scores were higher for the scalloped implant and these differences were statistically significant for the PES and the mesial JPI.

Papilla formation for this study as evaluated using the Jemt score was 65% of sites with complete papilla fill for the scalloped implant and only 11 percent for the standard. When  $\geq 50\%$  papilla formation was evaluated, the scalloped implant sites met the criteria 88% of the time while the standard sites met the criteria 78% of the time. When compared to previous studies complete papilla formation reported by Jemt (1997) was 10%, 0% by Schropp et al. (2005) for both early and delayed placement, 9% by Cardaropoli et al. (2006), and 13% by Martin (2006) for standard implants while the scalloped implant in this study was 65%. Comparison of  $\geq 50\%$  papilla formation reported by Jemt (1997) was 50%, by Schropp 32% for early and 26% for delayed, 32% by Cardaropoli et al. (2006), and 35% by Martin (2006) for standard implants while the scalloped in this study was 88%. Thus previous studies had about 33% or one third of sites with  $\geq 50\%$  papilla formation for standard implants while this study had 88% for scalloped implants.

Martin (2006) has also tested papilla formation with scalloped implants but with delayed placement and complete flap reflection, including papilla. He found 74% of sites had  $\geq 50\%$  papilla formation while this study had 88% for immediate sites using a papilla

preservation flap. Thus it appears that use of the scalloped implant has a profound effect on initial papilla formation and that the effect may be enhanced when a papilla preservation flap is employed.

This study showed  $\geq 50\%$  papilla fill at 78% of standard implant sites. Previous reports have shown  $\geq 50\%$  papilla fill at about 33% of sites (Jemt 1997, Schropp et al. 2005, Cardaropoli et al. 2006, Martin 2006). All of the previous studies have used complete flap reflection, including papilla. This study used a papilla preservation flap. Thus papilla preservation flaps may have a profound effect on early papilla formation at the time of crown placement. This needs to be confirmed by a future study.

Jemt (1997), Schropp et al. (2005), and Cardaropoli et al. (2006) reported that at the time of crown placement papilla were present a low percentage of the time but by 1.0 to 1.5 years there was much greater papilla fill. Thus the papilla outcome for patients in this study should improve substantially from the current assessment at the 6-month crown placement. Considering the high percentage (65%) of complete papilla fill at the time of crown placement there is the potential for most sites to be completely filled 1 year after crown placement.

Papilla harmony was present 67% of the time for the scalloped implant and 33% of the time for the standard. The purpose of this assessment was to determine if the papilla were similar in height to other teeth in the same area. In some situations a contact is lengthened to prevent a "black triangle". Thus if only the JPI was used a papilla could be scored as a "complete fill" when actually it was the long contact that filled the "black triangle", not the papilla. So the papilla harmony score was considered an important part

of the esthetic outcome in this study while "contact lengthening" was considered a less ideal solution.

Gingival margin harmony served the same purpose and was used to compare the gingival margin height at the implant to the level on the adjacent teeth. Both the scalloped and the standard implant had gingival margin harmony 78% of the time. Facial recession was assessed relative to the gingival margin level on adjacent teeth, since the implant does not have a CEJ. Both the scalloped and the standard implant had minimal recession of about 0.25 mm at crown placement. This may be attributable to the effect of the roughened collar. An evaluation over a longer period of time, at least an additional year, is needed to determine if the soft tissue margin remains stable.

Subjective assessment of esthetics by the patient was done using a visual analog scale. The patient was asked to assess the tooth, the soft tissue, and the overall appearance. Scores for the scalloped implant were higher in all 3 categories and the difference was statistically significant for the overall appearance score. This may have been related to the better papilla harmony established with the scalloped implant. LaVacca et al. (2005) have shown that patients tend to give a higher subjective esthetic score when symmetry is present. Also quantitative assessment of the vertical height of the black triangle indicated that the mean height was greater for the standard implants.

Bone loss on adjacent teeth was similar for both the scalloped and the standard implant. Mean bone loss varied from 1.1 to 2.0 mm from implant placement to crown placement at 6 months which was a statistically significant loss. Previous studies of extraction sites have shown mean bone loss ranging from 0.9 to 1.5 mm (Lekovic et al.

1997, Lekovic et al. 1998, Iasella et al. 2002). The amount of loss is clinically significant because of the effect on the osseous crest to contact distance.

The presence or absence of a papilla has been associated with the osseous crest to contact vertical dimension and the tooth to implant horizontal dimension (Gastaldo et al. 2004). In general the horizontal dimension was about 2 mm in this study and the vertical osseous crest to contact distance varied between 5.5 to 6.0 mm. Despite these dimensions the scalloped implant had complete papilla fill in 11 of 17 (65%) sites while the standard implant had only 2 of 18 (11%) sites with complete fill. This difference may be due to advantages of the scalloped implant design that tend to support the papilla and favor complete papilla fill.

## **CHAPTER V**

### **CONCLUSIONS**

Within the limits of this study design it may be concluded that, at the time of crown placement, a greater percentage of complete papilla fill was obtained with the scalloped implant design. A more pleasing esthetic result in the maxillary anterior region, as evaluated by both objective and subjective esthetic scores, was obtained with the scalloped implant design. There was mean bone loss on adjacent teeth of about 1.6 mm.

**Table 27**

**Jemt Papilla Index Data from Previous Studies**

	<b>Complete</b>	<b>≥ 50%</b>	<b>&lt; 50%</b>	<b>Complete</b>	<b>≥ 50%</b>	<b>&lt; 50%</b>
<b>Jemt 1997</b>	10	50	50	60	90	10
<b>Schropp et al. 2005</b>						
<b>Early</b>	0	32	68	0	57	43
<b>Delayed</b>	0	26	74	0	63	37
<b>Cardaropoli et al. 2006</b>	9	32	68	18	86	14
<b>Martin 2006</b>						
<b>Scalloped</b>	13	74	26			
<b>Standard</b>	13	35	65			
<b>McGehee 2006</b>						
<b>Scalloped</b>	65	88	12			
<b>Standard</b>	11	78	22			

Complete - 3 or 4; ≥ 50% = 2 or 3 or 4; < 50% = 0 or 1



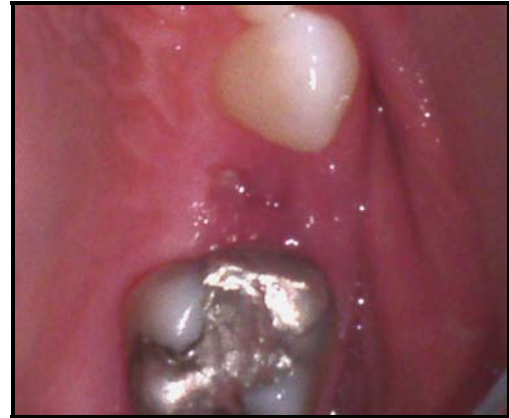
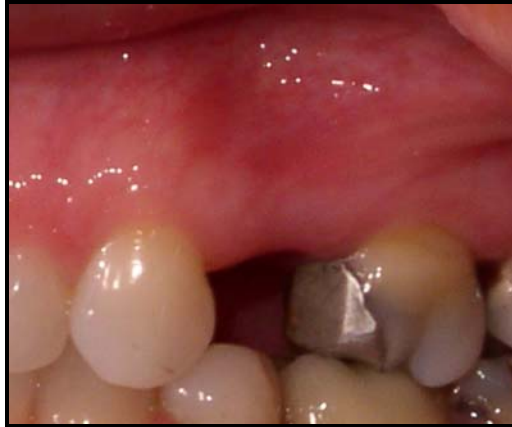
Figure 2. a) Scalloped pre-op buccal; b) Scalloped pre-op occlusal

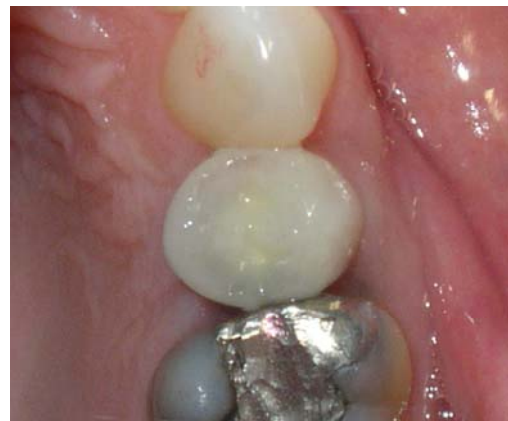
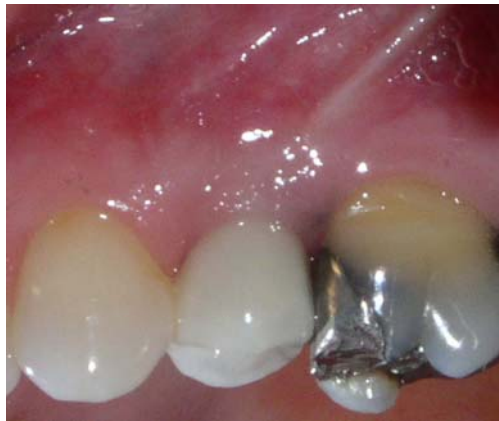
Figure 2. c) Scalloped crown placement buccal; d) Scalloped crown placement occlusal

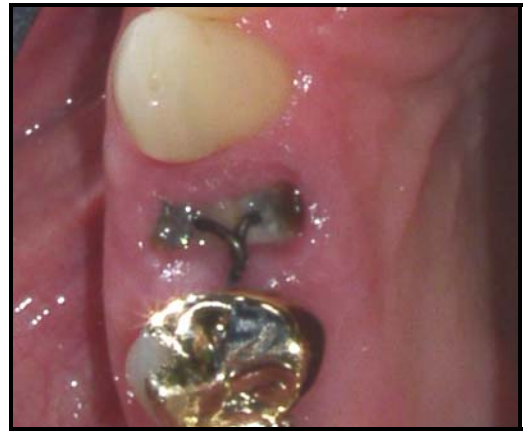
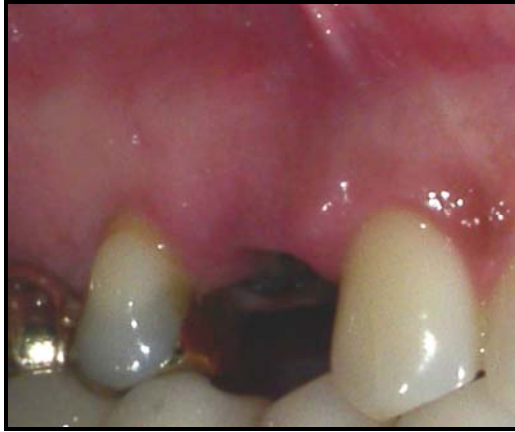
Figure 3. a) Standard pre-op buccal; b) Standard pre-op occlusal

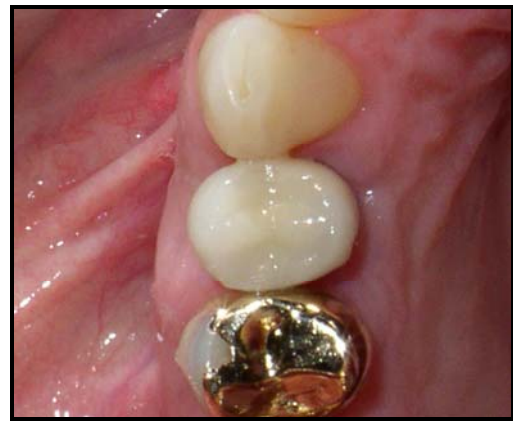
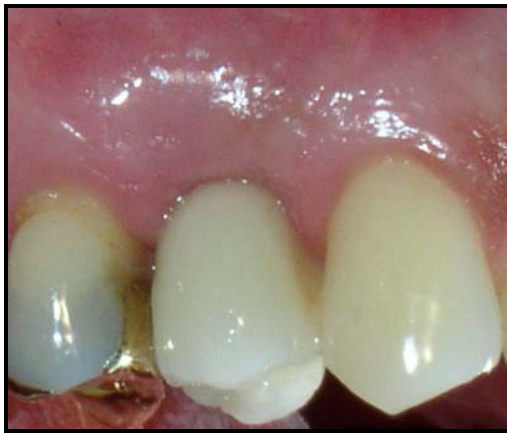
Figure 3. c) Standard crown placement buccal; d) Standard crown placement occlusal

## REFERENCES

- Albandar JM, Kingman A. Gingival recession, gingival bleeding, and dental calculus in adults 30 years of age and older in the United States, 1988-1994. *J Periodontol* 1999;70(1):30-43.
- Albrektsson T, Zarb G, Worthington P, Eriksson AR. The long-term efficacy of currently used dental implants: a review and proposed criteria of success. *Int J Oral Maxillofac Implants* 1986;1(1):11-25.
- Allen EP. Surgical crown lengthening for function and esthetics. *Dent Clin North Am* 1993;37(2):163-180.
- Auty C, Siddiqui A. Punch technique for preservation of interdental papillae at nonsubmerged implant placement. *Implant Dent* 1999;8(2):160-166.
- Avivi-Arber L, Zarb GA. Clinical effectiveness of implant-supported single-tooth replacement: the Toronto Study. *Int J Oral Maxillofac Implants* 1996;11(3):311-321.
- Azzi R, Etienne D, Takei H, Fenech P. Surgical thickening of the existing gingiva and reconstruction of interdental papillae around implant-supported restorations. *Int J Periodontics Restorative Dent* 2002;22(1):71-77.
- Bauman GR, Rapley JW, Hallmon WW, Mills M. The peri-implant sulcus. *Int J Oral Maxillofac Implants* 1993;8(3):273-280.
- Becker W, Ochsenbein C, Tibbetts L, Becker. Alveolar bone anatomic profiles as measured from dry skulls. Clinical ramifications. *J Clin Periodontol* 1997; 24(10): 727-731.
- Botticelli D, Berglundh T, Lindhe J. Hard-tissue alterations following immediate implant placement in extraction sites. *J Clin Periodontol* 2004;31(10):820-828.
- Campelo LD, Camara JR. Flapless implant surgery: a 10-year clinical retrospective analysis. *Int J Oral Maxillofac Implants* 2002;17(2):271-276.

- Cardaropoli G, Lekholm U, Wennstrom JL. Tissue alterations at implant-supported single-tooth replacements: A 1-year prospective clinical study. *Clin Oral Implants Res* 2006; 17: 165-171.
- Chang M, Odman PA, Wennstrom JL, Andersson B. Esthetic outcome of implant-supported single-tooth replacements assessed by the patient and by prosthodontists. *Int J Prosthodont* 1999;12(4):335-341.
- Choquet V, Hermans M, Adriaenssens P, Daelemans P, Tarnow DP, Malevez C. Clinical and radiographic evaluation of the papilla level adjacent to single-tooth dental implants. A retrospective study in the maxillary anterior region. *J Periodontol* 2001;72(10):1364-1371.
- Cochran DL, Hermann JS, Schenk RK, Higginbottom FL, Buser D. Biologic width around titanium implants. A histometric analysis of the implanto-gingival junction around unloaded and loaded nonsubmerged implants in the canine mandible. *J Periodontol* 1997;68(2):186-198.
- Cohen DW. Biologic Width. Lecture, Presented at Water Reed Army Medical Center, Washington, DC. 1962
- Covani U, Barone A, Cornelini R, Crespi R. Soft tissue healing around implants placed immediately after tooth extraction without incision: a clinical report. *Int J Oral Maxillofac Implants* 2004;19(4):549-553.
- Davarpanah M, Martinez H, Celletti R, Tecucianu JF. Three-stage approach to aesthetic implant restoration: emergence profile concept. *Pract Proced Aesthet Dent* 2001;13(9):761-767.
- Eckfeldt A, Carlsson GE, Borjesson G. Clinical evaluation of single-tooth restorations supported by osseointegrated implants: a retrospective study. *Int J Oral Maxillofac Implants* 1994;9(2):179-183.
- El-Salam El-Askary A. Use of a titanium papillary insert for the construction of interimplant papillae. *Implant Dent* 2000;9(4):358-362.
- Evian CI, Corn H, Rosenberg ES. Retained interdental papilla procedure for maintaining anterior esthetics. *Compend Contin Educ Dent* 1985;6(1):58-64.
- Frisch J, Jones RA, Bhaskar SN. Conservation of maxillary anterior esthetics: a modified surgical approach. *J Periodontol* 1967;38(1):11-17.

- Furhauser R, Florescu D, Benesch T, Haas R, Mailath G, Watzek G. Evaluation of soft tissue around single-tooth implant crowns: the pink esthetic score. *Clin Oral Implants Res* 2005;16(6):639-644.
- Gargiulo AW, Wentz FM, Orban B. Dimensions and relations of the dentogingival junction in humans. *J Periodontol* 1961;37:238-253.
- Gastaldo JF, Cury PR, Sendyk WR. Effect of the vertical and horizontal distances between adjacent implants and between a tooth and an implant on the incidence of interproximal papilla. *J Periodontol* 2004;75(9):1242-1246.
- Gelb DA. Immediate implant surgery: three-year retrospective evaluation of 50 consecutive cases. *Int J Oral Maxillofac Implants* 1993;8(4):388-399.
- Gomez-Roman G. Influence of flap design on peri-implant interproximal crestal bone loss around single-tooth implants. *Int J Oral Maxillofac Implants* 2001;16(1):61-67.
- Gomez-Roman G, Kruppenbacher M, Weber H, Schulte W. Immediate postextraction implant placement with root-analog stepped implants:surgical procedure and statistical outcome after 6 years. *Int J Oral Maxillofac Implants* 2001;16(4):503-513.
- Goodacre CJ, Kan JY, Rungcharassaeng K. Clinical complications of osseointegrated implants. *J Prosthet Dent* 1999;81(5):537-552.
- Grossberg DE. Interimplant papilla reconstruction: assessment of soft tissue changes and results of 12 consecutive cases. *J Periodontol* 2001;72(7):958-962.
- Grunder U. The inlay-graft technique to create papillae between implants. *J Esthet Dent* 1997;9(4):165-168.
- Jemt T. Regeneration of gingival papillae after single-implant treatment. *Int J Periodontics Restorative Dent* 1997;17(4):326-333.
- Kan JY, Rungcharassaeng K. Interimplant papilla preservation in the esthetic zone: a report of six consecutive cases. *Int J Periodontics Restorative Dent* 2003;23(3):249-259.
- Kan JY, Rungcharassaeng K, Kois JC. Removable ovate pontic for peri-implant architecture preservation during immediate implant placement. *Pract Proced Aesthet Dent* 2001;13(9):711-715.

- Kan JY, Rungcharassaeng K, Umezu K, Kois JC. Dimensions of peri-implant mucosa: an evaluation of maxillary anterior single implants in humans. *J Periodontol* 2003;74(4):557-762.
- Kinzer GA, Kokich VO Jr. Managing congenitally missing lateral incisors. Part III: single-tooth implants *J Esthet Restor Dent* 2005;17(4):202-210.
- Kois JC. Altering gingival levels: The restorative connection Part I: Biologic variables. *J Esthet Dent* 1994; 6: 3-9.
- Kois JC. Predictable single tooth peri-implant esthetics: five diagnostic keys. *Compend Contin Educ Dent* 2001;22(3):199-206.
- Kokich VO, Kiyak HA, Shapiro PA. Comparing the perception of dentists and lay people to altered dental esthetics. *J Esthet Dent* 1999; 11(6):311-324.
- La Vacca MI, Tarnow DP, Cisneros GJ. Interdental papilla length and the perception of esthetics. *Pract Proced Aesthetic Dent* 2005; 17(6): 405-412.
- Levi A, Psoter WJ, Agar JR, Reisine ST, Taylor TD. Patient self-reported satisfaction with maxillary anterior dental implant treatment. *Int J Oral Maxillofac Implants* 2003;18(1):113-120.
- Levin L, Pathael S, Dolev E, Schwartz-Arad D. Aesthetic versus surgical success of single dental implants: 1- to 9-year follow-up. *Pract Proced Aesthet Dent* 2005;17(8):533-538.
- Leziy SS, Miller BA. Replacement of adjacent missing anterior teeth with scalloped implants: a case report. *Pract Proced Aesthet Dent* 2005;17(5):331-338.
- Listgarten MA. Electron microscopic study of the gingivo-dental junction of man. *Am J Anat* 1966;119(1):147-177.
- London RM. The esthetic effects of implant platform selection. *Compend Contin Educ Dent* 2001;22(8):675-682.
- Martin EA. Implant esthetics using a Nobel Replace standard implant vs. Nobel Perfect scalloped implant placed in edentulous spaces in the esthetic zone of the maxilla. Thesis. University of Louisville, 2006.
- Meijer HJ, Stellingsma K, Meijndert L, Raghoobar GM. A new index for rating aesthetics of implant-supported single crowns and adjacent soft tissues--the Implant Crown Aesthetic Index. *Clin Oral Implants Res* 2005;16(6):645-649.

- Michaelides PL, Wilson SG. A comparison of papillary retention versus full-thickness flaps with internal mattress sutures in anterior periodontal surgery. *Int J Periodontics Restorative Dent* 1996;16(4):388-397.
- Misch CE, Al-Shammari KF, Wang HL. Creation of interimplant papillae through a split-finger technique. *Implant Dent* 2004;13(1):20-27.
- Neale D, Chee WW. Development of implant soft tissue emergence profile: a technique. *J Prosthet Dent* 1994;71(4):364-368.
- Nemcovsky CE, Moses O, Artzi Z. Interproximal papillae reconstruction in maxillary implants. *J Periodontol* 2000;71(2):308-314.
- Nordland WP, Tarnow DP. A classification system for loss of papillary height. *J Periodontol* 1998;69(10):1124-1126.
- Ochsenbein C, Ross S. A reevaluation of osseous surgery. *Dent Clin North Am* 1969;13(1):87-102.
- Olsson M, Lindhe J, Marinello CP. On the relationship implant at time of placement between crown form and clinical features of the gingival in adolescents. *J Clin Periodontol* 1993;20:570-577.
- Priest G. Predictability of soft tissue form around single-tooth implant restorations. *Int J Periodontics Restorative Dent* 2003;23(1):19-27.
- Rosenberg ES, Torosian J. An evaluation of differences and similarities observed in fixture failure of five distinct implant systems. *Pract Periodontics Aesthet Dent* 1998;10(6):687-698; quiz 700.
- Salama H, Salama M. An algorithm for decision making in anterior tooth replacement: Implants vs. fixed partial dentures. Lecture presented at Academy of Osseointegration annual meeting. 2005
- Salama H, Salama M, Garber D, Adar P. Developing optimal peri-implant papillae within the esthetic zone: guided soft tissue augmentation. *J Esthet Dent* 1995;7(3):125-129.
- Schroeder A, van der Zypen E, Stich H, Sutter F. The reactions of bone, connective tissue, and epithelium to endosteal implants with titanium-sprayed surfaces. *J Oral Maxillofac Surg* 1981;9(1):15-25.

- Schropp L, Isidor F, Kostopoulos L, Wenzel A. Interproximal papilla levels following early versus delayed placement of single tooth implants: A controlled clinical trial. *Int J Oral Maxillofac Implants* 2005; 20(5): 753-761.
- Schwartz-Arad D, Grossman Y, Chaushu G. The clinical effectiveness of implants placed immediately into fresh extraction sites of molar teeth. *J Periodontol* 2000;71(5):839-844.
- Shibli JA, d'Avila S, Marcantonio E Jr. Connective tissue graft to correct peri-implant soft tissue margin: A clinical report. *J Prosthet Dent* 2004;91(2):119-122.
- Silness J, Loe H. Periodontal disease in pregnancy. II. Correlation between oral hygiene and periodontal conditions. *Acta Odontol Scand* 1964; 22(1):121-135.
- Small PN, Tarnow DP. Gingival recession around implants: a 1-year longitudinal prospective study. *Int J Oral Maxillofac Implants* 2000;15(4):527-532.
- Small PN, Tarnow DP, Cho SC. Gingival recession around wide-diameter versus standard-diameter implants: a 3- to 5-year longitudinal prospective study. *Pract Proced Aesthet Dent* 2001;13(2):143-146.
- Steigmann M, Wang HL. Esthetic buccal flap for correction of buccal fenestration defects during flapless immediate implant surgery. *J Periodontol* 2006;77(3):517-522.
- Tarnow DP, Cho SC, Wallace SS. The effect of inter-implant distance on the height of inter-implant bone crest. *J Periodontol* 2000;71(4):546-549.
- Tarnow DP, Magner AW, Fletcher P. The effect of the distance from the contact point to the crest of bone on the presence or absence of the interproximal dental papilla. *J Periodontol* 1992;63(12):995-996.
- Testori T, Bianchi F, Del Fabbro M, Capelli M, Zuffetti F, Berlucchi I, Taschieri S, Francetti L, Weinstein RL. Implant aesthetic score for evaluating the outcome: immediate loading in the aesthetic zone. *Pract Proced Aesthet Dent* 2005;17(2):123-130.
- Weisgold AS. Contours of the full crown restoration. *Alpha Omegan* 1977;70(3):77-89.
- Wilderman MN, Pennel BM, King K, Barron JM. Histogenesis of repair following osseous surgery. *J Periodontol* 1970;41(10):551-565.
- Westcott RL. Cosmetic considerations in gingivectomy operations. *Ill Dent J* 1965; 34:242.





## Appendix A

### The Plaque Index

(Silness J, Løe H. Periodontal disease in pregnancy. II. Correlation between oral hygiene and periodontal conditions. Acta Odontol Scand 1964;22(1):121-135.)

The plaque index of Silness and Loe (1964) will be measured. Scores will be as follow:

0 - No plaque

1 - A film of plaque adhering to the free gingival margin and adjacent area of the tooth.

The plaque may be seen in situ only after application of disclosing solution or by using the probe on the tooth surface.

2 - Moderate accumulation of soft deposits within the gingival pocket, or on the tooth and gingival margin which can be seen with the naked eye.

3 - Abundance of soft matter within the gingival pocket and/or on the tooth and gingival margin.

Each gingival unit (buccal, lingual, mesiobuccal, distobuccal, mesiolingual, and distolingual) of the individual tooth will be given a score from 0-3, called the plaque index for the area. The scores from the 6 areas of the tooth are added and divided by 6 to

give the plaque index for the tooth.

## **Appendix B**

### **The Gingival Index**

(Lobene R, Weatherford T, Ross W, et al. A modified gingival indices for use in clinical trials. Clin Prev Dent 1986;8(1):3-6.)

The Gingival Index (Lobene et al. 1986) will be measured. Scores will be as follows:

0 - Normal gingiva

1 - Mild inflammation - slight change in color, slight edema

2 - Moderate inflammation - redness, edema, and glazing.

3 - Severe inflammation - marked redness and edema. Ulceration.

Each gingival unit (buccal, lingual, mesiobuccal, distobuccal, mesiolingual, and distolingual) of the individual tooth will be given a score from 0-3, called the gingival index for the area. The scores from the 6 areas of the tooth are added and divided by 6 to give the gingival index for the tooth.

## Appendix C

### Tooth Mobility

(Laster L, Laudenbach K, Stoller N. An evaluation of clinical mobility measurements. J Periodontol 1975;46(10):603-607.)

Miller proposed the following tooth mobility index:

0 - Movability of the crown within normal physiologic limits.

1 - Movability of the crown up to 0.5 mm in one direction. Does not exceed 1.0 mm in both directions.

2 - Movability of the crown from 0.5 to 1 mm in one direction. Does not exceed 2.0 mm in both directions.

3 - Movability of the crown exceeding 1 mm in one direction and/or vertical depressibility. Greater than 2.0 mm in both directions and/or vertical depressibility.

The index that will be used in the study is a modification of Miller's index (Laster et al., 1975) where half scores are used. Thus scores of 0, 0.5, 1, 1.5, 2, 2.5, and 3 will be utilized.

## **Appendix D**

### **Standardized Radiographic Technique**

An occlusal stent is used to provide a stable foundation for the radiograph holder. The stent is placed on a cast and the Rinn radiograph holder is positioned to allow as near as possible paralleling technique. Radiographs will be taken at baseline, pre-implant placement, immediately post-implant placement, 2 months, 4 months and 6 months post-implant placement.

## **Appendix E**

### **Periodontal Form**

(Kois JC: Altering gingival levels: the restorative connection part I: biologic variables. J Esthet Dent 6:3-9, 1994.)

Kois found the following average measurements for categories of periodontal form based on the gingival form:

**Pronounced Scallop:** A distance of greater than 5 mm exists from the midfacial free gingival margin to a periodontal probe positioned horizontally at the most coronal tip of the interproximal papilla.

**Scalloped:** A distance of 4 to 5 mm exists from the midfacial free gingival margin to a periodontal probe positioned horizontally at the most coronal tip of the interproximal papilla.

**Flat:** A distance of less than 4 mm exists from the midfacial free gingival margin to a periodontal probe positioned horizontally at the most coronal tip of the interproximal papilla.

## **Appendix F**

### **Periodontal Biotype**

A UNC periodontal probe will be inserted into the gingival sulcus of the facial tooth surface. If the probe is not visible through the facial gingival, a thick biotype will be assigned. If only the black color of the probe markings are visible, a moderate biotype will be assigned. If the millimeter markings on the probe are completely visible through the tissues the biotype will be designated as thin.



## Appendix G

### Pink Esthetic Score

(Furhauser et al. Evaluation of soft tissue around single-tooth implant crowns: The pink esthetic score. Clin Oral Implants Res 16(6): 639-644, 2005.)

Seven variables are assessed with a score of 2, 1, or 0 with 2 being the best and 0 being the worst with the highest possible score attainable being 14 (score of 2 x 7 variables).

<b>Variables</b>	<b>0</b>	<b>1</b>	<b>2</b>
Mesial Papilla	Absent	Incomplete	Present
Distal Papilla	Absent	Incomplete	Present
Level of Soft Tissue Margin	Major Discrepancy > 2mm	Minor Discrepancy 1-2 mm	No Discrepancy < 1mm
Soft-Tissue Contour	Unnatural	Fairly Natural	Natural
Alveolar Process	Obvious	Slight	None
Soft-Tissue Color	Obvious Difference	Moderate Difference	No Difference
Soft-Tissue Texture	Obvious Difference	Moderate Difference	No Difference

## Appendix H

### Jemt Papilla Index Scoring System

(Jemt T. Regeneration of gingival papillae after single-implant treatment. Int J Periodontics Restorative Dent 17(4): 326-333, 1997.)

The mesial and distal papillae were each given a score of 0 to 4.

Score 0	No papilla is present
Score 1	Less than half of the papilla is present
Score 2	At least half of the papilla is present but the papilla tip does not extend to the interproximal contact point.
Score 3	Papilla completely fills the embrasure space and is harmonious with the adjacent papillae.
Score 4	The papilla is overfilling the embrasure and covering the adjacent crown.

## Appendix I

### Visual Analog Scale

After crown placement each patient was given the following 3 questions and a mirror and asked to rate their response to each question on this 100 mm line with "0" being the least favorable response and "100" being the most favorable.

1. I am pleased with the way the implant crown looks compared to the surrounding teeth.

0 \_\_\_\_\_ 100

2. I am pleased with the way the gums around the implant tooth look.

0 \_\_\_\_\_ 100

3. Overall, I am please with my implant tooth.

0 \_\_\_\_\_ 100

Each patient was assigned a score for each question by an investigator who measured with a millimeter ruler the distance from the point designated "0" to the patients marking.

## **CURRICULUM VITAE**

John W. McGehee, Jr., DMD, MS

### **EDUCATION**

2003-2006 University of Louisville Graduate Periodontics  
Certificate in Periodontics

2003-2006 University of Louisville  
Master of Science in Oral Biology

1999-2003 University of Mississippi School of Dentistry  
Doctor of Dental Medicine (D.M.D)

1993-1997 Millsaps College  
Bachelor of Science (B.S.)  
Cum Laude

### **LICENSURE**

June 2003-Present Commonwealth of Kentucky Dental License

June 2003-Present State of Mississippi Dental License

Category II Laser certification 2003

CPR certification 2006

ACLS certification 2004

## **PROFESSIONAL ASSOCIATIONS**

American Dental Association member

Kentucky Dental Association member

Mississippi Dental Association member

American Academy of Periodontology member

Southern Academy of Periodontology member

Academy of Osseointegration member

## **RESEARCH ACTIVITIES**

McGehee J, Greenwell H, Hill M, Martin E, Jones D, Zeena R, Paris M, Morris C, Sheetz J. Implant esthetics using a Nobel Replace standard implant vs. Nobel Perfect scalloped implant placed in immediate extraction sockets in the esthetic zone of the maxilla. Submitted for publication.

McGehee J, Johnson R. Biomarkers of bone turnover can be assayed from human saliva. *J Gerontol A Biol Sci Med Sci.* 2004; 59(3): 196-200.

Poster Presentation of "Biomarkers of bone turnover can be assayed from human saliva" at International Academy of Dental Research in San Antonio, TX .Spring 2003.

Salivary ELISA analysis. Research technician to Roger B. Johnson DDS, Ph.D., Professor in the Department of Periodontics and Department of Anatomy at the University of Mississippi Medical Center. Summer 2000.

Catfish lymphocyte cell culture. Research technician to Craig J. Lobb Ph.D., Professor in the Department of Microbiology and Immunology at the University of Mississippi Medical Center. Summer 1997 to Summer 1999.

## **HONORS AND AWARDS**

Billy M. Pennel Award for Clinical Research. Southern Academy of Periodontology. 3rd Place. June 2006

American Academy of Periodontology Award May 2003

Quintessence Publishing Company Research, Achievement Award May 2003

Recipient of Armed Forces Health Professionals Scholarship July 1999

Order of Omega- Leadership Honorarium May 2002

Fraternity Leadership/Academic Excellence Award August 2002

Beta Beta Beta- Biology Honorarium December 2002

Phi Eta Sigma- Freshmen Scholarship/Leadership Honorarium May 2004

### **EXTERNSHIPS**

Internal Medicine Rotation, University of Louisville Hospital May 2004

Anesthesiology Rotation, University of Louisville Hospital June 2004