

University of Louisville

ThinkIR: The University of Louisville's Institutional Repository

Electronic Theses and Dissertations

12-2011

Incidence of soft tissue calcifications of the head and neck region on maxillofacial cone beam computed tomography.

Adam B. Wells 1977-
University of Louisville

Follow this and additional works at: <https://ir.library.louisville.edu/etd>

Recommended Citation

Wells, Adam B. 1977-, "Incidence of soft tissue calcifications of the head and neck region on maxillofacial cone beam computed tomography." (2011). *Electronic Theses and Dissertations*. Paper 1545.
<https://doi.org/10.18297/etd/1545>

This Master's Thesis is brought to you for free and open access by ThinkIR: The University of Louisville's Institutional Repository. It has been accepted for inclusion in Electronic Theses and Dissertations by an authorized administrator of ThinkIR: The University of Louisville's Institutional Repository. This title appears here courtesy of the author, who has retained all other copyrights. For more information, please contact thinkir@louisville.edu.

**INCIDENCE OF SOFT TISSUE CALCIFICATIONS OF THE HEAD AND NECK
REGION ON MAXILLOFACIAL CONE BEAM COMPUTED TOMOGRAPHY**

By

Adam B. Wells B.A., D.M.D.

Masters Candidate in Oral Biology at the University of Louisville School of Dentistry

A Thesis
Submitted to the Faculty of the
Graduate School of the University of Louisville
In Partial Fulfillment of the Requirements
for the Degree of

Master of Science

Program in Oral Biology
School of Dentistry
University of Louisville
Louisville, Kentucky

December 2011

Copyright 2011 by Adam B. Wells

All rights reserved

**INCIDENCE OF SOFT TISSUE CALCIFICATIONS OF THE HEAD AND NECK
REGION ON MAXILLOFACIAL CONE BEAM COMPUTED TOMOGRAPHY**

By

Adam B. Wells B.A., D.M.D.

Masters Candidate in Oral Biology at the University of Louisville School of Dentistry

A Thesis Approved on

November 21, 2011

by the following Thesis Committee:

William C. Scarfe, B.D.S., F.R.A.C.D.S., M.S.
Thesis Director

Allan G. Farman, B.D.S., Ph.D., D.Sc.
Co-Thesis Director

Zafrulla Khan, B.D.S., M.S.

Sunita Chandramani, D.M.D., M.S.

Anibal Silveira, D.D.S.

DEDICATION

For my wonderful family and dearest friends, who have stood by me and supported me in all my endeavors. My parents, in particular, have taught me that perseverance and dedication are necessary to chasing goals and aspirations. I would like to dedicate this to my parents, sister and dearest friends for their unwavering love and support throughout my educational endeavors and journey through life.

ACKNOWLEDGEMENTS

There are several people I would like to acknowledge for helping in the creation and completion of this research project and thesis. I would sincerely like to thank Dr. William Scarfe for agreeing to mentor this research project. I am grateful to Dr. Scarfe for his unwavering support, guidance, and patience. From the moment he agreed to serve as my mentor for this project as well as the oral biology master's program, he went out of his way to make sure that I was on the right path and understood the intricacies of the project and how to conduct the research. Not only regarding this particular project, but the knowledge and expertise Dr. Scarfe has as a dental radiologist is outstanding. As it took a significant time to finish this project beyond my residency graduation, I cannot thank Dr. Scarfe enough for his patience and his dedication to helping me complete this research project. I would also like to thank Dr. Allan G. Farman for serving as a mentor for, not only this Master's thesis but, for an earlier project leading to this larger study. His knowledge and expertise in the field were crucial to the development and completion of this project. In addition, I would like to acknowledge Dr. Zafrulla Khan for his help in collaborating on an earlier pilot study. Using data from his practice was extremely resourceful. Finally, I would like to thank Drs. Sunita Chandiramani and Anibal Silveira for their help and guidance with many areas of this paper, namely the review of the literature. I also extend gratitude to these two individuals for their dedication to the ULSD Orthodontic Graduate Program and my education during this time. Thanks to all of these people for their dedication to our great field as well their dedication to education.

ABSTRACT

INCIDENCE OF SOFT TISSUE CALCIFICATIONS OF THE HEAD AND NECK REGION ON MAXILLOFACIAL CONE BEAM COMPUTED TOMOGRAPHY

Adam B. Wells

November 21, 2011

The aim of the study was to determine the incidence and imaging characteristics of soft tissue calcifications on cone beam computed tomography (CBCT). 556 CBCT image datasets were reviewed and 308 included. The following conditions were recorded: 1) Carotid artery calcifications (CAC), 2) Triciceous cartilage (TC), 3) Superior cornu of the thyroid cartilage (SCT), 4) Tonsilloliths (T) and, 5) Other including lymph nodes (O). The age and sex of patients who were excluded served as controls. 107 (34.75%) demonstrated at least one calcification. Those with calcifications were approximately 12 years older than controls (t value = 6.32, $p < 0.001$). The incidence of calcifications in decreasing order are TC (11.4%), CAC (10.4%), T (10.4%) and, SCT (5.2%). Differential location and appearance of calcifications were described. Soft tissue calcifications were a common finding with TC, CAC and T presenting in almost equal frequency. Calcifications exhibit unique characteristics on CBCT images.

TABLE OF CONTENTS

	PAGE
DEDICATION.....	iii
ACKNOWLEDGEMENTS.....	iv
ABSTRACT	v
LIST OF TABLES.....	vii
LIST OF FIGURES	ix
CHAPTER	
I. INTRODUCTION AND LITERATURE REVIEW	1
II. STATEMENT OF OBJECTIVES AND HYPOTHESIS.....	24
Study Objectives.....	24
Study Hypothesis.....	24
III. METHODS AND MATERIALS	26
Research Design	26
Sample	27
Data Collection.....	28
Data Coding.....	30
Analysis	32
IV. RESULTS.....	35
V. DISCUSSION.....	74
VI. SUMMARY AND CONCLUSION	87
REFERENCES	88
CURRICULUM VITAE.....	91

LIST OF TABLES

TABLE	PAGE
1. Demographics of sample patients- included vs. excluded: Age.....	37
2. Frequency distribution of sample patients vs. control: Sex.....	37
3. Frequency distribution of sample patients vs. control: Scan Type.....	38
4. Frequency distribution of sample patients: Scan Type and Sex.....	39
5. Sample demographics- Calcification pts vs. controls: Age.....	40
6. Sample demographics- Calcification pts vs. controls: Sex (%)......	41
7. Sample demographics- Calcification pts vs. controls: Scan Type.....	41
8. Frequency distribution of type of calcification within sample.....	43
9. Frequency distribution of patients presenting with multiple calcifications.....	44
10. Carotid artery calcification vs. controls: Age.....	53
11. Carotid artery calcification vs. controls: Sex.....	54
12. Carotid artery calcification vs. controls: Scan Type.....	54
13. Carotid artery calcification location according to vertebral level & side.....	55
14. Comparative dimensions of CAC according to side location.....	56
15. Comparative dimensions of CAC according to uni- or bilateral distribution.....	56
16. Triticeous cartilage calcification vs. controls: Age.....	60
17. Triticeous cartilage calcification vs. controls: Sex.....	60
18. Triticeous cartilage calcification vs. controls: Scan Type.....	61

19. Tonsillar tissue calcification vs. controls: Age.....	64
20. Tonsillar tissue calcification vs. controls: Sex	64
21. Tonsillar tissue calcification vs. controls: Scan Type	65
22. Thyroid cartilage calcification vs. controls: Age.....	69
23. Thyroid cartilage calcification vs. controls: Sex	70
24. Thyroid cartilage calcification vs. controls: Scan Type	70
25. Frequency distribution of patients demonstrating “Other” calcifications	73

LIST OF FIGURES

FIGURE	PAGE
1. Panoramic radiograph demonstrating carotid artery calcifications	8
2. Carotid artery calcifications on panoramic and PA cephalometric radiographs.....	9
3. Stylohyoid ligament calcification on panoramic radiograph.....	14
4. Thyroid cartilage calcification on lateral cephalometric radiograph.....	16
5. Salivary gland calcification on panoramic radiograph.....	19
6. Lymph node calcification on panoramic radiograph.....	20
7. Tonsillar tissue calcification on panoramic radiograph.....	22
8. Phlebolith on panoramic and PA cephalometric radiograph	23
9. Frequency distribution of patient sample based on age.....	39
10. CBCT images of three common soft tissue calcifications	42
11. Axial CBCT projections of carotid artery calcifications	46
12. Axial CBCT projections of carotid artery calcifications	47
13. Axial CBCT projections of carotid artery calcifications	48
14. Axial CBCT projections of carotid artery calcifications	49
15. Coronal CBCT projections of carotid artery calcifications	50
16. Sagittal CBCT projections of carotid artery calcifications.....	51
17. Sagittal CBCT projections of carotid artery calcifications.....	52
18. Sagittal CBCT projections of carotid artery calcifications.....	52
19. Axial CBCT projections of triticeous cartilage calcifications.....	57

20. Coronal CBCT projections of triticeous cartilage calcifications.....	58
21. Sagittal CBCT projections of triticeous cartilage calcifications	59
22. Axial, Coronal, & Sagittal CBCT projections of calcifications of the tonsils.....	63
23. Axial CBCT projections of thyroid cartilage calcifications	66
24. Coronal CBCT projections of thyroid cartilage calcifications	67
25. Sagittal CBCT projections of thyroid cartilage calcifications.....	68
26. Axial, Coronal, & Sagittal CBCT projections of lymph node calcifications	71
27. Axial CBTC projection of peripheral skin tissue calcifications	72
28. Axial, Coronal, Sagittal CBCT projections of cerebral tissue calcification.....	72

CHAPTER I

INTRODUCTION AND LITERATURE REVIEW

The purpose of this research is threefold: 1) To provide a thorough review of the literature on the etiology, pathogenesis, presentation and significance of common soft tissue calcifications in the head and neck region potentially observed radiographically in dental practice, 2) To report the incidence of these conditions on a sample of patients referred for cone-beam computed tomography (CBCT) and, 3) To characterize the imaging appearance of these conditions. We hope to provide clinicians with an understanding of the incidence, presentation and significance of common soft tissue calcifications on CBCT images and how these characteristics may differ from what is known on conventional 2-D images.

The Significance of Calcifications in the Head and Neck Region

Calcifications of various structures located in the head and neck region are a relatively common occurrence in the population at large and should also be present on patients seeking dental care. Calcifications are detected on conventional imaging used in dental practice especially panoramic radiography. However many of the structures in the head and neck region are in close proximity to one another which makes localization and identification difficult. In addition detection and confirmation is complicated on conventional extra-oral dental images by the fact that most radiographic images in

dentistry are planar, that is, provide a two dimensional (2-D) representation of a three dimensional (3-D) object. This potentially results in the both false positive and false negative detection of various calcifications on conventional images. Some of the calcifications of concern in this region include, but are not limited to calcification of atherosclerotic plaques within the carotid arteries (both intra- and extra-cranially), the thyroid cartilage, the triticeous cartilage, the stylohyoid ligament, tonsillar concretions, lymph nodes, salivary glands, calcified acne areas, as well as calcifications of the venous system (phleboliths). There is a gap in the current literature in clinical guidelines for the localization and characterization of various calcifications in the head and neck region using different imaging modalities. This is certainly necessary on panoramic imaging and, perhaps, more importantly, for cone beam computed tomography (CBCT). With the rapid adoption of CBCT imaging in dental practice, particularly by practitioners other than those trained in oral and maxillofacial imaging, research providing information on the incidence and presentation of the calcification characteristics of these structures will aid the clinician to, if not definitively diagnose, at minimum, formulate a differential diagnosis leading to a more appropriate referral protocol. As health care costs continue to rise, avoiding unnecessary and unjustified diagnostic tests and referrals is a welcome consequence of an increase in the understanding of the nature of soft tissue calcifications in the head and neck. Proper knowledge and diagnosis of these calcifications will afford the clinician the ability to seek more diagnostic information, refer to a physician, further monitor the condition, or do nothing at all in situations not warranting further action.

Cone beam computed tomography is gaining more widespread use in multiple fields of dentistry and is an exciting and welcomed tool. However there is scant literature

of dental relevance on the anatomy of these structures and how they present when they are calcified.

The Process of Calcification

It is important to understand the process of calcification, or mineralization, of soft tissues including the vasculature. According to Kirsch [1], physiological mineralization is restricted to specific sites in skeletal tissues, including growth plate cartilage, bones, and teeth. Uncontrolled or pathological mineralization can occur in any soft tissue. Articular cartilage, cardiovascular tissues, the kidney, ligaments and even tonsils are prone to undergo pathological mineralization. The mineralization of arteries leads to morbidity and mortality, whereas mineralization of articular cartilages, and often ligaments, can lead to their destruction and joint stiffness. Interestingly, recent studies have shown that components regulating physiologic mineralization are also present in areas of pathological mineralization suggesting that the mechanisms regulating pathological mineralization may be similar or identical to those regulating physiological mineralization. Although physiological mineralization is a complex process involving a well-balanced interplay between inhibitory and stimulatory components, recent *in-vitro* and *in-vivo* studies have identified some of these components and mechanisms that regulate physiological mineralization. Mouse models and other studies have supported the suggestion that the same or similar factors and mechanisms controlling physiological mineralization may also regulate pathological mineralization. Therefore, a detailed understanding of the roles of various factors and the coordinated interactions between those factors in regulating physiological mineralization will provide novel therapeutic

strategies to prevent ectopic or pathological mineralization. [1, 2]

According to Shroff and Shanahan, [2] vascular calcification is an active, cell-mediated process that results from an imbalance between the promoters and inhibitors of mineralization. The process of vascular calcification shares many similarities with that of skeletal mineralization. However, while skeletal mineralization is a regulated process induced by complex well-timed developmental cues, vascular calcification is a pathological process occurring in response to dysregulated and inappropriate environmental cues. Many aspects of the mechanisms underlying vascular calcification have been defined through in vitro studies and molecular biological techniques; however, there are still unanswered questions, particularly with respect to the relationship between bone and vascular calcification processes. A better understanding of the complex mechanisms regulating tissue calcification may yield novel therapeutic approaches in reducing the cardiovascular disease associated morbidity and mortality in patients with these pathologic changes.

The two most important mechanisms of calcification are dystrophic and metastatic calcification. Dystrophic calcification occurs in soft tissue tissues that normally do not contain such deposits and result due to chronic inflammation, necrosis or scarring. The deposition of mineral salts in dead or degenerating tissues is referred to as *dystrophic calcification*. In contrast, metastatic calcification is the process by which normal undamaged tissues are calcified by means of a hypercalcemia such as that which occurs in hyperparathyroidism. The minerals deposited in the tissues may not necessarily be calcium salts exclusively.

This brief review of the forms of calcifications and accompanying descriptions is

not intended to be fully comprehensive and exhaustive. It provides only a brief background as it pertains to this study, which investigates calcifications of various head and neck structures.

Calcification of Structures in the Head and Neck

Structures which can undergo pathological calcification in the head and neck region include but are not limited to; atherosclerotic plaque deposits within the intra- and extra-cranial (particularly at the bifurcation region) carotid arteries, the thyroid cartilage, the triticeous cartilage, the stylohyoid ligament, the para-pharyngeal tonsillar crypts, the lingual arteries, the supra-clavicular lymph nodes, the salivary glands, the sub-dermal facia (e.g. calcified acne areas), and the venous system (phleboliths). These areas, when calcified, will often appear as radiopaque masses of various sizes, shape and often in specific locations, on conventional extra-oral radiography. Detection of calcified masses on CBCT images however may present with greater frequency as this modality provides multiple viewing modalities. Most calcifications within the head and neck are relatively benign in nature and are associated with few negative outcomes. Therefore detection, or lack thereof, by any imaging modality is of little clinical consequence in many circumstances. However dystrophic calcification in some tissues may suggest the presence of a systemic condition and represent a manifestation of more potentially ominous sequelae. It is therefore important for the dental clinician to possess a solid foundation in his or her understanding of the anatomy of the head and neck structures. A mastery of sectional head and neck anatomy will enhance the clinician's ability to understand the radiographic presentation of each structure, leading to a stronger ability to

recognize and diagnose changes (i.e. calcifications) within these head and neck structures. [3] More appropriate dental and/or medical referral and less potential for a poor outcome for these patients, along with a reduction in the ever-increasing medical expenditures in this country will be the result of a more widespread, thorough comprehension of head and neck structure calcifications.

Structures of the Head and Neck commonly undergoing Calcification

Carotid Artery Calcification

Carotid arteries are not uncommonly found to be calcified on routine forms of dental radiography including panoramic, lateral and frontal cephalometry, as well as CBCT imaging. As these arteries provide the main blood supply to the brain, any pathologic calcification in this area is associated with potentially morbid consequences. Atherosclerosis is a pathological condition of the arterial vasculature. It is beyond the scope of this research paper to discuss the details of the pathophysiology of the atherosclerosis process; however, calcification is a potential finding in atheroma-related thrombi and emboli. Atherosclerotic conditions of a carotid artery can lead to neural ischemia (inadequate oxygen to the brain from thrombus formation or embolus) thus resulting in a cerebrovascular accident, or stroke. In the United States, 731,000 suffer a stroke each year with 165,000 not surviving. [3] There are approximately 4 million stroke survivors. Lifelong disabilities such as loss of mobility and motor skills, aphasia, and depression often afflict survivors. [4] Estimated healthcare costs related to acute and chronic management of strokes are \$40 billion annually. Atheroma-related formations of

thrombi and emboli in the carotid artery is the most frequent cause of stroke. [5]

Calcification in the carotid arteries may be visualized by a variety of dental imaging modalities which include coverage of the cervical region. These radiographic images include postero-anterior skull, cephalometric, and panoramic examinations. Over the past 2 decades, several studies have shown that partially or fully calcified atherosclerotic plaques in the region of the carotid bifurcation can be detected by panoramic radiography. [6-8] Since 1981, Friedlander and his colleagues have actively promoted panoramic radiology as an aid in detecting patients at risk of stroke. [6] The prevalence of carotid calcifications, as diagnosed on panoramic radiographs, varies from 0.1% to 3.2% among patients above 50 years of age. On panoramic radiographs, calcified plaques in the carotid vessel are usually occur at the carotid bifurcation and are located postero-inferior to the angle of the mandible (Fig. 1) adjacent to the cervical spine and hyoid bone. Such atheromas may appear as nodular radiopaque masses or as double radio-opaque vertical lines within the neck. These calcifications are found at the level of the lower margin of the third and the entirety of the fourth cervical vertebra, about 1.5 to 2.5 cm inferior-posterior to the angle of the mandible. [9]

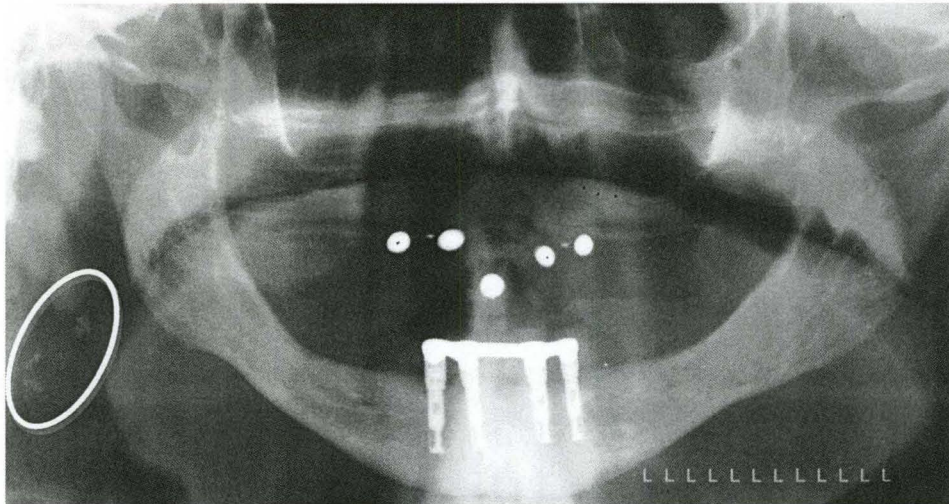
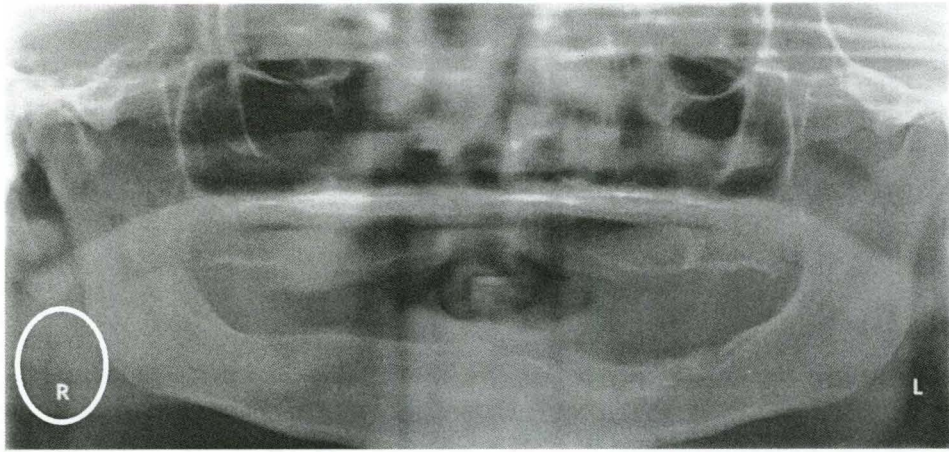
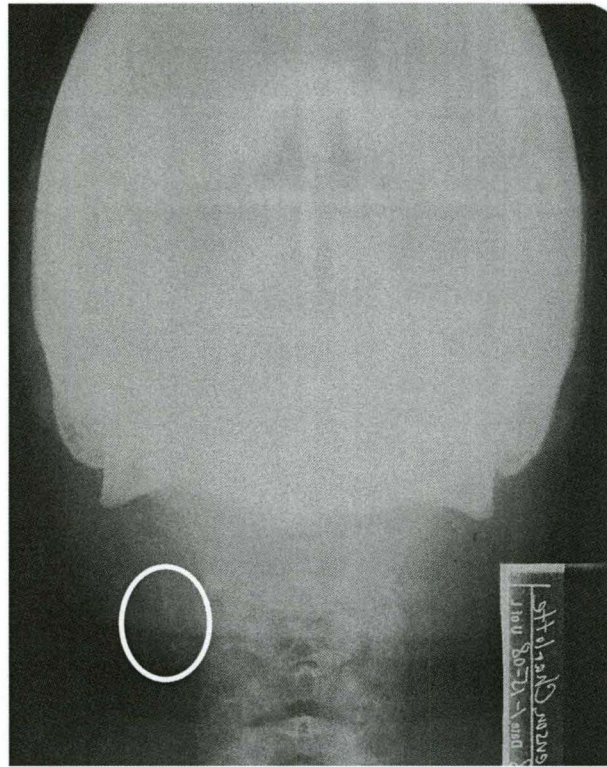


Figure 1. Panoramic radiograph of a patient presenting for the assessment of potential implant sites in the totally edentulous maxilla demonstrating carotid artery calcifications on the right (circle).



a.



b.

Figure 2. Carotid artery calcifications on panoramic radiography (circle) (a) and as confirmed on a posterior-anterior cephalometric (circle) (b).

Similar calcifications are found in the coronary arteries of individuals having ischemic heart disease.[10] Atherosclerosis is not the only cause of soft-tissue calcifications seen anterior to the cervical vertebrae in panoramic radiographs. Care needs to be applied to differentiate carotid calcifications from calcified triticeous or thyroid cartilages, calcified lymph nodes and non-carotid phleboliths, or normal anatomy in the area (i.e. hyoid bone). For this reason, when using 2D images it is important to have an Anterior-Posterior (AP) radiograph of the neck made using soft tissue exposure settings (Fig. 2). In this projection calcifications within the carotid arteries will appear lateral to the spine, whereas calcifications in the thyroid gland, thyroid cartilage, triticeous cartilage or epiglottis will be in the midline, superimposed over the spine. Other calcifications that can be superimposed over the same part of the panoramic film include phleboliths (sclerosing hemangiomas), and calcified acne or lymph nodes. The stylohyoid and stylomandibular ligaments are situated more posterior than inferior to the mandibular ramus and therefore should be readily differentiated. It is also important to be cognizant of the prevalence of these conditions in the general population; it is equally important to note any associations or factors that increase the incidence of carotid plaque calcification. Between 1981-2003, there were 39 peer reviewed dental manuscripts and 29 pertinent abstracts reporting the observation of incidental carotid calcifications visible on routine panoramic radiographs. These studies documented a 3% to 5% prevalence of carotid artery calcifications in the general dental population, with higher percentages occurring in patients having medical illnesses associated with advanced atherosclerosis. Most carotid plaques accumulate at the bifurcation of the internal and external carotid arteries, as the shear forces are greatest in areas of arterial bifurcation. Studies that

reported more than anecdotal information documented prevalence rates ranging from 3% to 5% in a patient population with a benign general medical history and without history of prior stroke or transient ischemic attack (TIA), and from 22% to 37% in populations exhibiting a medical history with atherosclerotic risk factors (e.g. hypertension, cardiovascular disease, past stroke/cardiovascular accident (CVA), TIA or diabetes). These studies also demonstrated that the older the patient population, the greater the prevalence of such calcifications. Other risk factors associated with increased incidence of carotid plaque calcifications include, but are not limited to: hypercholesterolemia, obesity and physical inactivity, cigarette smoking, sleep apnea, head and neck radiation therapy, and male gender.

In another study, examining a total of 500 panoramic radiographs, 4% showed evidence of carotid calcification. Of those, 346 subjects that had no pertinent medical history, 2.6% had calcification. Of the 154 subjects with a pertinent medical history, 7.1% had calcifications.[11] In other words, carotid calcifications are nearly three-times more likely to be seen on panoramic radiographs of patients with a medical history that places them at high risk for stroke.

Furthermore, carotid calcifications on panoramic radiographs are an important marker for vascular risk. [12, 13] Eighty-six percent of subjects found to have carotid artery calcifications on routine panoramic films have one preexisting vascular risk factor, and 73% have multiple risk factors. The predictive value of a panoramic radiograph with a calcified atheroma is also very significant. Fifty-seven percent of such patients within 2.7 years (on average) suffer myocardial infarction (11%); stroke (7%); death (15%); revascularization procedures (11%); transient ischemic attack (3%); and angina

(10%).[13] These events not only lead to staggering health care costs but, most importantly, are life-threatening and altering to even fatal. Early detection may lower these figures and prevent these outcomes for those at risk.

An appropriate referral protocol to a medical specialist is important if a dental practitioner suspects calcification of atheroma of the carotid artery. While the panoramic image is a good screening tool, it is not the ultimate end point in diagnosis. The best diagnostic, non-invasive, tool currently used is duplex ultrasonography. This provides the best information for determining the degree of stenosis of the artery, which is directly related to the risk of a stroke. Recently Yin and colleagues determined that ultrasonography is only cost-effective to screen for carotid stenosis if the prevalence of stenosis in the screened populations was at least 4.5%.[14] Given that the prevalence in the overall general population is below 4.5%, panoramic imaging, in addition to known risk factors, can be a non-invasive tool to aid in proper referral which is cost-effective and, more importantly, can decrease associated morbidity.

There is a great deal of focus and research on calcifications of the carotid arteries for obvious reasons; however, there is more scant literature on the remaining areas potentially found to be calcified in the head and neck region. For the remainder of the introduction, other types of head and neck calcifications will be discussed.

Stylohyoid Ligament

Another head and neck structure often calcified is the stylohyoid ligament. This ligament stretches from the styloid process of the temporal bone inferiorly to the hyoid bone. It is useful to recall that the hyoid bone, the styloid process, and the stylohyoid

ligament are all derived from Reichert's cartilage in the second branchial arch. [15-18]. It appears to be relatively common and can be routinely found on radiologic imaging of the head and neck region, although the reported incidence ranges from approximately 1% to 80%.[15, 16] O'Carroll reports that incidence is proportional to age with a sharp increase in incidence of calcification during the first three decades of age from 45.3% in the first decade to 86.2% in the third, with a gradual increase from the fourth to the seventh decade (87.3% to 92%).[16] In this study the incidence increases to 100% by the eighth decade. Other authors have not found an increase in incidence with age.[19].

Two theories have been proposed on the etiology and pathogenesis of calcification of the stylohyoid ligament. One theory is that degeneration of the ligament with deposition of calcium salts in the fibrous tissue accounts for the condition. Others support a developmental theory, where direct ossification of cartilaginous cells remaining in the ligament (recall Reichert's cartilage) in patients of adult age contributes. Research on this is still needed, and possibly a combination of both theories is more accurate. There appears to be no race predilection for calcification, a slight sex predilection for females, and an age incidence that seems to support both the developmental and degenerative theories of etiology of calcification in the stylohyoid ligament.

Clinically, osseous elongation of the styloid process or calcification of the stylohyoid ligament complex may give rise to clinical symptoms of facial pain, throat discomfort, otalgia, dysphagia, headache or vertigo. It is also known to impinge on the carotid arteries potentially contributing to more serious implications.[17] When multiple symptoms are present, the condition is referred to in a variety of ways, including Eagle's syndrome, elongated styloid process syndrome, styloid process-carotid artery syndrome

in addition to others.[20, 21] Each of these syndromes has slight variations from one another and it is beyond the scope of this paper to discuss those differences in detail.

Radiographically, this presents very commonly on virtually any extra-oral radiograph of the maxillofacial region including panoramic imaging. In less advanced cases a single calcified line, generally in the upper part of the ligament, is evident.[22] Other times, there may be multiple calcified segments along the ligament, while in more extreme cases a complete ossification of the ligament may be seen. The normal length of the styloid process is usually considered to be approximately 25 to 30mm.[20] Some believe, due to the magnification factor of panoramic and other forms of extra-oral radiography, the norm should be in the area of 35mm. Most consider lengths of greater than 35mm to be elongated. Research using 3D imaging is scarce and little was found in the literature.

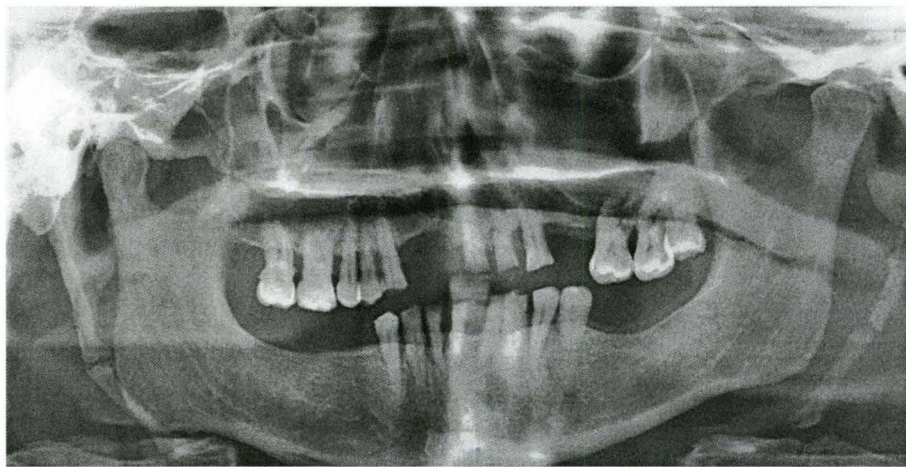


Figure 3. Prominent elongated and calcified stylohyoid ligament calcification on panoramic radiography

Triticeous Cartilage

Triticeous (tri-tish'us) cartilages are bilateral ovoid structures that are part of a complex of structures found in the area of the laryngeal skeleton.[23, 24] The triticeous

cartilage is located centrally in the lateral thyrohyoid ligament at the level of third and fourth cervical vertebrae (C3-C4). Clinically, the triticeous cartilage has no known function; although recently it has been suggested that it might help reinforce the lateral thyrohyoid ligament.[23] When calcified, the triticeous cartilage can be readily seen on a panoramic radiograph and, due to its location, can be misdiagnosed as a calcification in the carotid artery or other dystrophic calcifications of soft tissue. Since calcified carotid atheromas are a risk factor for stroke, clinicians need to differentiate between a calcified triticeous cartilage and a calcified carotid atheroma.

According to Ahmad, *et al.*,[25] the prevalence of triticeous cartilage on panoramic radiographs was 5.0% in males and 12.0% in females. The prevalence was 9.3% in the 40- to 60-year-old group and 7.8% in the group older than 60 years and not age dependent. In contrast Hately, *et al.*,[26] reported that calcification of the triticeous cartilage occurs more prevalently in men. In this study, 29% of men and 22% of women were affected.

Ahmad, *et al.*[25] classified the radiographic appearance of triticeous calcifications and compared and contrasted their appearance with carotid artery calcifications. Differentiation between triticeous cartilages and carotid atheromas was possible based on shape and outline of the calcifications. Calcified carotid atheromas were mostly linear, with irregular margins and appeared punctate and with areas of radiolucencies. Calcified triticeous cartilages were mostly oval, with a smooth, well-defined corticated border.[25] These ovoid radiopacities, approximately 2mm to 4 mm wide by 7mm to 9 mm in length, are usually imaged within the pharyngeal air space adjacent to the superior portion of C4.[26, 27]

Thyroid Cartilage Calcification

The thyroid is the largest and most superior of the cartilages of the larynx and is suspended immediately below the hyoid bone by the thyrohyoid membrane, median and lateral thyrohyoid ligaments. The latter extends from the terminal portion of the GCHB inferior to a lateral prominence called the superior cornu of the thyroid cartilage. In the thyroid cartilage, calcification is a progressive condition[28] that normally starts at the posterior border, the lower margin, and the inferior horn of the thyroid cartilage and is completed around the age of 70 years.[29] Calcification of the superior cornu of the thyroid (SCT) on panoramic imaging only occurs in older individuals and presents in the same regional location as the TC (Calcified triticeous cartilage) and more importantly the CAC (Carotid artery calcification).[11]

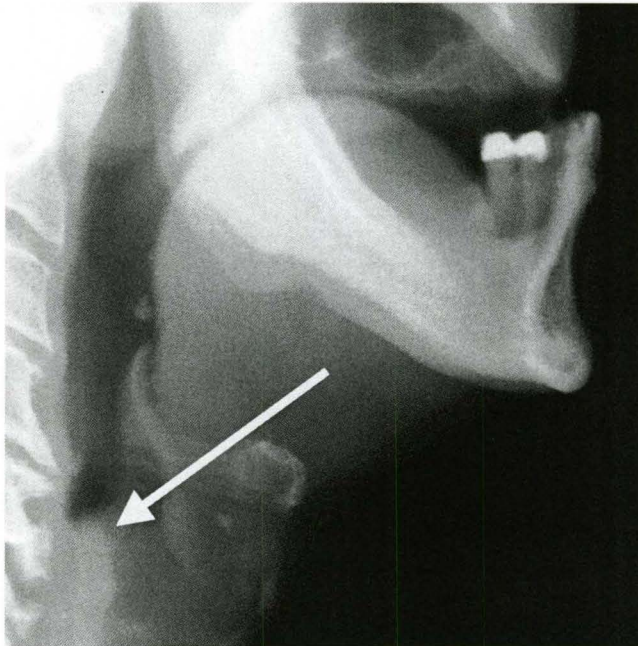


Figure 4. Thyroid cartilage calcification. Cropped view of the lateral cephalometric radiograph showing the calcified superior cornu of the thyroid cartilage seen extending superiorly just anterior to the 4th cervical vertebra (arrow).

Sialoliths

A sialolith is commonly defined as an aggregation of calcified material found within the ducts or glandular tissue of salivary glands. It is also referred to as a salivary stone or salivary gland calculus. It is one of the most frequent disorders of salivary glands, second only to viral parotitis (mumps). Patients can be afflicted any time from the first decade of life on, with the peak incidence occurring between the fourth and the sixth decades. According to Gordon, *et al.*, males are affected twice as often as females.[30]. Iro, *et al.*,[31] however found no race or sex predilection. The submandibular gland is the most affected major salivary gland accounting for 80% of cases. The parotid gland is affected in 19% of cases and is the second most affected, followed by the sublingual gland showing calcifications in only 1% of cases.[30] Sialoliths can also occur in minor salivary glands, primarily in the upper lip and buccal mucosa.[32]

Stones in the submandibular gland tend to form near the hilum of the gland or in the proximal portion of Wharton's duct. Parotid calcifications are most commonly located in Stenson's duct and usually distinguished from submandibular sialoliths by location and by size and number, as they are smaller and multiple in nature. Pathogenesis appears to be related to the pH level of the saliva (a more alkaline or basic pH favors calculus formation), mucus content of the saliva, salivary flow stasis, physical course of the duct[30] and the formation of eosinophilic crystalloids in the ducts.[33] Patients with sialolithiasis may be totally asymptomatic, or they may develop an obstructive sialadenitis characterized by pain and periodic swelling, especially around mealtime when salivary flow is stimulated.

Sialoliths may be discovered on routine films in asymptomatic patients. Submandibular sialoliths may appear on a periapical film as a radiopacity superimposed over the alveolar bone and possibly the roots of mandibular teeth. Submandibular sialoliths are difficult to see on panoramic films because most of Wharton's duct is not within the focal trough. If a sialolith is suspected, a mandibular occlusal film is indicated. Parotid sialoliths may be seen on a panoramic film superimposed over the ramus (Fig. 5). Detection of sialolithiasis can also be aided with the use of sialography. This procedure involves the injection of radiopaque contrast medium into the duct system of a major salivary gland. Computed tomography is superior to sialography alone in the assessment of space-occupying lesions of salivary glands; however it may be used in conjunction with sialography.[34] Sialoliths causing obstructive symptoms in a patient should be removed. If the stone is located near a duct orifice, it is possible to remove the obstruction without removing the salivary gland. There are several clinical states that simulate sialolithiasis, such as vascular lesions. Vascular lesions, such as hemangiomas, can be extremely serious and need to be readily differentiated from sialoliths. A false positive diagnosis of a vascular lesion (when the accurate diagnosis is a salivary gland calcification) may lead to a deadly, unnecessary surgical procedure. Further examinations must be held when the clinical and radiographic signs are not conclusive. Many authors recommend performing plain radiographs from different angles, sialography of the adjacent salivary gland, ultrasound, CT scan and diagnostic sialoendoscopy. In order to differentiate the vascular lesions from sialoliths, it is wise to perform Doppler sonography examination. In summary, radiopacities located in the salivary gland region are not always sialoliths. Although rare, other pathologies must be

included in the differential diagnosis, and one must avoid misdiagnosing vascular lesions as sialoliths in order to avoid unnecessary life-threatening procedures.[35]

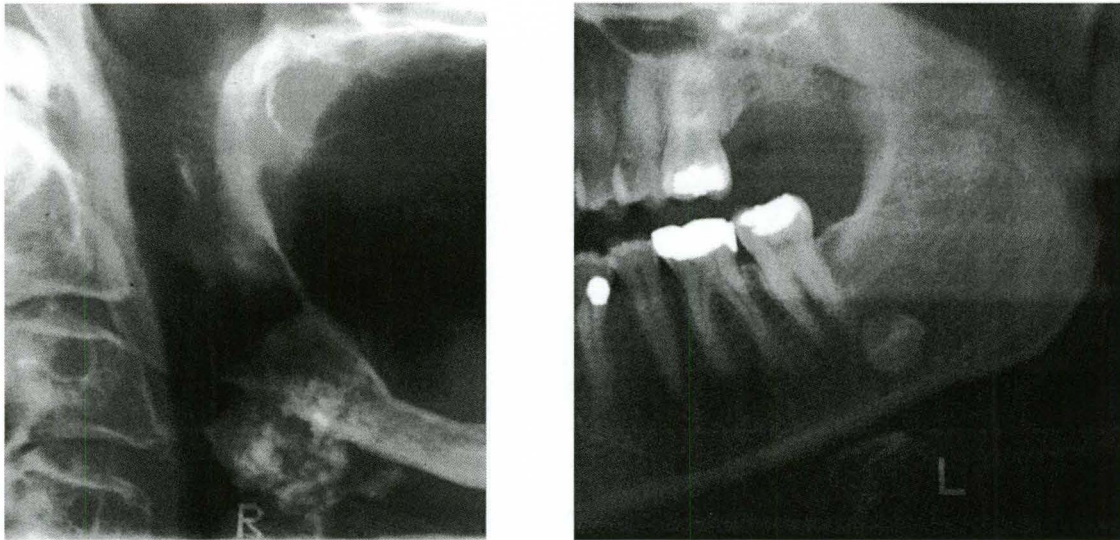


Figure 5. Large coalescing calcified salivary glands (Sialoliths) superimposed on right edentulous mandible extending below the lower border of the mandible (right) and small single discrete sialolith superimposed over inferior alveolar canal on the left dentate mandible (right).

Lymph Nodes

Calcification of the lymph nodes in the head and neck region is another possible radiographic finding presenting on conventional or CBCT imaging. A calcified lymph node usually is asymptomatic, but the clinician may be able to detect it on palpation. In many cases, patients who have a history of chronic inflammation in the area or patients who have been treated for lymphoma commonly present with calcified nodes. [36] A single lymph node can be calcified or several may be affected. Common sites in which a

dentist may discover calcified lymph nodes include the submandibular, submental, preauricular, and lymph nodes of the cervical areas. Radiographically, these calcifications usually appear as distinct, irregularly shaped opacities. The irregular shape is a radiographic trademark and may be described as “cauliflower-like.” In dental practice, they are most often observed on panoramic films, where they present below the inferior border of the mandible and near the mandibular angle (Fig. 6). They must be differentiated from a sialolith in the submandibular duct or gland. One potential method to differentiate between the two is to note that calcified lymph nodes are often multiple, whereas a submandibular sialolith is most frequently solitary. No treatment has been suggested for calcified lymph nodes other than noting its presence and radiographic and clinical monitoring.

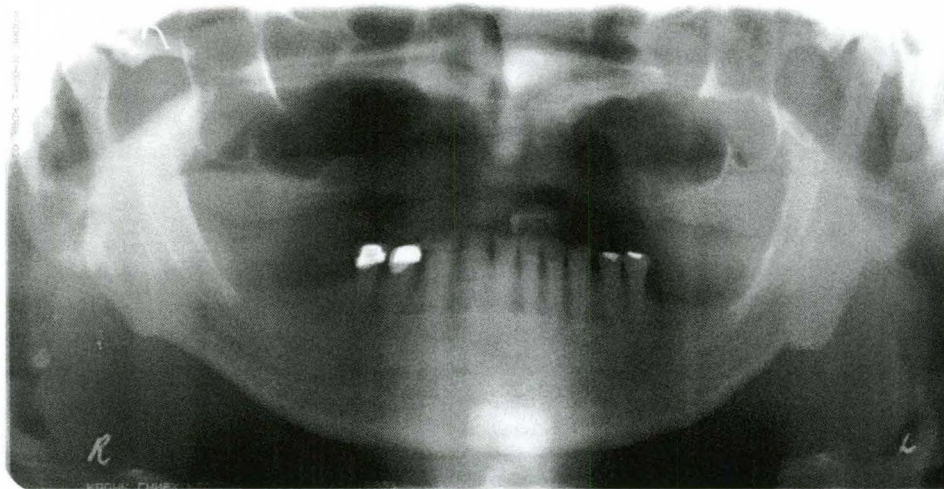


Figure 6. Calcified lymph node. This figure shows the presence of a calcification of the right cervical lymph node.

Tonsilloliths

Tonsilloliths range from small to very large areas of calcifications thought to be

resulting from recurrent tonsillitis and retention of bacterial debris in the tonsillar crypts[37]. Others believe the etiology is due to stasis of saliva in the efferent ducts of the accessory salivary gland, secondary to mechanical obstruction arising from post-tonsillectomy scars or chronic inflammation.[38] The affected patient is usually a young adult with a long history of recurrent sore throats. The patient may be asymptomatic or may complain of persistent throat irritation, foul taste and odor, otalgia, or foreign body sensation[39]. The mineralized material in tonsilloliths has been reported to be primarily calcium hydroxyapatite and calcium carbonate apatite.[39].

The age range of the patients with tonsilloliths described in the literature is from 10 to 77 years with a mean of 50 years and a 1:1 male/female ratio. As for location, tonsilloliths found are distributed as follows: 21.2% in the tonsillar fossa, 69.7% in the tonsillar tissue and 9% in the palate. The size of the concretions ranged from a few millimeters to several centimeters. Frequently, the tonsillolith is hard in consistency, can be single or multiple, can vary in shape, and can vary greatly in color.

Tonsilloliths may be discovered on routine films in asymptomatic patients. Asperstrand and Kolbenstvedt[40] found tonsillar calcifications in 16% of 100 patients who received CT scans of the oropharyngeal region. These calcifications are also often visible on panoramic images as small opaque masses in soft tissues near the anterior border of the oropharyngeal airway space (Fig 7). Axial CT sections may demonstrate these lesions and may provide additional information when differentiation among calcification of the lymph nodes, salivary glands or tonsils, or other potentially calcified structures in the region is difficult.[40] With regard to therapy, a tonsillolith can usually be removed by curettage under local anesthesia.[41-43] An incision is often necessary to

expose it. Tonsillectomy is indicated for patients with chronic tonsillitis.[44]

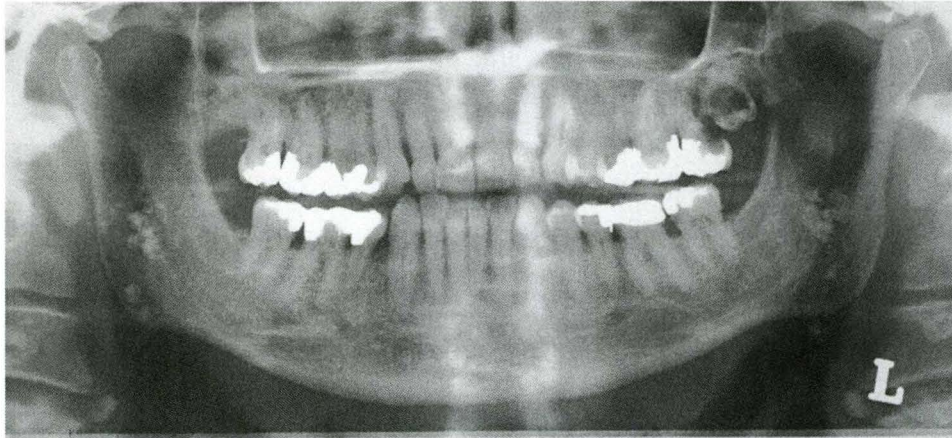


Figure 7. Calcified tonsillar tissue (Tonsillolith) bilaterally superimposed over oropharyngeal airspace.

Phleboliths

A phlebolith is a calcified vascular thrombus that is most frequently associated with a vein, venule, or hemangioma not contained within bone. Their formation is thought to be as a result of vascular anomaly, which induces thrombus formation. The end result is calcium deposit with eventual stone formation.[45] They are usually laminated with a radiopaque centre (“onion-like” appearance) and are spherical in shape. The phlebolith usually points out the occurrence of hemangioma in the juxta-salivary region in a plain X-ray film (Fig. 8).

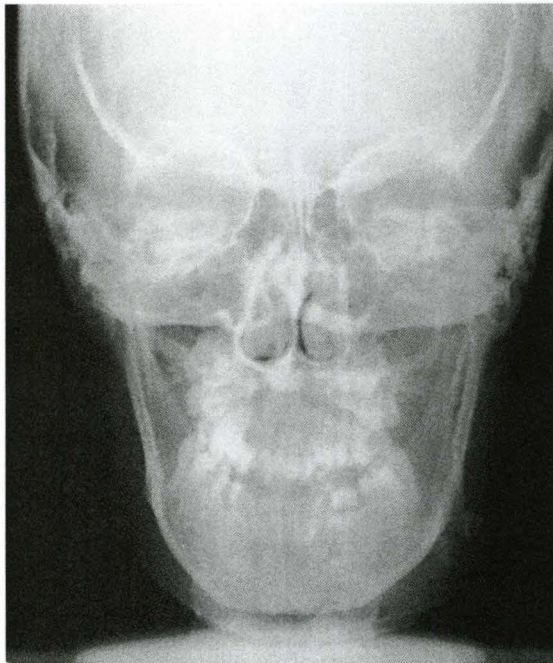
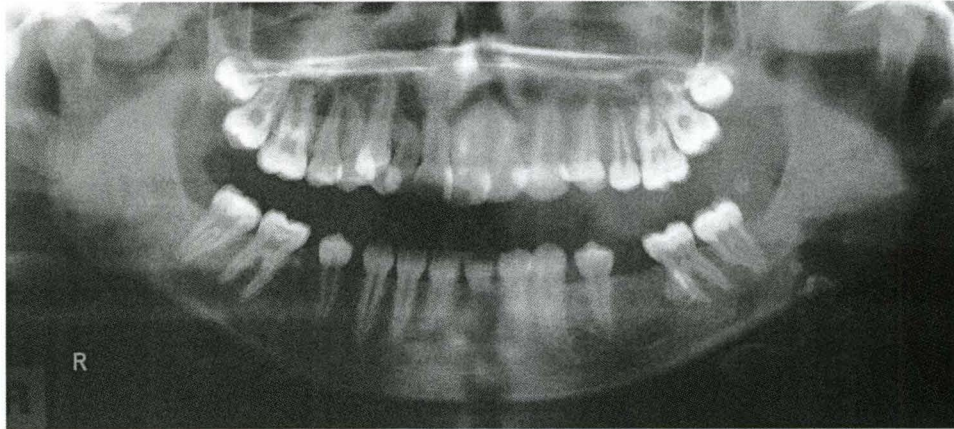


Figure 8. Multiple phleboliths superimposed and circumscribing the left right mandibular body and ramus on a. panoramic (a.) and cephalometric (b.) images.

CHAPTER II

STATEMENT OF OBJECTIVES AND HYPOTHESES

Study Objectives

The aim of this research is to quantify the incidence of and characterize soft tissue calcifications detected on a sample of CBCT images. This is important because there is a gap in the literature on how these soft tissue calcifications present on CBCT. Although much has been investigated on how these various calcifications present on 2D images, there is scant research studying the 3D image characteristics as well as the demographics of these conditions. Being able to view soft tissue calcifications in three dimensions should give more detail on the precise location and presentation, facilitating diagnosis. Furthermore, this research could lead the dental clinician and/or oral and maxillofacial radiologist to make more appropriate referrals and eliminate unnecessary medical referrals. This could ultimately cut medical expenditures, and more importantly reduce negative outcomes associated with certain broader medical conditions found to affect the head and neck region.

Specific Aims

The specific aims of this study were to:

1. Identify the overall incidence of dystrophic calcifications involving the

head and neck soft tissues identified on a sample of patients presenting for CBCT imaging.

2. Describe the demographics (i.e. age and sex) of patients who present with soft tissue calcifications as well as the demographics for each soft tissue structure involved
3. Describe and characterize the specific imaging characteristics of each dystrophic calcification including location, size, and shape, number (one or multiple), and sidedness.
4. Specifically analyze the dimensions of carotid artery calcifications including the relational cervical vertebral superior-inferior height, the lateral-medial width, and anterior-posterior length.

CHAPTER III

METHODS AND MATERIALS

Research Design

The purpose of this study was to determine the incidence and characterize the imaging presentation of soft tissue calcifications in the head and neck region from a sample of patients who presented for cone beam computed tomography (CBCT) to a university-based oral and maxillofacial radiology imaging facility. This was a retrospective study design conducted at the University of Louisville School of Dentistry in Louisville, Kentucky. We hypothesized that dystrophic calcifications would be a common finding on CBCT imaging. We hoped to elucidate new information on the image characteristics of various types of calcifications as well as the demographics of the calcification group as a whole and demographics relevant to each subgroup. The sample was obtained from a retrospective audit of approximately 500 radiographic reports performed over a 12 month period; the calendar year 2007. The nature of this study precludes a prospective, randomized clinical trial.

Axial, coronal and sagittal orthogonal CBCT views were used to determine the presence of calcification in the head and neck region. Further information noted included age of the patient at the time of the scan, sex, scan type including field of view, and type of calcification or area affected. Additional information was noted for calcifications within a carotid artery including size, shape, sidedness, and whether the calcification was

single or multiple.

Sample

The subject sample consisted of all the CBCT patient scans (iCAT™, Imaging Sciences International, Hatfield, PA) from an independent University-based imaging facility located in Radiology and Imaging Science at the University of Louisville School of Dentistry, Louisville, Kentucky. This imaging referral service is operated as an intramural private faculty practice within the Faculty Private Practice (FPP) administrative structure in accordance with the University of Louisville School of Dentistry Faculty Handbook. All interpretive reports were performed and generated by either Drs. Allan G. Farman or William C. Scarfe. Both are registered dentists, board certified and licensed specialists in the Commonwealth of Kentucky in Oral and Maxillofacial Radiology. Radiology patients had been referred for CBCT imaging from both within the School of Dentistry and from clinicians in private practice.

Institutional Review Board (IRB) approval was granted on December 18, 2007 (IRB Tracking# 07.0137) through the Expedited Review Procedure, according to 45 CFR 46.116(b) and 45 CFR 46.116(D). The study was closed October 6, 2008. This study involved only the retrospective use of an imaging report database treatment records. The radiologic reports for all patients over the period were developed using a database (FileMaker Pro Version.10.0v3, FileMaker, Inc. Santa Clara, CA). This program allowed for the export of specific fields within the report.

Only limited, relevant patient information was extracted from these records and consisted of the date the scan was performed, the sex and age of the patient, patient

number (generated patient number for identification purposes), CBCT procedure or type of scan provided, CBCT procedure provided, ICD-9 codes, radiologic findings, and a summary of radiologic interpretation. From the ICD-9 codes, free-textual responses associated with the radiologic findings and summary of radiologic interpretation, the presence or absence of dystrophic calcification was determined, in addition to the tissue involved and associated descriptive information. Patient waivers were not necessary, as all personal information was stripped from the data set collected for analysis. No medical or dental histories were known for these patients.

Data Collection

A retrospective review of the available patient reports within the CBCT database (approximately 2,000) was commenced over a month period between January 1st through January 31st 2008 by ABW. During this period a total of 556 patient scans within the CBCT radiologic database of patients were accessed. This comprised mostly of scans of the previous calendar year 2007; however a few were retrieved from the previous year's (2006) archived CBCT.

Each scan was viewed initially with a slice thickness (ST) of 40mm using axial, coronal, and sagittal orthogonal views. If more detail was needed once the calcification was identified, thinner slice thicknesses could be attained. Frequently, ST of 10mm were used to characterize and measure the various calcifications found. There was no exclusion based on age or sex.

The following exclusion criteria were applied:

1. Scans of the maxilla only were excluded from consideration.

2. Any scan not including at least the 4th cervical vertebrae inferiorly was excluded.
3. Any scan of poor diagnostic quality.

If the scan was in the database and was not ruled out by exclusion criteria, it was included in the study. ABW reviewed the scans after training from two board certified oral and maxillofacial radiologists, Drs. William Scarfe and Allan G. Farman.

For each scan included in the study, the patient was given a code. This code was logged on a database and would be used throughout the study as a unique identifier.

The following information was recorded for each patient:

1. patient age at the time of scan (2-digit year)
2. sex (male or female)
3. scan type (mandible only, maxilla and mandible, and full scan; no maxilla only scans were included).

The database also included information concerning:

1. presence or absence of calcifications
2. type (or what soft tissue structure) of calcification present
3. sidedness (i.e. unilateral or bilateral and what side)
4. single or multiple occurring

Any soft tissue calcifications were noted and described according to the following categories:

1. Carotid artery,
2. Triticeous cartilage,
3. Thyroid cartilage,

4. Tonsilloliths,
5. Lymph nodes, and
6. Other. Any calcifications not fitting into the defined categories listed above were placed into this category. Specific details of each “other” calcification were recorded.

Data Coding

For all patients, relevant information was entered and maintained using a Microsoft Excel spreadsheet (Microsoft Office Excel, 2007, Redmond WA, USA). This data was coded and categorically entered as follows:

1. Patient Number: For each patient, a 2-digit numerical value was entered. This allowed for ease of identification. In addition, it provided an accurate total sample patient count.
2. Sex: This categorical information was coded as numerical data: Male (1) and Female (2). This was the preferred coding in order to facilitate statistics.
3. Age: The age of the patient was entered as a 2-digit numerical value. For example, “01” would describe a patient who is 1 year of age.
4. Scan Type: The type of scan performed describing the field of view (FOV) was categorized as either:
 - a. Full scan (13.2 cm height)
 - b. Maxilla/Mandible scan (8 cm height)
 - c. Mandible only scan (6 cm height)
5. Calcification Presence/Absence: If the patient presented with a dystrophic

calcification, it was noted with a “Y” or “N”.

6. Type of Calcification: This denoted the structure or tissue affected.

These included:

- a. Carotid Artery Calcifications (CAC)
- b. Triticeous Cartilage Calcifications (TC)
- c. Tonsiloliths (T)
- d. Calcifications of the Superior Cornu of the Thyroid (SCT)
- e. Lymph Node Calcifications (LN)
- f. Other (O)—examples included intracranial calcifications, skin surface calcifications, phleboliths, etc.

7. Sidedness: Unilateral (Uni), Bilateral (Bi), Right (R), and Left (L) were used.

Image characteristics for each type of calcification were recorded. This information was not coded, but was included in the results section to further characterize the presentation of these calcifications. Each orthogonal view was viewed to supplement the original descriptions of the imaging presentation. If multiple calcifications were found, it was noted how many were present and what structures were affected.

Carotid artery calcifications were described in more detail by a specific code. In addition to listing the side(s) affected, the location of the CAC was described. The description included the vertical level at which the calcification was present in relation to cervical vertebrae. The first letter was always c which stands for cervical. A number will follow which designates at what vertebral level the calcification is located. The final letter further specifies the vertical level within that vertebrae that the calcification is present (a= upper 1/3 of the particular vertebrae; b= middle 1/3; c= lower 1/3).

Therefore a c3a indicates that a carotid artery calcification is present at the level of the 3rd cervical vertebrae in the upper 1/3 of the vertebrae. If the CAC were large and extended over a number of vertebrae then there location was described as such. For example c3a-4b denotes a CAC extending vertically from the upper 1/3 of the 3rd cervical vertebrae to the middle 1/3 of the 4th cervical vertebrae.

In addition the following dimensions of the CAC were measured to the nearest 1/10th of a millimeter in each of the three orthogonal planes - axial, coronal, and sagittal.

1. Height = superior-inferiorly (S-I)
2. Width = lateral-medially (L-M)
3. Length = anterior-posteriorly (A-P)

Data Analysis

The data collected was analyzed and descriptive statistics used to provide information about head and neck soft tissue calcifications according to the following strategy.

1. Comparison of Demographics of Patients whose Datasets were Included to those that were Excluded:
 - a. Mean age, sex and scan type of the included datasets were compared to datasets that failed to satisfy the inclusion criteria to ensure validity of our exclusion/inclusion criteria. A significant difference in any of these variables would signal a potential bias in the sampling of our study. Different statistical analyses were used to compare present and control groups. Two-tail un-paired *t* test with unequal variances

were used to determine differences in age. The Chi-square test with Yates correction was used to indicate sex and scan type differences. Significance level was set at $p \leq 0.05$.

2. Sample Demographics for patients whose datasets satisfied all inclusional criteria:
 - a. Mean age, age range (Max, Min), median age, mode age, standard deviation, and frequency of patients within predetermined age groups (0-9, 10-19, 20-29, 30-39, 40-49, 50-59, 60-69, 70-79, 80-89) were determined.
 - b. Male and female distribution was noted as a percentage.
 - c. Frequency distribution was provided to note the differences in percentage of patients according to scan type. Percentages of patients in each scan type category and the percentages of males/females within each scan type were noted.
3. Comparative Demographics of Affected vs. Control Patient Group
 - a. Two tail un-paired t test with unequal variances were used to determine differences in age of the calcification patients vs. controls. The Chi-square test with Yates correction was used to indicate sex and scan type differences. Significance level was set at $p \leq 0.05$.
4. Comparative Incidence of Calcifications
 - a. A frequency distribution examined the incidence of each type of calcification. Percentages were calculated describing the frequency of the overall sample and those who presented with calcifications.

5. Demographics of the specific types of calcifications
 - a. Two tail un-paired t test with unequal variances were used to determine differences in age of the calcification patients of the specific type vs. controls. The Chi-square test with Yates correction was used to indicate sex and scan type differences. Significance level was set at $p \leq 0.05$.
 - b. Mean age, age range (Max, Min), median age, mode age and standard deviation were determined for each calcification type.
 - c. For carotid artery calcifications, statistics were used to further describe the class. Mean size, size range (Max, Min) and standard deviation were calculated for right and left unilateral and bilateral CAC. Width, length and height were measured. Significance (T-test values and p-values) was noted. Totals were calculated for location of CAC with respect to cervical vertebrae and side as well.

CHAPTER IV

RESULTS

The descriptive statistics of this study are divided into two approaches:

- a. ***Total CBCT Patient Database.*** The demographics of the total patient CBCT database and comparison of the age, sex and scan type of the included individuals whose dataset was included to those whose dataset was excluded (controls). This was performed to confirm the judicious application of the inclusion and exclusion criteria without selection bias based on age, sex or scan type.
- b. ***CBCT Sample.*** The incidence of specific calcifications with respect to age, sex and scan type was compared to others in the sample who did not present with calcifications. These individuals acted as controls.

Patient and Sample Demographics

A total of 556 scans within the CBCT database of patients were accessed over the period January 1st 2008 through January 31st 2008. This comprised mostly of scans of the previous calendar year 2007; however a few had been retrieved from previously archived CBCT scans in 2006. Of the total available scans in the database, the sample was reduced by 248 (44.6%) by application of the following exclusion criteria:

- a. 198 (35.6 %) were excluded because the scan area incorporated the maxillary region only.
- b. 50 (8.8 %) were excluded because the lower level of the region of interest of the scan did not include at least the most superior portion of the 4th cervical vertebrae. Of these 6 were full scans (13.2 cm), 5 were scans of the maxilla and mandible (8 cm) and 41 were mandibular scans (6 cm).

Therefore a total of 308 (55.4%) of the available CBCT database patient scans satisfied the inclusion criteria.

Excluded Patients Compared to Sample Patients

The demographics of those individuals in the database **excluded** from the sample as compared with those included in the sample are shown in Tables 1-3.

Table 1 shows the comparative age demographics of those excluded from the sample compared to those who satisfied the inclusion criteria. Two tail un-paired *t* test with unequal variances failed to demonstrate a significant difference in mean age between excluded and included patients (*t* value = 0.7, *p*=0.49).

Table 1: Demographics of Patients in the Sample compared to those whose CBCTs were excluded according to Age.

<i>Age Parameter</i>	<i>Patient Sample</i>	
	<i>Excluded (n = 248)</i>	<i>Included Patients (n=308)</i>
Mean (\pm s.d.)*	50.58 \pm 19.21	51.69 \pm 18.03
Median	56	55
Mode	62	52
Minimum	5	7
Maximum	89	86

*Unpaired t test assuming unequal variances (t value = 0.7, p=0.49)

Table 2 shows the comparative sex demographics of those excluded from the population compared to the sample. Chi-square (Yates correction for continuity) ($X^2=3.24$; $p=0.072$) indicated no differences between sex for those excluded from the sample and those included.

Table 2: Frequency Distribution (%) of Patients in the Sample compared to those whose CBCTs were excluded according to Sex.

<i>Sex</i>	<i>CBCT Patient Population</i>		
	<i>Excluded</i>	<i>Included (Sample)</i>	<i>Total</i>
Male	127 (51%)	133 (43%)	260 (47%)
Female	121 (49 %)	175 (57%)	296 (53%)
Total	248 (100 %)	308 (100%)	556 (100%)

Table 3 shows the distribution of type of scan performed on those who were excluded from the sample and those included. Excluding the maxillary scans, which were

by their very nature unable to be included, Chi-square ($X^2=23.8$; $p\leq 0.001$) indicated significant differences in the distribution of scan type between the groups, with a greater proportion of maxillary scans in the excluded population.

Table 3: Frequency Distribution (%) of Patients in the Sample compared to those who were excluded according to Scan Type.

<i>Scan Type</i>	<i>Group</i>		<i>Total</i>
	<i>Excluded</i>	<i>Included (Sample)</i>	
Full	6 (2%)	117 (38%)	123 (22%)
Mx / Mn	5 (2%)	60 (19%)	65 (12%)
Mandible	41 (17%)	131 (43%)	172 (31%)
Maxilla	196 (79%)	0 (0%)	196 (35%)
Total	248 (100%)	308 (100%)	556 (100%)

Patient Sample

The mean age of patients in the sample was 51.7 ± 18.03 years. The median age was 55 years, and the mode was 52. The age range was from 7 to 86 years old. Of the 308 referrals, 175 (56.8%) were women and 133 (43.2%) were men.

Figure 9 shows the frequency distribution of patients according to age (decade). This graph shows a unimodal distribution, with a preponderance of patients (26.6%) in the 51-60 year age group. The next most frequently occurring age group was the 60-70 age group (22.1%) followed by the 40-50 age group (15.6%).

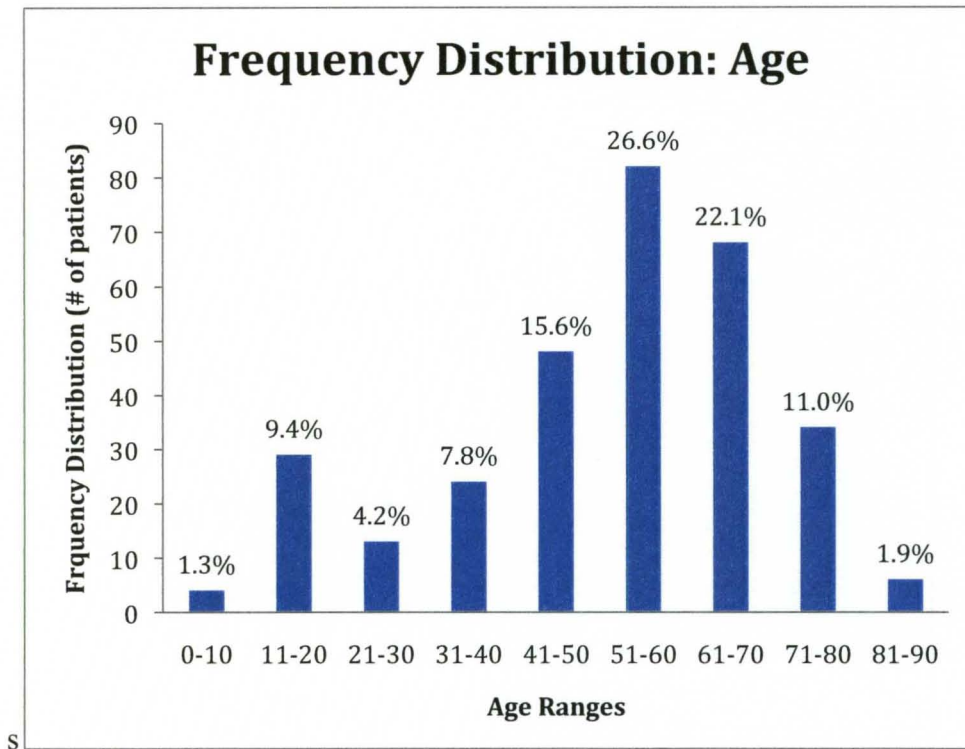


Figure 9. Frequency distribution: Patients by Age (Decade). The numbers at the top of the graph bars indicate percentage of patients in the sample.

Table 4 shows the frequency distribution of patients according to scan type and sex.

Table 4: Frequency Distribution (%) of Patients according to Scan Type and Sex

<i>Gender</i>	<i>Scan Type</i>			<i>Total</i>
	<i>Full (13.2 cm)</i>	<i>Mx / Mn (8 cm)</i>	<i>Mn (6 cm)</i>	
Male	57 (49%)	23 (38%)	53 (40%)	133 (43%)
Female	60 (51%)	37 (62%)	78 (60%)	175 (57%)
Total	117 (100%)	60 (100%)	131 (100%)	308 (100%)

Comparative Demographics of Patients Demonstrating Calcifications

Of the 308 patients in the sample, 107 (34.75%) demonstrated at least one form of calcification. Table 5 shows the comparative age demographics of those who demonstrated calcifications compared to controls. Two tail un-paired *t* test with unequal variances demonstrated a significant difference in mean age between those with calcifications compared to controls (t value = 6.32, p<0.001). Those with calcifications were, on average, approximately 12 years older than those who did not.

Table 5: Demographics of Patients in the Sample who presented with Calcifications compared to controls According to Age.

<i>Age</i>	<i>Group</i>	
	<i>Calcifications</i>	<i>Control</i>
Mean (\pm s.d.)*	59.5 \pm 13.9	47.5 \pm 18.6
Median	60	51
Mode	59	49
Minimum	10	7
Maximum	86	84

*Unpaired t test assuming unequal variances (t value = 6.32, p<0.001)

Table 6 shows the comparative sex demographics of those who demonstrated calcifications compared to controls. Chi-square analysis (Yates correction for continuity) ($X^2=0.03$; p=0.83) indicated no differences between sex for those who demonstrated calcifications and controls.

Table 6: Frequency Distribution (%) of Patients according to Presence of Calcification and Sex

<i>Sex</i>	<i>Group</i>		<i>Total</i>
	<i>Calcifications</i>	<i>Control</i>	
Male	45 (42 %)	88 (44%)	133 (43 %)
Female	62 (58 %)	113 (56%)	175 (57 %)
Total	107 (100 %)	201 (100%)	308 (100%)

Table 7 shows the type of scan performed on those who demonstrated calcifications compared to controls. Chi-square analysis ($X^2=1.61$; $p=0.45$) indicated no differences between scan type for those who demonstrated calcifications and controls.

Table 7: Frequency Distribution (%) of Patients according to Presence of Calcification and Scan

<i>Scan Type</i>	<i>Group</i>		<i>Total</i>
	<i>Calcifications</i>	<i>Control</i>	
Full	38 (36 %)	79 (39 %)	117 (38 %)
Mx / Mn	25 (23 %)	35 (17 %)	60 (19%)
Mandible	44 (41%)	87 (43 %)	131 (43 %)
Total	107 (100 %)	201 (100 %)	308 (100%)

Comparative Incidence of Calcifications

The relative incidence of type of calcification present in the sample is shown in Table 8. Carotid artery calcifications, calcifications of the triticeous cartilage and

calcifications of the tonsils (tonsilloliths) comprised approximately 90% of all calcifications, each with an almost equal distribution (Fig. 10).

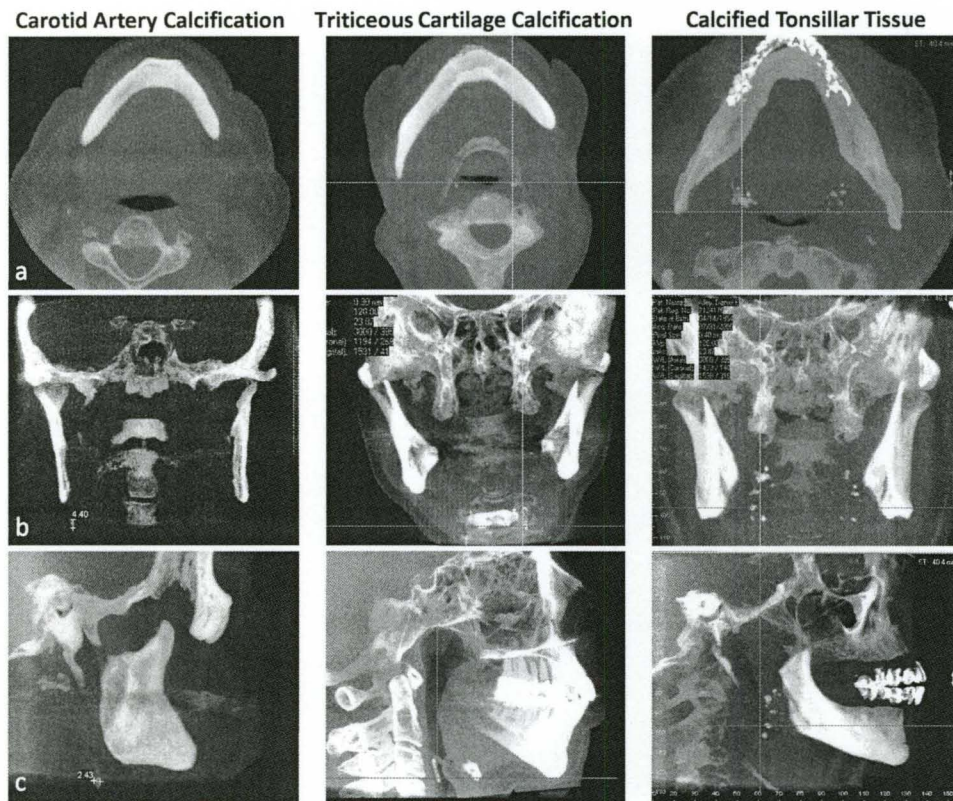


Figure 10. Representative axial (a), coronal (b) and sagittal (c) medium slice (10-20mm) maximum intensity orthogonal projection images of the three most common soft tissue calcifications found on CBCT scans within the patient sample.

Table 8: Frequency Distribution (%) of Patients in the Sample according to Presence of Calcification.

<i>Type of Calcification</i>	<i>Sample</i>		<i>Percentage</i>	
	<i>N</i>	<i>Of Total Sample (n=308)</i>	<i>Of Patients with Calcifications (n=107)^</i>	
Carotid Artery Calcifications	32	10.4%	29.9%	
Triticeous Cartilage	35	11.4%	32.3%	
Tonsillolith	32	10.4%	29.9%	
Superior Cornu of Thyroid	16	5.2%	15%	
Lymph Node	5	1.6%	4.8%	
Other*	12	3.9%	11.2%	

^ Percentage is greater than 100% because a number of patients demonstrated multiple calcifications

* This includes intra-cranial calcifications, skin surface calcifications scars, etc.

A number of patients demonstrated multiple calcifications. The relative incidence of multiple calcifications present in the sample is shown in Table 9.

Table 9: Frequency Distribution of Patients presenting with Multiple Calcifications

<i>Secondary Calcification</i>	<i>Primary Calcification</i>					
	<i>Carotid Artery Calcifications</i>	<i>Triticeous Cartilage</i>	<i>Tonsilloliths</i>	<i>Superior Cornu of Thyroid</i>	<i>Lymph Node</i>	<i>Other</i>
Carotid Artery Calcifications		1 Bilateral	2 bilateral	1 bilateral	---	1 bilateral
Triticeous Cartilage	1 Uni (Rt)		5 (4 Bi, 1 Uni [Lt])	10 (5 Bi, 5 Uni [4 Rt, 1 Lt])	---	1 Bi
Tonsilloliths	2 Bi	5 (3 Bi, 2 Uni [1 Rt, 1 Lt])		2 Bi	1 Uni (Rt)	3 (1 Bi, 2 Uni [1 Rt, 1 Lt])
Superior Cornu of Thyroid	---	10 (7 Bi, 3 Uni [Rt])			1 Bi	
Lymph Node	---	---	1	1		
Other*	Calcified skin / midline brain Calcification (1)	Calcified skin (1)	Calcified skin (2), C3 osteophyte (1)	---	---	
Total	4	17*	13^	14†	2	5‡

*, † Two patients had more than one additional calcification; ^ Three patients had more than one additional calcification; ‡ One patient had more than one additional calcification.

Lt = left; Rt = right; Bi = bilateral; Uni = unilateral.

Calcification Presentation and Distribution

Carotid Artery Calcifications (CAC)

Presentation

The location and presentation of CAC on medium thickness (10-20mm) MIP orthogonal slices generated according to the protocol was remarkably consistent. The salient imaging features are dependent on orthogonal projection and are summarized as follows:

- a. ***Axial section.*** On this projection, most CAC presented as single or multiple “rice grains”, linear, or curvilinear homogeneous opacifications (Fig. 11a-c). As the size of the calcifications increased the number of ipsilateral opacifications often increased tending to form larger coalescing masses (Fig 11d). Curvilinear calcifications presented as a crescent shape or extended into a “C” with a few almost completely encompassing the vessel forming a circle or appeared to occlude the soft tissue region (Fig. 12). All CAC were located in the soft tissue approximately 0-10mm antero-laterally to the anterior tubercle of the transverse process, lateral or more often latero-posterior to the greater cornu of the hyoid bone (Fig. 13). They were always postero-lateral to the pharyngeal airway space. On some occasions, depending on the window and level settings of the scan, it was possible to delineate the soft tissue vessel within which the calcification occurred within the carotid space (Fig. 14).

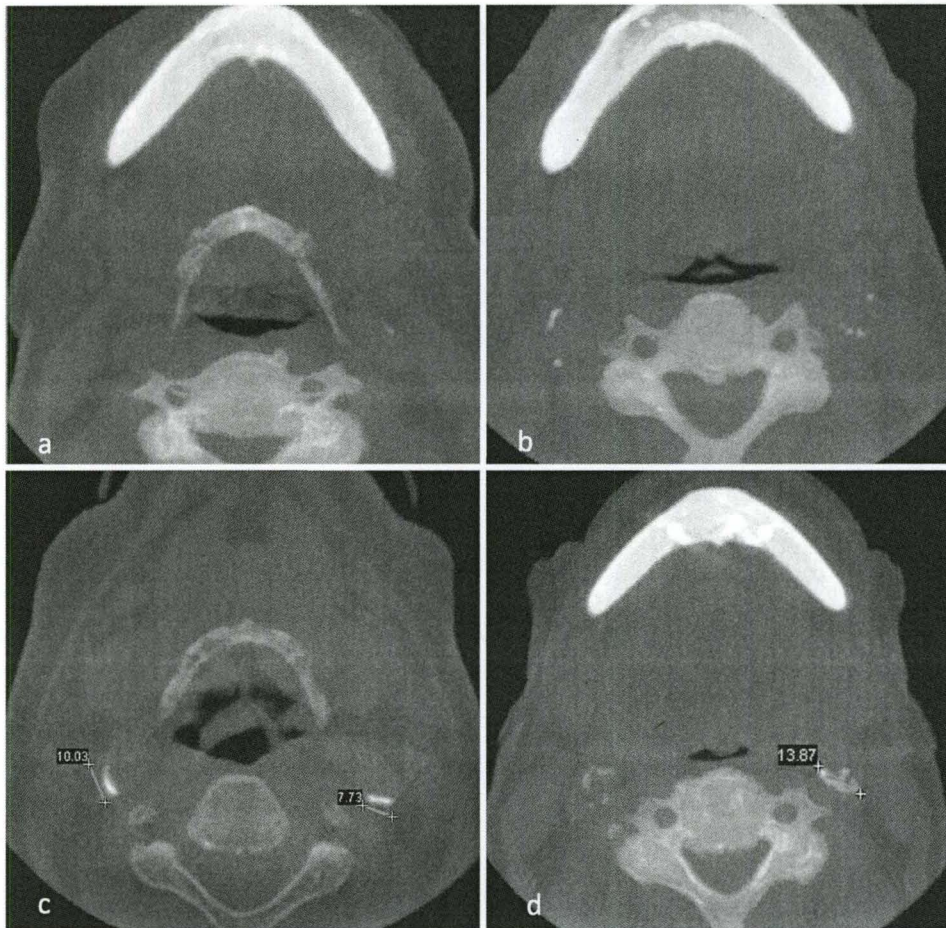

Figure 11. Axial projections demonstrating the varying presentations of CAC as single rice grain (a), multiple “rice grains” (b – right), linear (b – left; c – right), or curvilinear (c – left; d – left) homogeneous opacifications. Often as the size of the CAC increased the number of ipsilateral opacifications also increased (d – left) tending to form larger coalescing masses (d – right)

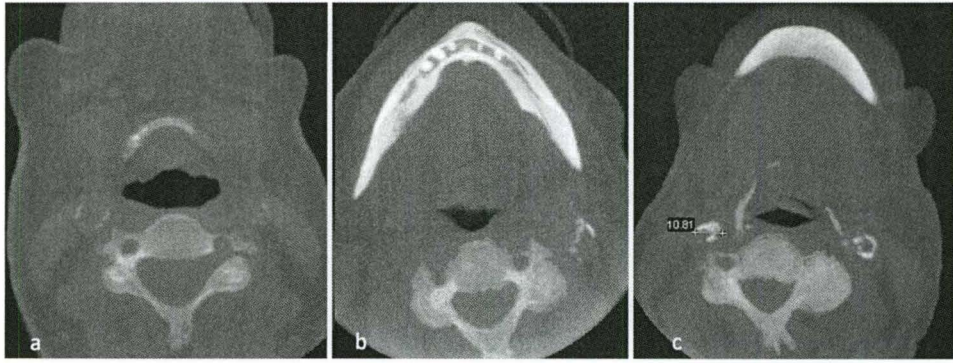


Figure 12. Axial medium slice (10-20mm) maximum intensity orthogonal projection demonstrating presentation of curvilinear CAC as a crescent shape (a), extended into a “C” (b) or almost completely forming a circle (c).

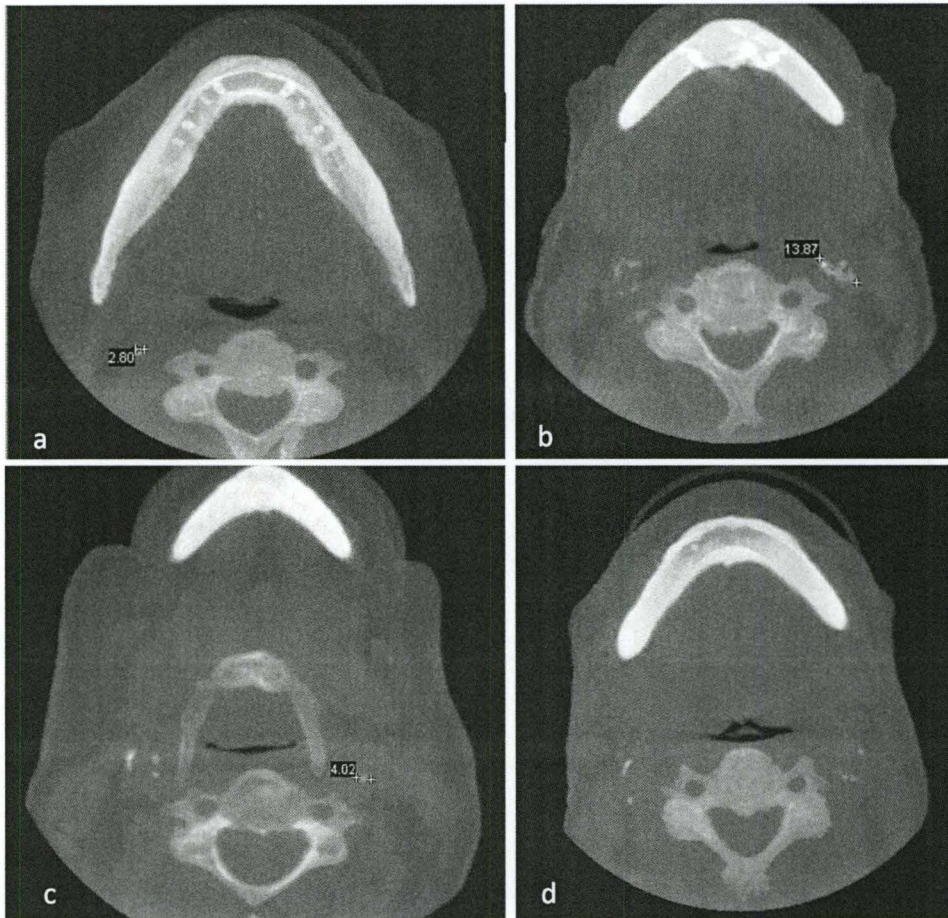

Figure 13. Axial medium slice (10-20mm) maximum intensity orthogonal projection demonstrating location of CAC antero-lateral to the anterior tubercle of the cervical vertebra, postero-lateral to the oro-pharyngeal airway and lateral or latero-posterior to the greater cornu of the hyoid.

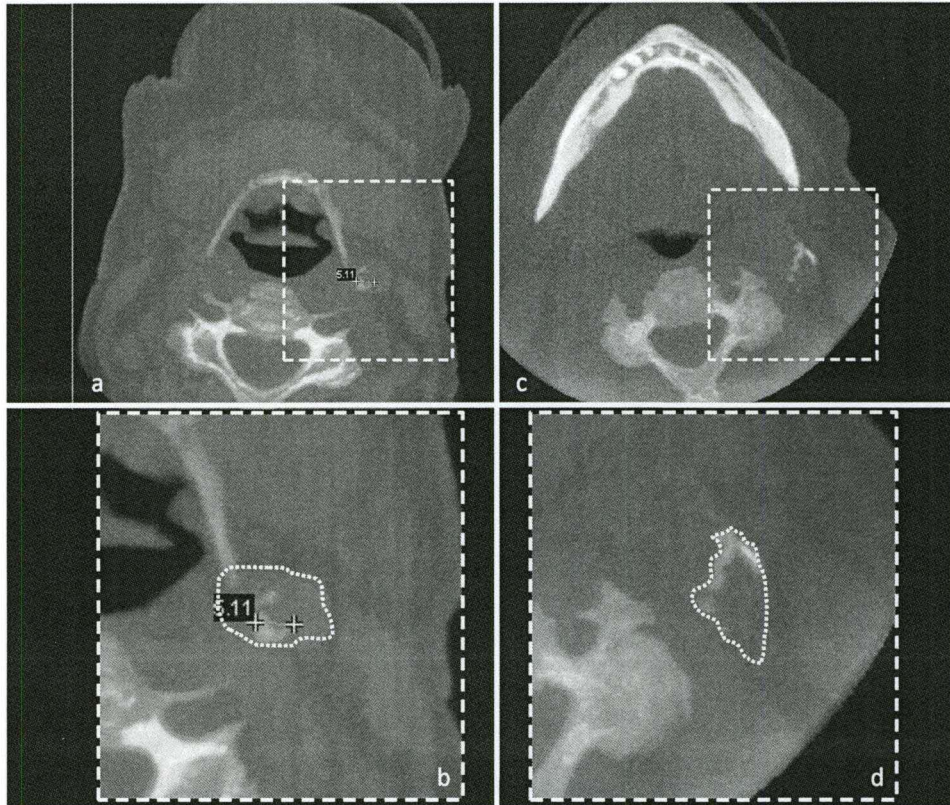


Figure 14. Two (a/b) axial medium slice (10-20mm) maximum intensity orthogonal projection demonstrating correlation of CAC boundary with soft tissue outline.

- b. **Coronal section.** All CAC were lateral to the anterior tubercle of the cervical vertebrae. From this projection, CAC presented as linear, linear globular, or globular calcifications (Fig. 15).

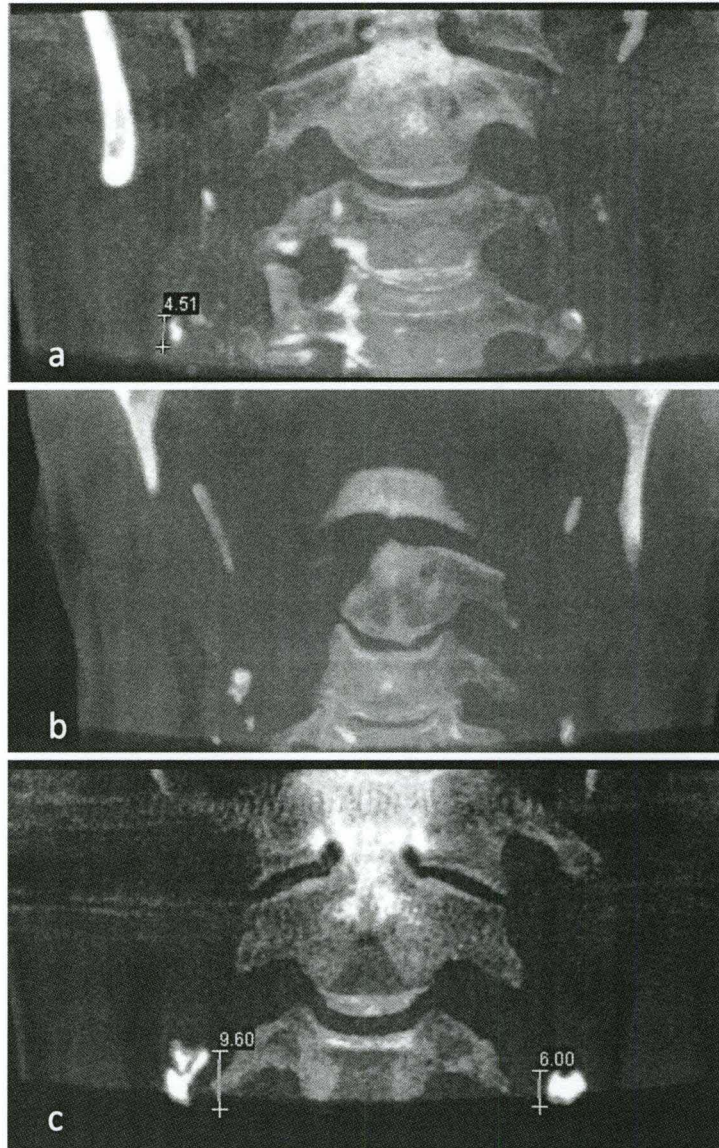


Figure 15. Coronal medium slice (10-20mm) maximum intensity orthogonal projections demonstrating location of CAC lateral to the cervical vertebrae and variation in presentation from linear (a), linear globular (b), or globular calcifications (c)

- c. *Sagittal section.* All CAC were posterior and inferior to the angle of the mandible, lateral and mostly anterior to the cervical tubercle with vertical position varying from C3 to C5. While most were either at or below the level

of the superior cornu of the hyoid bone, some were above this structure (Fig. 16). Presentation ranged from a linear to linear oblique to globular homogeneous opacifications (Fig. 17). Sometimes multiple discontinuous globular opacifications were evident (Fig. 18).

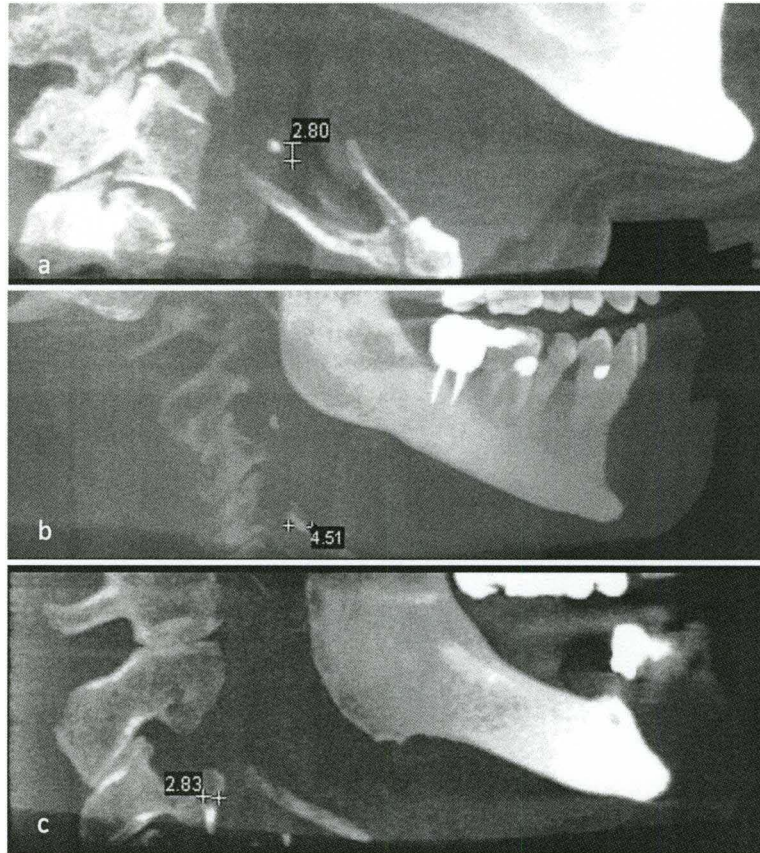


Figure 16. Sagittal medium slice (10-20mm) maximum intensity orthogonal projections demonstrating location of CAC in relation to the hyoid bone as either above (a) above (b) at the level of (b) or below (c) the hyoid bone.

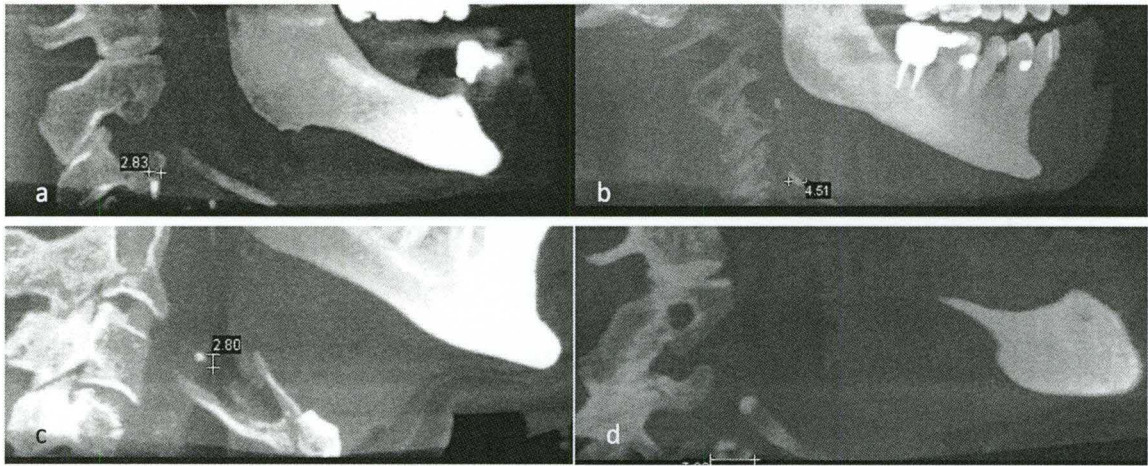


Figure 17. Sagittal medium slice (10-20mm) maximum intensity orthogonal projections demonstrating appearance of CAC as linear (a), oblique linear (b), globular (c) or coalescing globules (d).

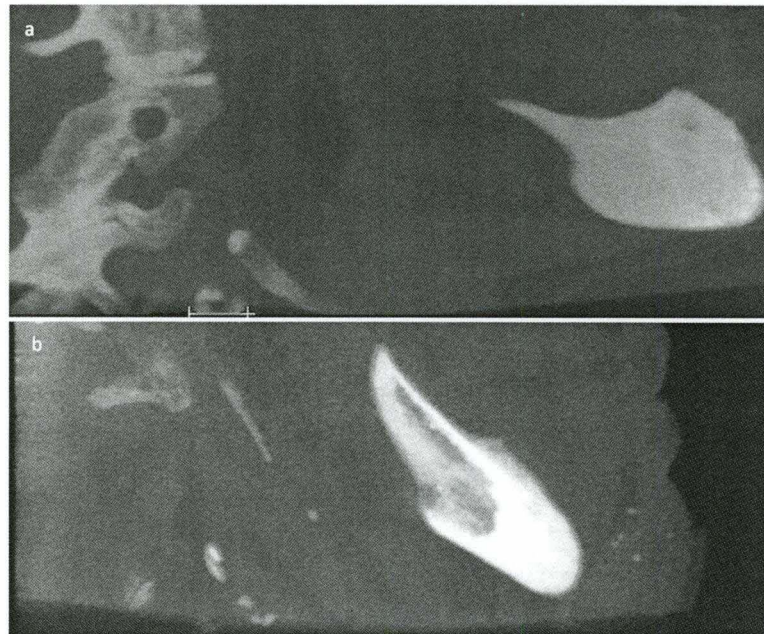


Figure 18. Sagittal medium slice (10-20mm) maximum intensity orthogonal projections demonstrating multiple discontinuous globular calcification appearance of CAC.

Demographics

Comparison of age of patients presenting with CAC with those not presenting in the sample is shown in Table 10. The mean age of presenting was 68.2 ± 8.9 years. The median age was 67 years, and the mode was 67. The age range was from 45 to 86 years old. Two tailed un-paired t test with unequal variances demonstrates a significant difference ($t = 5.76, P < 0.0001$) in mean age between those with CAC compared to controls.

Table 10: Demographics of Patients Demonstrating CAC compared to Controls

According to Age

<i>Age Parameter</i>	<i>Group</i>	
	<i>CAC</i>	<i>Control</i>
Mean (\pm s.d.)*	68.2 \pm 8.9	49.8 \pm 17.84
Median	67	52
Mode	67	52
Minimum	45	7
Maximum	86	84

*Unpaired t test assuming unequal variances
(t value = 5.76, $p < 0.0001$)

The sex distribution of patients with carotid artery calcification is shown in Table 11. While males more commonly presented with CAC than females, Chi-square analysis ($X^2=3.82; p=0.15$) indicated no sex differences between those who demonstrated CAC and controls.

Table 11: Frequency Distribution (%) of Patients Demonstrating CAC compared to Controls According to Sex

<i>Sex</i>	<i>Group</i>		<i>Total</i>
	<i>Calcifications</i>	<i>Control</i>	
Male	19 (59 %)	114 (41 %)	133 (43 %)
Female	13 (41%)	162 (59 %)	175 (57%)
Total	32 (100 %)	276 (100 %)	308 (100%)

Table 12 shows the type of scan performed on those who demonstrated CAC compared to controls. Chi-square analysis ($\chi^2=1.18$; $p=0.55$) indicated no differences between scan type for those who demonstrated calcifications and controls.

Table 12: Frequency Distribution (%) of Patients Demonstrating CAC compared to Controls According to Scan Type.

<i>Scan Type</i>	<i>Group</i>		<i>Total</i>
	<i>CAC</i>	<i>Control</i>	
Full	13 (41 %)	104 (38 %)	117 (38 %)
Mx / Mn	8 (25 %)	52 (18 %)	60 (19 %)
Mandible	11 (34 %)	120 (43 %)	131 (43 %)
Total	32 (100%)	276 (100 %)	308 (100%)

Tables 13-15 describe the presentation of CAC with respect to location and size. Table 13 shows that of the 47 CAC in 32 patients, most ($n=30$, 63.8%) were bilateral and occurred most frequently at the level of C4 ($n=22$, 46.8%) followed by C3 ($n=17$, 36.2%).

Of the 32 patients with CAC, four had additional calcifications: a unilateral

triticous calcification (1), a bilateral calcified superior cornu of the thyroid cartilage (1), a bilateral tonsillolith (1) and one had both bilateral tonsilloliths and a midline brain calcification (1).

Table 13. Summary of Location of CAC with respect to Level of Cervical Vertebrae and Side

<i>Cervical vertebrae level</i>	<i>Unilateral</i>			<i>Bilateral</i>			<i>Overall</i>
	<i>Left</i>	<i>Right</i>	<i>Subtotal</i>	<i>Left</i>	<i>Right</i>	<i>Sub Total</i>	
C3	3	7	10	4	3	7	17
C3-C4	---	---	---	2	3	5	5
C4	3	1	4	9	9	18	22
C4-C5	1	1	2	---	---		2
C5	---	1	1	---	---		1
Total	7	10	17	15	15	30	47

Table 14 shows the mean dimensions of CAC according to location side. There were no left or right-sided differences therefore we assumed that the dimensions could be pooled to compare the overall dimensions.

Table 14. Comparative Dimensions of CAC according to Side Location

<i>Location</i>	<i>Parameter</i>	<i>Dimension (mm)</i>						<i>Significance</i>	
		<i>Right</i>			<i>Left</i>			<i>T</i>	<i>p</i>
		<i>Mean (s.d.)</i>	<i>Min</i>	<i>Max</i>	<i>Mean (s.d.)</i>	<i>Min</i>	<i>Max</i>		
Unilateral	Width	4.08 ± 2.6	2.1	10.8	3.0 ± 1.3	2	5.1	1.01	0.33
	Length	4.06 ± 1.9	2.1	8.5	3.1 ± 2.1	2	7.8	0.96	0.35
	Height	4.91 ± 2.6	2.8	10.2	2.76 ± 1.1	2	4.8	2.08	0.06
Bilateral	Width	6.5 ± 3.4	1	10.8	5.3 ± 3.6	2	13.9	1.09	0.29
	Length	5.1 ± 2.6	1	10.1	5.3 ± 3.6	2	13.9	.22	0.83
	Height	7.67 ± 4.9	1	17.6	7.1 ± 5.1	2	18.1	.54	0.59

Table 15 shows the pooled mean dimensions of CAC according to location.

Bilateral CAC were statistically larger in width and height as compared to unilateral CAC.

Table 15. Comparative Dimensions of CAC according to Uni- or Bilateral Distribution

<i>Parameter</i>	<i>CAC Dimension (mm)</i>		<i>Significance</i>	
	<i>Unilateral (n=17)</i>	<i>Bilateral (n=30)</i>	<i>t</i>	<i>p</i>
Width	3.63 ± 2.2	5.9 ± 3.48	2.43	0.019
Length	3.67 1.98	5.23 3.07	1.88	0.067
Height	4.02 2.31	7.37 4.9	2.64	0.012

Calcification of the Triticeous Cartilage (TC)

Presentation

The location and presentation of TC on medium thickness (10-20mm) MIP

orthogonal slices generated according to the protocol was also consistent. On imaging, TC always appeared as a single “rice grain” like ovoid homogeneous dense opacification. The localization of the opacification on orthogonal projections coinciding with the anatomic location of this feature differentiated this calcification from the CAC or calcified tonsillar tissue and can be summarized as follows:

- a. **Axial section.** On this view, single discrete calcifications were always located medio-posterior to the most distal extent of the greater cornu of the hyoid bone and in the vicinity of the superficial soft tissue in the lateral pre-vertebral space immediately adjacent but posterior to the maximum width of the oropharyngeal airspace (Fig. 19).

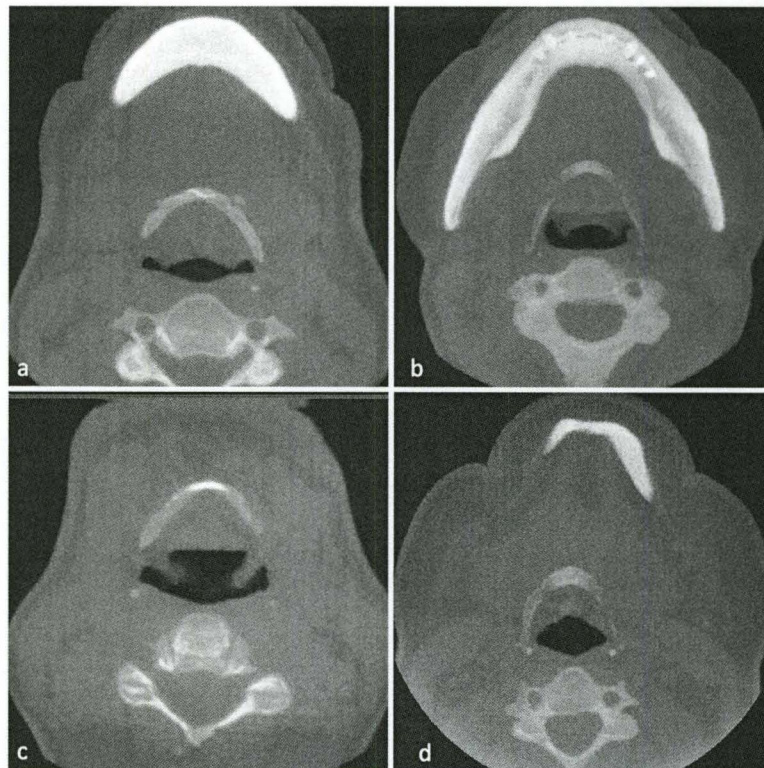

Figure 19. Axial medium slice (10-20mm) maximum intensity orthogonal projections demonstrating the consistent location and appearance of the TC (a – d).

- b. **Coronal.** The characteristic location of the TC was immediately inferior to the greater cornu of the hyoid bone (Fig. 20).

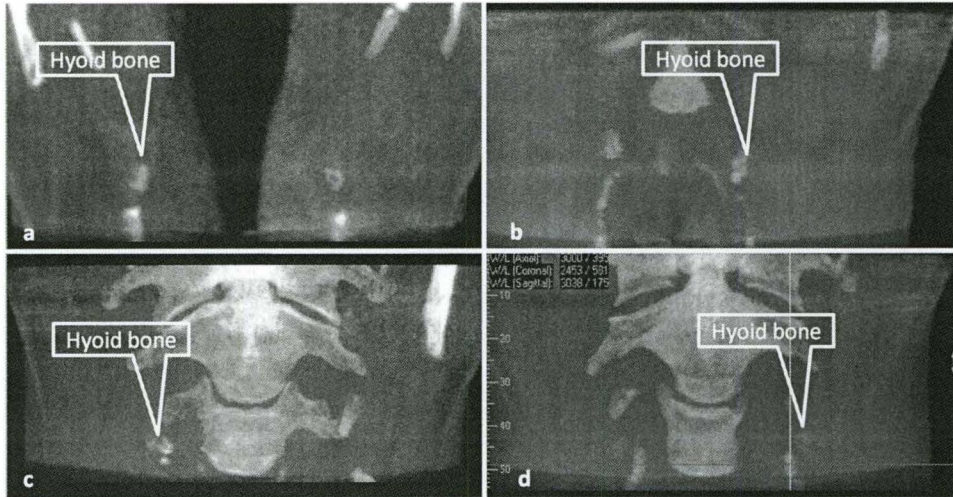


Figure 20. Coronal medium slice (10-20mm) maximum intensity orthogonal projections demonstrating the consistent location and appearance of the TC immediately inferior to the maximal extension of the greater cornu of the hyoid bone (a – d).

- c. **Sagittal.** The characteristic location of the TC was immediately inferior and slightly anterior to the greater cornu of the hyoid bone (Fig. 21).

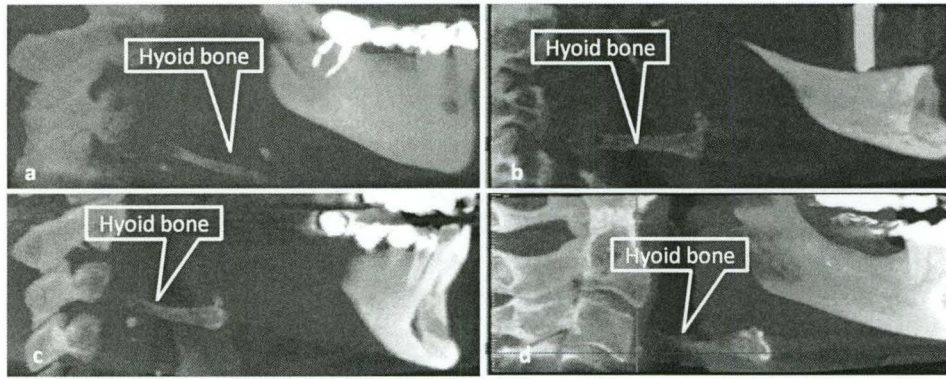


Figure 21. Sagittal medium slice (10-20mm) maximum intensity orthogonal projections demonstrating the location and appearance of the TC immediately inferior to the maximal extension of the greater cornu of the hyoid bone (a – d).

Demographics

Comparison of age of patients presenting with calcification of the triticeous cartilage (TC) with internal controls within the sample is shown in Table 16. The mean age of patients presenting with TC was 56.23 ± 10.62 years. The median age was 58 years, and the mode was 59. The age range was from 37 to 84 years old. Two tailed unpaired t test with unequal variances does not demonstrate significant difference (t value = 1.58, $p = 0.114$) in mean age between those with TC compared to controls.

Table 16: Demographics of Patients Demonstrating TC compared to Controls According to Age

<i>Age Parameter</i>	<i>Group</i>	
	<i>TC</i>	<i>Control</i>
Mean (\pm s.d.)*	56.23 \pm 10.62	51.11 \pm 18.71
Median	58	54
Mode	59	52
Minimum	37	7
Maximum	84	86

*Unpaired t test assuming unequal variances
(t value = 1.58, p= 0.114)

The sex distribution of patients with triticeous cartilage calcifications are shown in Table 17. Chi-square analysis (Yates correction for continuity) ($X^2=7.62$; p=0.006) indicates that TC is more likely to occur in females than males as compared controls.

Table 17: Comparative Frequency Distribution (%) of Patients Demonstrating TC and Controls According to Sex

<i>Sex</i>	<i>Group</i>		
	<i>TC</i>	<i>Control</i>	<i>Total</i>
Male	7 (20 %)	126(46 %)	133(43 %)
Female	28 (80 %)	147 (52 %)	175 (57 %)
Total	35 (100 %)	273 (100 %)	308 (100%)

Table 18 shows the type of scan performed on those who demonstrated calcifications compared to controls. Chi-square analysis ($X^2=0.59$; p=0.75) indicated no differences between scan type for those who demonstrated calcifications and controls.

Table 18: Frequency Distribution (%) of Patients Demonstrating TC Compared to Controls According to Scan Type

<i>Scan Type</i>	<i>Group</i>		<i>Total</i>
	<i>TC</i>	<i>Control</i>	
Full	12 (34 %)	105 (38 %)	117 (38 %)
Mx / Mn	6 (17 %)	54 (20 %)	60 (19 %)
Mandible	17 (49 %)	114 (42 %)	131(43 %)
Total	35 (100 %)	273 (100 %)	308 (100%)

Calcifications of the triticeous cartilage occurred most frequently bilaterally (n=23, 65.7%). Of the remaining unilateral calcifications most (n=9, 25.7%) occurred on the right while the remainder (n=3, 8.6%) appeared on the left.

Of the 35 patients with triticeous cartilage calcification, 15 (42.9%) had additional calcifications. Thirteen patients (37.2%) had one additional finding whereas 2 (5.7%) had two additional calcifications. The most common additional finding was calcification of the superior cornu of the thyroid (10 total; 7 bilateral, 3 unilateral [right]). Tonsilloliths were the second most common finding (5 total; 3 bilateral, 2 unilateral [1 left, 1 right]). One patient had a bilateral CAC, and one had calcified acne scars.

Calcification of the Tonsils (CT)

Presentation

The location and presentation of CT on medium thickness (10-20mm) MIP orthogonal slices generated according to the protocol was pathognomonic. On imaging, CT appeared as a single but more often multiple clustered “rice grain” like ovoid homogeneous dense opacifications. The localization of the opacification on orthogonal

projections coinciding with the anatomic location of this feature immediately superficial to the lateral oro-pharyngeal airway space differentiated this calcification from the CAC or calcified triticeous cartilage and can be summarized as follows:

- a. ***Axial section.*** On this projection multiple small opacifications were consistently located antero-lateral to the oro-pharyngeal airway space immediately medial to the angle or ramus of the mandible. The depth of the calcifications with respect to the surface of the airway space was variable (Fig. 22a).
- b. ***Coronal section.*** On this projection the clusters were often superimposed over the anterior tubercle of the cervical spine and spanned supero-inferiorly linearly in line with the pterygoid plates (Fig 22b).
- c. ***Sagittal section.*** On this projection the opacifications were usually located superimposed over the shadow of the oro-pharyngeal airway space or anterior to it (Fig. 22c).

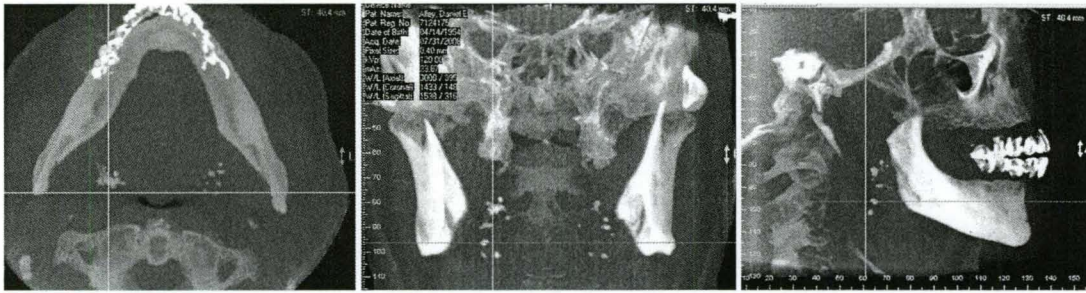


Figure 22. Orthogonal projections (10-20mm) of calcifications of tonsillar tissue. Axial slice demonstrating opacifications antero-lateral to oro-pharyngeal airway space and medial to angle or ramus of the mandible (a). Coronal slice demonstrates clusters of opacifications superimposed over the anterior tubercle of the cervical spine and spanning in line with the pterygoid plates (b). Sagittal view shows opacifications superimposed over the shadow of the airway space or slightly anterior to it (c).

Demographics

Comparison of the age of patients presenting with calcification of the tonsils (CT) or *tonsilloliths* with those not presenting this calcification in the sample is shown in Table 19. The mean age of patients presenting with CT was 57.68 ± 12.19 years. The median age was 57 years, and the mode was 58. The age range was from 26 to 83 years old. Two tailed un-paired t test with unequal variances demonstrates a significant difference (t value = 1.99, p= 0.047) in mean age between those with CT compared to controls.

Table 19: Demographics of Patients Demonstrating CT compared to Controls According to Age.

<i>Age Parameter</i>	<i>Group</i>	
	<i>CT</i>	<i>Control</i>
Mean (\pm s.d.)*	57.68 \pm 12.19	50.99 \pm 18.48
Median	57	54.5
Mode	58	52
Minimum	26	7
Maximum	83	86

*Unpaired t test assuming unequal variances
(t value = 1.99, p= 0.047)

The sex distribution of patients with CT are shown in Table 20. Chi-square analysis (Yates correction for continuity) ($X^2=0,07$; $p=0.79$) indicates no difference in the incidence of calcified tonsils as compared to controls.

Table 20: Frequency Distribution (%) of Patients Demonstrating CT compared to Controls According to Sex.

<i>Sex</i>	<i>Group</i>		
	<i>TC</i>	<i>Control</i>	<i>Total</i>
Male	15 (47 %)	118 (43 %)	133(43 %)
Female	17 (53 %)	158 (57 %)	175 (57 %)
Total	32 (100 %)	276 (100 %)	308 (100%)

Table 21 shows the type of scan performed on those who demonstrated calcifications compared to controls. Chi-square analysis ($X^2=4.14$; $p=0.13$) indicated no differences between scan type for those who demonstrated calcifications and controls.

Table 21: Frequency Distribution (%) of Patients Demonstrating CT compared to Controls According to Scan Type

<i>Scan Type</i>	<i>Group</i>		<i>Total</i>
	<i>CT</i>	<i>Control</i>	
Full	8 (25 %)	109 (39 %)	117 (38 %)
Mx / Mn	10 (31 %)	50 (18 %)	60 (19 %)
Mandible	14 (44 %)	117 (42 %)	131 (43 %)
Total	32 (100 %)	276 (100 %)	308 (100%)

CT occurred most frequently bilaterally (n=18, 56.3%). Of the remaining unilateral calcifications there was approximately equal distribution of left (n=6, 18.8%) and right (n=8, 24.9%).

Of the 32 patients with CT, 10 (31.25%) had additional calcifications. Seven patients (21.88%) had one additional finding, whereas 3 (9.37%) had two additional calcifications. The most common supplementary finding was TC (5 total; 4 bilateral, 1 unilateral [left]). The second most common calcification was other (3 total; 2 calcified acne scars and a single C3 osteophyte). Calcification of the cornu of the superior thyroid (2; 6.25%), CAC (2; 6.25%) were the next most common secondary findings. One patient had a calcified lymph node.

Calcification of the Superior Cornu of Thyroid Cartilage (SCT)

Presentation

On imaging, SCT most often appeared similar in appearance as the greater cornu of the hyoid; however, it can be distinguished from the hyoid as a discontinuous perpendicular extension progressing antero-inferiorly. The localization of the

opacification on orthogonal projections coinciding with the anatomic location of this feature immediately superficial to the lateral oro-pharyngeal airway space differentiated this calcification from the CAC or calcified triticeous cartilage and can be summarized as follows:

- a. **Axial section.** On this projection the SCT appeared as a single distinct circular opacification immediately posterior to the greater cornu of the hyoid bone. (Fig. 23) This projection can differentiate between SCT and the triticeous cartilage which always appears medial to the most posterior extent of the greater cornu of the hyoid (Fig. 23b).

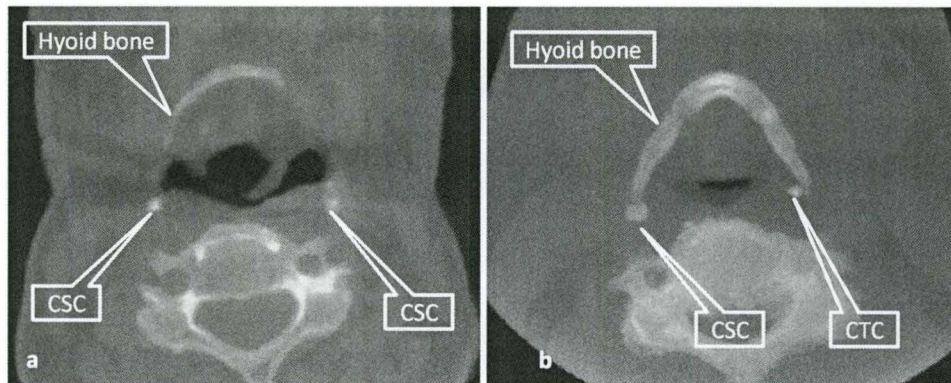


Figure 23. Cropped axial medium slice (10-20mm) maximum intensity orthogonal projections demonstrating the location and appearance of the SCT on axial images. Triticeous cartilage can be differentiated from the SCT on this image as being medial to the greater cornu (b)

- b. **Coronal section.** On this projection the SCT appeared as a linear cylindrical opacification extending inferior from the greater cornu of the hyoid (Fig. 24). These structures were separated; however, occasionally a “rice-grain” size

opacification was interposed between them (calcified triticeous) (Fig 24b).

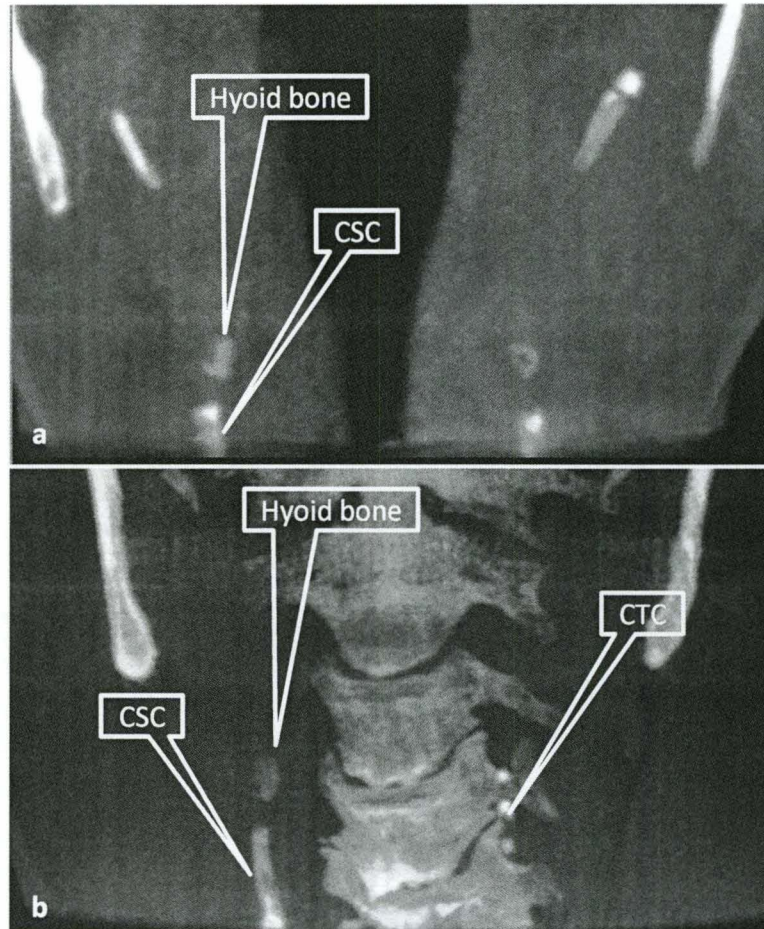


Figure 24. Coronal medium slice (10-20mm) maximum intensity orthogonal projections demonstrating the location and appearance of the SCT in relation to the hyoid bone (a). Triticeous cartilage can be differentiated from the SCT on these images as immediately inferior to the greater cornu and more solidly calcified (b)

- c. *Sagittal section.* On this projection the single peripherally corticated opacification were usually located along a line projected inferiorly and slightly anterior to the most posterior extent of the greater cornu of the hyoid bone (Fig. 25). Separation of the SCT from the greater cornu was evident

however sometimes a single more densely calcified structure (calcified triticeous cartilage) was located between these structures.

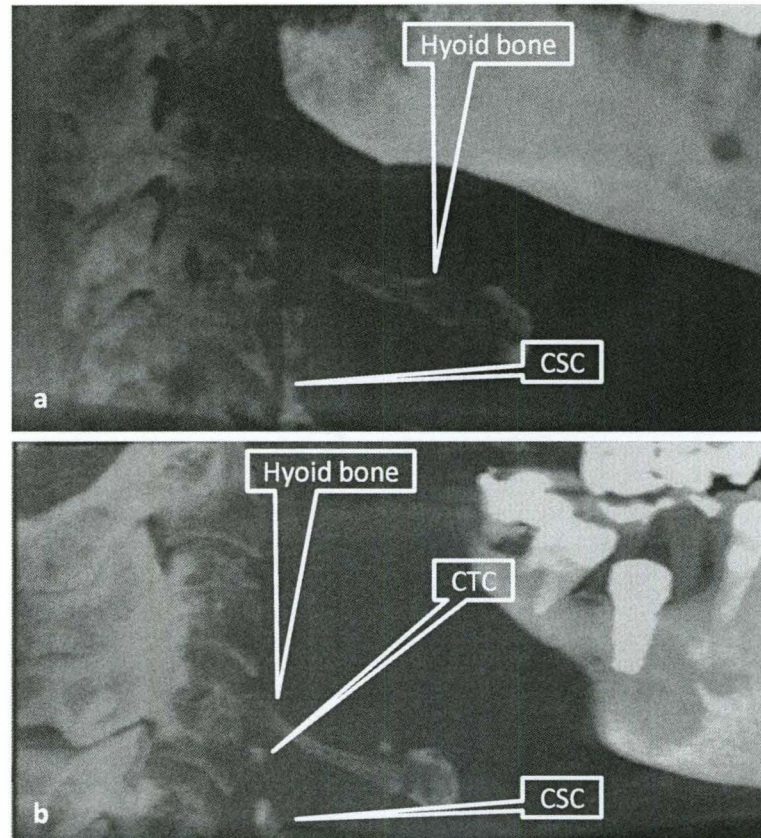


Figure 25. Sagittal medium slice (10-20mm) maximum intensity orthogonal projections demonstrating the location and appearance of the SCT in relation to the hyoid bone (a). Triticeous cartilage can be differentiated from the SCT on these images as immediately inferior to the greater cornu and more solidly calcified (b)

Demographics

Comparison of age of patients presenting with calcification of the superior cornu of the thyroid cartilage (SCT) with those not presenting this calcification in the sample is

shown in Table 22. The mean age of patients presenting with CT was 55.94 ± 10.06 years. The median age was 56 years, and the mode was 58. The age range was from 37 to 77 years old. Two tailed un-paired t test with unequal variances demonstrates no significant differences (t value = 0.97, p= 0.33) in mean age between those with CT compared to controls.

Table 22: Demographics of Patients Demonstrating SCT Compared to Controls

According to Age

<i>Age Parameter</i>	<i>Group</i>	
	<i>SCT</i>	<i>Control</i>
Mean (\pm s.d.)*	55.94 \pm 10.06	51.46 \pm 18.35
Median	56	55
Mode	58	52
Minimum	37	7
Maximum	77	86

*Unpaired t test assuming unequal variances
(t value = 0.97, p= 0.33)

The sex distribution of patients with CT are shown in Table 23. Chi-square analysis (Yates correction for continuity) ($X^2=0,53$; p=0.46) indicates no difference in the distribution of sex of those demonstrating SCT as compared to controls.

Table 23: Frequency Distribution (%) of Patients Demonstrating SCT and Controls
According to Sex.

<i>Sex</i>	<i>Group</i>		<i>Total</i>
	<i>SCT</i>	<i>Control</i>	
Male	5 (31 %)	128 (44 %)	133(43 %)
Female	11 (69 %)	164 (56 %)	175 (57 %)
Total	16 (100 %)	292 (100 %)	308 (100%)

Table 24 shows the type of scan performed on those who demonstrated calcifications compared to controls. Chi-square analysis with collapsed values from Full and Mx/Mn ($X^2=1.96$; $p=0.16$) indicated no differences between scan type for those who demonstrated calcifications and controls.

Table 24: Frequency Distribution (%) of Patients Demonstrating SCT Compared to Controls According to Scan Type.

<i>Scan Type</i>	<i>Group</i>		<i>Total</i>
	<i>SCT</i>	<i>Control</i>	
Full	5 (31 %)	112 (38 %)	117 (38 %)
Mx / Mn	1 (6 %)	59 (20 %)	60 (19 %)
Mandible	10 (63 %)	121 (41 %)	131 (43 %)
Total	16 (100 %)	292 (100 %)	308 (100%)

SCT occurred most frequently bilaterally ($n=12$, 75%). Of the remaining unilateral calcifications all were right ($n=4$, 25%).

Of the 16 patients with SCT, 12 (75%) had additional calcifications. Ten patients (62.5%) had one additional finding, whereas 2 (12.5%) had two additional calcifications.

The most common supplementary finding was TC (10 total; 5 bilateral, 5 unilateral [4 right, 1 left]). The second most common calcification was tonsilolith (2 total; both bilateral). One patient had a calcified lymph node and another had a CAC.

Lymph Node and Other Calcifications

Presentation

A number of other opacifications were observed in the sample that did not correspond to the anatomic location of the features previously described. Their identification was implied from their location and a consideration of the tissues in the corresponding region. These included lymph nodes (Fig. 26), superficial peripheral skin soft tissue calcifications (Fig. 27) and brain calcifications (Fig. 28).

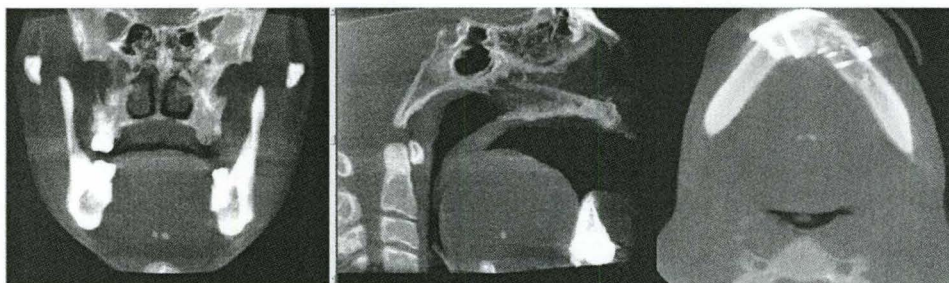

Figure 26. Coronal (left), sagittal (center) and axial (right) medium slice (10-20mm) maximum intensity orthogonal projections demonstrating the location and appearance of bilateral mid-line calcifications in the floor of the mouth. The location of these features is too posterior for salivary gland calcifications, too anterior for tonsilloliths and too central for ligamentous attachment calcifications. We classified these opacifications as submental lymph nodes based on the location of the SCT in relation to the hyoid bone

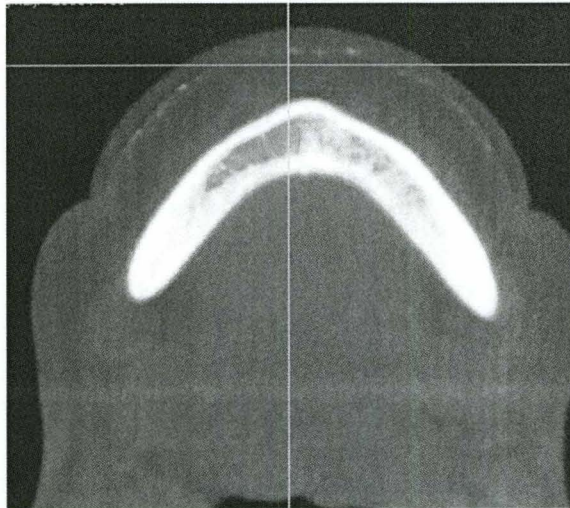

Figure 27. Axial medium slice (10-20mm) maximum intensity orthogonal projections demonstrating multiple small peripheral opacifications corresponding with calcifications in the skin – possibly calcified acne scars.

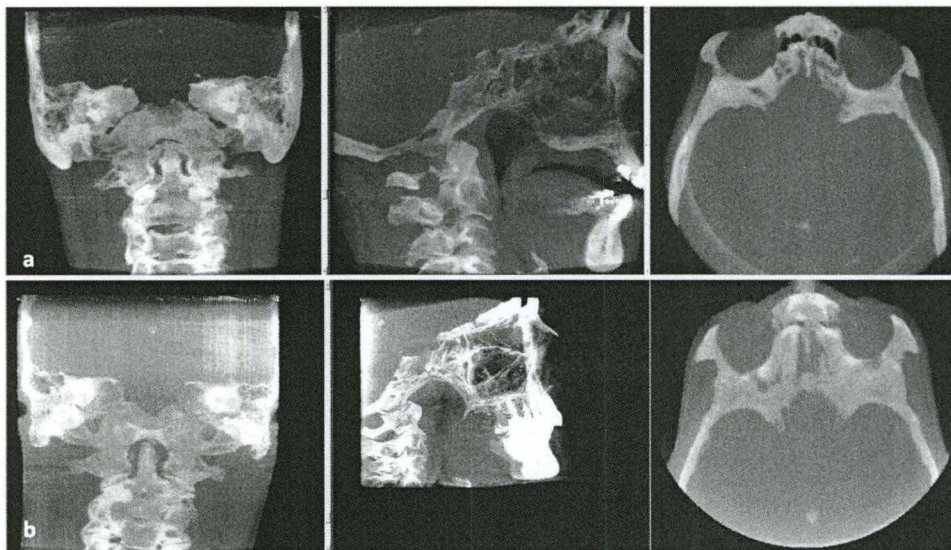


Figure 28. Coronal (left), sagittal (center) and axial (right) medium slice (10-20mm) maximum intensity orthogonal projections demonstrating a single small midline posterior opacification – the location and size is consistent with calcification of the falx cerebri

Demographics

Seventeen patients presented with incidental calcifications other than those previously described. The incidence of these calcifications relative to the overall sample and those with calcifications is shown in Table 25. Brain calcifications occurred most frequently, followed by lymph node and superficial skin calcifications.

Table 25: Frequency Distribution (%) of Patients Demonstrating Other Calcifications in Relation to the Total Sample and those Demonstrating Calcifications.

<i>Type of Calcification</i>	<i>Sample</i>		<i>Percentage</i>	
	<i>N</i>	<i>Of Total Sample (n=308)</i>	<i>Of Patients with Calcifications (n=107)</i>	
Superficial skin	4	1.3 %	3.7 %	
Brain	7	2.3 %	6.5 %	
Lymph Node	5	1.6 %	4.8 %	
Laryngeal stent	1	0.3 %	0.9 %	

Of the 17 patients with other calcifications including lymph nodes, 6 (35.3%) had additional calcifications. Five patients (47%.5%) had one additional finding, whereas 1 (5.9%) had two additional calcifications. The most common supplementary finding was CT (4 total; 1 bilateral, 3 unilateral [2 right, 1 left]). The remaining patients demonstrated bilateral SCT (1), TC (1) and CAC (1).

CHAPTER V

DISCUSSION

Purpose and Motivation

The purpose of this study was to identify the incidence and imaging characteristics of head and neck soft tissue calcifications on maxillofacial CBCT. Little research has been performed previously to define the incidence of calcifications on CBCT. Perhaps more importantly, there is scant information published on the imaging characteristics of how each calcification appears radiographically, especially on CBCT. Additional motivation for this study was to develop a broader knowledge on the characteristics of calcifications of atheromatous plaques within the carotid arteries on CBCT. This condition potentially poses more ominous clinical sequelae for patients, particularly as they act as a marker for cerebrovascular accident, or stroke. A better understanding of the presentation of these calcifications on CBCT will allow the dental practitioner using this imaging modality to more accurately distinguish calcified structures. This will permit a more timely and appropriate medical referral, particularly when identifying a problem within the carotid vessel.

Discussion of the Results

The study proves soft tissue calcifications of head and neck structures are a

common finding on CBCT scans in the relatively large sample size we used. Nearly 35% of patients exhibited at least one form of calcification. Past studies have evaluated the incidence of various structures of the head and neck region. These studies have proved to be informative, yet quite variable in the incidence percentages reported. As the majority of these studies used traditional 2D imaging modalities, a plausible explanation for the relatively large percentage in our study may be due to the superior imaging capabilities of CBCT. Another explanation may be due to the age and health of the patients in the database. Boyle, *et al.*[46] reported that 73% of all patients referred to the Radiology and Imaging Sciences Department at the University of Louisville were for implant site assessment and 86% of these were for patients over the age of 40. We know from previous studies that increasing age is correlated to increased incidence of calcification. The health of these patients was not known in this study, however, it can be assumed that many aging patients also may possess risk factors for dystrophic and pathologic calcification, namely within the carotid arteries. Past research studies have examined specific structures for calcifications, but did not look at the entire head and neck region for any form of calcification. Often past studies reported findings from conventional 2D imaging modalities and these modalities prove to be inferior in not only detection of a calcification, but in differentiating the precise diagnosis of the structure affected. The characteristics of the calcifications we found were quite variable and the 3D nature of the CBCT provided a superior diagnostic ability to view and study these characteristics in comparison to conventional 2D radiographic techniques.

In our sample, patients demonstrating calcifications were significantly older than those without. This is likely due to the aging process and processes mediated on a

cellular level. As will be discussed later, for arterial calcifications, an increase in prevalence with age is not only due to age, but due to risk factors associated with atherosclerosis and plaque formation.

It is important to comment briefly on our patient sample. The sample was reduced from 556 scans to 308 due to the application of exclusion criteria. No statistical significance was found between the included and excluded patient sample according to age or sex of the sample. This suggests that our findings are representative of the entire database with respect to age and sex.

Of the 308 patients included in the sample, 107 (35%) demonstrated at least one form of head and neck calcification. Those demonstrating calcifications were significantly older, on average by 12 years, than controls not showing calcified head and neck structures. The mean age of those with calcifications was 60 years compared to 48 for the control group. There were, however, no statistical differences for sex or scan type between the groups.

The most common type of calcification found in the study was the triticeous cartilage calcification. It comprised approximately 32% of all calcifications found. Followed closely and with nearly equal frequency were the carotid artery calcifications and tonsilloliths. Next was the superior cornu of the thyroid, the group of “other” types of calcifications (including brain, skin surface and scarring calcifications), and lastly lymph nodes. Within the calcification group, many patients were found to have more than one head and neck structure calcified contributing to a greater than 100% affected. Displaying more than one calcification was a relatively common finding in our study. This may carry little clinical consequence or significance; however it could be indicative

of an increased pathological process and represent an increased risk for arterial calcification. So noting single, and certainly multiple, calcifications on patient images should alert the clinician to monitor this patient more closely. Of the total patient sample, the triticeous cartilage had the highest overall incidence with 11.4% of the total sample. Followed closely were the carotid artery, the tonsils, the thyroid, structures within the “other” category, and lastly the lymph nodes.

Carotid Artery Calcifications

Central to our study was a thorough evaluation of calcifications of the carotid arteries. Over 10% of the patients in the sample demonstrated calcification within the carotid arteries. Previous studies have reported percentages ranging from 2.6% (with no pertinent medical history) to 7.1% (with a pertinent medical history).[11] Two likely explanations for the increased percentage of CAC in our study are the superiority of CBCT imaging versus 2D imaging modalities and an older, perhaps more at-risk, patient sample. Undoubtedly, pertinent medical history including risk factors such as body mass index, smoking, excessive alcohol consumption, stress, age and family history (to name a few) predispose a patient to developing atherosclerosis. The fact that we did not use the patient’s medical history or know of any risk factors could explain the slight increase in incidence in our study versus previous studies. As the average age of our patient sample was 52 years, it seems reasonable that our study would exhibit a slightly higher percentage of CAC in comparison to studies with lower mean ages. It could be that our particular patient sample exhibited greater than normal risk factors than the general population. Age was certainly a major factor in a patient’s likelihood of displaying a

calcification of the carotid artery. Patients were, on average, 18 years older than those not demonstrating a carotid artery calcification with the mean age at slightly over 68 years. It is also interesting to note that the lower end of the age range for the CAC was 45 years. This adds strength to age being a strong factor. Consistent with what has been reported in previous studies, males were more likely to be affected than females although the difference was not significant in our study. The type of scan administered revealed no difference between groups. This finding is important as it confirms that the type of scan will not preclude the dental professional from recognizing a CAC, so long as it meets our previously mentioned inclusion criteria (i.e. includes the region of interest and displays at minimum cervical vertebrae C3-C5). Again, for example, calcifications of any lower neck region calcifications (i.e. CAC) would not be evaluated on a CBCT scan of the maxilla only.

A relationship suggesting that finding a head and neck calcification would predispose that patient to CAC was not found as only 4 of the 32 patients had additional calcifications; however, it seems prudent for the clinician to become alerted and monitor more closely patients who exhibit some form of calcification.

Calcifications of the carotid artery were found to be quite variable in their size presentation using axial, coronal and sagittal slices; however quite consistent in their spatial orientation as they related to other head and neck structures. Being able to view the head and neck structures in three dimensions more readily allows for identification of these CAC and how they are oriented to other structures. This is perhaps the biggest diagnostic advantage with CBCT over 2D images. Viewing a cross section of the carotid artery presented interesting characteristics of these CAC. They could be found to be

remarkably small often occupying only a very tiny portion of the vessel wall to extremely large, encircling the vessel in its entire circumference. Identification and detection of calcifications of the carotid artery have important, potentially morbid, medical consequences. Brand, *et al.*[13] reported that serious sequelae and complications arise in patients who are found to have CAC seen on panoramic radiography. He noted that fifty-seven percent of such patients within 2.7 years (on average) suffer myocardial infarction (11%); stroke (7%); death (15%); revascularization procedures (11%); transient ischemic attack (3%); and angina (10%).

Most CAC were found to be bilateral and occurred at the level of C4 most commonly, followed by C3. All calcifications were found between the 3rd and 5th cervical vertebrae. This area corresponds to the level of the bifurcation which, as many previous studies indicate, is the most common area where calcified carotid artery plaques are found. There was no significant difference in sidedness, with right and left calcifications seen statistically with the same incidence. Evaluating the size of the CAC, it was found that they were larger when bilaterally occurring versus when only present on one side. Unilateral CAC were, on average, 2-3mm smaller in all dimensions than bilateral CAC.

As noted previously, image characteristics were quite variable in their presentation within the group and when using axial, coronal as well as sagittal slicing. However, they were quite consistent in their spatial orientation as they related to other head and neck structures. Using multiple projections facilitated the diagnosis of CAC and allowed for differentiation CAC from other head and neck calcifications. In the axial dimension, all CAC were within the soft tissue located anterior and lateral to the

transverse process. In relation to the hyoid bone, CAC were lateral and/or latero-posterior to the greater cornu. CAC were always posterior and lateral when compared to the pharyngeal airway space. Coronal slicing revealed CAC to be lateral to the anterior tubercle of the cervical vertebrae. Lastly, the sagittal dimension displays CAC to be inferior, and mostly posterior, to the angle of the mandible. CAC were also mostly anterior to the anterior cervical tubercle. Cervical level varied from C3 to C5 and was not seen outside this range either superiorly or inferiorly. Generally, CAC were either at or below the level of the superior cornu of the hyoid (a few were found to be above this structure).

Calcification of the Triticeous Cartilage

The most commonly occurring calcifications in our study were those involving the triticeous cartilage. Over 11% of all patients included in our study were found to exhibit calcification within this cartilage. Although the patients with TC were, on average, 5 years older than our control group, the difference was not significant. Using panoramic radiographs, Perez, *et al.*[25] found that calcifications of the triticeous cartilage were not age-dependent. They showed a mildly higher, albeit not significant, prevalence of TC in the 40-60 age group in comparison to the over 60 year age group.

In previous studies using 2D image modalities (i.e. panoramic radiographs), it was extremely difficult to differentiate between TC and CAC due to their proximity when viewed in two dimensions. Border shape, marginal and internal characteristics, as well as general opacification with the calcification were the only means to delineate a TC from CAC prior to 3D imaging.

Using orthogonal slices, we were able to characterize the presentation of these triticeous cartilage calcifications in all three dimensions. In the axial view, TC were medial and posterior to the greater cornu of the hyoid bone and approximating the superficial soft tissue in the lateral pre-vertebral space. The presentation on axial viewing allows for ready differentiation from a calcified carotid artery because a CAC opacification would be seen latero-posterior to the GCHB. This was adjacent but posterior to the oro-pharyngeal airway space at its widest portion though the slice. In coronal and sagittal views, all TC were immediately inferior to the greater cornu of the hyoid bone. It is slightly anterior to the greater cornu in the sagittal view.

In our study, females had a significantly higher incidence of triticeous cartilage calcification than males. Ahmad, *et al.*, [25] found females to have a greater predilection for calcification of the triticeous, while Hately, *et al.*, [26] contrarily found that men were more commonly affected.

Calcification of the Tonsils

Along with the carotid artery and the triticeous cartilage, the tonsils were found to exhibit a high incidence of calcification in our study. Over 10% of all patients in the study were affected, while tonsilloliths comprised 30% of all the calcifications found. We found a significant difference in age compared to our control group with patients demonstrating tonsilloliths patients being on average 7 years older. No differences were found when comparing sex or scan type. Interestingly, 31% of the patients in this group had additional calcifications. Again, this could suggest a pathologic process and alert the clinician to look for other head and neck calcifications, namely within a carotid artery.

The presentation and location of the tonsilloliths was pathognomonic. Most often, they appeared multiple in nature and were clustered homogenous dense opacifications. In the axial view, multiple small opacifications were located anterior and lateral to the oro-pharyngeal airway space. This makes them readily differentiated from triticeous calcifications of the triticeous cartilage and carotid artery as these will appear posterior to the airway space. They are immediately medial to the mandibular angle or ramus. On coronal slicing, tonsilloliths were often found superimposed over the anterior tubercle of the cervical spine. In the sagittal view, they were superimposed over the shadow of the oro-pharyngeal airway space or anterior to it.

Calcification of the Superior Cornu of Thyroid Cartilage

The thyroid cartilage was found to have calcifications in over 5% of our total sample and comprised 15% of our calcification group. Although patients exhibiting SCT were 5 years older than controls, it was not statistically significant. In addition, no significant difference was noted for sex or the type of scan administered for the patient. The fact that we did not see a significant difference in age between groups could be attributed to the manner in which this cartilage becomes calcified. As Salman, et al.,[47] noted, this calcification of the thyroid is a progressive condition normally being completed around age 70. Looking closely at the age distribution in our study, we see that our youngest patient was 37. A progressive condition suggests the calcification process begins (hence is radiographically detectable) at an earlier stage or age and continues to progress as that patient ages.

As it can easily be misdiagnosed for a triticeous or carotid calcification as well as

the greater cornu of the hyoid bone, it is important to further characterize its CBCT presentation. On our axial slices, it is noted that the opacification was immediately posterior to the greater cornu of the hyoid bone. This is a clear differentiation from the TC that appears medial to the most posterior extent of the GCHB. Viewing coronally, linear cylindrical opacifications extending inferiorly from the GCHB were noted. Occasionally, “rice-grain” size opacities (SCT) were interposed between the GCHB and the thyroid calcification. The location and mostly the size of the radiopacities allowed for more ready differentiation when viewing only this orthogonal projection. Supplementing the view with axial and sagittal slicing allows for more definitive differentiation. Sagittal projections show single peripherally corticated opacification usually located along a line projected inferiorly and slightly anterior to the most posterior extent of the GCHB. Again, an occasional SCT was interposed between the two structures. Typically, the SCT was single and more densely calcified.

Other Calcifications

Seventeen additional calcifications were found in our patient sample comprising nearly 6% of the sample and 16% of the calcification group. They included calcification of lymph nodes, brain tissue, and superficial peripheral skin soft tissue calcifications. We identified the structure affected by their location and taking into account the surrounding tissues. Each orthogonal view was used to identify the location and form a diagnosis. These incidental findings did not have image properties nor approximate the area of the carotid artery so these do not pose a real harm for the patient with the information that we know now. However, it is prudent for the dental professional to be cognizant of these

findings. Of the “other” group, brain calcifications occurred most frequently with seven patients affected followed by lymph node calcifications and those affecting the skin.

Limitations of this Study

It is important to comment on the limitations of this study. One problem or limitation with a study of this nature is that all patients in the study came from the same source. All patients in the study were from a University-based private office. It can be reasonably speculated that the patient pool is not entirely representative of the general population. One such example of this lack of general population representation lies in the reason for them getting a CBCT scan. The great majority of the patients are receiving CBCT for dental implant purposes. These patients will obviously, on average, be older than a normal randomized sampling of the general population. This can skew overall incidence numbers. Another factor to note is the lack of medical history for our sample. Only the age, sex, date of scan and scan type were known for the patient. It is quite reasonable to assume patients who are receiving CBCT, on average, are older and likely more medically compromised than the general population. It is well documented that more morbid conditions, such as carotid artery calcifications, are closely related to patients’ age and compromised medical history.

Areas of Future Research

While we were able to gain more knowledge from this study on the incidence and imaging characteristics of specific soft tissue dystrophic calcifications, future areas of research should be directed towards identifying and correlating more specific clinical risk

factors with each type of calcification. This would require access to patient information including dental and medical histories for the patient sample. It would also be prudent to follow a patient group to see how these calcifications morphological alter and whether or not a change in size occurs with time. This would require a longitudinal, long-term study design.

Ominous sequelae can await patients who are found to have calcified carotid arteries. Future areas of research could serve to develop more defined referral protocols for these patients. It would be useful to collaborate with a medical team, including a cardiologist, to follow these patients. Perhaps a study using Doppler sonography to measure stenosis within the vessel along with the size and morphology of the calcification on CBCT would add enormous data and information relevant to that person's medical care. This would elucidate some information on whether the magnitude or size of the calcification is correlated with the level of arterial stenosis within the carotid. This could also potentially cut medical expenditures as well as yield more accurate referral and help prevent morbid outcomes for these patients.

Other areas of future research in this arena may include a direct comparison of planar versus CBCT image presentation for the same patient. Another possible investigation could be directed towards assessment of non-trained vs. trained dental professionals' detection and knowledge of head and neck calcifications. Knowing the success rate of the dentist in accurately identifying a carotid artery calcification would be of great value and lends enormous credibility to a study such as this. This could be a great tool for educating dental professionals on accurately diagnosing carotid artery calcifications which pose such potential for morbidity. In concert with knowing the

patient's medical history (i.e. risk level), a good understanding of the image presentation and characteristics should decrease misdiagnosis. As most head and neck soft tissue calcifications are benign in nature, the key is accurately diagnosing them. A false negative in diagnosis of carotid artery calcification could prevent critical medical evaluation.

CHAPTER VI

SUMMARY AND CONCLUSIONS

- A substantial portion (35%) of the patient sample had at least one head and neck soft tissue calcification identifiable on CBCT imaging.
- The most common dystrophic calcifications occurred in the triticeous cartilages, the tonsils, and the atheromatous plaque of carotid arteries at the carotid bifurcation (with nearly equal frequency)
- CBCT imaging gives differential detailed information concerning the image characteristics of these calcifications.
- The imaging presentation of soft tissue calcifications in the head and neck provide consistent spatial orientation.
- Calcifications of the atheromatous plaque of carotid arteries can be accurately detected and characterized with CBCT.

REFERENCES

1. Kirsch, T., *Determinants of pathological mineralization*. *Curr Opin Rheumatol*, 2006. **18**(2): p. 174-80.
2. Shroff, R.C. and C.M. Shanahan, *The vascular biology of calcification*. *Semin Dial*, 2007. **20**(2): p. 103-9.
3. Tegos, T.J., *et al.*, *The genesis of atherosclerosis and risk factors: a review*. *Angiology*, 2001. **52**(2): p. 89-98.
4. Gorelick, P.B., *et al.*, *Prevention of a first stroke: a review of guidelines and a multidisciplinary consensus statement from the National Stroke Association*. *JAMA*, 1999. **281**(12): p. 1112-20.
5. Friedlander, A.H. and I.K. Friedlander, *Identification of stroke prone patients by panoramic dental radiography*. *Oral Health*, 1996. **86**(7): p. 7, 9-10.
6. Friedlander, A.H. and A. Lande, *Panoramic radiographic identification of carotid arterial plaques*. *Oral Surg Oral Med Oral Pathol*, 1981. **52**(1): p. 102-4.
7. Carter, L.C., K. Tsimidis, and J. Fabiano, *Carotid calcifications on panoramic radiography identify an asymptomatic male patient at risk for stroke. A case report*. *Oral Surg Oral Med Oral Pathol Oral Radiol Endod*, 1998. **85**(1): p. 119-22.
8. Freymiller, E.G., E.C. Sung, and A.H. Friedlander, *Detection of radiation-induced cervical atheromas by panoramic radiography*. *Oral Oncol*, 2000. **36**(2): p. 175-9.
9. Friedlander, A.H. and M. August, *The role of panoramic radiography in determining an increased risk of cervical atheromas in patients treated with therapeutic irradiation*. *Oral Surg Oral Med Oral Pathol Oral Radiol Endod*, 1998. **85**(3): p. 339-44.
10. Friedlander, A.H., *et al.*, *Detection of radiation-induced, accelerated atherosclerosis in patients with osteoradionecrosis by panoramic radiography*. *J Oral Maxillofac Surg*, 1998. **56**(4): p. 455-9.
11. Almog, D.M., *et al.*, *Correlating carotid artery stenosis detected by panoramic radiography with clinically relevant carotid artery stenosis determined by duplex ultrasound*. *Oral Surg Oral Med Oral Pathol Oral Radiol Endod*, 2002. **94**(6): p. 768-73.
12. Friedlander, A.H., *et al.*, *The prevalence of carotid atheromas seen on panoramic radiographs of patients with obstructive sleep apnea and their relation to risk factors for atherosclerosis*. *J Oral Maxillofac Surg*, 1999. **57**(5): p. 516-21; discussion 521-2.

13. Geist, J.R. and J.W. Brand, *Oral pathology quiz #6. Calcified atheromas*. J Mich Dent Assoc, 2002. **84**(6): p. 36-9.
14. Yin, D. and J.P. Carpenter, *Cost-effectiveness of screening for asymptomatic carotid stenosis*. J Vasc Surg, 1998. **27**(2): p. 245-55.
15. Gossman, J.R., Jr. and J.J. Tarsitano, *The styloid-stylohyoid syndrome*. J Oral Surg, 1977. **35**(7): p. 555-60.
16. MK, O.C., *Calcification in the stylohyoid ligament*. Oral Surg Oral Med Oral Pathol, 1984. **58**(5): p. 617-21.
17. Monsour, P.A. and W.G. Young, *Variability of the styloid process and stylohyoid ligament in panoramic radiographs*. Oral Surg Oral Med Oral Pathol, 1986. **61**(5): p. 522-6.
18. Messer, E.J. and A.M. Abramson, *The stylohyoid syndrome*. J Oral Surg, 1975. **33**(9): p. 664-7.
19. Correll, R.W., et al., *Mineralization of the stylohyoid-stylomandibular ligament complex. A radiographic incidence study*. Oral Surg Oral Med Oral Pathol, 1979. **48**(4): p. 286-91.
20. Langlais, R.P., D.A. Miles, and M.L. Van Dis, *Elongated and mineralized stylohyoid ligament complex: a proposed classification and report of a case of Eagle's syndrome*. Oral Surg Oral Med Oral Pathol, 1986. **61**(5): p. 527-32.
21. Camarda, A.J., C. Deschamps, and D. Forest, *I. Stylohyoid chain ossification: a discussion of etiology*. Oral Surg Oral Med Oral Pathol, 1989. **67**(5): p. 508-14.
22. Ferrario, V.F., et al., *Calcification of the stylohyoid ligament: incidence and morphoquantitative evaluations*. Oral Surg Oral Med Oral Pathol, 1990. **69**(4): p. 524-9.
23. Carter, L.C., *Discrimination between calcified triticeous cartilage and calcified carotid atheroma on panoramic radiography*. Oral Surg Oral Med Oral Pathol Oral Radiol Endod, 2000. **90**(1): p. 108-10.
24. Ajmani, M.L., S.P. Jain, and S.K. Saxena, *A metrical study of laryngeal cartilages and their ossification*. Anat Anz, 1980. **148**(1): p. 42-8.
25. Ahmad, M., R. Madden, and L. Perez, *Triticeous cartilage: prevalence on panoramic radiographs and diagnostic criteria*. Oral Surg Oral Med Oral Pathol Oral Radiol Endod, 2005. **99**(2): p. 225-30.
26. Hatley, W., E. Samuel, and G. Evison, *The Pattern of Ossification in the Laryngeal Cartilages: A Radiological Study*. Br J Radiol, 1965. **38**: p. 585-91.
27. O'Bannon, R.P. and O.H. Grunow, *The larynx and pharynx radiologically considered*. South Med J, 1954. **47**(4): p. 310-6.
30. Rabinov, K., T. Kell, Jr., and P.H. Gordon, *CT of the salivary glands*. Radiol Clin North Am, 1984. **22**(1): p. 145-59.

31. Iro, H., J. Długaiczek, and J. Zenk, *Current concepts in diagnosis and treatment of sialolithiasis*. Br J Hosp Med (Lond), 2006. **67**(1): p. 24-8.
32. Jensen, J.L., *et al.*, *Minor salivary gland calculi. A clinicopathologic study of forty-seven new cases*. Oral Surg Oral Med Oral Pathol, 1979. **47**(1): p. 44-50.
33. Takeda, Y., *Crystalloids with calcareous deposition in the parotid gland: one of the possible causes of development of salivary calculi*. J Oral Pathol, 1986. **15**(8): p. 459-61.
34. van den Akker, H.P., *Diagnostic imaging in salivary gland disease*. Oral Surg Oral Med Oral Pathol, 1988. **66**(5): p. 625-37.
35. Bar, T., *et al.*, *Calcifications simulating sialolithiasis of the major salivary glands*. Dentomaxillofac Radiol, 2007. **36**(1): p. 59-62.
36. Williams, M.P. and G.R. Cherryman, *Lymph-node calcification in Lennert's lymphoma*. Br J Radiol, 1987. **60**(719): p. 1131-2.
37. Cerny, R. and V. Bekarek, *Tonsillolith*. Acta Univ Palacki Olomuc Fac Med, 1990. **126**: p. 267-73.
38. Cooper, M.M., *et al.*, *Tonsillar calculi. Report of a case and review of the literature*. Oral Surg Oral Med Oral Pathol, 1983. **55**(3): p. 239-43.
39. Pruet, C.W. and D.A. Duplan, *Tonsil concretions and tonsilloliths*. Otolaryngol Clin North Am, 1987. **20**(2): p. 305-9.
40. Aspestrand, F. and A. Kolbenstvedt, *Calcifications of the palatine tonsillary region: CT demonstration*. Radiology, 1987. **165**(2): p. 479-80.
41. Hiranandani, L.H., *A giant tonsillolith*. J Laryngol Otol, 1967. **81**(7): p. 819-22.
42. Neshat, K., K.J. Penna, and D.H. Shah, *Tonsillolith: a case report*. J Oral Maxillofac Surg, 2001. **59**(6): p. 692-3.
43. Castellano, M. and G. Marcolli, *[Giant tonsillar calculus simulating a neoplasm]*. Minerva Med, 1966. **57**(38): p. 1686-8.
44. Jones, J.W., *A tonsillolith*. Br Dent J, 1996. **180**(4): p. 128.
45. Hessel, A.C., *et al.*, *Vascular lesion of the masseter presenting with phlebolith*. Otolaryngol Head Neck Surg, 1999. **120**(4): p. 545-8.
46. Boyle, E.M., *Emerging Trends in Cone Beam Computed Tomography Utilization*. Masters of Science in Oral Biology, University of Louisville Graduate School, May, 2010
47. Salman, R.A., Kinney L.A., *Calcified thyroid cartilage*. Oral Surg Oral Med Oral Pathol, 1990. **70**: 806-807.

CURRICULUM VITAE

NAME: Adam Brent Wells

ADDRESS: 2634 Escala Circle, San Diego, CA 92108

DOB: Middletown, Ohio - April 20, 1977

EDUCATION AND TRAINING: University of Louisville School of Dentistry
-Doctor of Dental Medicine
-D.M.D.- *cum laude* graduate- 2006
-Department of Orthodontics & Dentofacial Orthopedics, Residency Program- 2008
-Department of Oral Biology
Master's in Oral Biology- 2007-present
Miami University, Oxford, Ohio
-B.A. in Zoology- 1999

AWARDS: Certificate of Merit in Research
Quintessence Publishing Company- 2006
ULSD Dean's Scholar & Dean's List- 2002-2006
James C. Moore Physiology Award Candidate- 2002

PROFESSIONAL SOCIETIES: American Association of Orthodontists
Pacific Coast Society of Orthodontists
American Dental Association

PUBLICATIONS: University of Louisville Department of Radiology-
Khan Z, Wells A, Scarfe W, Farman A. Cone Beam CT
isolation of calcifications in the maxillofacial and cervical
soft tissues: A retrospective analysis. *Int J Computer Assist
Radiol Surg* 2008;3 (Suppl1): S221-S222.

University of Cincinnati Department of Cell Biology
Coolen LM, Veening JG, Wells AB, Shipley MT. 2003.
*Afferent Connections of the Parvocellular
Subparafascicular Thalamic Nucleus in the Rat: Evidence
for Functional Subdivisions. Journal of Comparative
Neurology.* 463:132-156.

**PRESENTATIONS/
MEETINGS:**

Society for Behavioral Neuroendocrinology Mtg
Scottsdale, Arizona- June 2001. *Copulation-induced
neural activation in lumbar spinal cord of the rat.* Wells
AB, and Coolen L M.

Research! Louisville- Louisville, Ky- November 2005.
*Habits, systemic health, demographics and prevalence of
carotid plaque calcification*
Wells AB, Khan Z, Scheetz JP, Farman AF. Presented
poster on summer research project.