

Coll. Antropol. 28 (2004) 2: 937–941  
UDC 616.341-006.44:616.346.2-002  
Case report

# Spontaneously Ruptured Gastrointestinal Stromal Tumor (GIST) of the Jejunum Mimicking Acute Appendicitis

Marko Ajduk<sup>1</sup>, Danko Mikulić<sup>2</sup>, Božidar Šebečić<sup>1</sup>, Slavko Gašparov<sup>3</sup>, Leonardo Patrlj<sup>1</sup>, Lidija Erdelez<sup>1</sup>, Andrija Škopljanac<sup>1</sup>, Mario Starešinić<sup>1</sup>, Slobodan Dešković<sup>1</sup>, Tomislav Šoša<sup>1</sup> and Sanda Šitić<sup>3</sup>

<sup>1</sup> Department of Surgery, University Hospital Merkur, Zagreb, Croatia

<sup>2</sup> Department of Surgery, Zagreb Children's Hospital, Zagreb, Croatia

<sup>3</sup> Department of Pathology, University Hospital Merkur, Zagreb, Croatia

## ABSTRACT

*Gastrointestinal stromal tumors (GISTs) are characterized with diverse clinical presentations, including acute and chronic gastrointestinal bleeding, abdominal pain, presence of an intra-abdominal mass, anorexia, and intestinal obstruction. A 60-year-old obese woman presented as an acute abdominal emergency with right lower quadrant (RLQ) pain and tenderness, nausea and leukocytosis, all mimicking acute appendicitis. Laparotomy revealed a spontaneously ruptured GIST of the jejunum, which was localized to the RLQ due to postoperative adhesions following previous two cesarean sections and cholecystectomy. Complete surgical resection was performed, followed by an uneventful early postoperative course.*

**Key Words:** *gastrointestinal stromal tumor, acute appendicitis, intestinal bleeding, intestinal ulceration, abdominal mass, proto oncogene c kit, tyrosin kinase, imatinib mesylate*

## Introduction

Gastrointestinal stromal tumors (GISTs) are the largest category of primary non-epithelial, non-lymphoid neoplasms of the gastrointestinal tract. Malignant form of

GIST represents about 2% of malignant gastrointestinal tumors.<sup>1</sup> GISTs were previously referred to as leiomyomas, leiomyosarcomas, or schwannomas. With

the recent development of increasingly accurate analytical tools, incomplete myogenic, neural or mixed differentiation and remarkable cellular variability were demonstrated.<sup>2,3</sup> The candidates for histogenetic origin of the tumor include interstitial cells of Cajal and pluripotential stem cells.<sup>4</sup> Presently, diagnosis of GIST requires the use of immunohistochemical studies.<sup>5</sup>

GISTs are most commonly located in the stomach (60–70%) and small intestine (20–25%). Less frequent tumor sites include the colon and rectum, esophagus and locations outside the gastrointestinal tract (omentum, mesenteries, and retroperitoneum).<sup>5</sup> Malignant potential of GISTs is difficult to predict, although tumor size (diameter > 5cm), high mitotic rate (> 5 mitoses per 50 high-power fields) and site (malignant GISTs are more common in the ileum), have traditionally been accepted as indicators of increased aggressiveness.<sup>6,7</sup> Most recently, genetic markers, including DNA ploidy, telomerase activity and mutation status of the c-kit proto-oncogene, have been identified as factors useful to distinguish the tumors with malignant potential.<sup>8–10</sup>

Clinical presentation of GIST is primarily dependent on the site of origin and it shows exceptional variability.<sup>11</sup> Signs and symptoms are usually nonspecific and not evident until the tumor is advanced and of considerable size. With the development of such circumstances, a patient may experience anorexia, abdominal pain, weight loss or symptoms of intestinal obstruction.<sup>12</sup> Sometimes, a palpable intra-abdominal mass is present. Acute or chronic blood loss with resulting anemia is common, with ulcerating lesions.<sup>13</sup> Spontaneous rupture of the tumor with peritonitis has also been described.<sup>14</sup> Review of the available literature did not reveal cases of GIST clinically simulating acute appendicitis.

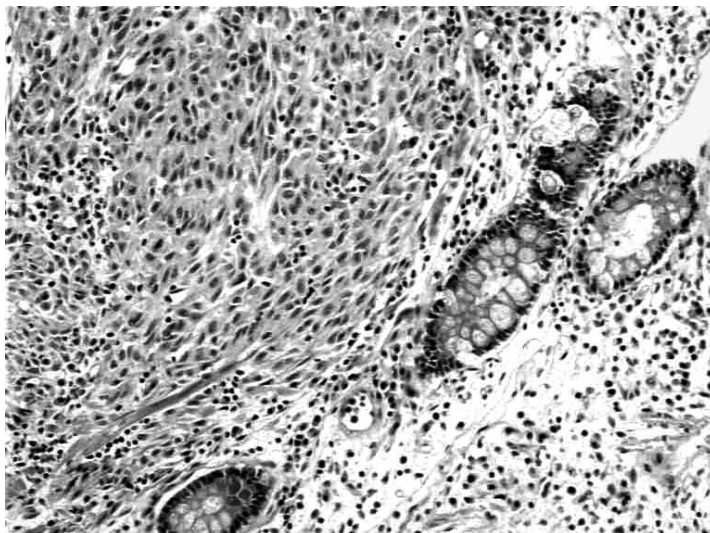
## Case report

A 60-year-old obese woman presented with a 2-day history of severe pain localized to the right lower abdominal quadrant. The patient had nausea; however, vomiting was absent. Bowel and urinary function were normal. Body temperature at admission was 37.5 °C and blood pressure was normotensive. The patient's previous medical history included two cesarean sections, cholecystectomy, and surgery for meningioma of the posterior cranial fossa. A year prior to present illness there was an episode of melena, which was not diagnostically evaluated.

Physical examination revealed tenderness to palpation in the RLQ with rebound tenderness and guarding. Rectal examination was nonspecific except for tenderness localized to the right side. The only abnormality documented in the laboratory examinations was a leukocytosis of  $12.9 \times 10^9$ , with a shift to the left.

A preoperative diagnosis of acute appendicitis was made and a laparotomy was performed through a standard McBurney incision. Free blood in the peritoneal cavity was found and a ruptured tumor was visualized arising from the anti-mesenteric side of a jejunal loop, which was fixed to the ileo-cecal fossa by postoperative adhesions. The tumor appeared as an exophytic mass ca. 7 cm in diameter, with a smooth outer surface and a tear through which central necrosis was seen. Segmental resection of the portion of jejunum containing the lesion was performed, followed by a termino-terminal anastomosis. Postoperative recovery was uneventful and the patient was released from the hospital on postoperative day 12 and referred to an oncologist for further evaluation and treatment.

Histopathology revealed a gastrointestinal stromal tumor, measuring 7.5 cm in diameter and protruding out of the bowel with the significant portion, only a



*Fig. 1. The neoplastic cells infiltrate mucosa of small intestine (hematoxylin and eosin, magnification  $\times 100$ ).*

smaller portion being intramural. An area of ulcerated intestinal mucosa that measured 1.5 cm in diameter was present. The outer surface of the tumor was smooth, whereas cross-sections showed a pseudocystic structure with central necrotic areas. Cellular morphology was partly spindle-shaped, but predominantly epitheloid.

The neoplastic cells infiltrated mucosa of the small intestine (Fig. 1). Mitotic count was 3 per 10 high-power fields. Immunohistochemical stainings were performed for vimentin (M7020; Dako; 1:100), S-100 protein (Z311; Dako; 1:1000), CD 34 (M0824; Dako; 1:25), CD117 (c-kit protein: A4502; Dako; 1:50), NSE (N0873; Dako; 1:300), and smooth muscle actin (M851; Dako; 1:50). The detection system used was horseradish peroxidase (HRP). The tumor cells stained positive for vimentin, S-100 protein, CD34, and CD117 (c-kit protein; Fig. 2). There was no immunoreactivity for NSE and smooth muscle actin.

## Discussion

To the best of our knowledge, spontaneously ruptured gastrointestinal stromal tumor clinically mimicking acute appendicitis has not been reported previously. Various reported presentations include acute and chronic gastrointestinal bleeding, abdominal pain, anorexia, presence of an intra-abdominal mass, intestinal obstruction and rupture with diffuse peritonitis.<sup>11–14</sup> Our patient's tumor was located in the distal jejunum. However, due to adhesions from previous operations (two cesarean sections and cholecystectomy), jejunum was positioned in the ileo-cecal fossa. When the spontaneous rupture of the tumor and hemoperitoneum occurred, peritoneal irritation with subsequent pain and tenderness remained localized to the RLQ. Due to obesity of the patient, the tumor was not palpable preoperatively.

It seems likely that the episode of gastrointestinal bleeding that occurred 1 year prior to presentation resulted from the same tumor, ulcerating the jejunal

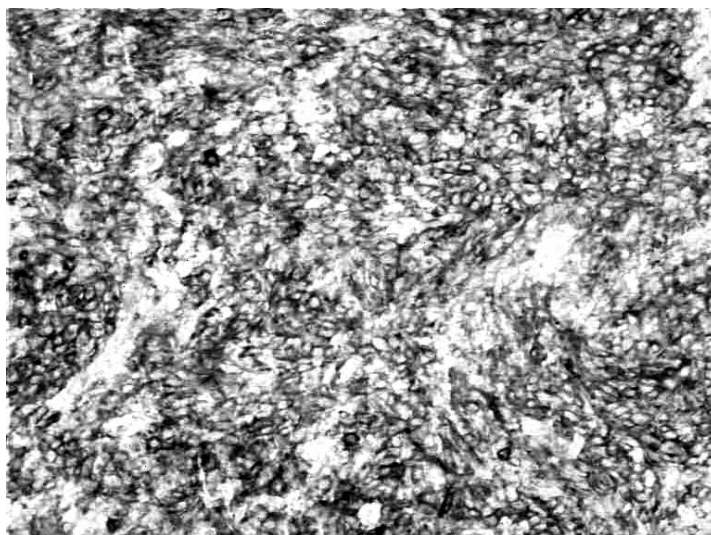


Fig. 2. The tumor cells show strong immunoreactivity for c-kit (HRP, magnification  $\times 100$ ).

mucosa. Unfortunately, diagnostic evaluation was not carried out at the time and the cause of bleeding remained obscure. The size of the tumor, mitotic activity and occurrence of rupture, predispose this patient to an unfavorable long-term prognosis.

Gastrointestinal stromal tumors (GISTs) are a rare group of neoplasms with diverse biologic, clinical and histological presentations. Since GISTs are resistant to irradiation and standard chemotherapy, surgical resection is considered to be the mainstay of treatment. Recently, major advances have been made in understanding the biology of GIST, especially regard-

ing the role of mutation of the c-kit proto-oncogene and resulting tyrosine kinase activation.<sup>10</sup> Novel molecularly targeted therapies using tyrosine kinase inhibitors have been developed with established as an effective agent in patients with advanced, metastatic, or unresectable tumors.<sup>16–18</sup> Currently, it is also under investigation as an adjuvant and neoadjuvant therapy.<sup>19</sup>

This case report shows how wide spectrum of diseases can result with similar clinical presentation, requiring high index of suspicion even with such a »clear« diagnosis as acute appendicitis is considered to be.

## REFERENCES

1. ROSAI, J.: Gastrointestinal tract. In: ROSAI, J. (ed). Ackerman's Surgical Pathology, 8<sup>th</sup> ed. (Mosby, St Louis, 1996), pp. 645–647. — 2. MIETTINEN, M., Am. J. Clin. Pathol., 89 (1988) 601. — 3. ERLANDSON, R. A., D. S. KLIMSTRA, J. M. WOODRUFF, Ultrastruct. Pathol., 20 (1996) 373. — 4. SIRCAR, K., B. R. HEWLETT, J. D. HUIZINGA, K. CHORNEYEKO, I. BEREZIN, R. H. RIDDEL, Am. J. Surg. Pathol., 23 (1999) 377. — 5. MIETTINEN, M., J. LASOTA, Virchows Arch., 438 (2001) 1. — 6. PIDHORECKY, I., R. T. CHENEY, W. G. KRAYBILL, J. F. GIBBS, Ann. Surg. Oncol., 7 (2000) 705. — 7. MIETTINEN, M., W. EL-RIFAI, H. L. SOBIN, J. LASOTA, Hum. Pathol., 33 (2002) 478. — 8. CARRILLO, R., A. CANDIA, J. L. RODRIGUEZ-PERALTO, V. CAZ, Am. J. Clin. Pathol., 103 (1995) 41. — 9. SAKURAI, S., M. FUKAYA-

- MA, Y. KAIZAKI, K. SAITO, K. KANAZAWA, M. KITAMURA, Y. IWASAKI, T. HISHIMA, Y. HAYASHI, M. KOIKE, *Cancer*, 83 (1998) 2060. — 10. HEINRICH, M. C., B. P. RUBIN, B. J. LONGLEY, J. A. FLETCHER, *Hum. Pathol.*, 33 (2002) 484. — 11. CATENA, F., E. PASQUALINI, O. CAMPIONE, *Dig. Surg.*, 17 (2000) 503. — 12. DEMATTEO, R. P., J. J. LEWIS, D. LEUNG, S. S. MUDAN, J. M. WOODRUF, M. F. BRENNAN, *Ann. Surg.*, 231 (2000) 51. — 13. BAGNOLO, F., U. BONASSI, R. SCELISI, P. A. TESTONI, *Eur. J. Gastroentrol. Hepatol.*, 10 (1988) 791. — 14. KITABAYASHI, K., T. SEKI, K. KISHIMOTO, *Surg. Today*, 31 (2001) 350. — 15. DEMETRI, G. D., *Semin. Oncol.*, 28 (2001) 19. — 16. VAN OOSTEROM, A. T., I. R. JUDSON, J. VERWEIJ, S. STROOBANTS, H. DUMEZ, E. DONATO DI PAOLA, R. SCIOT, M. VAN GLABBEKE, S. DIMITRIJEVIC, O. S. NIELSEN, *Eur. J. Cancer*, 38 Suppl 5 (2002) 83. — 17. DEMETRI, G. D., *Eur. J. Cancer.*, 38 suppl 5 (2002) 52. — 18. DAGHER, R., M. COHEN, G. WILLIAMS, M. ROTHMANN, J. GOBBURU, G. ROBBIE, A. RAHMAN, G. CHEN, A. STATEN, D. GRIEBEL, R. PAZDUR, *Clin. Cancer Res.*, 8 (2002) 3034. — 19. DEMATTEO, R. P., M. C. HEINRICH, W. M. EL-RIFAI, G. DEMETRI, *Hum. Pathol.*, 33 (2002) 466.

*M. Ajduk*

*Department of Surgery, University Hospital Merkur, Zajčeva 19, 10000 Zagreb, Croatia  
e-mail: majduk@globalnet.hr*

## **SPONTANO RUPTURIRANI GASTROINTESTINALNI STROMALNI TUMOR (GIST) JEJUNUMA KOJI JE UPUĆIVAO NA AKUTNI APENDICITIS**

### **S A Ž E T A K**

Gastrointestinalni stromalni tumori (GIST) mogu imati raznoliku kliničku sliku. Ona uključuje akutno i kronično gastrointestinalno krvarenje, bolove u trbuhu, palpabilne tumorske mase, anoreksiju i simptome crijevne opstrukcije. Šezdesetgodišnja žena primljena je s bolovima i peritonealnim podražajem u donjem desnom kvadrantu trbuha, mučninom i leukocitozom. Klinička slika i nalazi upućivali su na akutni apendicitis. Laparotomijom se nađe rupturirani GIST jejunuma u donjem desnom kvadrantu trbuha, privučen priraslicama nakon dva prethodna carska reza i kolecistektomije. Tumor je liječen resekcijom zahvaćenog dijela crijeva. Perioperacijski tijek bolesnika bio je uredan.