

Recurrent Pleomorphic Adenoma of Epipharynx Following Irradiation Therapy

Gordana Zamolo¹, Miran Coklo¹, Marija Petković², Tanja Batinac³, Alan Bosnar⁴, Darko Manestar⁵, Andrea Dekanić¹ and Božidar Vojniković⁶

¹ Department of Pathology, Faculty of Medicine, University of »Rijeka«, Rijeka, Croatia

² Department of Radiotherapy and Oncology, Clinical Hospital Center »Rijeka«, Rijeka, Croatia

³ Department of Dermatovenereology, Clinical Hospital Center »Rijeka«, Rijeka, Croatia

⁴ Department of Forensic Medicine, Faculty of Medicine, University of Rijeka, Rijeka, Croatia

⁵ Department of Otorhinolaryngology, Clinical Hospital Center »Rijeka«, Rijeka, Croatia

⁶ Polyclinic »Dr. B. Vojnikovic«, Rijeka, Croatia

ABSTRACT

We present a case of a 67-year-old female patient having a pleomorphic adenoma of epipharynx with intact fibrous capsula, which despite its benignity recurred and, moreover, responded quite well to irradiation therapy. The patient, at first, refused any therapy. Three years later, when the CT showed tumor enlargement she accepted only irradiation therapy, resulting in significant reduction of tumor size. Five years later the tumor recurred but without malignant transformation. She still refused surgery, but accepted re-irradiation therapy. After a three-year follow-up the patient has no symptoms of the tumor enlargement. This case shows that the irradiation therapy might be quite effective in the treatment of pleomorphic adenoma of epipharynx, but it is clear that much better results could be accomplished in combination with the surgery. In cases when the surgery is rejected or not possible because of the vicinity of the vital structures, we recommend the irradiation therapy as a therapy of the choice.

Key words: pleomorphic adenoma, epipharynx, irradiation, regression, CT

Introduction

Pleomorphic adenoma (PA) is the most common benign tumor of the major salivary glands, especially parotid gland, lacrimal glands, and adnexal glands of the skin. The occurrence of this neoplasm is rare in the epipharynx¹. The growth of pleomorphic adenoma of the epipharynx is generally not signalized by any symptoms for a long period of time. The recurrence of this tumor is generally late¹.

Here we report a case of a 67-year-old woman with pleomorphic adenoma of the epipharynx that despite its benignity recurred (without malignant transformation) and, moreover, responded quite well to irradiation therapy.

Case report

A 67-year-old woman had been suffering from the right side deafness, otitis and periodical epistaxes for

nine months when she was first admitted to hospital at the Department of Otorhinolaryngology. The tympanic membrane of the right ear was dragged in, muddy and without triangular reflex. The posterior rhinoscopy revealed that the right-sided deafness was caused by semi-rounded tumor mass 2 x 4 cm in diameter located on the right lateral wall of epipharynx towards the right hoana. CT scans of the epipharynx were performed, demonstrating a unilateral soft tissue mass in the right side of the epipharynx with diameters 4.3 x 2.9 x 3.0 cm. The mass extended from the skull base towards the *processus pterygoideus medialis* and towards the nasal septum partially obstructing the right hoana. The *musculi pterygoidei* were sharply delineated towards the tumor process. There were no signs of the skull base destruction. The tumor mass was well delineated from the surrounding structures suggesting its benignity. There were no palpable lymph nodes on the patient's neck, which was confirmed by ultrasound. Routine analysis

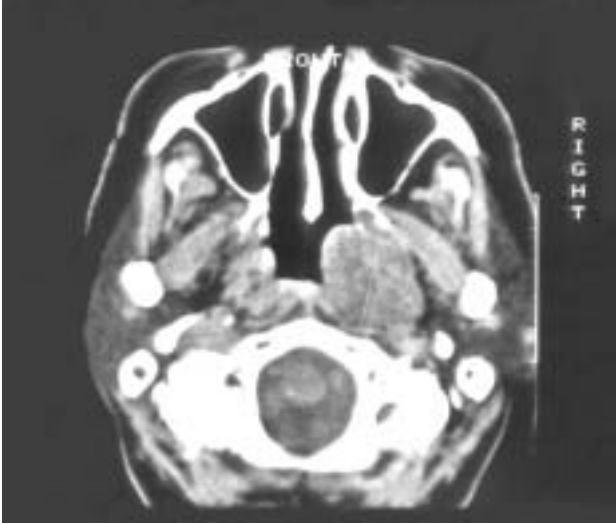


Fig. 1. CT of epipharynx performed three years after the diagnosis shows the tumor mass with diameters 4.8 x 3.4 x 4.0 cm.

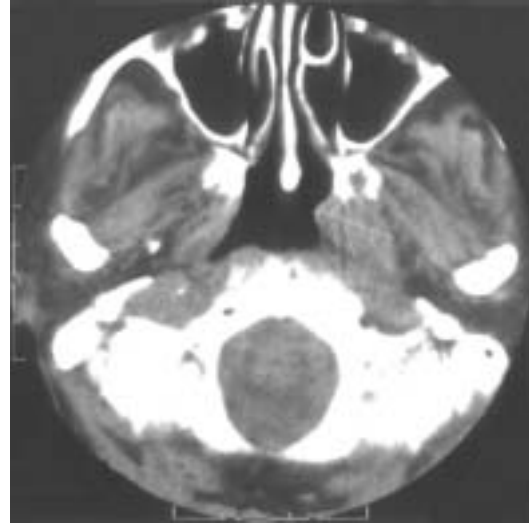


Fig. 2. CT of epipharynx performed after the irradiation therapy shows the tumor mass with diameters 3.0 x 1.8 x 1.9 cm and an obvious tumor regression.

showed increased erythrocyte sedimentation rate of 43 mm/h, hematocrites of 31% and suggested sideropenic anemia.

The biopsy was performed. Histology of the tumor mass revealed pleomorphic adenoma. The tumor was bounded with intact fibrous capsule and consisted of solid area of cuboidal cells, chondro-myxoid stroma and minor areas with tubuloductal structure.

We informed the patient of various therapeutic procedure possibilities: anterior or posterior rhinoscopy with flexible endoscope and tumor excision, lateral rhinotomy with surgical exeresis of tumor or irradiation therapy. The patient decided to refuse both the surgical and the irradiation therapy of the tumor, and accepted only miringotomy with the tube setting.

The patient was periodically examined because of the treatment of conductive partial deafness of the right ear (*myringotomia et implantatio tubuli ventilatorii*) and had only a few episodes of the epistaxes. She was admitted again three years later because of the pain at the right side of the head. CT revealed a tumor enlargement resulting in size of 4.8 x 3.4 x 4.0 cm (Figure 1). This time, the patient accepted the irradiation therapy, but still rejected the surgery. She underwent the cobalt therapy with direct and opposite fields with TD of 60 Gy. The control CT showed the obvious tumor regression with diameters of 3.0 x 1.8 x 1.9 cm (Figure 2). The patient felt better, and had no symptoms of the tumor enlargement. She was periodically examined. Five years later she was hospitalized again due to epistaxis, deafness and headache. The increase of the tumor size was observed by posterior rhinoscopy and confirmed by CT scans. The histological analyses revealed a pleomorphic adenoma again, without any signs of malignant transformation. The patient accepted the suggested re-irradiation therapy.

After a three year follow up, the patient feels well, except for the salivary glands dysfunction symptoms (xerostomia), caused by the irradiation therapy. She had no symptoms of the tumor enlargement.

Discussion

The pleomorphic adenoma of epipharynx is a rarely seen tumor whose growth shows no symptoms for a long period of time like it was in the case of our patient.

The recurrence of this tumor is generally late, with an average of 14.9 years¹, while our two recurrences occurred relatively early – after three and five years. Local recurrence rate varies between 1% and 50%, mostly because of incomplete removal², but it seems that the recurrence is most likely in patients who develop their primary tumor at an earlier age³, which was not the case with our 67-year-old patient.

Several factors strongly suggested the tumor benignity. The CT scans of the epipharynx showed that the tumor mass was well delineated from the nearby structures, showing no signs of their destruction. Histological analyses revealed that the tumor was bounded with intact fibrous capsule and consisted of masses or sheets of small cuboidal cells, exhibiting little tendency to form ducts in chondro-myxoid stroma.

Pleomorphic adenoma can show diverse lines of differentiation in the epithelial and myoepithelial elements and even develop a myoid differentiation, which can lead to the misinterpretation with rhabdomyosarcoma in differential diagnose⁴. The differential diagnosis towards adenoid cystic carcinoma and myoepithelial carcinoma can be difficult in particular with small biopsies. The distinction between benign and malignant mixed tumors is often difficult, but the histological features, that most reliably separate the two, include a tendency

for perivascular, perineural and capsular invasion as well as a significant cellular atypia and mitosis⁵. In our case there were no signs of malignancy. There were also no signs of malignant transformation in the recurrences.

Interestingly, a benign tumor showed quite a good regression to irradiation therapy, lowering all the three tumor diameters. There is no literature data about the efficacy of irradiation therapy in the pleomorphic adenoma treatment. Moreover, it is well known that benign tumors are much less sensitive to irradiation than malignant tumors.

This case shows that, despite its benignity, the irradiation therapy might be quite effective in the treatment of pleomorphic adenoma of epipharynx, but not just as a monotherapy. It is clear that much better results could be accomplished in combination with the surgery. But in cases when the surgery is rejected or not possible because of the vicinity of the vital structures, we recommend the irradiation therapy as a therapy of the choice.

REFERENCES

1. YASUMOTO, M., K. SUNABA, H. SHIBUYA, T. KURABAYASHI, *Neuroradiology*, 41 (1999) 300. — 2. NATVIG, K., R. SOBERG, *Head Neck*, 16 (1994) 213. — 3. SHAABAN, H., J. BRUCE, P. J. DAVENPORT,

Br. J. Plastic. Surg., 54 (2001) 245. — 4. LAM, P. W., J. K. CHAN, V. C. SIN, *Human Pathology*, 28 (1997) 1299. — 5. LIVOLSI, V. A., K. H. PERZIN, *Cancer*, 39 (1977) 2209.

G. Zamolo

*Department of Pathology, Faculty of Medicine, University of Rijeka, B. Branchetta 20, 51000 Rijeka, Croatia
e-mail: gordanazamolo@yahoo.com*

REKURENTNI PLEOMORFNI ADENOM EPIFARINKSA NAKON TERAPIJE ZRAČENJEM

SAŽETAK

Prikazujemo slučaj 67-godišnje pacijentice s pleomorfnim adenomom epifarinksa s intaktnom fibroznom kapsulom, koji je, iako benignan, rekurirao, ali i dobro odgovorio na terapiju zračenjem. Pacijentica je u početku odbila terapiju. Nakon tri godine, kada je CT pokazao povećanje tumorske mase, pacijentica je pristala samo na terapiju zračenjem, koja je dovela do značajnog smanjenja veličine tumora. Tumor se ponovno pojavio nakon pet godina, ali bez maligne alteracije. Pacijentica je i dalje odbijala kirurški zahvat, ali je pristala na ponovno zračenje. Nakon trogodišnjeg praćenja, pacijentica nije pokazivala znakove povećanja tumora. Ovaj slučaj pokazuje da iradijacijska terapija može biti znatno učinkovita u liječenju pleomorfnog adenoma epifarinksa, ali je sasvim jasno da terapija zračenjem u kombinaciji s kirurškim zahvatom ostvaruje puno bolje rezultate. U slučajevima kad operacijski zahvat bude odbijen ili on nije moguć zbog blizine vitalnih struktura, preporučamo iradijacijsku terapiju, kao terapiju izbora.