

Coll. Antropol. 28 (2004) 1: 447–453
UCD 616.516:616.311-076
Original scientific paper

Tissue Expression of Proliferative Antigens (*PCNA* and *Ki-67*) in Oral Lichen Ruber Related to Clinical Status

Ahmed Pirkić¹, Dolores Biočina-Lukenda², Ana Cekić-Arambašin²,
Dino Buković³, Mario Habek⁴ and Iva Hojsak⁴

¹ Department of Clinical Pathology »Ljudevit Jurak«, University Hospital
»Sestre milosrdnice«, Zagreb, Croatia

² Department of Oral Medicine, School of Dental Medicine, University of Zagreb, Croatia

³ Department of Prosthodontics, School of Dental Medicine, University of Zagreb, Croatia

⁴ Department of Gynecologic Oncology, University Hospital Center »Zagreb«, Zagreb, Croatia

ABSTRACT

The aim of this study was to determine the expression intensity of PCNA and Ki-67 tissue antigens related to pathologically modified oral mucosa in OLR lesions, and to determine the reaction intensity of these antigens in individual clinical forms, i.e. lichen ruber planus (LRP) and lichen ruber erosivus (LRE) comparing the reaction intensity with the inflammation grade and the degree of hyperkeratosis in lesions of 30 patients. Control group included patients (n = 15) with oral leukoplakia simplex. Tissue antigens were observed by immunohistochemical analysis using APAAP and LSAB methods. The reaction on tested tissue antigens was focal positive and of mosaic type. The reaction of the PCNA antigen was intensely high in OLR lesions regardless on the clinical form of the lesion. The reaction intensity positively correlated with the inflammation grade and the degree of hyperkeratosis in lesions. The reaction on Ki-67 tissue antigen ranged from low to moderately high intensity. Intensely high reaction was observed in lesions of lichen ruber erosivus. The reaction positively correlated with the inflammation grade and the degree of hyperkeratosis in lesions. Observed modified reaction of analyzed tissue antigens related with individual clinical forms of OLR might be the indicator of transformed nature of these lesions.

Key words: oral lichen ruber planus, proliferating cell nuclear antigens, PCNA, Ki-67, immunohistochemistry

Introduction

Intensified expression of proliferative antigens PCNA and Ki-67 can be found in numerous malignant and premalignant lesions like head and neck carcinoma^{1–8}. Oral dysplastic lesions with the increase of cell atypism correlate with increased proliferating activity and aneuploidy in basal layer cells⁹. Intensified cells proliferation marked with PCNA and Ki-67 tissue antigens were observed in lesions with chronic inflammation¹⁰.

The intensity of reaction on tissue antigen was stronger with the higher grade of dysplastic changes in those lesions¹¹.

Assuming that oral lichen ruber is precancerous lesion, potential malignant transformation of cells in pathologically changed oral epithelium and increased malignant potential of lesions especially in erosive and atrophic forms of OLR, we determined the aim of the study depending on various clinical forms of OLR and clinical intensity of inflammation and hyperkeratosis of oral mucosa.

Materials and Methods

Subjects

This study included 30 patients with oral lichen ruber, 15 patients with clinical manifestations of lichen ruber planus (LRP) and 15 patients with clinical manifestations of lichen ruber erosivus (LRE). Control group included 15 patients diagnosed with homogenous oral leukoplakia (OL).

The investigation included clinical diagnosis and determination of clinical OLR forms and clinical diagnosis of OL^{12,13}.

Clinical status of OLR and OL was evaluated with clinical parameters of the disease, inflammation, hyperkeratosis, lesion volume (erosions, bullae) and graded 0, 1, 2 and 3¹⁴.

The diagnosis of oral lichen ruber and oral leukoplakia determined on a basis of described clinical oral tests and parameters was confirmed in all patients by pathohistologic diagnosis^{12,15}.

Biopsy samples

Biopsy samples were collected from the pathologically transformed oral mucosa, on the border between healthy and diseased tissue, after the administration of 1 ml of local anesthetic solution (3% Mepivastein, ESPE, Germany).

All patients with OLR and OL were not subjected to adequate systemic or local therapy before the biopsy sampling.

Immunohistochemical analysis of biopsy samples

Tissue samples were fixated in buffered 4% paraformaldehyde for 24 h, embedded in paraffin and sectioned with cryomicrotome to 4 nm thick slices. After deparaffination and rehydration, tissue slices were routinely processed and stained with hematoxylin-eosin and mounted on a slide with Canada balsam.

For the purpose of immunohistochemical analysis antigen demasking was performed by heating tissues sections in a microwave oven (MOULINEX) 3x5' at 800 W in citric acid buffer (pH 6.0). Then the sections were irrigated several times in TRIS buffer (pH 7.6) and processed with APAAP method (Alkaline Phosphatase-Anti-Alkaline Phosphatase Complex) by incubation with BCIP/NBT (Alkaline Phosphatase chromogen kit) (DAKO) substrate for 1 hour at the room temperature. The tests were performed on mouse monoclonal antibody anti-PCNA (DAKO) in optimal solution of 1:100 and on mouse monoclonal antibody anti-Ki-67 (DAKO) in optimal solution of 1:50. The reaction product was either blue (APAAP) or brown (LSAB) nuclear precipitate depending on the method used.

The intensity of immunohistochemical reaction of tissue antigens *PCNA* and *Ki-67* expression in samples was evaluated semi quantitatively and marked as a reaction of negative intensity (–), low positive intensity (+), moderate positive intensity (++) and high positive intensity (+++).

Statistical data processing

The results were statistically analyzed using nonparametric χ^2 test and the Spearman rank correlation method. The results were considered statistically important if the level of importance was 5% or lower ($p < 0.05$). Statistical program STATISTICA for Windows, Release 5.5 H ('99 Edition) was used during the analysis of the results.

Results

Obtained values of expression intensity of *PCNA* antigen, i.e. the proportion of individual grades of tissue expression intensity of this antigen is shown in Figure 1.

Statistically higher expression intensity reaction of that antigen was observed when compared with the intensity of its

expression in OL samples ($\chi^2 = 16.4007$; $p = 0.0003$).

Immunohistochemical analysis of biopsy samples of OLR revealed moderately high to high expression intensity (++) of *PCNA* tissue antigen. Diffuse and continuous reaction was observed in parabasal and basal layer cells of epithelium, and spinous cells layer showed mostly focal positive reaction. The reaction was intense in lymphatic infiltrate of lamina propria and highly intense in stromal macrophages (Figure 2).

Immunohistochemical analysis of biopsy samples of OL lesions showed negative to moderately high expression intensity (–/++) in basal layer of epithelium and in lymphatic infiltrate of lamina propria (Figure 3).

Expression intensity of *PCNA* antigen was equal in biopsy samples of various clinical forms of LRE and LRP ($\chi^2 = 3.33$; $p = 0.0679$).

Positive correlation between the inflammation grade of lesions and the expression intensity of tissue antigen *PCNA* ($\sigma = 0.880$; $p < 0.001$) was demonstrated.

Positive correlation between the hyperkeratosis of lesions and the expression intensity of tissue antigen *PCNA* ($\sigma = 0.404$; $p < 0.006$) was demonstrated.

Statistically higher expression intensity of *Ki-67* antigen was observed when compared with the intensity of its expression in OL samples ($\chi^2 = 21.4696$; $p < 0.00001$).

Immunohistochemical analysis of *Ki-67* antigen tissue expression in biopsy samples of OLR lesions revealed the reaction ranging from low to moderately high intensity (+/++). Discontinued mosaic-type reaction in basal layer cells of epithelium was observed which was negative in other epithelium layers (Figure 4). The reaction was positive in lamina propria with diffusely thick lymphoid infiltrate.

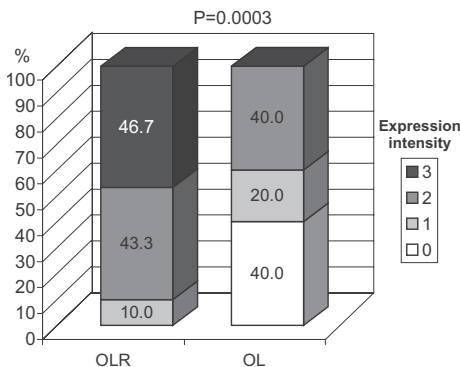


Fig. 1. The proportions of expression intensity of *PCNA* tissue antigen in oral lichen ruber lesions (OLR; N=30) and in oral leukoplakia lesions (OL; N = 15).

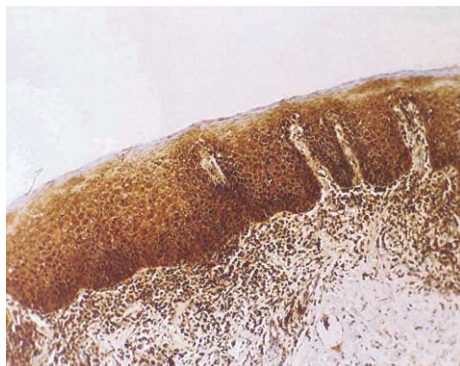

Fig. 2. Oral lichen ruber (OLR). Positive immunohistochemical reaction of the PCNA antigen in oral epithelium. High intensity reaction in lamina propria (LSAB $\times 200$).

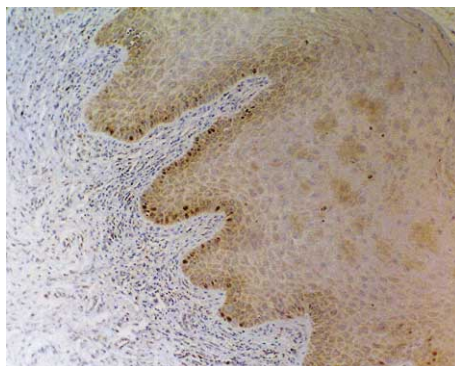


Fig. 4. Oral lichen ruber (OLR). Positive immunohistochemical reaction of the Ki-67 antigen in individual basal layer cells of oral epithelium (LSAB $\times 100$).

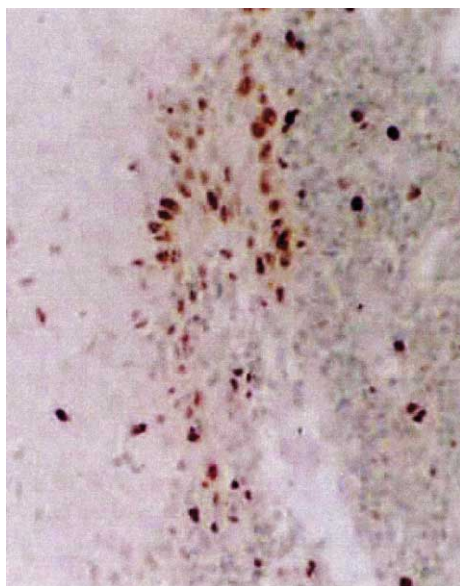


Fig. 3. Oral leukoplakia (OL). Focal positive immunohistochemical reaction of the PCNA antigen in basal layer cells of oral epithelium and in lymphoid infiltrate of lamina propria (LSAB $\times 200$).

Immunohistochemical analysis of the *Ki-67* antigen expression in OL biopsy samples revealed negative to moderately

high intensity reaction ($-/+$) specifically in lymphoid infiltrate of lamina propria but only focal in basal layer of the epithelium.

LRE samples had statistically higher expression intensity of *Ki-67* antigen when compared with its expression intensity in LRP samples ($\chi^2 = 6.53$; $p = 0.0106$).

Inflammation intensity in OLR and OL lesions was positively correlated with the expression intensity of *Ki-67* tissue antigen ($\sigma = 0.879$; $p < 0.001$).

The comparison between expression intensity of *Ki-67* tissue antigen and the intensity of hyperkeratosis in OLR and OL lesions is shown in Table 1 and in Table 2.

Hyperkeratosis intensity in OLR and OL lesions was positively correlated with the expression intensity of *Ki-67* tissue antigen ($\sigma = 0.303$; $p < 0.043$).

Discussion

Proliferative activity of cells might not be exclusively induced by the damaged genes but also by the array of immunological events crucial in pathogenetic mechanism of OLR. The risk from mali-

TABLE 1
PROPORTIONS OF EXPRESSION INTENSITY OF TISSUE ANTIGEN KI-67 IN RELATION TO THE DEGREE OF HYPERKERATOSIS IN ORAL LICHEN RUBER LESIONS (OLR; N = 30)

Expression intensity of <i>Ki-67</i> antigen	Degree of hyperkeratosis in OLR lesions % (N)			
	0	1	2	3
+	0	13.3 (4)	33.3 (10)	3.3 (1)
++	0	0	20.0 (6)	26.7 (8)
+++	0	0	0	3.3 (1)

+ = low positive; ++ = moderate positive; +++ = high positive

TABLE 2
PROPORTIONS OF EXPRESSION INTENSITY OF KI-67 TISSUE ANTIGEN IN RELATION TO THE DEGREE OF HYPERKERATOSIS IN ORAL LEUKOPLAKIA LESIONS (OL; N = 15)

Expression intensity of <i>Ki-67</i> antigen	Degree of hyperkeratosis in OL lesions % (N)			
	0	1	2	3
∅	0	0	40.0 (6)	13.3 (2)
+	0	0	0	40.0 (6)
++	0	0	0	3.3 (1)

∅ = negative; + = low positive; ++ = moderate positive; +++ = high positive

gnant transformation of those lesions is not too high if the activity of genes and genetic products, which oversee cell cycle, is normal and if the cellular response to stimulating signal paths is not damaged. It is important to know the kinetic of premalignant and malignant lesions of oral lichen ruber for better understanding of their nature.

In our study tissue expression of *PCNA* antigen in OLR lesions showed moderately high to high reaction on that antigen. Intensely high intensity was observed in OLR lesions. Positive correlation between the expression intensity of *PCNA* antigen and the inflammation grade as well as the degree of hyperkeratosis in OLR and OL lesions was demonstrated.

Tissue expression of *Ki-67* antigen in OLR lesions reveals low to moderately high reaction on that antigen. Relevantly high intensity was observed in OLR lesions. Moreover, intensely high expres-

sion intensity of *Ki-67* antigen in lesions of lichen erosivus when compared with the expression intensity in lichen planus was demonstrated. This was the expected result because of demonstrated positive correlation between the expression intensity of *Ki-67* antigen and the inflammation grade intensity, and because of the higher inflammation intensity in erosive lichen form than in lichen planus. Positive correlation between the expression intensity of *Ki-67* antigen and the intensity of hyperkeratosis in OLR and OL lesions was confirmed. It was noted that higher expression intensity of that antigen correlates with the degree of clinical parameters of OLR and OL lesions.

Intranuclear reaction on *PCNA* and *Ki-67* antigens was described. Reaction on *PCNA* antigen was continuous and localized mostly in basal and spinous layer cells, and the reaction on *Ki-67* antigen was discontinuous and focal in basal lay-

er cells and lamina propria. Those results correlate with the results of studies performed by other authors^{7,8}.

Expression of *PCNA* and *Ki-67* antigen in suprabasal and basal layer is considered a marker of the dysplasia in oral epithelium referring to the proliferate status of the lesion^{10,11}.

Determination of proliferative activity through the application of specific antibodies has certain »biomarker« value whose expression intensity in lesion is proportional with the degree of dysplasia. The number of positive cells in OLR lesions with the accent on accelerated proliferation of basal layer cells was interesting. The increase of proliferation activity in oral lichen lesions combined with the result of degenerative changes in basal membrane may be induced by local mononuclear lymphocyte infiltrate¹.

Since the prognostic factors of OLR lesions were not completely investigated, new perceptions about the kinetics and the nature of those lesion cells point to conclusion that determination of cell parameters, like DNA status, proliferation degree and the presence of growth factor receptors, may be helpful when assessing the potential malignant transformation of those lesions as well as when assessing their invasiveness.

Conclusion

Cell proliferation markers for *PCNA* and *Ki-67* antigens are indicators of cells proliferation, which may be induced not only by the array of genetic errors but

also by local immunological events, as observed in OLR lesions too. Modified expression of tissue antigens *PCNA* and *Ki-67* in OLR lesions was observed, where continuous reaction in parabasal and basal layer of the epithelium and focal positive reaction in spinous layer point to certain activity of those lesions. Intensely higher reaction intensity on *Ki-67* antigen in LRE lesions compared with the intensity of this antigen in LRP lesions with the positive correlation with the inflammation grade confirms the existence of certain malignant potential in erosive lesions of oral lichen.

However, since the prognostic factors of OLR lesions were not completely investigated, new perceptions about the kinetics and the nature of those lesion cells point to conclusion that determination of cellular parameters, like DNA status, proliferation degree and the presence of growth factor receptors, may be helpful when assessing the potential malignant transformation of those lesions as well as when assessing their invasiveness. The studies dealing with the role of proliferating cell nucleus antigens *PCNA* and *Ki-67* in diagnostic and prognostic purposes in oral lichen lesions are still inadequate. That reveals the necessity to standardize the methods used in determination of proliferation activity of those lesions. Daily clinical practice should include the assessment of the importance of those proliferation markers with respect to the clinical results of OLR and with respect to the course, prognosis and the treatment of the disease.

REFERENCES

1. GIROD, S. C., P. PFEIFFER, H.-D. PAPE, Br. J. Oral Maxillofac. Surg., 36 (1998) 252. — 2. LOERZ, M., E. MEYER-BREITING, R. BETTINGER, Eur. Arch. Otorhinolaryngol., 251 (1994) 91. — 3. GIROD, S. C., H.-D. PAPE, G. R. F. KRUGER, Eur. J. B. Oral Oncol., 30 (1994) 419. — 4. TSAI, T. S., Y. T. YIN, J.

Oral Pathol. Med., 24 (1995) 313. — 5. KRECICKI, T., M. JELEN, J. Laryngol. Otol., 112 (1998) 310. — 6. MORAWSKI, K., A. GABRIEL, G. MAMYSŁOWSKI, A. ZIOLKOWSKI, V. PIETRAWSKA, K. STEPLEWSKA, Eur. Arch. Otorhinolaryngol., 256 (1998) 378. — 7. TAKAHASHI, M., T. ADACHI, R. MATSUI, N. MI-

- YAKAWA, Eur. Arch. Otorhynolaryngol., 255 (1998) 311. — 8. STROEKEL, S., T. REICHERT, K. A. REIF-FEN, W. WAGNER, Eur. J. Cancer B Oral Oncol., 29B (1993) 273. — 9. STEINBECK, R. G., J. MOEGE, K. M. HESELMAYER, W. KLEBE, W. NEUGEBAUER, B. BORG, G. U. AUER, Eur. J. Cancer B Oral Oncol., 29B (1993) 279. — 10. MRAVAK-STIPETIĆ, M., A. PIRKIĆ, I. VIDAS, Coll. Antropol., 22 Suppl. (1998) 103. — 11. OGNJENOVIC, M., D. KARELOVIC, V. V. CINDRO, I. TADIN, Coll. Antropol., 22 Suppl. (1998) 89. — 12. WHO, Oral Surg. Oral Med. Oral Pathol., 46 (1978) 213. — 13. ANDREASEN, J. O., Oral Surg. Oral Med. Oral Pathol., 25 (1968) 31. — 14. DOBRENIĆ, M. (JUMENA, Zagreb, 1987). — 15. ANDREASEN, J. O., Oral Surg. Oral Med. Oral Pathol., 25 (1968) 158.

A. Pirkić

Department of Clinical Pathology »Ljudevit Jurak«, University Hospital
»Sestre milosrdnice«, Vinogradska c. 29, 10000 Zagreb, Croatia

TKIVNA EKSPRESIJA PROLIFERATIVNIH ANTIGENA (PCNA I KI-67) KOD ORALNOG LICHEN RUBERA U ODNOSU NA KLINIČKI STATUS

S A Ž E T A K

Cilj ove studije bio je odrediti intenzitet ekspresije tkivnih antigena *PCNA* i *Ki-67* u odnosu na patološki promijenjenu oralnu sluznicu u OLR lezijama te utvrditi intenzitet reakcije ovih antigena u pojedinim kliničkim formama tj. u lichen ruber planus (LRP) i erozivnom lichen ruberu (LRE) usporedbom intenziteta reakcije sa stupnjem upale i stupnjem hiperkeratoze u lezijama 30 bolesnika. Kontrolna skupina uključila je bolesnike ($n = 15$) s oralnom leukoplakijom (simplex). Antigeni tkiva testirani su imunohistokemijskom analizom korištenjem APAAP i LSAB metoda. Reakcija na testirane tkivne antigene bila je fokalno pozitivna i mozaičkog tipa. Reakcija PCNA antigena bila je intenzivno visoka u OLR lezijama bez obzira na kliničku formu lezija. Intenzitet reakcije bio je pozitivno koreliran sa stupnjem upalnih promjena i sa stupnjem hiperkeratoze u lezijama. Reakcija *Ki-67* tkivnog antigena kretala se u rasponu od niskog do umjereno visokog intenziteta. Izrazito intenzivna reakcija primijećena je u lezijama erozivnog lichen rubera. Reakcija je bila pozitivno korelirana sa stupnjem upale i stupnjem hiperkeratoze u lezijama. Povezanost zamijećenih modifikacija reakcije analiziranih tkivnih antigena i pojedinih kliničkih formama OLR mogući je indikator promijenjene prirode ovih lezija.