

Intact Radial and Median Nerve after Open Third Degree Distal Fracture of the Humerus

Borislav Has¹, Slavica Kvolik², Jozo Kristek¹ and Dubravko Habek³

¹ Department of Surgery, University Hospital Osijek, Osijek, Croatia

² Department of Anesthesiology and ICU, University Hospital Osijek, Osijek, Croatia

³ Department of Gynecology, University Hospital Osijek, Osijek, Croatia.

ABSTRACT

A 54 year old man sustained a third degree open fracture at the distal part of the right humerus with massive soft tissue defect involving most of the upper arm. The radial and median nerves were completely bared and exposed by 6 cm for radial and 3 cm for median nerve. The nerves were in continuity, but there was complete rupture of surrounding muscles: biceps, triceps and brachialis. The fracture was stabilized by external fixation method – reinforced by wires. Preoperative and postoperative sensorimotor status of the right hand was good. One year later sensory and motoric status of right hand showed no deficiencies, but flexion and extension in elbow were limited to 100 and 180 degrees respectively. Pronosupination was restricted. This case report is consistent with results of biomechanical studies *in vitro* confirming high tolerance of radial and median nerve to stretching injury.

Key words: radial nerve, median nerve, humerus, open and closed fractures, biomechanics

Introduction

Fractures of the third part of distal humerus (open or closed) are often accompanied with contusion and rupture of the radial nerve^{1–3}. The median and other nerves are less susceptible^{4,5}. The reasons for radial nerve vulnerability are: close relationship with the humerus in the lower part of the spiral groove and limited mobility of the nerve where it pierces the lateral intermuscular septum^{6,7}. An internal fixation of unstable humerus fractures performed with careful exploration of radial and median nerve may cause at least transitory nerve palsy^{8,9}. The radial nerve lesion may also result after closed humerus fracture reposition.

A surgical treatment of second and third degree of unstable open humerus fractures using external fixation method demands careful wound exploration and surgeon's familiarity with the course of the radial nerve. A careful manipulation is necessary to preserve radial and median nerve continuity and function.

The aim of this report is to describe one patient who had a third degree open fracture of humerus with exposed radial and median nerves. Those nerves suffered traction or contusion injury while surrounding muscles

were completely disrupted. However, the patient showed a clinically good neurovascular status of right hand before and after surgical repair of the injury. Biomechanical properties of muscle, bone and nerve tissues could explain this unusual outcome of injury.

Case Report

A 54-year old man who sustained an open fracture of the third degree at the lower part of humerus (Figure 1) was admitted in emergency unit 20 min after injury. An accident happened when a paint mixer caught his limb and made a deep laceration, almost a semi-amputation of his upper arm. An extensive, circumferential laceration involved the greatest part of circumference at the lower third of the upper arm. An initial rough neurovascular examination showed no sensomotor deficiency of hand. After standard radiograms were taken, preoperative assessment of the fracture and nerve inspection was performed. Complete muscle disruption of the brachialis, biceps and triceps brachii, located at the distal third of upper arm, could be noticed. In the wound there were ra-

dial and median nerve clearly visible, both having preserved continuity and visible for 6 cm for the radial and 3 cm for the median nerve (Figure 1b). The pulsation of brachial artery was palpable near these structures. Peripherally obtained capillary refill was 2–3 seconds. A pulse wave was registered on the right hand fingers by pulse oximeter (monitor PM 8060 Vitara, Draeger, Lü-

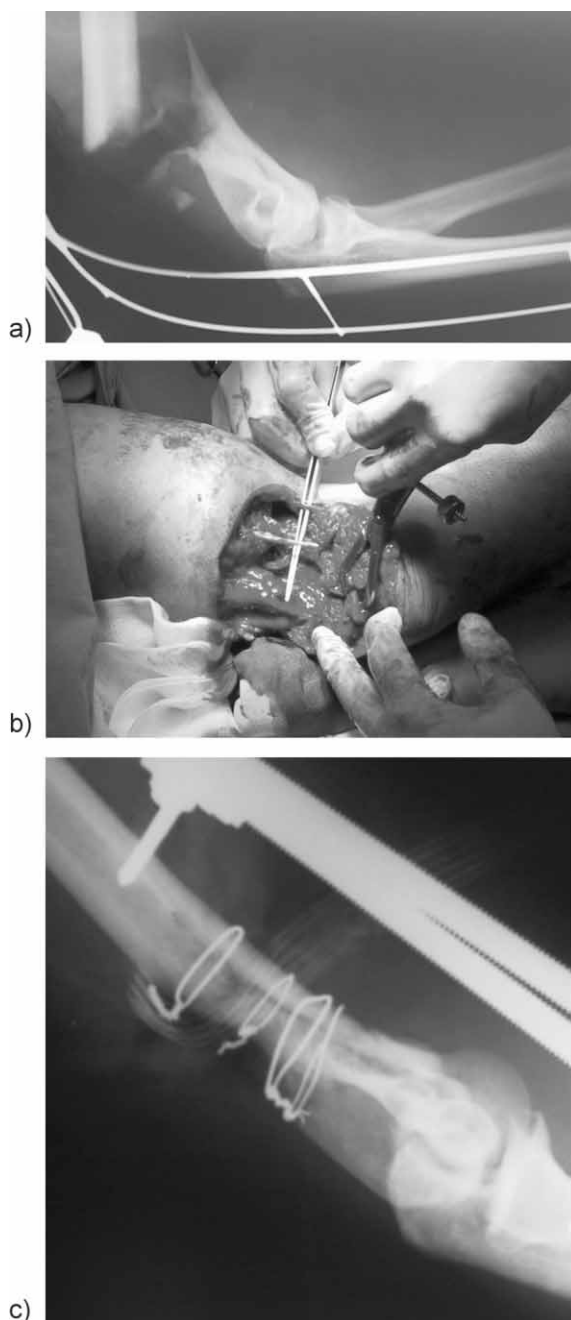


Fig. 1. Open humerus fracture of third degree and bared radial and median nerve after external fixation and wire reinforcement: a) An open comminuted fracture of third degree at lower third of the humerus, b) Bared radial and median nerves in open fracture wound, c) The stabilization of humerus fracture with external fixation method and cerclage.

beck, Germany). It showed high amplitude of pulsations and hemoglobin saturation by 98%. Antibiotic regimen of cefazolin and gentamycin was immediately instituted and continued for 10 days.

The wound was carefully cleaned in the operating theatre. After the primary surgical treatment of soft tissues, a stabilization of the open third degree comminuted fracture was performed. The stabilization of the broken humerus fragments was achieved with external fixation method (»Zagreb 1« type of fixator, Figure 2a and b)^{10,11}. Circular wires were used for further reposition of minor bone fragments (Figure 1c), although Kirschner wires are usually added to the external fixation method in Clinical hospital Osijek^{11,12}.

After humerus stabilization, the surgery was directed toward simple suture repair of disrupted muscles, using end-to-end technique. Slight muscle tension remained after repair. The wound was closed by spaced skin sutures and dressed with local antiseptic (povidone iodine).

Clinical examination during the postoperative period showed no neurologic deficiencies. Mild swelling due to extensive trauma to venous circulation of this area was observed distally of the wound, at the elbow and forearm (Figure 2a). Three weeks after the injury, the posttraumatic edema resolved.

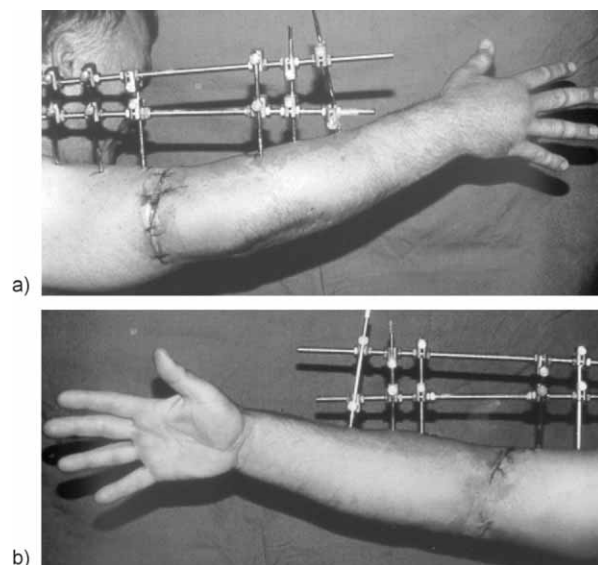


Fig. 2. Semi amputation of distal third of right upper arm after surgical repair. Clinically good neurovascular status of the right hand in the postoperative period from: a) The lateral aspect, b) The medial aspect.

Gentle active motion exercises of the hand were encouraged by the physical therapist to minimize the loss of muscular strength and withhold the progression of muscle atrophy in the forearm. The limb was immobilized for a period of eight weeks, when an acceptable level of bone and muscle healing was achieved to allow the removal of the external fixator. Cerclage wires were not removed

due to high probability of secondary nerve lesion. More vigorous exercises were initiated. Stronger flexion-extension motions of the arm, forearm, rotation as well as exercises to restore muscular strength were instituted.

Postoperative clinical measurements, including elbow flexion, extension, pronation, supination as well as wrist flexion, extension, radial and ulnar deviation, were performed at a year after injury. Full extension in the elbow was achieved, whereas flexion was limited to 100°. Pronation and supination were limited and painful, so non-opioid analgesics were given to enable further exercises. Radial and ulnar deviations were not altered. No sensory deficiencies were observed one year after injury.

Discussion

We presented the case of a patient who has suffered an open upper arm fracture of third degree with radial and median nerves bared and clearly visible for 6 and 3 cm respectively. There were no clinical signs of radial and median nerve lesion. It is unusual in such injury with completely disrupted biceps, brachialis, and triceps and open humerus fracture that both, radial and median nerve remained intact.

Some properties of nerves and surrounding tissues involved in this injury were important for understanding of the biomechanical principles involved in this traumatic event. In vitro systems, neurons express a remarkably high tolerance to dynamic stress injury. In one study it has been found that certain portions of the axons were 60% longer immediately after injury¹³. Axons returned to their original length within the first 5 minutes after injury, showing signs of swelling similar to that found in brain injury¹⁴. Nerve branching is another parameter of importance. For instance, stretching the median nerve proximally from the elbow causes less tension than stretching median nerve distal from the elbow, because of many branches¹⁵. Nerve mobility depends also on the surrounding tissues, and is of great importance. If the paraneurium became fibrotic and form adhesions like those in rheumatoid arthritis or posttraumatic conditions, nerve mobility may decrease¹⁶. Besides fibrotic processes, the joint position also influences nerve tension and mobility. A shoulder in 90° abduction, dorsiflexion of the hand with extended elbow resulted in increased tension in both distal and proximal parts of the median nerve in the cadaver study. In this position the median nerve elongates by 4.5%. With the shoulder in abduction and flexion in the elbow an increased tension was measured only in the distal part of the nerve, and was diminished when the hand was in flexion. During maximal flexion of the elbow, the median nerve has to shorten by 15%, narrowing along its course¹⁵. Elasticity of the muscles decreases during contraction and its capability to absorb and transduce energy from external destructive forces arises. The force exerted on the tendon of a muscle is equal to the sum of the external, passive and elastic forces¹⁷.

A simple schematic illustration of forces involved in the described patient is shown in Figure 3. Upper arm muscles were contracted, and the hand was in flexed position carrying a load. An external rotatory force of great strength and low velocity acted to distal third of humerus. The humerus and muscles were insufficient to counteract to external force, so muscles have disrupted and the humerus fractured. Since the elbow position did not cause stretching to the nerves, no adhesions were present and velocity of blunt rotating object was low, conditions for preserving nerve continuity were achieved.

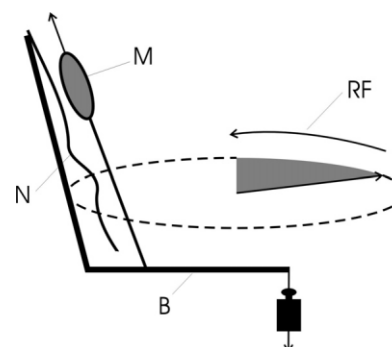


Fig. 3. A schematic diagram of forces acting at the moment of traumatic event. M – muscle, B – bone, R – rotatory force, N – nerve.

In our patient, surgery of an extensive muscle defect repair was needed, both for preserving hand function and to promote a callus formation. A precise 'low friction' suture technique was inappropriate in this case due to character of the wound (open bone fracture with high possibility of infection and non-union). The simple suture repair performed for muscle reconstruction offers minimal additional trauma to the tissue, decreases possibility of infection, but does not offer ideal postoperative function. Therefore, a limited flexion, pronation and supination persisted after complete biceps, brachialis and triceps disruption followed by extensive adhesions.

Most of veins, located predominantly at medial anterior aspect of upper arm, were also disrupted. Owing to the abundant microcirculation surrounding the elbow, a posttraumatic swelling caused by trauma and vascular damage resolved so that the venous return was preserved.

Nerve lesions are common in humerus shaft fractures, appearing as primary, traumatic and secondary, resulting from reposition maneuvers, intraoperative damage or late adhesion formation^{1–6}. In the described case nerve damage was avoided by precise and careful manipulation during operative bone reconstruction nearby vulnerable nerves. An external fixation technique is widespread used for open humerus shaft fractures treatment. Additional stabilization of minor bone fragments was achieved by wire reinforcement. A normal humerus length was maintained and bone mass reduction minimized (Figure 1c).

We conclude that outcome of this brutal injury was appropriate to the tissue lesion localization and severity. An assembly of biomechanical tissue properties was achieved so that nerve continuity and function were pre-

served. A choice of an appropriate operative treatment and meticulous work contributed to good outcome of this severe injury.

REFERENCES

- FOSTER, R. J., M. F. SWIONTKOWSKY, A. W. BACH, J. T. SACK, J. Hand. Surg.-Am., 18 (1993) 121. — 2. HEE, H. T., B. Y. LOW, H. F. SEE, Ann. Acad. Med., Singap., 27 (1998) 772. — 3. SHAH, J. J., N. A. BHATTI, Clin. Orthop., 172 (1983) 171. — 4. ASPERGIS, E., D. AKTIPIS, A. GIOTA, G. KASTANIS, G. NTEIMENTES, A. PAPANICOLAOU, J. Trauma, 45 (1998) 825. — 5. BROWN, I. C., D. M. ZINAR, J. Paediatr. Northup., 15 (1995) 440. — 6. LINEMAN, L., J. Bone. Joint Surg., 48 (1966) 105. — 7. SUNDERLAND, S., Nerves and Nerve Injuries, (Churchill Livingstone, Edinburgh 1978). — 8. SAMARĐIĆ, M., D. GRUJIĆIĆ, Z. B. MILINKOVIĆ, Injury, 21 (1990) 220. — 9. BURČAK, R., J. Orthop. Trauma, 8 (1994) 252. — 10. JANOŠI, K., Z. LOVRIĆ, Croat. Med. J., 36 (1995) 104. — 11. HAS, B., S. JOVANOVIĆ, B. WERTHEIMER, I. MIKOLAŠEVIĆ, P. GRDIĆ, Injury, 26 (1995) 245. — 12. HAS, B., S. JOVANOVIĆ, B. WERTHEIMER, G. KONDŽA, P. GRDIĆ, K. LEKO, Croat. Med. J., 42 (2001) 630. — 13. SMITH, D. H., J. A. WOLF, T. A. LUSARDI, T. A. LEE, D. F. MEANY, J. Neurosci., 19 (1999) 4263. — 14. MEANEY, D. F., D. H. SMITH, D. I. SHREIBER, A. C. BAIN, R. T. MILLER, D. T. ROSS, T. A. GENNARELLI, J. Neurotrauma, 12 (1995) 689. — 15. KLEINRENSINK, G. J., R. STOECKART, A. VLEEMING, C. J. SNIJDERS, P. G. MULDER, Clin. Biomech., 10 (1995) 240. — 16. MIYAMOTO, Y., S. WATARI, K. TSUGE, Plast. Reconstr. Surg., 63 (1979) 398. — 17. UCHIYAMA, E., K. K. YAMAKOSHI, T. SASAKI, J. Biomech. Eng. 120 (1998) 85.

B. Has

Department of Surgery, Clinical Hospital Osijek, J. Huttlara 4, 31000 Osijek, Croatia
e-mail: elschon@yahoo.com

NEOZLJEĐENI N. RADIALIS I N. ULNARIS U SLUČAJU OTVORENOG PRIJELOMA III. STUPNJA DONJEG OKRAJKA NADLAKTIČNE KOSTI

SAŽETAK

Muškarac star 54 godine zadobio je otvoreni prijelom III stupnja desne nadlaktice u području donjeg okrajka. Nervus radialis je bio ogoljen i vidljiv u dužini oko 6 centimetara, a nervus medianus u dužini oko 3 centimetra. Živci su imali sačuvani kontinuitet, ali su bili u cjelosti odvojeni od susjednih mišića. Prijelom kosti je stabiliziran metodom vanjske fiksacije, a dodatna stabilnost se postigla žičanim šavima. Preoperacijski i postoperacijski je ozljeđenik imao dobru neuromuskularnu funkciju okrajine ekstremiteta. Godinu dana nakon ozljede nismo primjetili neuromuskularne nedostatke desne šake. Pokreti savijanja u laktu su bili izvodivi do 100°, a ispružanja do 180°. Rotacijski pokreti u laktu su također bili znatno ograničeni. Prikaz ovog slučaja potvrđuje biomehaničke studije »in vitro« o visokoj toleranciji nervusa radialisa i medianusa pri ozljedi istežanjem.