

Relevant Sonographic Parameters of a Painful Shoulder in Symptomatic Dialyzed Patients versus Asymptomatic Dialyzed and Healthy Volunteers

Igor Barišić¹, Dragan Ljutić², Stipan Janković¹, Tonko Vlasković³, Snježana Tomić⁴, Slaven Kokić⁵ and Marinko Erceg⁶

¹ Department of Diagnostic and Interventional Radiology, University Hospital Split, Split, Croatia

² Department of Nephrology, University Hospital Split, Split, Croatia

³ Department of Physical Medicine, Rehabilitation and Rheumatology, University Hospital Split, Split, Croatia

⁴ Department of Pathology and Cytology, University Hospital Split, Split, Croatia

⁵ Clinical Department of Endocrinology, University Hospital Split, Split, Croatia

⁶ Department of Orthopedics, University Hospital Split, Split, Croatia

ABSTRACT

The aim of this study is to find dialysis relevant sonographic parameters of painful shoulder of the symptomatic dialyzed patients comparing them with parameters in asymptomatic dialyzed patients and healthy volunteers. Significant difference in all metric parameters (thickness of supraspinatus tendon, diameter of biceps tendon sheath and capsula-bone distance) were noticed between all groups and the symptomatic had the highest values. Asymptomatic had the higher values than volunteers. Inhomogeneity of the tendon and biceps tendon sheath effusion in the symptomatic patients were the most often occurred. Subdeltoid effusion, deposits and tendon rupture were found only in symptomatic patients. No difference in presence of calcifications between symptomatic and asymptomatic was found. Metric parameters are relevant and associated with dialysis, as well as biceps tendon effusion tendon inhomogeneity, deposits and subdeltoid effusion. Tendon ruptures are relatively rare and nonspecific.

Key words: sonographic parameters, painful shoulder, dialysis

Introduction

Chronic shoulder pain in chronic haemodialysis is associated with dialysis related arthropathy, bacterial arthritis, gout and pseudo gout¹.

The term of dialysis related arthropathy is commonly associated with accumulation of fibrils of β 2-microglobuline in bones and joints due to insufficient elimination during haemodialysis. In patients in terminal stadium of chronic renal failure is also occurred. The shoulder is predominantly involved^{1,2}.

Dialysis related arthropathy with stiffness and motion reduction in shoulders is associated with long term haemodialysis, over 10 years, but also patients with painful shoulder after short term dialysis and even asymptomatic patients may have some analogous morphologic joint changes^{1,3}.

Bone changes, like bone cysts and erosions were not considered, as very late sign of arthropathy.

Sonographic parameters relevant for painful shoulder are calcifications of the rotator cuff, especially supraspinatus tendon^{1,4-6}.

Thickness of spraspinatus tendon and biceps tendon are associated with dialysis related arthropathy^{1,7-10}.

The corrupted texture (inhomogeneity) of supraspinatus tendon are strongly associated with dialysis related arthropathy^{3,10}, but it can be found in the symptomatic shoulders in rheumatoid arthritis³.

The biceps tendon sheath effusion can be found in dialysis related arthropathy as a sign of inflammation^{1,7-11},

but it can be associated with impingement syndrome due to repetitive pressure^{12–14}.

The increased distance capsula-bone, as a sign of joint effusion and subdeltoid bursa effusion are signs associated with dialysis related, rheumatoid arthritis^{1,8–10} and sometimes in painful shoulder noninflammatory origin^{12,13,15}.

Partial and total ruptures are associated with painful shoulder noninflammatory origin, especially in patients with impingement syndrome^{3,13,14}, but it can be found in the long term dialyzed patients with corrupted texture of rotator cuff^{3,10}.

The aim of this study is to notice differences in morphologic parameters between patients with and without painful shoulder on chronic dialysis, and morphologic parameters in healthy volunteers. That would point out relevant sonographic parameters for painful shoulder in dialyzed patients and estimate morphologic parameters in dialyzed patients, especially asymptomatic, whether those parameters should be treated normal or not.

Materials and Methods

Patients and variables

Real time sonography of the shoulders with linear transducer of 10 MHz was performed in 54 patients receiving chronic haemodialysis as a treatment of terminal renal failure, 27 symptomatic with persistent pain and stiffness in both shoulders and lasting for more than 6 weeks and restriction of movements in various degree

and 27 asymptomatic. Each group of patients consisted of 17 males and 10 females, mean age 57.6 ± 14.8 in symptomatic and 51.9 ± 14.2 in asymptomatic. Group of 50 healthy volunteers consisted of 24 males and 26 females, mean age 53.2 ± 17.2 .

In 208 shoulders thickening of tendon of m. supraspinatus were examined. The thickness of supraspinatus was measured in both longitudinal and transversal view, in neutral position of the shoulder and in the adduction, hyperextension and internal rotation of the arm. The mean values between transversal and longitudinal view in both positions are calculated as follows:

1. Transverse view: superior of the head of humerus, just above the bicipital groove, taken mid-point between symmetrical lateral narrowing of the tendon.
2. Longitudinal view: measured at point where tendon emerges beneath acromial shadow.

Diameter of the biceps tendon sheet was measured in the level of the superior margin of the bicipital grow, in both transverse and longitudinal view.

Glenohumeral joint effusion (bone-capsule distance) was measured in transaxillar scan approaching the part of the humerus head not covered with rotator cuff.

Subdeltoid bursa effusion and biceps tendon sheet effusion were also noticed.

During examination texture of the tendons, especially inhomogeneity, hyperechoic amyloid deposits, small calcium deposits supraspinatus tendon ruptures were observed.

TABLE 1
NUMERIC SONOGRAPHIC PARAMETERS OF SHOULDER STRUCTURES IN SYMPTOMATIC AND ASYMPTOMATIC DIALYZED PATIENTS AND HEALTHY VOLUNTEERS

		Symptomatic N=27	Asymptomatic N=27	Volunteers N=50	p
Thickness of supraspinatus tendon (left, mm)	X±SD	7.97±1.07	7.28±0.74	6.4±0.38	<0.001
	Median	7.8	7.2	6.45	
	Min. – Max.	5.8 – 10.1	6.0 – 8.8	5.7 – 7.2	
Thickness of supraspinatus tendon (right, mm)	X±SD	7.68±1.07	6.92±0.68	6.54±0.38	<0.001
	Median	7.8	6.9	6.58	
	Min. – Max.	5.5 – 10.4	5.6 – 8.8	5.8 – 7.3	
Diameter of biceps tendon sheet (left, mm)	X±SD	6.37±1.11	5.19±1.12	4.2±0.3	<0.001
	Median	6.51	4.8	4.2	
	Min. – Max.	4.3 – 8.7	3.6 – 7.9	3.6 – 4.7	
Diameter of biceps tendon sheet (right, mm)	X±SD	6.28±1.35	5.18±1.02	4.22±0.27	<0.001
	Median	6.35	4.95	4.2	
	Min. – Max.	4.3 – 9.6	3.4 – 7.2	3.7 – 4.7	
Capsule-bone distance (left, mm)	X±SD	3.96±0.92	2.75±0.52	2.12±0.23	<0.001
	Median	4.2	2.6	2.1	
	Min. – Max.	2.4 – 5.3	2.1 – 3.9	1.7 – 2.8	
Capsule-bone distance (right, mm)	X±SD	3.72±0.91	2.59±0.55	2.13±0.18	<0.001
	Median	4.0	2.3	2.05	
	Min. – Max.	2.2 – 5.5	1.8 – 3.9	1.8 – 2.6	

Supraspinatus tendon was defined as homogenous if the fibrillar structure was preserved and border towards subdeltoid bursa clearly defined. Tendon is defined as inhomogeneous if the fibrillar structure was corrupted without clear border towards subdeltoid bursa.

Data analysis

The software package Statistica 6. was used. To estimate statistical significant difference between numeric parameters, analysis of variance was used. Correlation between categorical variables between groups was estimated by χ^2 test.

Results

Thickness of supraspinatus tendon of both shoulders in symptomatic dialyzed patients is significantly higher than in asymptomatic dialyzed or in healthy volunteers, and thickness of supraspinatus tendon in asymptomatic dialyzed is significantly higher than in healthy volunteers (Table 1).

Diameter of biceps tendon sheet of both shoulders in symptomatic dialyzed patients patients is significantly higher than in asymptomatic dialyzed or in healthy vol-

unteers, and it is higher in asymptomatic dialyzed than in volunteers (Table 1).

Capsule-bone distance of both shoulders shoulders in symptomatic dialyzed patients is significantly higher than in asymptomatic dialyzed or in healthy volunteers, and it is higher in asymptomatic dialyzed than in volunteers (Table 1).

There is no significant difference between symptomatic and asymptomatic dialyzed patients concerning the presence of calcifications in supraspinatus tendon (Figure 1) of both shoulders ($\chi^2=2.01$, $p=0.2$). There are calcifications in significantly more number of shoulders in symptomatic dialyzed than in volunteers ($\chi^2=15.36$, $p=0.001$), as well as in asymptomatic dialyzed patients than in volunteers ($\chi^2=5.14$, $p=0.025$, Figure 2).

Inhomogeneity of the supraspinatus tendon (Figure 3) is found in significantly more shoulders in symptomatic than in asymptomatic dialyzed patients ($\chi^2=57.22$, $p=0.001$) and in volunteers ($\chi^2=100.58$, $p=0.001$). There is no difference between asymptomatic dialyzed and healthy volunteers ($\chi^2=3.2$, $p=0.10$, Figure 4).

Biceps tendon sheet effusion (Figure 5) is found in significantly more shoulders in symptomatic than in asymptomatic dialyzed patients ($\chi^2=23.34$, $p=0.001$) and

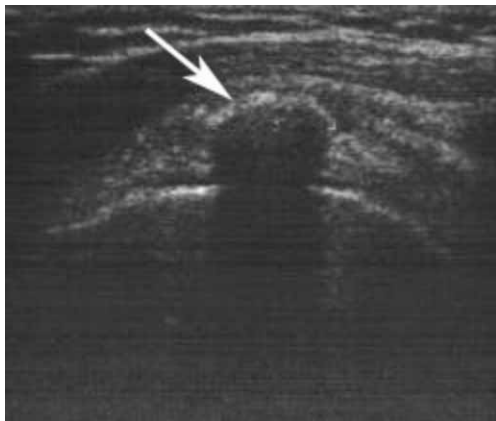

Fig. 1. Calcification in supraspinatus tendon (white arrow).

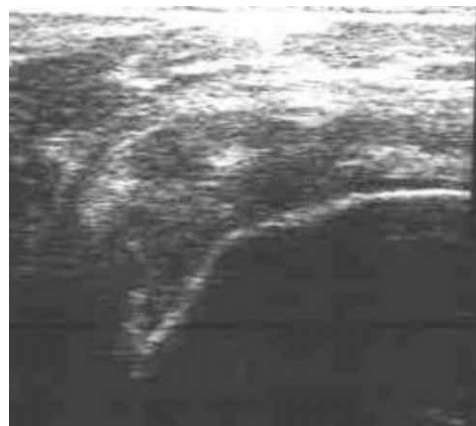

Fig. 3. Inhomogeneity of supraspinatus tendon.

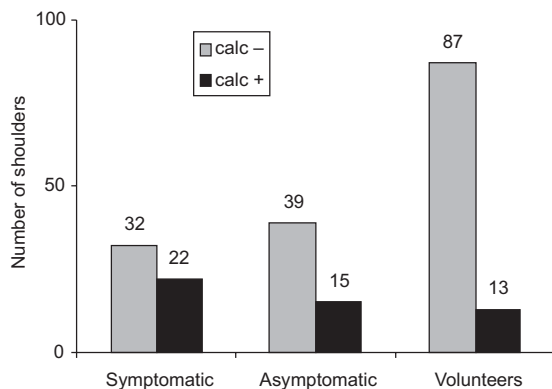


Fig. 2. Presence of supraspinatus tendon calcifications (calc-, calc+) in symptomatic and asymptomatic dialyzed patients and healthy volunteers.

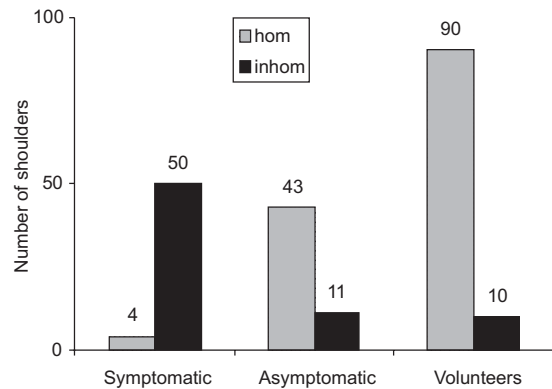


Fig. 4. Number of homogenous V_1 (hom) and inhomogeneous V_2 (inhom) supraspinatus tendons in symptomatic and asymptomatic dialyzed patients and healthy volunteers.

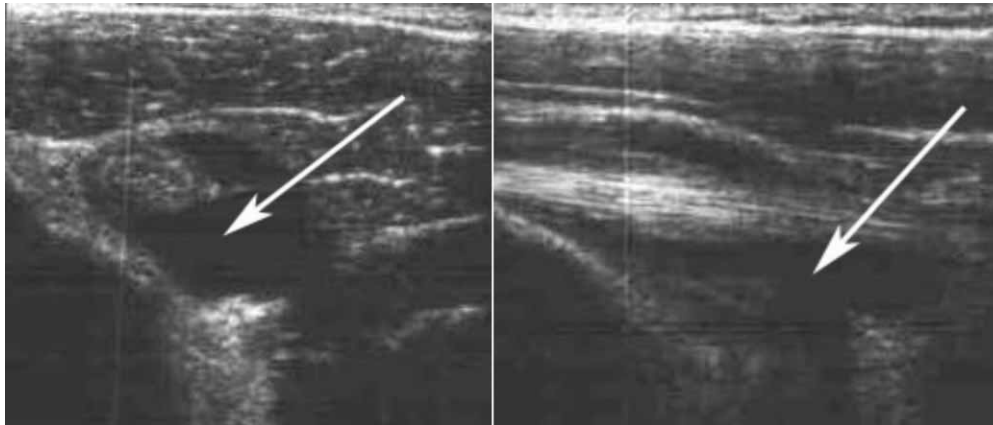

Fig. 5. Biceps tendon sheet effusion (white arrows). a) transverse view, b) longitudinal view.

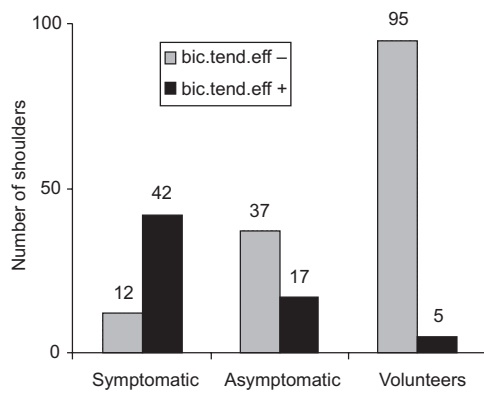


Fig. 6. Presence of biceps tendon sheet effusion (bic. tend.eff.) in symptomatic and asymptomatic dialyzed patients and healthy volunteers.

in volunteers ($\chi^2=87.58$, $p=0.001$). It is found in more shoulders in asymptomatic dialyzed patients than in healthy volunteers ($\chi^2=20.08$, $p=0.10$, Figure 6).

Subdeltoid bursa effusion (Figure 7) is found only in symptomatic dialyzed patients Figure 8 as well as hypo-

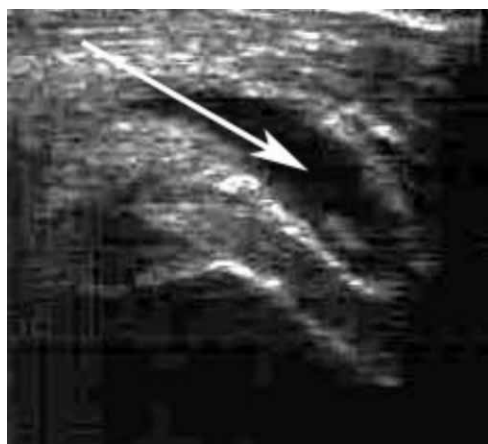

Fig. 7. Subdeltoid bursa effusion (white arrow).

hiperechogenic deposits in rotator cuff and bursae and partial ruptures, while total ruptures were found only in few shoulders in symptomatic patients.

Discussion

Thickness of supraspinatus tendon and diameter of biceps tendon sheet are parameter associated with dialysis arthropathy, especially histological proved dialysis related amiloidosis found in long term dialysis, over ten years^{1,7-10}.

In our study, together with capsula-bone distance, as indicator for shoulder joint effusion¹ supraspinatus tendon thickness was found as relevant metric parameter of painful shoulder in patients on shorter term dialysis. The fact that asymptomatic dialyzed patients have higher values than healthy volunteers means that those parameters are associated with that kind of therapy and that show higher values gradually. Pain may occur due to inflammatory or impingement due to reduction of subacromial space.

There was no significant difference between symptomatic and asymptomatic dialyzed patients concerning

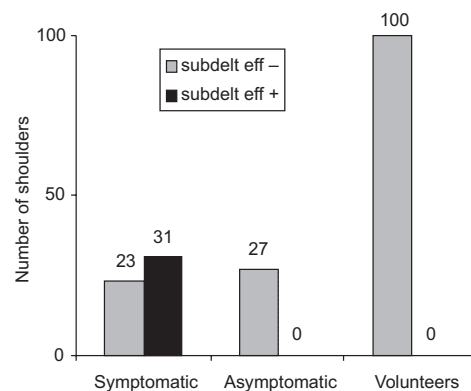


Fig. 8. Presence of subdeltoid bursa (subdelt. eff.) effusion in symptomatic and asymptomatic dialyzed patients and healthy volunteers.

the presence of calcifications in supraspinatus tendon. Calcifications are in literature associated with painful shoulder^{4,5} and with dialysis arthropathy¹, but considering that they are found not only in asymptomatic patients, but even in healthy volunteers, relevance of this parameter is doubtful.

Inhomogeneity of the supraspinatus tendon is parameter that had been noticed in few reports in the patients of long term dialysis¹⁰, and in painful shoulder after shorter time of this therapy¹⁶. It occurs partly due to small deposits in subdeltoid bursa expanding into the corrupted tendon. In our study it is strongly associated with painful shoulder in dialyzed patients. It occurs also in asymptomatic patients, but also in certain shoulders in healthy volunteers with calcifications, so it is clear that in those cases inhomogeneity has different origin.

Biceps tendon sheath effusion can be found in impingement syndrome due to repetitive pressure of rotator cuff and biceps tendon^{12,13}.

It can be found in dialyzed patients due to inflammatory reaction as a isolated entity or together with impingement due to adjacent impingement due to thicken-

ing of rotator cuff and consequently reduction of subacromial space. It is found in many cases in the group of asymptomatic patients so it can be established as early sign. In few cases it can be found even in volunteers without explained reason.

Subdeltoid bursa effusion is usually found in inflammatory diseases^{5,13}, painful shoulder noninflammatory origin due to massive rotator cuff rupture¹⁴ or in dialyzed patients^{1,9,10}, where the inflammatory component is to be emphasised¹⁶. In our study it is found only in symptomatic patients, so it can be considered as latter sign of shoulder changes due to dialysis.

Hiper-hipo echogenic foci being considered as deposits due to accumulation of fibrils of modified β 2-microglobuline is associated with long term dialysis and of course it can be found only in symptomatic patients.

Total supraspinatus ruptures are associated with dialysis only in presence of deposits which corrupted tendon¹⁰.

Partial ruptures may be the same origin, or may be associated with other influences independent of dialysis therapy.

REFERENCES

1. COARY, G., A. IAGNOCCO, S. MAGGI, M. BRACCI, A. DE CATA, M. MASTANTUONO, M. LARCIPRETE, S. PERSICHETTI, Eur. Radiol., 6 (1996) 890. — 2. JADOUL, M., J. MALGHEM, B. VAN DE BERG, C. VAN YPERSELE DE STRIHOU, Kidney Int., 41 (1993) 106. — 3. BARIŠIĆ, I.: Connection of β 2-microglobuline with radiologic morphologic parameters of painful shoulder in patients on chronic haemodialysis, PhD Thesis, In Croat. (University of Split, Split, 2006). — 4. CHIOU, H. J., Y. H. CHOU, J. J. WU, T. F. HUANG, H. L. MA, C. C. HSU, C. Y. CHANG, Ultrasound. Med. Biol., 27 (2001) 735. — 5. IAGNOCCO, A., E. FILIPUCCI, G. MEENAGH, A. DELLE SEDIE, L. RIENTE, S. BOMBARDIERI, W. GRASSI, G. VALESINI, Clin. Exp. Rheumatol., 24 (2006) 6. — 6. CHIOU, H. J., Y. H. CHOU, J. J. WU, C. C. HSU, D. Y. HUANG, C. Y. CHANG, J. Ultrasound. Med., 21 (2002) 289. — 7. MCMAHON, L. P., J. RADFORD, J. K. DAEBORN, Clin. Nephrol., 35 (1991) 227. — 8. KAY, J., C. B. BENSON, S. LESTER, Arthritis. Rheum., 35 (1992) 926. — 9. NAGI, S., Y. KITA, K. UCHITA, T. ABE, Nippon. Jinzo. Gakka. Shi., 37 (1995) 29. — 10. SOMMER, R., G. J. VALEN, Y. ORI, T. WEINSTEIN, M. KATZ, D. HENDEL, A. KORZETS, J. Ultrasound. Med., 19 (2000) 765. — 11. FLOEGE, J., J. SCHAFFER, K. M. KOCH, S. SHALDON, Kidney. Inter., 38 (1992) 78. — 12. WARNER, J. P.: Pathophysiology and findings in impingement and rotator cuff tears. (American Medical Society for Sports Medicine, Hilton Head Island, 1995). — 13. IAGNOCCO, A., G. COARY, A. LEONE, G. VALESINI, Clin. Exp. Rheumatol., 21 (2003) 355. — 14. ČIČAK, N., Liječnički Vjesnik, 121 (1999) 87. — 15. SHER, J. S., J. W. URIBE, A. POSADA, B. J. MURPHY, M. B. ZLATKIN, J. Bone Joint. Surg., 77 (1995) 77. — 16. BARIŠIĆ, I., V. WILHELM, N. ŠTAMBUK, K. KARAMAN, S. JANKOVIĆ, P. KONJEVODA, B. POKRIĆ, Croat. Chem. Acta, 75 (2002) 935.

I. Barišić

Department of Diagnostic and Interventional Radiology, University Hospital Split (Križine), Šoltanska 1, 21000 Split, Croatia
e-mail: igorbarisic@net.hr

ZNAČAJNI ULTRAZVUČNI PARAMETRI BOLNOG RAMENA SIMPTOMATSKIH DIJALIZIRANIH BOLESNIKA U ODNOSU NA PARAMETRE ASIMPTOMATSKIH DIJALIZIRANIH I ZDRAVIH DRAGOVOLJACA

S A Ž E T A K

Svrha rada je utvrditi značajne ultrazvučne parametre bolnog ramena simptomatskih dijaliziranih bolesnika uspoređujući ih s parametrima u asimptomatskih dijaliziranih bolesnika i zdravih dragovoljaca. Značajna razlika među metričkim parametrima (debljina tetive m. supraspinatusa, promjer ovojnice tetive duge glave bicepsai distanca zglobova – kost glave humerusa) nađena je između svih skupina ispitanika, a simptomatski su imali najviše vrijednosti. Asimptomatski dijalizirani su imali više vrijednosti od dragovoljaca. Inhomogenost tetive supraspinatusa i izljev u

ovojnicu tetive duge glave bicepsa najčešći su u simptomatskih dijaliziranih. Izljev u subdeltoidnu burzu, depoziti i rupture tetive supraspinatusa nađeni su samo kod simptomatskih ispitanika. Nije nađena značajna razlika među simptomatskih i asimptomatskih ispitanika glede pojavnosti kalcifikacija. Metrički parametri su značajni i povezani su s dijalizom, kao i izljev u ovojnicu tetive duge glave bicepsa, inhomogenost tetive m. supraspinatusa, depoziti te izljev u subdeltoidnu burzu. Rupture tetiva su rijetke i nisu specifične.