



Patterns of Otolaryngologic Sequelae of Suicide Attempts Seen in Nigerian Tertiary Hospitals

Olajuyin OA^{1*}, Olajide TG², Oluwole LO³, Lawal MA⁴, Ali A⁵, Olajuyin AB⁶ and Olajuyin AA⁷

¹Department of ENT, Ekiti State University Teaching Hospital, Nigeria

²Department of ENT, Ekiti and Afe Babalola University, Nigeria

³Department of Psychiatry, Ekiti State University Teaching Hospital, Nigeria

⁴Department of Psychiatry, Ekiti and Afe Babalola University, Nigeria

⁵Department of ENT, Federal Teaching Hospital, Nigeria

⁶Department of Family Medicine, Ekiti State University Teaching Hospital, Nigeria

⁷Department of Obstetrics-Gynaecology, Ekiti State University Teaching Hospital, Nigeria

Abstract

Background: Otolaryngologic sequelae of suicide attempts are rarely reported as an entity. In this report, we describe the patterns otolaryngologic sequelae of suicide attempts seen in Nigerian tertiary hospitals.

Objective: To improve among clinicians, knowledge of the patterns of otolaryngologic sequelae of suicide attempts with a view to promote their management at the three tiers of health care delivery.

Methodology: A retrospective analysis of clinical records of survivors of suicide attempts seen in Nigerian tertiary hospitals.

Results: In all, 52 patients were seen. Of this, 34 were cases of otolaryngologic sequelae. Majority, (56.0%) of the sequelae were corrosive oesophagitis. Other sequelae were: corrosive oropharyngoesophagitis (14.7%), corrosive oropharyngitis (8.8%), and corrosive laryngitis (5.9%), hypertrophy scar on the neck (5.9%), laryngeal stenosis (2.9%), pharyngocutaneous fistula (2.9%) and sudden hearing loss (2.9%). The sudden hearing loss was caused by overdose of diazepam. There was discordance in the prevalence of isolated corrosive oesophagitis and oropharyngitis as noted by the 56.0% vs. 8.8% respectively in a pathologic continuum.

Conclusion: Corrosive oesophagitis is the most common otolaryngologic sequelae of suicide attempts accounting for 56.0% of cases in this study. There was discordance in the patterns of corrosive injuries of the oesophagus and oropharynx as noted by the 56.0% and 8.8% prevalence respectively, in a pathologic continuum. This stresses the need to avoid using the clinical state of the oropharynx to gauge the condition of the oesophagus. It also emphasizes the importance of diagnostic endoscopy in all symptomatic cases of corrosive ingestion. The occurrence of sudden hearing loss post-ingestion of diazepam remains enigmatic. We therefore suggest empirical studies on this unique finding using laboratory animals.

Keywords: Suicide attempts; Otolaryngologic sequelae; Patterns; Corrosive oesophagitis; Sudden hearing loss

Introduction

Suicide attempt is of public health importance. Apart from imposing psychological, social and economic burdens on the victims, family members and societies, the condition is associated with diverse clinico-pathological consequences. Although, interrelated, suicide attempts is far more common than the complete suicide. In the United States, about 80 suicides and 1,500 unsuccessful suicides occur per day [1]. Globally, suicide attempts are estimated to be 20 times as frequent as completed suicides [2]. Non-fatal suicide behaviors are powerful predictors of subsequent suicide deaths [2]. They are warning behavioral signs that attempter is prone to suicide. Therefore, the stakeholders must intervene lest the victim commits eventual suicide. Suicides have been recorded more in men than women [3-5]. The rate increases with age with a major peak in adolescents and young adults [6]. The risk factors to suicide and suicide attempts include mental disorders,

OPEN ACCESS

*Correspondence:

Olajuyin OA, Department of ENT, Ekiti State University Teaching Hospital, Ado- Ekiti, Ekiti State, Nigeria, Tel: +2348035769839;

E-mail: oyebanjiolajuyin@yahoo.com

Received Date: 06 Jul 2019

Accepted Date: 01 Aug 2019

Published Date: 08 Aug 2019

Citation:

Olajuyin OA, Olajide TG, Oluwole LO, Lawal MA, Ali A, Olajuyin AB, et al. Patterns of Otolaryngologic Sequelae of Suicide Attempts Seen in Nigerian Tertiary Hospitals. *Am J Otolaryngol Head Neck Surg.* 2019; 2(7): 1063.

Copyright © 2019 Olajuyin OA. This is an open access article distributed under the Creative Commons Attribution License, which permits unrestricted use, distribution, and reproduction in any medium, provided the original work is properly cited.

drug/alcohol abuse, and family history of suicides, socio-economic disorders, hopelessness, stressful life issues and quest for relief from guilt, shame, rejection and loneliness [7-10]. The method adopted for suicide and suicide attempts depends on the availability and accessibility of such method in the environment. They include ingestion of chemicals, drug overdose, firearms, drowning, cut throats, hanging, jumping from a height, burning and running into traffics [11,12]. Overall, men tend to choose violent means while women tend to choose less violent means of suicides [1]. Those with religious affiliation are less likely to attempt suicide compared with non-religious [13]. The clinico-pathologic consequences of suicide attempts depend on the nature and potency of the method used, the part of the body targeted and prompt medical attention. In many instances, the head and neck and upper aero digestive tracts are the targets for suicide attempts. Accordingly, the otolaryngologists, head and neck surgeons are in the frontline of treating the victims. That the case is an attempted and not completed suicide implies that the victim is alive. Therefore, all attempts must be made to halt and prevent progression of the otolaryngologic sequelae to eventual death. This requires that clinicians at all levels of health care delivery understand the patterns and their roles in the management of the otolaryngologic sequelae. However, the epidemiological data needed to understand the patterns are sparse in the developing countries as cases are largely underreported. Thus, in this study, we report the patterns of otolaryngologic sequelae of suicide attempts with a view to promote the roles of clinicians in the management of the sequelae at the three tiers of health care delivery.

Statement of the problem

Suicide is one of the ten leading causes of death in the world with 1 million deaths recorded annually [2]. In the United State of America, it is the 11th leading cause of death in 2004 [14]. There are several forms of suicidal behavior which falls within the self-destructive spectrum. These include; suicide attempt, suicide gesture, suicide gamble and suicide equivalent [6]. About 1/3rd of people who attempted suicide will repeat the act within a year while 10% of people who threaten or attempted to commit suicide will eventually kill themselves [6].

Significance of this study

This study beams research lights on the otolaryngologic sequelae of suicide attempts. The study in particular, illustrates the clinico-pathological relationship between mental and otolaryngologic disorders. It describes the strategies for the prevention, diagnosis and treatment of the otolaryngologic sequelae of suicide attempts which hitherto are underreported. Considering the fact that the head and neck are the seats of the brain, great vessels, respiratory and food passages, any study to control or manage injuries to these vital structures is justifiable.

Materials and Methods

Study setting

This is a ten-year review of survivors of suicide bids in two tertiary hospitals. The study was conducted at the Ear, Nose and Throat, Psychiatry, Accident and Emergency Departments of the Tertiary Hospitals. The hospitals serve the communities in the local and neighboring states in south-western Nigeria.

Ethical consideration

Ethical clearance for the study was obtained from the Institution's Ethics and Research Committee.

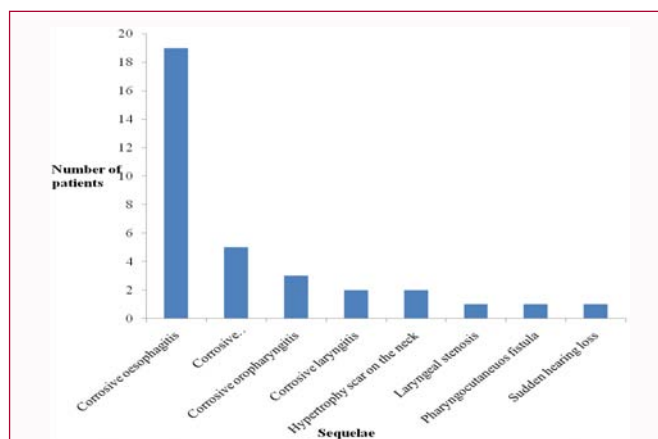


Figure 1: Frequency distribution of the otolaryngologic sequelae of suicide attempts.

Study design and data collection

Records of the patients were retrieved and analysed. The information retrieved were age, sex, occupation, religion, home address, precipitating factors, means of attempts, place of attempts, previous attempts, number of attempts, who discovered the attempts, mode of presentations, use of suicidal notes and otolaryngologic sequelae. All patients with complete data were included while those with incomplete data and those with non-otolaryngologic sequelae were excluded from the study.

Data analysis

The data generated were entered into personal computer and simple descriptive statistics was performed using SPSS Version 20.

Results

In all, records of 52 victims of suicide attempts were analyzed. There were 39 males and 13 females given a M:F ratio of 3:1. Their age ranged from 13 years to 60 years, mean =33.9, Standard deviation =12.4. Suicide attempt was highest in the age group 21 years to 30 years. Majority (55.8%) of the victims were married. Large percentages (90.4%) were Christians while 9.6% were Muslims. Secondary education scored highest on the frequency scale of educational levels attained by the victims. Majority were students while a banker occupies the lowest rung of the occupation ladder (Table 1). Failure to attain financial goals was the most frequent reason for attempting suicide (Table 2). The methods chosen for the suicide attempts are presented in Table 3. Of the 52 victims, 34 (65.4%) had otolaryngologic sequelae. Majority, (56.0%) of the sequelae were corrosive oesophagitis. Other sequelae were: corrosive oropharyngoesophagitis (14.7%). Corrosive oropharyngitis (8.8%), corrosive laryngitis (5.9%), hypertrophy scar on the neck (5.9%), laryngeal stenosis (2.9%), pharyngocutaneous fistula (2.9%) and sudden hearing loss (2.9%). The sudden hearing loss was caused by the ingestion of diazepam overdose. There was discordance in the prevalence of isolated corrosive oesophagitis and oropharyngitis as noted by the 56.0% vs. 8.8% respectively in a pathologic continuum. Those (26.3%) referred from the primary health care level needed no referral while majority (75%) of those referred from the secondary health care level came with oesophageal strictures. A repeat suicide attempts were recorded once in 6 and twice in 2 of the 52 cases.

Discussion

Reports had shown that the head and neck and upper aero

Table 1: Showing socio-demographic characteristics of the patients (n=52).

Variable	Frequency (n)	Percentage (%)
Age (years)		
<20	8	15.4
21-30	17	32.7
31-40	10	19.2
41-50	12	23.1
51-60	5	9.6
Gender		
Male	39	75.0
Female	13	25.0
Marital Status		
Married	29	55.8
Single	22	42.3
Widow	1	1.9
Occupation		
Student	15	28.8
Trading	11	21.2
Civil servant	8	15.4
Unemployed	7	13.5
Farmer	6	11.5
Artisan	4	7.7
Banker	1	1.9
Educational level		
No formal education	7	13.5
Primary	4	7.7
Secondary	24	46.2
Tertiary	17	32.7
Religion		
Christianity	47	90.4
Islam	5	9.6

digestive tracts are most often the targets for suicide attempts. In Ile-Ife, Nigeria, those who used gun as means of suicide applied it to the head and neck region in 76% of the cases [15]. In the Niger-Delta, the neck was the target as hanging was the commonest method of suicide [1]. In the present study, the oesophagus, oropharynx, and larynx were the most common targets for suicide attempts with 56.0% of the cases being corrosive oesophagitis. Previous studies in Nigeria had shown that corrosive oesophagitis in adults is suicidal in the majority of cases [16,17]. The preference for corrosive substances as the means of suicide attempts in the present study could be due to the availability and accessibility of these substances in our environment. That availability and accessibility were the determinant factors to the methods of suicide and suicide attempts has been reported [1,18]. Hanging as the most preferred means of suicide in the Niger-Delta was attributed to the availability and accessibility of ropes and cords in the study locale¹ while the availability of caustic soda was responsible for the accidental and suicidal ingestion of corrosives in the cases of Ogunleye et al. [17].

Pathologically, ingested caustic soda usually produces effects of great interest. According to Kluger et al. [19], alkali causes almost no

Table 2: Factors that precipitated the suicide attempts.

Category	Frequency (n)	Percentage (%)
Failure to attain financial goals	13	25.0
Marital conflicts	9	17.3
Failure in examinations	9	17.3
False accusation of theft	8	15.4
Financial Indebtedness	7	13.5
Unwanted pregnancy	4	7.7
Psychiatric problem	2	3.8
Total	52	100%

Table 3: Methods chosen for suicide attempts by the victims.

Items	Frequency (n)	Percentage (%)
Corrosives	27	51.9
Herbicide	8	15.4
Cut throat	6	11.6
Dry cell battery	4	7.7
Hanging	3	5.8
Jumping into river/drowning	2	3.8
Drug over dose	2	3.8
Total	52	100%

irritation to the oral cavity, which usually results in larger ingested volumes entering the gastrointestinal tract. In 10% to 30% of patients with severe oesophageal post-corrosive burns, there are no local changes in the oropharynx [20]. Supporting these reports, 56.0% of corrosive oesophagitis in the present study had no lesion in the oropharynx. By contrast, 8.8% of patients with oropharyngeal lesions in this study had no lesion in the oesophagus. In another report, 70% of patients with severe oropharyngeal injuries did not have noticeable oesophageal damages [20]. These pathological discordances stress the need to avoid using the appearance of the oropharynx as the clinical barometer of the pathological events in the oesophagus. It also stresses the importance of endoscopic view of the oesophagus in all symptomatic cases of corrosive ingestions. Clinically, patients with caustic injuries of the upper aero digestive tracts often present with oral pain, odynophagia and drooling of saliva. At the primary health care level, triaging is the key to effective management. The question to ask is: Is there airway involvement? Involvement of the airway is a sign of corrosive laryngitis and an indication for referral to centers where the airway can be managed. Corrosive laryngitis has been reported in the literature [21]. The clinical pointers include difficulty with breathing, sore throat and hoarseness. Presence of airway obstruction is an indication for end tracheal intubation or tracheostomy. The choice between the two depends on swiftness and effectiveness at restoring airway. Intubation requires no incisions, easier and faster. However, in the event of difficulty with intubation due probably to laryngeal oedema, the patient is ventilated with facemask via oropharyngeal airway while tracheostomy is being performed. Tracheostomy is effective, easier to manage and quite unlike the end tracheal tube, its tube can be manipulated by closing the stoma with finger to produce speech as a sign of recovery from the caustic laryngitis. The prognosis of caustic injury to the larynx depends on the extent of injury and part of the larynx involved. Two of the patients with upper gastrointestinal caustic injuries in this study had concomitant injuries to the supraglottis. However, the injuries

were minimal and both responded well to conservative management at our tertiary health care centers.

For those without airway involvement, the decision to manage at the primary health care level depends on the degree of injury of the oesophagus and oropharynx. Although, endoscopy is the means to establish the degrees of injuries in the oesophagus, endoscopy may be deferred in asymptomatic cases with no signs of oropharyngeal injury [22,23]. In such circumstances, the patient may be observed by the primary care physicians and discharged after 48 h [22]. There may be need for steroids and prophylactic antibiotics to prevent stricture and secondary bacterial infection respectively. Interestingly, 5 (26.3%) of the corrosive oesophagitis in this study were referred from the primary health care centers without the need for referral. Although, the patients might have been referred for psychiatric assessment, nothing in their referral notes was suggestive of referral for psychiatric evaluation. This stresses the need for the establishment of treatment protocol at the primary health care centers since not all cases will require or have access to higher levels of health care delivery. Such guideline will improve diagnostic accuracy, highlight the need for referral, promote appropriate therapeutic options and improve counselling education for the prevention of repeat suicide attempts.

Of great concern in this study was the high prevalence of oesophageal stricture among the cases of corrosive oesophagitis referred from the secondary health care centers. As noted, 75% of the cases referred from that level of health care delivery had developed stricture prior to the referral. Indeed, most of the patients were referred on account of oesophageal stricture. This finding might have been due to late presentation, severe injury and or ineffective care at the secondary health care centers. There is therefore the need for the update on the treatment protocols of corrosive oesophagitis at the secondary health care level. Generally, the management of caustic injury of the upper gastrointestinal tracts entails accurate diagnosis, appropriate referral and prompt treatment. Because the oesophagus is invisible to unaided eyes, endoscopy is now considered the gold standard for the accurate diagnosis of corrosive oesophagitis. It is recommended for symptomatic cases within 12 h to 24 h post ingestion [22]. Apart from its diagnostic role, the procedure is useful for prognostication and serves as a guide to the management of the caustic ingestion. With these valuable roles, it is possible to significantly reduce the incidence of stricture associated with caustic ingestion. The use of nasogastric tube is another means said to prevent stricture in corrosive oesophagitis. Proponents of the practice theoretically believe it will serve as a stent, maintain luminal integrity, minimize stricture formation and provide a pathway for enteral feeding [19]. However, opponents opine that nasogastric tube could induce retching, vomiting and being a foreign body acts as a nidus for infection in the acute stage [19,22]. In our own series, the use of nasogastric tube was found to be beneficial in selected cases. That steroid could prevent oesophageal stricture in corrosive oesophagitis have been reported in the literatures [24,25]. In the present study, two cases of second degree oesophageal caustic burns were found with complete resolution following treatment with steroid. However, the use of steroid in corrosive oesophagitis has been widely criticized by some researchers who believed the drug may do more harm than good [17,26,27]. According to Ogunleye et al. [17], steroid could interfere with wound healing, depress the body's immune defense mechanisms and mask the features of infection and visceral perforation. With these divergent opinions, steroid, in the treatment of corrosive oesophagitis must be used cautiously and individualized. Other

measures that could promote primary healing of the gastrointestinal tracts include enteral or parenteral nutrition and anti-inflammatory analgesics. The induction of vomiting and use of antidotes have not been universally adopted. Although, our records did not show if these treatment modalities were adopted by the referring centers, none of those that primarily presented to our centers were treated with the induction of vomiting and use of antidotes. Therefore, it could not be ascertained the values of these protocols in the management of patients with corrosive ingestion. Beyond the treatments at the secondary health care centers, patients with corrosive oesophagitis may require high skill surgical intervention at the tertiary centers. Such intervention may be for acute oesophageal perforation or long term complications. None of the cases in this study had oesophageal perforation that required immediate surgical intervention. However, one case required oesophagectomy plus gastric pull through to correct oesophageal stricture. Others with oesophageal strictures were managed with serial dilatations using bougies. In view of the complexity and technicalities involved in the management of caustic injuries of the upper aero-digestive tracts, there is the need for a multidisciplinary approach to share ideas and experiences in the treatment as this will not only facilitate diagnosis but also improve the prognostic outlook of the pathologic consequences.

Suicidal cut throat was found in 6 (11.6%) of our patients. However, only 4 (7.7%) had significant otolaryngologic sequelae. The objects used for the attempted self-harm were knives, broken bottles and razor blades. The knife injuries on the skin were mostly oblique and of varying lengths and depths. The pathologies ranged from mild through moderate to severe structural damage and functional loss. For those with superficial injuries with no threat to the airway, cleaning and dressing may suffice at the primary or secondary care levels. For life-threatening injuries, immediate transfer to the nearest specialist center keeping in mind the principle of ABC (Airway, Breathing and Circulation) of resuscitation is required. Sometimes, patient may require emergency tracheotomy. The goal of definitive management is to restore the structural and functional integrity of the throat. For this purpose, the severity of injury is assessed by assigning the injury to areas or zones of the neck [6]. With such systematic assessment, the affected tissues are determined and repaired appropriately. For those that present with secondary bacterial infection, debridement and copious irrigation of the wound are carried out. The wound is then repaired with infection-resistant sutures. In the event of tissue loss, there may be need to cover the defect with a flap. When poorly managed, suicidal cut throat may be complicated by pharyngocutaneous fistula. We recorded one of such in this study. Generally, the risk factors for the development of pharyngocutaneous fistula are foreign body, wrong surgical technique, malnutrition and concomitant underlying malignancy [6]. In our own case, the fistula resulted from late presentation, contamination and secondary bacterial infection. The treatments included tube-feeding and nil per oral to avoid further contamination of the fistula. Other therapies were nutritional support; antibiotics based on sensitivity report and wound dressing. In the event of persistent fistula, a myocutaneous flap may be required to restore both the structural and the functional integrity of the pharynx. It is worthy to note that pharyngocutaneous fistula increases the treatment costs of cut throat. Therefore, prevention should be the goal in all cases of cut throat. Provided the patient presents early, proper initial management and primary closure of the suicidal cut throat will prevent this complication.

Hanging, drowning, ingestion of dry-cell batteries and drug

overdose were other means of suicide attempts recorded in this study (Table 3). Hanging was found mostly in adults while ingestion of dry-cell batteries and drug overdose were found mostly in adolescents in this study. Hanging is a violent and swift method of committing suicide. The airway is the most vulnerable target among the victims. Except there is swift intervention, the victim may die of asphyxia. Thus rescuers must pay attention to the airway when patient is seen early. A close watch on survivors is important to prevent a repeat of their suicidal bids. Regular psychiatric evaluation and treatments are the essentials of preventive measures.

A unique finding in this study was the occurrence of sudden hearing loss in a teenager. This followed deliberate ingestion of diazepam overdose. Diazepam belongs to the benzodiazepine group of drugs. It is a long-acting, medium-potency benzodiazepine. In addition to its anticonvulsant property, the drug has anxiolytic, sedative, and myorelaxative effects. Degradation occurs in the body, in some cases to pharmacologically active metabolites. The common side effects include: drowsiness, lethargy, vertigo, slurred speech and blurred vision [28]. However, toxicology has not shown any deleterious effects on auditory pathways. The present case was noted following recovery from the sedative effect of overdose of diazepam. The patient was previously speech and auditory competent. The attention of the otolaryngologist was drawn to the case following her failure to respond to calls after full recovery from the diazepam sedation. Clinical and audiometric (Pure Tone and Tympanometry) evaluation showed that the hearing loss was sensorineural, bilateral and of moderate threshold. Sudden sensorineural hearing loss is an otologic emergency [29]. Steps must be taken to prevent the hearing loss from becoming permanent. This underscores the important role of the primary care physician in the management of this otologic tragedy. All the primary care physician need do is to establish the diagnosis and institute immediate treatment. The patient need not be referred for audiometric diagnosis or specialist care. A high dose of oral corticosteroids for cases within 72 h of onset has been recommended for the treatment [29]. In our own case, high dose of corticosteroids was administered with good response. Our attempt to correlate the clinical and audiometric findings with feigned, hysterical and psychosomatic deafness failed to show any correlation. Thus, we consider the pathophysiology of hearing loss in this case enigmatic and suggest empirical validation with animal studies.

Repeat suicide attempts were recorded once in 6 and twice in 2 of the cases in this study. Repeat suicide attempt is a major epidemiological challenge. Statistically, about one-third of people who attempted suicide will repeat the act within a year while 10% of people who threatened or attempted to commit suicide will eventually kill themselves [6]. In this regard, they tend to vary the methods of suicide bid in order to succeed in the repeated act. In this study, 5 (62.5%) of the repeat attempters varied the methods at the repeat attempts. Although, the reason could be lack of access to the previous means, the determination to succeed in the repeat attempts could be the reason for the change.

Considering the social, economic and health burdens of otolaryngologic sequelae of suicide attempts, there is the need to intensify efforts in the prevention of this menace and its underlying psychiatric disorders. This may require home visiting, socio-economic support, provision of psychiatric support and removal of stigma of seeking psychiatric help. Cases must be followed and cared for based on the preventive strategies targeted at individuals who have already

begun self-destructive behavior.

Although, the number of cases in this study is small, studies have shown that majority of patients in this part of the world don't access orthodox health care. Instead, they go to traditional healers, spiritualists and quacks for solutions to their health problems [30]. Thus, the number of cases in this study might just be the tip of an iceberg. This, notwithstanding, our study illustrates the characteristic pattern of otolaryngologic sequelae of suicide attempts which holds true irrespective of the numerical strength of our study (Figure 1). Thus, the report of this study is expected to serve a tool for sensitization towards the control and treatment of suicide attempts and its otolaryngologic sequelae in our environment.

Conclusion

Corrosive oesophagitis is the most common otolaryngologic sequelae of suicide attempts accounting for 56.0% of cases in this study. There was discordance in the patterns of corrosive injuries of the oesophagus and oropharynx as noted by the 56.0% and 8.8% prevalence respectively, in a pathologic continuum. This stresses the need to avoid using the clinical state of the oropharynx to gauge the condition of the oesophagus. It also emphasizes the importance of diagnostic endoscopy in all symptomatic cases of corrosive ingestion. The occurrence of sudden hearing loss post-ingestion of diazepam remains enigmatic. We therefore suggest empirical studies on this unique finding using laboratory animals.

References

- Offiah S, Obiorah CC. Pattern of suicide in Nigeria: The Niger Delta experience. *J Med Investig Pract.* 2014;9(1):8-11.
- Nock MK, Hwang I, Sampson N, Kessler RC, Angermeyer M, Beautrais A, et al. Cross-national analysis of the association among mental disorders and suicidal behaviour: Findings from WHO World Mental Health Survey. *PLoS Med.* 2009;6(8):e1000123.
- Kanchan T, Menon A, Menezes RG. Methods of choice in completed suicide: Gender differences and review of literature. *J Forensic Sci.* 2009;54(4):938-42.
- Parker G, Yap HL. Suicide in Singapore: A changing sex ratio over the last decade. *Singapore Med J.* 2001;42(1):11-14.
- Saeed A, Bashir MZ, Khan D, Iqbal J, Raja KS, Rehman A. Epidemiology of suicide in Faisalabad. *J Ayub Med Coll Abbottabad.* 2002;14(4):34-7.
- Adoga AA. Suicidal cut throat injuries: Management modalities. *Mental Illnesses-Understanding, Prediction and Control.* 2012;423-36.
- Qin P, Agerbo E, Mortensen PB. Suicide risk in relation to socioeconomic, demographic, psychiatric and familial factors: A national register-based study of all suicides in Denmark. 1981-1997. *Am J Psychiatry.* 2003;160(4):765-72.
- Khalid N. Pattern of suicide causes & methods employed. *J Comp Physicians Surg Pak.* 2001;11:759-61.
- Beautrais AL, Collings SCD, Ehrhardt P, Henare K. Suicide prevention: A review of evidence of risk and protective factors, and points of effective intervention. Wellington: Ministry of health. 2005;1-77.
- Adewuya AO, Ola BA, Coker OA, Atilola O, Zachariah MP, Olugbile O, et al. Prevalence and associated factors for suicidal ideation in the lagos state Mental health survey, Nigeria. *BJ Psych Open.* 2016;2(6):385-9.
- Santhosh CS, Bande N. Pattern of suicidal death at district hospital davangere, A Cross-Sectional Study. *J Indian Acad Forensic Med.* 2013;35(3):233-5.
- Pradhan A, Tripathi CB, Mandal BK, Karn A, Subedi ND. Suicide:

- Attempts, Methods and Causes in Cases Brought for Autopsy in Bpkihs, Dharan. *J Forensic Res.* 2012;3:166.
13. Dervic K, Oquendo MA, Grunebaum MF, Ellis S, Burke AK, Mann JJ. Religious affiliation and suicide attempt. *Am J Psychiatry.* 2004;161(12):2303-8.
14. Suicide in the US: Statistics and prevention. National Institute of Mental Health. 2018.
15. Nwosu SO, Odesanmi WO. Pattern of suicide in Ile-Ife, Nigeria. *West Afr J Med.* 2001;20(3):259-62.
16. Adedeji TO, Tobih JE, Olaosun AO, Sogebi OA. Corrosive oesophageal injuries: A preventable menace. *Pan Afr Med J.* 2013;15:11.
17. Ogunleye AOA, Nwaorgu OGB, Grandawa H. Corrosive oesophagitis in Nigeria: clinical spectrums and implications. *Tropical Doctor.* 2002;32(2):78-80.
18. Nordentoft M. Prevention of suicide and attempted suicide in Denmark. Epidemiological studies of suicide and intervention studies in selected risk groups. *Dan Med Bull.* 2007;54(4):306-69.
19. Kluger Y, Ishay OB, Sartelli M, Katz A, Ansaloni L, Gomez CA, et al. Caustic ingestion management: World society of emergency surgery preliminary survey of expert opinion. *World J Emerg Surg.* 2015;10:48.
20. Chibishev A, Pereska Z, Chibisheva V, Simonovska N. Ingestion of caustic substances in adults: A review article. *Iranian J Toxicol.* 2013;6(19):723-34.
21. Han KY, Song YJ, Ko HS, Kim JY, Kim JH, Shim BS, et al. Acetic acid induced laryngitis. *Korean J Otolaryngol-Head Neck Surg.* 2008;51:1129-33.
22. De Lusong MAA, Timbol ABG, Tuazon DJS. Management of oesophageal caustic injury. *World J Gastrointest Pharmacol Ther.* 2017;8(2):90-8.
23. Rathnaswami A, Ashwin R. Corrosive injury of the upper gastrointestinal tract: a review. *Arch Clin Gastroenterol.* 2016;2(1):56-62.
24. Boukthir S, Fetni I, Mrad SM, Mongalgi MA, Debbabi A, Barsaoui S. High doses of steroids in the management of caustic esophageal burns in children. *Arch Pediatr.* 2004;11(1):13-17.
25. Mrad SM, Boukthir S, Sfaïhi L, Fetni I, Dabbabi A, Zouari B, et al. Therapeutic management and clinical course of severe caustic oesophageal burns in children treated with methyl-prednisolone. Experience at a digestive endoscopic unit. *Tunis Med.* 2004;82(10):951-7.
26. Pelclová D, Navrátil T. Do corticosteroids prevent oesophageal stricture after corrosive ingestion? *Toxicol Rev.* 2005;24:125.
27. Dogan Y, Gulcan M, Urganci N, Onal Z, Erkan T, Cokugras FC, et al. The Effect of Steroid Therapy on Severe Corrosive Oesophageal Burns in Children: A Multicentric Prospective Study: PG4-06. *J Pediatr Gastroenterol Nutr.* 2005;40(5):656.
28. Griffin CE III, Kaye AM, Bueno FR, Kaye AD. Benzodiazepine Pharmacology and Central Nervous System-Mediated Effects. *The Ochsner J.* 2013;13(2):214-23.
29. Leung MA, Flaherty A, Zhang JA, Hara J, Barber W, Burgess L, et al. Sudden Sensorineural Hearing Loss: Primary Care Update. *Hawaii J Med Public Health.* 2016;75(6):172-74.
30. Eze CU, Desmond EI. Attributes of patients with suicide attempts seen at the Niger Delta University Teaching Hospital within a year: A Case Series. *Trop Med Surg.* 2014;2(3):170.