



PROTECTIVE EFFECT OF ETHANOLIC EXTRACT OF *CRASSOCEPHALUM RUBENS* LEAVES ON CARBON TETRACHLORIDE - INDUCED LIVER DAMAGE IN RATS

Olusola Bolaji Adewale*, Amos Onasanya, Scholastica Onyebuchi Anadozie, Catherine
Jimbia Ogbole, Idowu Anthonia Akintan, Miriam Favour Abu

Department of Chemical Sciences, Biochemistry Unit, Afe Babalola University, P.M.B.
5454, Ado-Ekiti, Nigeria.

Article Received on
28 June 2015,

Revised on 18 July 2015,
Accepted on 12 Aug 2015

***Correspondence for
Author**

Olusola Bolaji Adewale
Department of Chemical
Sciences, Biochemistry
Unit, Afe Babalola
University, P.M.B. 5454,
Ado-Ekiti, Nigeria.

ABSTRACT

Natural products, most especially from plant origin, possess antioxidant properties which are known to play crucial roles in preventing and treating various pathological conditions occasioned by free radicals. *Crassocephalum rubens* is a one of those plants, and this study investigated the protective properties of ethanolic extract of *C. rubens* (EECR) leaves against hepatic damage induced by carbon tetrachloride (CCl₄). Thirty rats divided into 6 groups (n=5) were used for the investigation. Group 1 served as normal control while groups 2, 3 and 4 were pretreated for 21 days with EECR leaves at 150 mg/kg, 300 mg/kg and 450 mg/kg b.w. respectively, prior to a single intraperitoneal administration of CCl₄. Animals in groups 5 received

only the extract at a dose of 450 mg/kg body weight while animals in group 6 were given only CCl₄. All animals were sacrificed 24 h after the administration of CCl₄. CCl₄ significantly ($p < 0.05$) induced marked hepatic damage as revealed by increased activities of plasma ALT, AST, GGT and ALP. Also, plasma total protein and albumin were significantly decreased in CCl₄-treated animals relative to normal control. Analyses of antioxidant status showed that CCl₄ elicited a significant decrease in the activities of antioxidant enzymes, with an increase in malondialdehyde levels in liver. Pre-treatment with the EECR leaves at all doses tested however, significantly ($p < 0.05$) reduced the observed biochemical lesions. The hepatoprotective effect of the EECR may be traceable to the presence of phytochemicals inherent in the plant.

KEYWORDS: Antioxidants; Carbon tetrachloride; *Crassocephalum rubens*; Hepatic; Hepatoprotective.

INTRODUCTION

Free radicals, particularly reactive oxygen species (ROS) have a greater impact on human both within the body and the environment. The harmful and adverse effect of free radicals causing potential biological damage is termed oxidative stress and nitrosative stress.^[1] Oxidative stress results from the metabolic reactions that uses oxygen and represent a disturbance in the equilibrium status of prooxidant/antioxidant reactions in living organisms. The excess ROS can damage cellular lipids, protein or DNA, thereby inhibiting their normal functions. Oxidative stress has therefore been implicated in a number of human diseases such as cardiovascular disease, cancer, diabetes, liver cirrhosis, hepatitis as well as in ageing process.^[2]

Toxicants, such as carbon tetrachloride, are known to cause fatty acid accumulation and hepatic necrosis.^[3] CCl₄ is activated by cytochrome P₄₅₀^[3] and causes disorders in many tissues including liver, kidney, lungs, testis and brain as well as in blood.^[4-7]

The liver is known to play a number of vital roles and these functions are often compromised in liver pathology. Treatment or prevention of liver diseases is still a major challenge as the only hope for long term survival for patients is resection and transplantation, which are often outside the reach of many people especially in developing countries.

Natural products, most especially from plant origin, possess antioxidant properties which are known to play crucial roles in preventing and treating various pathological conditions occasioned by free radicals. Over 5000 plants are known to be used for medicinal purposes in Africa, however only a few of these have been studied.^[8] There is therefore need to screen more plants so as to contribute to the search for a cheap, safe and readily available remedy against several ailments, most especially liver diseases. To the best of our knowledge, there has been no report on the protective properties of *Crassocephalum rubens* against CCl₄ - induced liver damage. In this study, the ethanolic extract of the leaves of *C. rubens* were evaluated for its hepatoprotective potential against CCl₄-induced damage in rats.

Crassocephalum rubens belongs to the family Asteraceae. It is highly consumed in south-western part of Nigeria and other humid zones of west and central Africa. The leaves are

eaten raw or cooked in sauce. They are used as a nutraceutical and are believed to have antibiotic, anti-helminthic, anti-inflammatory, anti-diabetic, anti-malaria and blood regulation properties. They are known to also treat hepatic insufficiency, indigestion, colds and intestinal worms.^[9] The phytochemical analysis of *C. rubens* revealed the presence of tannins, coumarins, mucilage, flavonoids, proanthocyanidin, reducing compounds and steroids in the leaves of *C. rubens*.^[9,10] Methanolic extract of *Crassocephalum rubens* was shown to exhibit potent antioxidant activity both *in vitro* and *in vivo*.^[11] In view of these, *C. rubens* can be considered as one of the plants possessing significant antioxidant or free radical scavenging activities, and can therefore be suggested to be active in the prevention of cellular damage occasioned by CCl₄.

MATERIALS AND METHODS

Chemicals

Carbon tetrachloride was purchased from Sigma-Aldrich, USA. All chemicals and reagents used were of analytical grade while the water was glass distilled.

Collection and identification of plant material

The leaves of *Crassocephalum rubens* were obtained from Bisi market Ado-Ekiti, Ekiti state in October, 2014 and were then authenticated at the Department of Plant Science, Ekiti State University, Ado-Ekiti, Nigeria. The voucher specimen of the plant is available. A sample of the plant portion was deposited at the Departmental Herbarium for future reference.

Preparation and administration of extract

The plant sample of the plant was air dried and blended. The blended leaf material was then soaked in absolute ethanol for 24 h following which it was filtered using Whatman filter paper number 1. The filtrate was then concentrated at 45 °C using a rotary evaporator. The extract was administered orally using gavage according to the required doses of 150, 300 and 450 mg/kg body weight for 21 days.

Experimental animals

A total of 30 Wistar strains of albino rats weighing between 180 and 220g was used for the experiment. They were housed in clean plastic cages and maintained under standard laboratory conditions. They were fed with pelletized rat feed and water *ad libitum*. The procedures adopted in this study were in accordance with Guidelines for Care and Use of Laboratory Animals in Biomedical Research of the National Institutes of Health of the United

States (NIH Publication, revised in 1985). All animal experiments were approved by the animal care committee of the Afe Babalola University Research Center, Ado-Ekiti, Ekiti State, Nigeria.

Grouping of animals

The animals were divided into 6 groups of 5 animals each. Group 1 (normal control) animals received normal feed while animals in group 2 received normal feed and *C. rubens* leaf extract at a daily dose of 150 mg/kg body weight. Group 3 animals received normal feed and leaf extract at a daily dose of 300 mg/kg body weight while animals in group 4 received normal feed and extract at a daily dose of 450 mg/kg body weight. Animals in group 5 received normal feed and leaf extract at a daily dose of 450 mg/kg body weight. Group 6 (negative control) animals received normal feed and a single intraperitoneal administration of CCl₄ only. Administration of different doses of the leaf extract lasted for 21 days following which, animals in groups 2, 3 and 4 received a single intraperitoneal injection of CCl₄ after an overnight fast.

Administration of CCl₄

Where necessary, each animal received 3 ml/kg body weight of a 1:1 preparation of CCl₄ and groundnut oil (in the ratio 1:1).

Preparation of plasma and liver homogenate

The rats were sacrificed by cervical dislocation 24 h after CCl₄ administration and then dissected. Blood samples were collected from the heart using the heart puncture technique. Blood was collected in heparinized bottles. The blood samples were subsequently centrifuged at 3000 rpm for 10 min using a bench centrifuge to obtain plasma. The plasma obtained was separated, and transferred into fresh plain sample bottles and used for the subsequent biochemical analyses. The liver of each animal was excised immediately after sacrifice. They were rinsed in ice-cold 1.15% potassium chloride, blotted with filter paper and weighed. Weighed portions were minced with scissors in 4ml of ice-cold 0.1M phosphate buffer, pH 7.4 and homogenized in a Potter-Elvehjem homogenizer. The homogenates were later centrifuged using refrigerated centrifuge at 12,000 x g for 15 min at 4°C to obtain clear supernatants, which were used for subsequent biochemical analyses.

Biochemical analyses

Biochemical analyses carried out included measurement of the activities of plasma alanine aminotransferase (ALT), aspartate aminotransferase (AST), gamma-glutamyl transferase (γ -

GT or GGT) and alkaline phosphatase (ALP); plasma total protein and albumin concentrations. The determination of the concentrations of these biochemical parameters was done using commercially available test kits, products of Randox Laboratories (Crumlin, United Kingdom).

Antioxidant assays

Lipid peroxidation was assessed by measuring the formation of thiobarbituric (TBA) reactive substances according to the method described by Varshney and Kale.^[12] Catalase (CAT) activity was determined according to the method of Sinha.^[13] Superoxide dismutase (SOD) activity was measured as described by Misra and Fridovich.^[14]

Histopathological assessment

Liver sections from rats of different groups were fixed in 10% neutral formalin solution, dehydrated in graded alcohol, and embedded in paraffin. Fine sections obtained were mounted on glass slides and counter-stained with hematoxylin-eosin for light microscopic analyses. To eliminate bias, the slides which were coded, were examined and photographed by a qualified histopathologist who had no knowledge of the treatment groups.

Statistical analysis

Statistical analysis was done by one-way analysis of variance (ANOVA) using windows SPSS software package. Post-hoc testing was performed for inter-group comparisons using the Least Significant Difference (LSD) test according to the method described by Zar.^[15] In all instances p values < 0.05 were considered statistically significant.

RESULTS

Figure 1 revealed the effect of ethanolic extract of *Crasocephalum rubens* (EECR) leaves on CCl_4 - induced changes in plasma marker enzymes. Intraperitoneal administration of CCl_4 resulted in marked tissue damage as revealed by significant elevation in the activities of ALT, AST, GGT and ALP when compared with normal control group ($p < 0.05$). Pretreatment with EECR leaves at 150 mg/kg, 300 mg/kg and 450 mg/kg body weight produced a significant decrease in the activities of these enzymes when compared with CCl_4 group. Treatment with 450mg/kg leaves extract produced a non significant difference in the activities of these enzymes when compared with normal control group. Pre-treatment doses did not show any significant difference in the activities of these enzymes except in the ALP activity where a

significant difference was observed at 150 mg/kg b.w. relative to 300 mg/kg and 450 mg/kg b.w. groups.

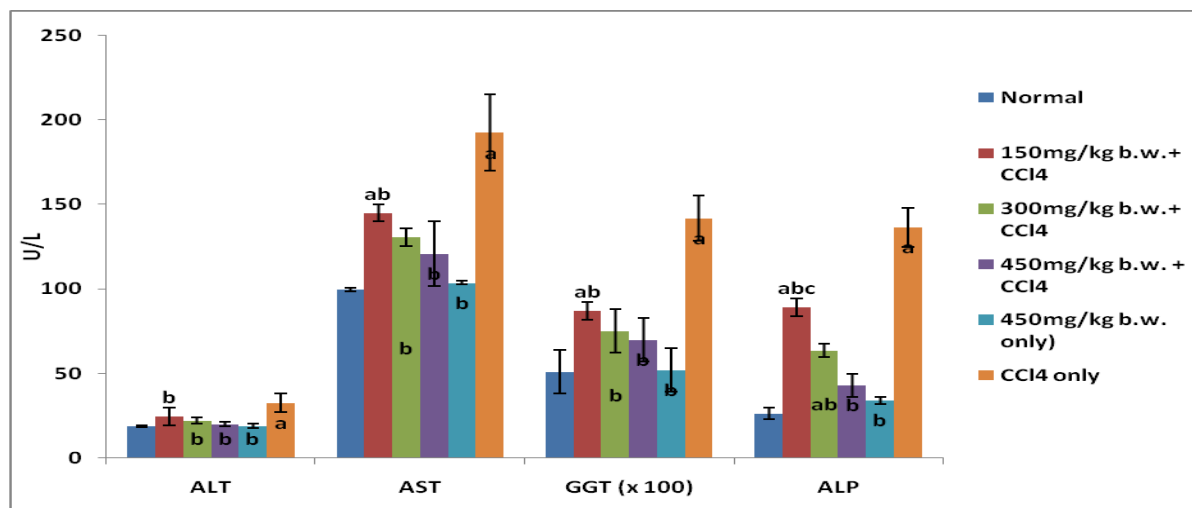


Figure 1: Effect of EERC leaves on CCl₄ - induced changes in plasma ALT, AST, GGT and ALP.

Values are expressed as Mean \pm SEM (n = 5)

^ap<0.05 when compared with Normal group

^bp<0.05 when compared with CCl₄ only

^cp<0.05 comparison among different doses of extract

Figure 2 showed the effect of ethanolic extract of the leaves of *Crasocephalum rubens* on CCl₄ - induced changes in plasma total protein and albumin. A significant decrease in the concentrations of total protein and albumin was observed following an intraperitoneal administration of CCl₄ when compared with normal group (p<0.05). Pre-treatment with EECR (leaves) at 150 mg/kg b.w., 300 mg/kg b.w. and 450 mg/kg b.w. resulted in significantly increased concentration of total protein and albumin when compared with the CCl₄ group. Treatment with 450mg/kg b.w. extract produced a non significant difference when compared with normal group. There were no significant differences among the tested doses.

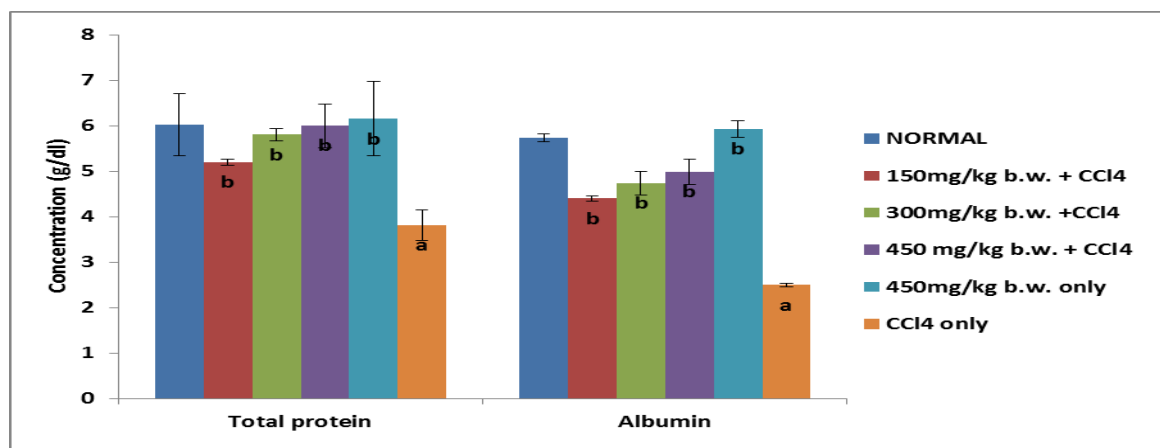


Figure 2: Effect of EECR leaves on CCl₄ - induced changes in plasma total protein and albumin levels.

Values are expressed as Mean \pm SEM (n = 5)

^ap<0.05 when compared with normal group

^bp<0.05 when compared with CCl₄ only

Figure 3 shows the effect of ethanolic extract of the leaves of *Crasocephalum rubens* on CCl₄ - induced changes in liver lipid peroxidation product (MDA), Superoxide dismutase (SOD) and Catalase (CAT). Malondialdehyde (MDA), an index of lipid peroxidation was significantly increased by the administration of CCl₄ when compared with normal control group (p<0.05). The induced peroxidation due to this increase was prevented by pretreatment with EECR leaves at 150 mg/kg b.w., 300 mg/kg b.w. and 450 mg/kg b.w. doses. Treatment with 450mg/kg b.w. leaves extract produced a non significant difference in the MDA level when compared with the normal group. Liver antioxidant marker enzymes (SOD and Catalase) activities on administration of CCl₄ on rats were significantly reduced when compared with normal control group (p<0.05). Pretreatment with EECR leaves at all the three doses gave a significant increase in their activities when compared with the toxicant group. Treatment with 450 mg/kg b.w. produced a non significant difference in the enzymes activities when compared with the normal control group. Pre-treatment doses did not show any significant difference in the activities of these enzymes except in the MDA level where a significant difference was observed at 150 mg/kg b.w. relative to 300 mg/kg and 450 mg/kg b.w. groups.

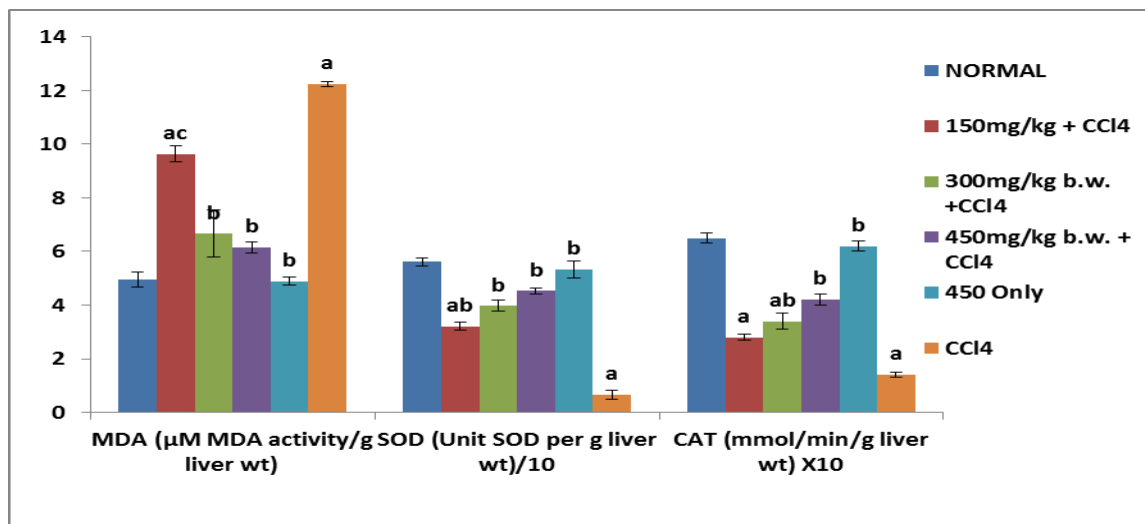


Figure 3: Effect of ethanolic extract of the leaves of *C. rubens* on CCl_4 - induced changes in Plasma MDA, SOD and Catalase.

Values are expressed as Mean \pm SEM (n = 5)

^ap<0.05 when compared with normal group

^bp<0.05 when compared with CCl_4 only

^cp<0.05 comparison among different doses of extract

Histopathology of the Liver

Histopathological examination of the liver sections from normal and 450 mg/kg EECR alone groups show no significant lesions (plate 1 (a and e)). The liver of rats pretreated with 150 mg/kg of EECR showed mild steatosis and inflammation (plate 1 (b)). With 300 mg/kg EECR pretreatment, lymphatic filtration was observed (plate 1 (c)). Pretreatment of rats with 450 mg/kg EECR showed multiple focal areas of granulation and mild steatosis (plate 1 (d)). In rats treated with CCl_4 only, multiple foci of hepatocellular necrosis with cellular infiltration by lymphocytes and macrophages was seen (plate 1 (f)).

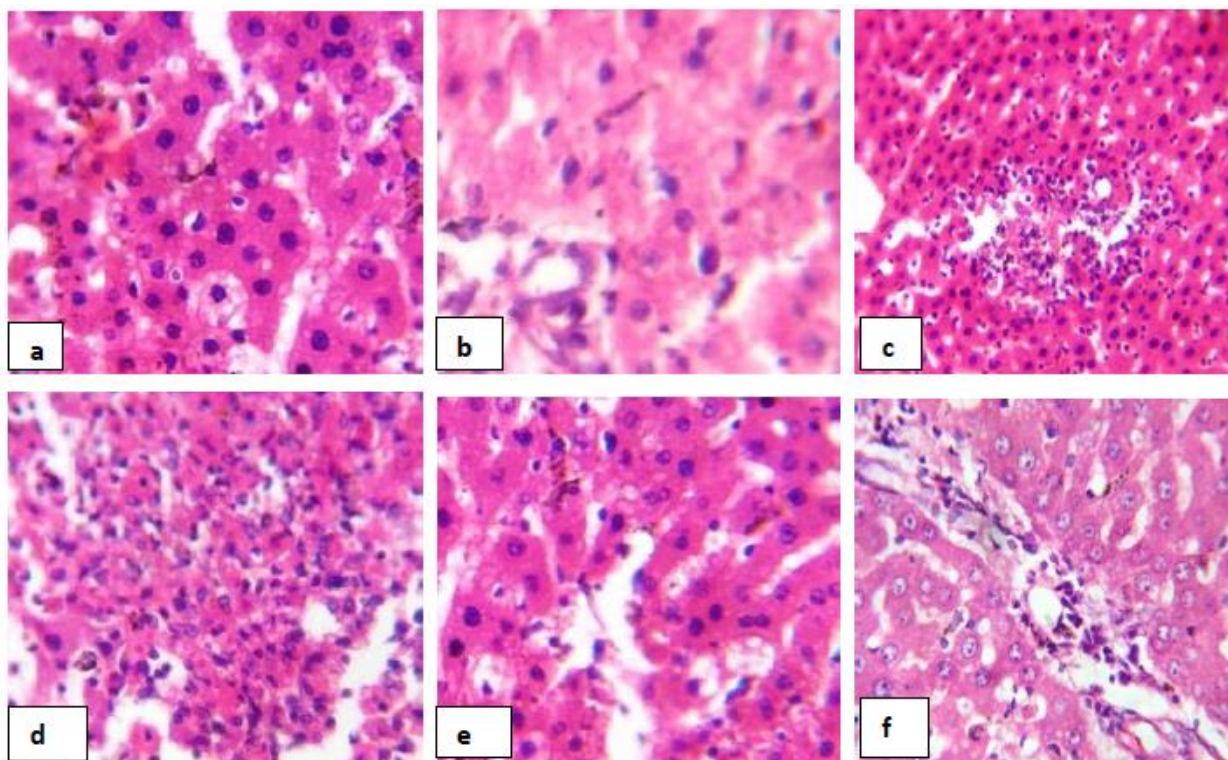


Plate 1: Histopathological results (x 400): a. Normal control; b. 150 mg/kg EECR + CCl₄; c. 300 mg/kg EECR + CCl₄; d. 450 mg/kg EECR + CCl₄; e. 450 mg/kg EECR only; f. CCl₄ only (negative control)

DISCUSSION

Carbon tetrachloride toxicity is an established model for the evaluation of hepatic damage.^[16-18] The toxic effect of CCl₄ manifested as markedly elevated levels of the enzymes ALT, AST, ALP and γ -GT. This is clearly indicative of cellular damage and loss of architectural and functional integrity of the membrane. Plasma levels of ALT and AST was shown to be crucial parameters in the diagnosis of liver damage.^[19] Damage to liver cells results in the leakage of intracellular enzymes into plasma, thus raising plasma concentration of such enzymes as observed in this study. Increased activities of plasma ALP may be due to its increased synthesis as a result of biliary obstruction as seen in cholestatic disease of the liver. GGT is a membrane-bound enzyme and a raised level in plasma is an indicator of cell or tissue damage.^[20]

It was reported that serum transaminases returned to normal activities with the healing of hepatic parenchyma and regeneration of hepatocytes.^[21] This effect may be an indication that EECR leaves offer protection against CCl₄ toxicity probably by protecting the structural and

functional status of hepatocytes, with preservation of cellular architecture and by stabilizing the cell membrane.

The administration of CCl₄ adversely interferes with protein metabolism probably by inhibiting the synthesis of proteins such as albumin.^[22] In consonance with previous studies,^[23-25] the present study showed that CCl₄ induced significant decrease in the plasma total protein content. Thus, a decline in total protein could be seen as a useful index of the severity of cellular dysfunction in chronic liver diseases. It was reported by Lin *et al.*^[26] that an increase in the levels of plasma total protein and albumin, as observed in this study, is an indication of the stabilization of plasma membranes as well as repair of hepatic tissue damage caused by CCl₄.

Lipid peroxidation of polyunsaturated fatty acids forms products such as MDA, which is regarded as a cancer-promoting substance.^[27] CCl₄ treatment increased tissue MDA content, as previously reported by some researchers.^[28-30] They attributed the increase in MDA levels to enhanced lipid peroxidation, thereby leading to tissue damage. Also, to the failure of antioxidant defense mechanisms to prevent the formation of excessive free radicals. This then alters the ratio of polyunsaturated to other fatty acids, thus, leading to a decrease in membrane fluidity, which may be sufficient to cause cell death.^[31] CCl₄ administration also resulted in an increase mobilization of antioxidant enzymes: Superoxide dismutase (SOD) and catalase (CAT), which ultimately led to their depletion.^[28] SOD and CAT have been reported to be the major antioxidant defense components that catalyze the dismutation of superoxide radical (O₂⁻) to H₂O₂ and decomposition of H₂O₂ to H₂O, respectively.^[32-34] It could be deduced, therefore, that the prevention in the formation of free radicals by EECR leaves can be as a result of the antioxidant potential of the plant. This can be linked to the mechanism of hepatoprotection by antioxidants.

The present results of biochemical alterations were insured by histopathological examination of the liver in the intoxicated rats, which revealed degenerative and necrotic changes. This is evident that the leaves extract of *C. rubens* showed excellent protection on CCl₄-induced tissue damage. The study provided preliminary information on the safety profile of the extract and evidence on the potency of the leaves of *C. rubens* as a hepatoprotective agent. More studies are however needed to investigate the effect of the plant on the kidney and other tissues.

CONCLUSION

It can be concluded that ethanolic extract of the leaves of *Crasocephalum rubens* possess antioxidant and medicinal values, sufficient to protect against CCl₄-induced hepatotoxicity in Wistar rats. Thus, this may be traceable to the presence of phytochemicals such as flavonoids and phenolic compounds inherent in the plant.

REFERENCES

1. Selvakumar K, Madhan R, Srinivasan G, Baskar V. Antioxidant Assays in Pharmacological research. *Asian J Pharm Tech.*, 2011; 1: 99-103.
2. Kohen R, Nyska A. Oxidation of biological systems: oxidative stress phenomenon, antioxidants, redox reaction and methods for their quantification. *Toxicol pathology.*, 2002; 30: 620-630.
3. Lee KJ, You HJ, Parks J, Kim YS, Chung VC, Jeong TC, Jeong HG. Hepatoprotective effect of flatycodon grandiflorum on acetaminophen-induced liver damage in mice. *Cancer Letters.*, 2001; 174: 73-81.
4. Ohata Y, Nikida K, Sasaki E, Kongo M, Ishiguro I. Attenuation of disrupted hepatic active oxygen metabolism with the recovery of acute liver injury in rats intoxicated with carbon tetrachloride. *Res Commun Mol Pathol Pharmacol.*, 1997; 95: 197-201.
5. Ozturk F, Ucar M, Ozturk IC, Vardi N, Batcioglu K. Carbon tetrachloride-induced nephrotoxicity and protective effect of betaine in Sprague-Dawley rats. *Urology.*, 2003; 62(2): 353-356.
6. Khan MR, Ahmed D. Protective effects of *Digera muricata* (L.) Mart. on testis against oxidative stress of carbon tetrachloride in rat. *Food Chem Toxicol.*, 2009; 47: 1393-1399.
7. Khan MR, Rizvi W, Khan GN, Khan RA, Shaheen S. Carbon tetrachloride - induced nephrotoxicity in rat: protective role of *Digera muricata*. *J Ethnopharmacol.*, 2009; 122(1): 91-99.
8. Taylor JLS, Rabe T, McGaw LJ, Jager AK, Van Staden J. Towards the scientific validation of traditional medicinal plants. *Plants growth Regul.*, 2001; 34: 23-27.
9. Adjatin AA, Dansi CS, Eze P, Assogba I, Dossou-Aminon K, Akpagana A, Akoegninou, Sanni A. Ethanobotanical investigation and diversity of Gbolo [*Crasocephalum rubens* (Juss. Ex Jacq). S. Moore and *C.crepidioides* (Benth) S. Moore], a traditional leafy vegetable under domestication in Benin. *Genet. Resour Crop Evol.*, 2012; 59(8): 1867-1881.

10. Okwu DE. Phytochemicals, vitamins and mineral contents of two Nigeria medicinal plants. *Int J Mole Medi Advan Sci.*, 2005; 1(4):375-381.
11. Omoregie ES, Osagie AU, Iruolaje EO. *In vitro* antioxidant activity and the effect of methanolic extracts of some local plants on nutritionally stressed rats. *Pharmacologyonline.*, 2011; 1: 23-56.
12. Vashney R, Kale RK. Effect of calmodulin antagonists on radiation induced lipid peroxidation in microsomes. *Int J Radiat Biol.*, 1990; 58: 733–743.
13. Sinha KA. Colorimetric assay of catalase. *Anal Biochem.*, 1972; 47: 389-394.
14. Misra HP, Fridovich I. The generation of Superoxide radical during the antioxidant of hemoglobin. *J Biol Chem.*, 1972; 247: 6960-6962.
15. Zar JH. Multisample hypotheses: The analysis of variance: Biostatistical Analysis. 2nd ed., Englewood Cliffs, NJ Prentice-Hall, Inc., 1984, pp. 162-184.
16. Yun JW, Kim CW, Bae IH. Determination of the key innate genes related to individual variation in carbon tetrachloride-induced hepatotoxicity using a pre-biopsy procedure. *Toxicol Appl Pharmacol.*, 2009; 239(1): 55–63.
17. Adesanoye OA, Farombi EO. Hepatoprotective effects of *Vernonia amygdalina* (astereaceae) in rats treated with carbon tetrachloride. *Exp Toxicol Pathol.*, 2010; 62(2): 197–206.
18. Coballase-Urrutia E, Pedraza-Chaverri J, C´ardenas-Rodríguez N. Hepatoprotective effect of acetonc and methanolic extracts of *Heterotheca inuloides* against CCl₄- induced toxicity in rats. *Exp Toxicol Pathol.*, 2011; 63(4): 363–370.
19. Williamson EM, Okpako DT, Evans FJ. Selection, preparation and pharmacological evaluation of plant material. John Wiley, England: 1996, pp 13.
20. Vasudha KC, Nirmal KA, Venkatesh T. Studies on the age dependent changes in serum adenosine deaminase activity and its changes in hepatitis. *Indian J Clin Biochem.*, 2006; 21: 116-120.
21. Thebrew M, Joice PA. Comparative study of the efficacy of *Pavetta indica* and *Osbeckia octanda* in the treatment of liver dysfunction. *Planta Med.*, 1987; 53: 239-241.
22. Iniaghe OM, Malomo SO, Adebayo JO. Hepatoprotective effect of the aqueous extract of leaves of *Acalypha racemosa* in carbon tetrachloride treated rats. *J Med Plants Res.*, 2008; 2(10): 301-305.
23. Wang FR, Ai H, Chen XM, Lei CL. Hepatoprotective effect of a protein-enriched fraction from the maggots (*Musca domestica*) against CCl₄-induced hepatic damage in rats. *Biotechnol Lett.*, 2007; 29(6): 853-858.

24. Koneri R, Balaraman R, Firdous-Vinoth KM. Hepatoprotective effects of *Momordica cymbalaria* Fenzl. against carbon tetrachloride - induced hepatic injury in rats. *Pharmacologyonline.*, 2008; 1: 365-374.
25. Hedge K, Joshi AB. Hepatoprotective effect of *Carissa carandas* Linn root extract against CCl₄ and paracetamol induced hepatic oxidative stress. *Indian J Exp Biol.*, 2009; 47(8): 660-667.
26. Lin HM, Tseng HC, Wang CJ, Lin JJ, Lo CW, Chou FP. Hepatoprotective effects of *Solanum nigrum* Linn extract against CCl₄-induced oxidative damage in rats. *Chemico-Biological Interactions.*, 2008; 171(3): 283–293.
27. Sehwat A, Sultana S. Chemoprevention by *Butea monosperma* of hepatic carcinogenesis and oxidative damage in male Wistar rats. *Asian Pac J Cancer Prev.*, 2006; 7: 140-148.
28. Cetin E, Kanbur M, Cetin N, Eraslan G, Atasever A. Hepatoprotective effect of ghrelin on carbon tetrachloride-induced acute liver injury in rats. *Regul Pept.*, 2011; 171(1-3):1-5.
29. Shenoy KA, Somayaji SN, Bairy KL. Hepatoprotective effects of *Ginkgo biloba* against carbon tetrachloride - induced hepatic injury in rats. *Ind J Pharmacol.*, 2001; 33: 260-266.
30. Patrick-Iwuanyanwu KC, Wegwu MO, Okiyi JK. Hepatoprotective Effects of African Locust Bean (*Parkia clappertoniana*) and Negro Pepper (*Xylopia aethiopica*) in CCl₄-Induced Liver Damage in Wistar Albino Rats. *Int J Pharmacology.*, 2010; 6: 744-749.
31. Rotruck JT, Pope AL, Ganther H, Awanson AB, Haffeman DG, Hofekstra WG. Selenium: Biochemical role as a component of glutathione peroxides. *Science.*, 1979; 179: 588-590.
32. Cheng LE, Kellog W, Palker L. Photoactivation of catalase. *Photochem Photobiol.*, 1981; 34: 125-129.
33. McCord JM, Fridovich I. Superoxide dismutase, an enzymic function for erythrocyte (hemocuprein). *J Biol Chem.*, 1969; 244: 6049-6055.