


# Ocimum gratissimum Ameliorates Gentamicin-Induced Kidney Injury but Decreases Creatinine Clearance Following Sub-Chronic Administration in Rats

Journal of Evidence-Based  
Complementary & Alternative Medicine  
2017, Vol. 22(4) 592-602  
© The Author(s) 2017  
Reprints and permission:  
[sagepub.com/journalsPermissions.nav](http://sagepub.com/journalsPermissions.nav)  
DOI: 10.1177/2156587217691891  
[journals.sagepub.com/home/cam](http://journals.sagepub.com/home/cam)  


Dare J. Ogundipe, BTech, MSc<sup>1</sup>, Rufus O. Akomolafe, BSc, MSc, PhD<sup>1</sup>,  
Abubakar A. Sanusi, MbChB, MD, FWACP<sup>1</sup>, Christian E. Imafidon, BSc, MSc<sup>1</sup>,  
Olaoluwa S. Olukiran, BTech, MSc<sup>1</sup>, and Ayowole A. Oladele, BMLS, MSc, PhD<sup>2</sup>

## Abstract

The effects of aqueous extract of *Ocimum gratissimum* leaf (AOGL) on the renal function of rats with gentamicin-induced nephrotoxicity were investigated. This study involved the use of forty five (45) adult male Wistar rats (housed in separate metabolic cages) such that graded doses of OAGL were administered to the experimental groups (p.o.) for 28 days after exposure to gentamicin toxicity (100 mg/kg i.p.) for 1 week. At the end of the study, comparisons of some indices of renal function as well as antioxidant status (GSH and TBARS) were made between the control, toxic and AOGL-treated groups at  $P < 0.05$ . The result showed that gentamicin treatment caused significant increase ( $P < .05$ ) in urine output, urea, creatinine, total protein, relative kidney weight, and TBARS, as well as significant decrease ( $P < .05$ ) in urine creatinine and GSH levels. Post-treatment with graded doses of AOGL caused significant increase in food consumption, GSH, urine, and plasma creatinine, as well as significant decrease ( $P < .05$ ) in relative kidney weight, TBARS, and urine total protein. There was an appreciable difference in the kidney histology of the AOGL-treated groups when compared with the toxic control. Hence, the extract has therapeutic potential in the management of gentamicin-induced kidney injury, although a risk profile of renal dysfunction is not unlikely from 28 days of administration as evident by the decrease in creatinine clearance.

## Keywords

*Ocimum gratissimum*, gentamicin, creatinine, TBARS, rats

Received May 16, 2016. Received revised December 16, 2016. Accepted for publication January 7, 2017.

Nephrotoxicity is an associated limitation for the clinical use of gentamicin, a potent gram-negative antibiotic.<sup>1</sup> Renal injury following gentamicin administration results from the inhibition of protein synthesis by renal cells, causing these cells to become necrotic in the proximal tubules.<sup>2</sup> Consequently, renal inflammation, tubular necrosis, and glomerular damage are the major events implicated in gentamicin nephrotoxicity.<sup>3,4</sup>

*Ocimum gratissimum*, an herbaceous plant belonging to the *Labiatae* family, is common in West Africa and India, which are tropical areas. It is widely cultivated in Nigeria, South Sea Islands, as well as Deccan and Nepal.<sup>5</sup> In Nigeria, this plant is known by several vernacular names such as “effirin-nla,” “Ahuji,” and “Daidoya” by the Yoruba-, Igbo-, and Hausa-speaking tribes, respectively.<sup>6</sup> It has found its relevance in traditional system of medicine and has been evaluated for its

anti-epilepsy and antidiarrhea properties as well as abating high fever.<sup>6</sup> Because the leaves and flowers of *Ocimum gratissimum* are rich in essential oils, which are reputed for their therapeutic value, this plant is used to prepare traditional tea and infusions.<sup>7</sup> Other medicinal values include, but are not limited to, preparation of decoctions for the treatment of mental illness<sup>8</sup> as well as treatment of fungal infections, cold, and catarrh.<sup>9</sup>

<sup>1</sup> Obafemi Awolowo University, Ile-Ife, Osun State, Nigeria

<sup>2</sup> Afe Babalola University, Ado-Ekiti, Ekiti State, Nigeria

## Corresponding Author:

Olaoluwa S. Olukiran, Department of Physiological Sciences, Obafemi Awolowo University, Ile-Ife A234, Nigeria.  
Email: [oololuwasesan@gmail.com](mailto:oololuwasesan@gmail.com)



Regardless of the apparently vast medicinal properties of *Ocimum gratissimum*, till date, available scientific data are inadequate to infer the nephrocurative and or nephrotoxic potentials of this plant in models of drug-induced kidney injury. Therefore, this study aimed at contributing to the body of existing knowledge by studying the effects of 28 days of administration of aqueous extract of *Ocimum gratissimum* leaf (AOGL) on the renal function of Wistar rats with gentamicin-induced kidney injury.

## Materials and Methods

### Drugs

Gentamicin injection 80 mg/2 mL was purchased from Shanxi Shuguang Pharmaceutical Co (Jinzhong, China), while the metabolic cages used for this study were fabricated by Central Technological Laboratory and Workshops, Obafemi Awolowo University, Ile-Ife, Nigeria.

### Extraction Process

Leaves of *Ocimum gratissimum* were collected, washed, air dried under shade, and ground into fine powder using a blender. The aqueous extract was prepared by macerating the powdered leaves (323 g) with 3 L of distilled water in an electric shaker for 48 hours. The extract was filtered through Whatmann No. 1 paper (Whatmann International Ltd, Maidstone, England) and evaporated under reduced pressure using a rotary evaporator. The yield (33.60 g) was kept in a bottle with a tight-fitting cover until it was needed for the study.

$$\text{Extraction yield in \%} = 33.60/323 \times 100 = 10.4\%$$

### Animal Care and Management

Forty-five adult male Wistar rats weighing 150 to 200 g were used for this study. They were obtained from the Animal Holdings of the College of Health Sciences, Obafemi Awolowo University, Ile-Ife, and were housed in plastic cages. The rats were kept under natural light/dark cycle and had access to standard rodent pellet diet (Caps Feed PLC, Osogbo, Nigeria) and water ad libitum. They were allowed to acclimatize in the laboratory for 2 weeks before the commencement of the study.

### Experimental Design

The rats were divided into 5 groups as follows: Group 1 (control) consisting of 5 rats received 2 mL/kg/day of distilled water via oral route for the study period. Twenty-four hours after final administration, the rats were euthanized. Group 2 (toxic) consisted of 10 rats, each of which received 100 mg/kg/day of gentamicin (intraperitoneal) for a week and thereafter left untreated (without AOGL) for 4 weeks. Five rats each were sacrificed a day after the final gentamicin administration as well as after 14 days of recovery period. Groups 3, 4, and 5 consisted of 10 rats each that were pretreated with gentamicin as group 2 and thereafter received graded doses of AOGL at 100, 200, and 400 mg/kg/day per os, respectively, for 28 days. Five rats from each group were sacrificed a day after the last dose of AOGL, while the remaining 5 rats were left for a 14-day recovery period. Creatinine clearance was calculated for all groups using the conventional formula:

$$C = U \times V/P$$

where C = clearance, U = urine creatinine, V = urine flow rate (volume of urine/time), and P = plasma creatinine.

### Assessment of Body Weight

This was carried out weekly with the aid of a digital weighing scale (Camry, Zhongshan, China).

### Assessment of Food Consumption, Water Intake, and Urine Volume

This was carried out with the aid of metabolic cages. The food consumption and water intake were determined by taking the difference between the previous weight/volumes and the leftover food after 24 hours. The value obtained was taken as the daily food consumption/water intake for each rat in the different groups.

The volumes of water taken and urine excreted by each rat were measured with a measuring cylinder, while food consumption was measured with the aid of a digital weighing scale (Camry, China).

### Biochemical Assay

Blood obtained after the rats were euthanized was collected into separate ethylenediaminetetraacetic acid bottles and centrifuged at 4000 rpm for 15 minutes using Cold Centrifuge (Model 8881, Centurion Scientific, West Sussex, England). The resulting plasma was analyzed for some biochemical indices of renal function. The urine samples were similarly subjected to the same procedure.

### Plasma Creatinine and Urea

Using a colorimetric method,<sup>10</sup> the plasma creatinine and urea concentrations were estimated using the laboratory protocol outlined by the manual provided in the Randox standard laboratory kit.

### Urine Creatinine and Urea

Urine samples were diluted with distilled water using 1 in 50. Thereafter, 0.1 mL of the diluted urine was pipette into the test tube for the aforementioned colorimetric method for creatinine and urea determination.

### Protein Determination

Protein determination was carried out according to the method of Lowry et al<sup>11</sup> as described by Holme and Peck.<sup>12</sup>

### Assessment of Antioxidant Status

Each carefully excised left kidney was weighed and homogenized with 10 mL of sucrose solution (0.25 M) using Electric Homogenizer (SI601001). The homogenate was centrifuged at 3000 rpm for 20 minutes and the supernatant was collected for the assessment of reduced glutathione (GSH) as well as thiobarbituric acid reactive substance (TBARS) levels.

**Table 1.** Effects of Aqueous Extract of *Ocimum gratissimum* on Food Consumption (g) and Body Weight (g) of Rats with Gentamicin-Induced Nephrotoxicity.

	Control	Toxic	Toxic Recovery	100 mg/kg AOGL	200 mg/kg AOGL	400 mg/kg AOGL
<b>Food consumption (g)</b>						
Baseline	17.60 ± 0.96	27.00 ± 2.00	14.25 ± 0.76	12.25 ± 1.65	14.50 ± 2.21	15.60 ± 1.69
Gentamicin treatment	24.00 ± 1.68	33.60 ± 5.27	15.50 ± 1.55	16.50 ± 1.70	17.80 ± 2.79	19.00 ± 1.29
28 days treatment	23.20 ± 0.96	—	28.75 ± 1.25*†	30.00 ± 0.91*†	34.00 ± 3.02*†	34.60 ± 2.29*†
14 days recovery	18.20 ± 0.66	—	—	28.75 ± 1.25*†	31.00 ± 1.87*†	32.00 ± 2.55*†
<b>Body weight (g)</b>						
Baseline	204.0 ± 3.55	188.0 ± 12.41	94.00 ± 1.73	98.00 ± 3.86	117.4 ± 9.05	92.20 ± 4.34
Gentamicin treatment	212.6 ± 3.89	195.6 ± 11.74	103 ± 2.12	102.5 ± 4.78	122.2 ± 8.59	101.80 ± 5.29
28 days treatment	239.8 ± 5.56*†	—	173.3 ± 5.39*†	184.0 ± 10.46*†	194.2 ± 7.55*†	171.0 ± 5.16*†
14 days recovery	264.0 ± 3.67*†	—	—	200.0 ± 2.25*†	199.0 ± 9.67*†	178.0 ± 6.04*†

Abbreviation: AOGL, aqueous extract of *Ocimum gratissimum* leaf.

\*Shows significant difference compared to the baseline at  $P < .05$ .

†Shows significant difference compared to the gentamicin treatment at  $P < .05$ .

**Table 2.** Effects of Aqueous Extract of *Ocimum Gratissimum* on Water Intake (mL) and Urine Volume (mL) of Rats With Gentamicin-Induced Nephrotoxicity.

	Control	Toxic	Toxic Recovery	100 mg/kg AOGL	200 mg/kg AOGL	400 mg/kg AOGL
<b>Water intake (mL)</b>						
Baseline	31.00 ± 2.12	17.40 ± 2.16	8.75 ± 0.75	9.400 ± 0.60	11.20 ± 0.97	11.60 ± 1.86
Gentamicin treatment	30.60 ± 9.51	13.00 ± 0.95	13.80 ± 1.59	15.00 ± 1.92	16.60 ± 2.38	23.60 ± 2.75
28 days treatment	32.40 ± 3.42	—	23.25 ± 1.03*	32.67 ± 5.60*†	54.80 ± 1.07*†	45.75 ± 6.27*†
14 days recovery	27.10 ± 2.59	—	—	12.00 ± 1.08	17.75 ± 3.22	15.50 ± 2.02
<b>Urine volume (mL)</b>						
Baseline	9.20 ± 1.02	6.00 ± 0.89	5.00 ± 0.45	3.90 ± 0.58	3.90 ± 0.43	4.50 ± 0.54
Gentamicin treatment	11.30 ± 0.95	9.50 ± 0.80*	9.75 ± 0.82*	7.60 ± 0.37*	7.00 ± 1.19*	8.10 ± 1.22*
28 days treatment	8.30 ± 1.55	—	5.12 ± 0.42†	5.00 ± 1.00	9.00 ± 1.52	4.83 ± 1.64
14 days recovery	8.12 ± 216	—	—	7.50 ± 0.96*	7.16 ± 1.01	4.00 ± 0.54

Abbreviation: AOGL, aqueous extract of *Ocimum gratissimum* leaf.

\*Shows significant difference compared to the baseline at  $P < .05$ .

†Shows significant difference compared to the gentamicin treatment at  $P < .05$ .

### Estimation of Reduced Glutathione and Thiobarbituric Acid Reactive Substance (TBARS) in the Kidney Homogenate

GSH was measured by the method of Beutler et al,<sup>13</sup> while TBARS was determined by the method of Ohkawa et al.<sup>14</sup>

### Histopathological Examination

After rats were sacrificed, their right kidneys were carefully excised, weighed, and fixed in 10% formo-saline solution. Thereafter, the tissues were embedded in paraffin wax, sectioned, and stained using hematoxylin and eosin.

### Statistical Analysis

The results obtained were expressed as mean ± SEM. The data were analyzed using one-way analysis of variance followed by Neumann-Keuls post hoc test with the aid of GraphPad prism (GraphPad Software Inc, La Jolla, CA) statistical package. The results were considered significant when  $P < .05$ .

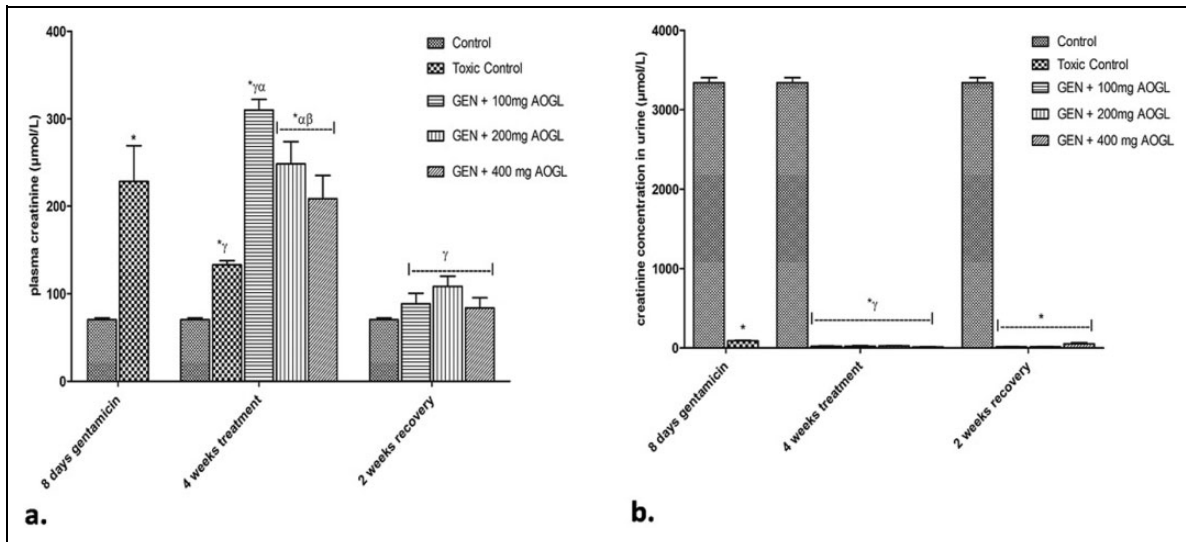
## Results

### Food Consumption and Body Weight

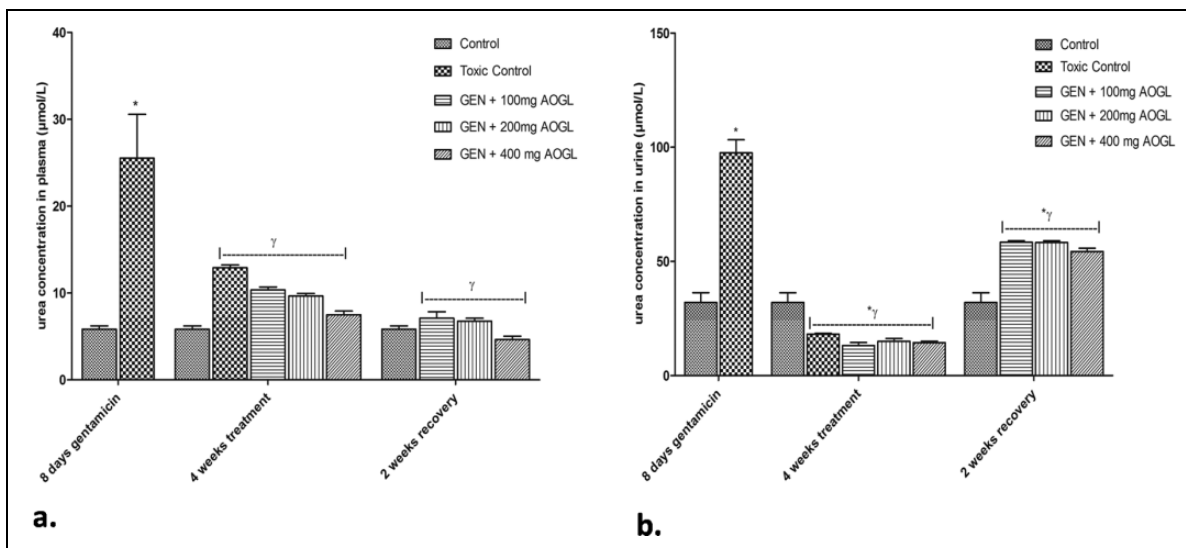
Insignificant increase in food consumption and body weight were observed in the toxic group when compared with their pretreatment values (Table 1). However, the food consumption and body weight of the toxic recovery group increased significantly ( $P < .05$ ) when compared with both its pretreatment values and values obtained during gentamicin administration. The food consumption and body weight of the AOGL-treated groups and those that were left for a 2-week recovery period were significantly higher ( $P < .05$ ) when compared with their pretreatment values and values obtained during gentamicin administration (Table 1).

### Water Intake and Urine Volume

A significant increase ( $P < .05$ ) in urine volume was observed in the toxic group without a corresponding increase in water intake when compared with its pretreatment value (Table 2).



**Figure 1.** Effects of AOGL on plasma and urine creatinine level of Wistar rats with gentamicin-induced nephrotoxicity. \*Shows significant difference compared to the control at  $P < .05$ . <sup>γ</sup>Shows significant difference compared to the toxic control group at  $P < .05$ . <sup>α</sup>Shows significant difference compared to the toxic recovery group at  $P < .05$ .



**Figure 2.** Effects of AOGL on plasma and urine urea levels of Wistar rats with gentamicin-induced nephrotoxicity. \*Shows significant difference compared to the control at  $P < .05$ . <sup>γ</sup>Shows significant difference compared to the toxic control group at  $P < .05$ .

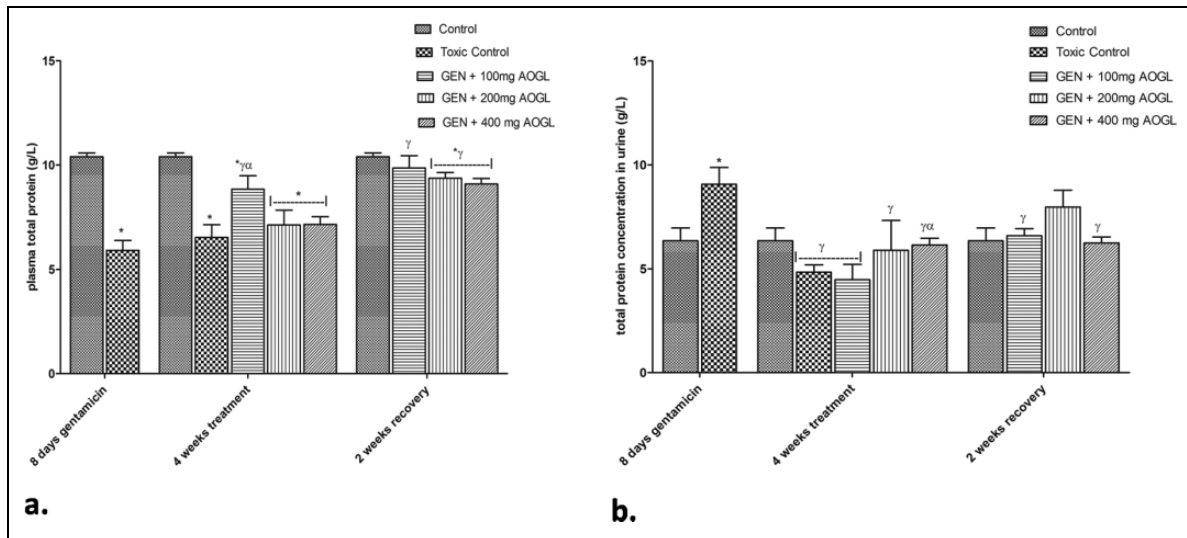
However, the water intake of the AOGL-treated groups increased significantly ( $P < .05$ ) without a corresponding increase in urine output when compared with their pretreatment values. No significant difference was observed in the water intake and urine volume of rats that were allowed a 2-week recovery period when compared with their pretreatment values (Table 2).

**Plasma and Urine Level of Creatinine, Urea, and Total Protein**

The plasma creatinine and urea levels of the toxic group were significantly higher ( $P < .05$ ) than that of the control group

(Figures 1 and 2). Similarly, the toxic recovery group recorded a significantly higher ( $P < .05$ ) plasma creatinine when compared with the control but this was significantly lower when compared with the toxic group. A significantly higher ( $P < .05$ ) plasma creatinine concentration was observed in the AOGL-treated groups when compared with the control but no significant difference was shown at the 2-week recovery period (Figure 1a). The plasma creatinine concentration of 100 mg/kg/day AOGL-treated group was significantly higher ( $P < .05$ ) than that of the toxic group as well as other treated groups (Figure 1a).

There was no significant difference observed in the plasma urea of the AOGL-treated groups when compared with those



**Figure 3.** Effects of AOGL on plasma and urine total protein levels of Wistar rats with gentamicin-induced nephrotoxicity. \*Shows significant difference compared to the control at  $P < .05$ . <sup>γ</sup>Shows significant difference compared to the toxic control group at  $P < .05$ . <sup>α</sup>Shows significant difference compared to the toxic recovery group at  $P < .05$ .

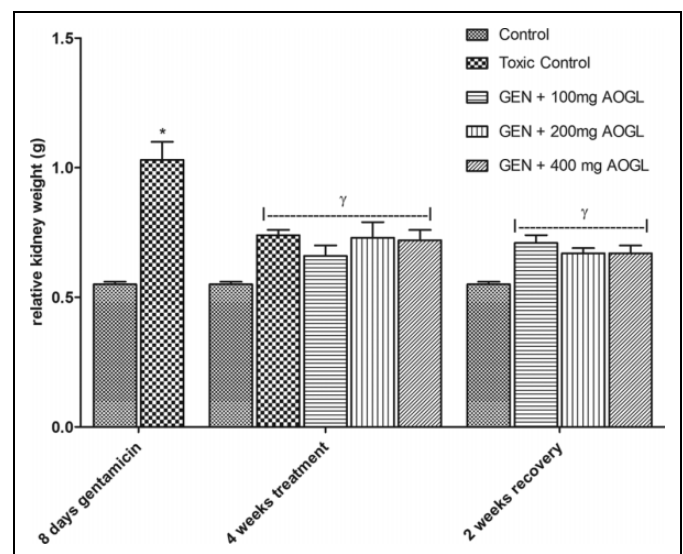
that were left for the 2-week recovery period as well as with the control (Figure 2).

The plasma total protein concentration of the toxic group and AOGL-treated groups were significantly lower ( $P < .05$ ) than that of the control. The plasma total protein concentration of rats that received 100 mg/kg/day of AOGL were significantly higher ( $P < .05$ ) than that of the toxic group and other AOGL-treated groups. At 2-week recovery period, the toxic recovery group had significantly lower ( $P < .05$ ) plasma total protein concentration when compared with the control and the AOGL-treated groups (Figure 3).

The urine creatinine concentration of the toxic group, AOGL-treated groups, as well as the 2-week recovery groups were significantly lower ( $P < .05$ ) when compared with the control (Figure 1b). The toxic group had significantly higher urine total protein and urea concentrations when compared with the control (Figures 3b and 2b, respectively). Urine urea concentration of the toxic recovery group, AOGL-treated groups, and 2-week recovery group were significantly higher ( $P < .05$ ) when compared with that of the control but was significantly lower than that of the toxic group (Figure 2b). However, the urine total protein concentrations of the AOGL-treated groups and 2-week recovery group showed no significant difference when compared with the control (Figure 3b). The AOGL-treated groups as well as the 2-week recovery groups showed a significant decrease ( $P < 0.05$ ) in urine concentrations of urea when compared with that of the toxic control (Figure 2b).

### Relative Kidney Weight, TBARS, and GSH

A significant increase ( $P < 0.05$ ) in the relative kidney weight was observed in the toxic group when compared with the control. The relative kidney weight of the toxic recovery group,

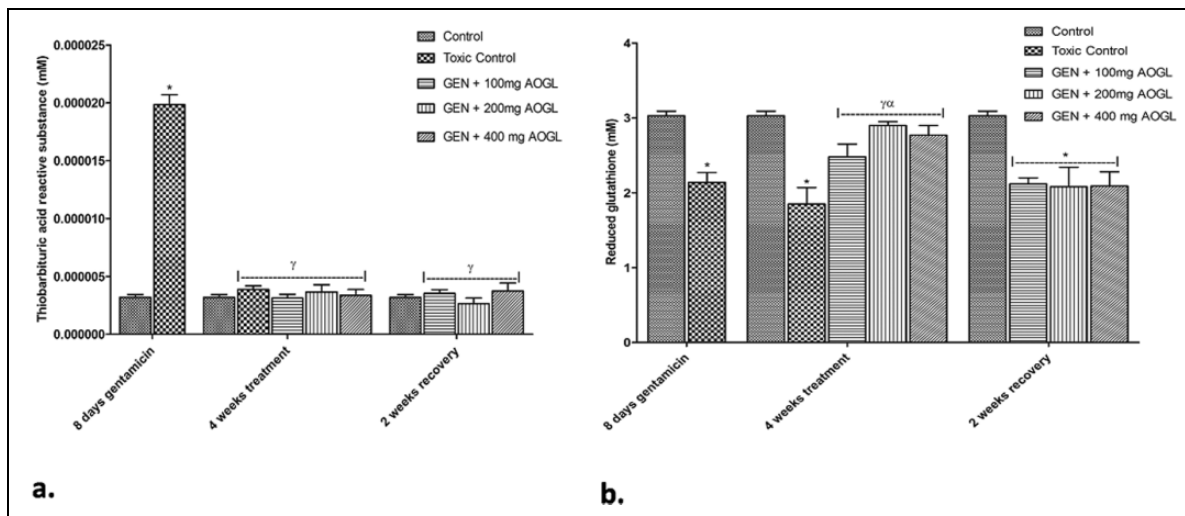


**Figure 4.** Effects of AOGL on relative kidney weight of Wistar rats with gentamicin-induced nephrotoxicity. \*Shows significant difference compared to the control at  $P < .05$ . <sup>γ</sup>Shows significant difference compared to the toxic control group at  $P < .05$ .

AOGL-treated groups, and the 2-week recovery group was not significantly different from that of the control (Figure 4).

The TBARS level of the toxic group showed a significant increase ( $P < 0.05$ ) when compared with the control. The TBARS levels of the toxic recovery group, AOGL-treated groups, and the 2-week recovery group were significantly lower ( $P < 0.05$ ) than that of the toxic group at the end of the study (Figure 5).

The toxic and toxic recovery groups had significantly lower GSH levels ( $P < .05$ ) when compared with the control. On the other hand, the GSH levels of the AOGL-treated groups showed significant increase ( $P < .05$ ) in kidney GSH level when



**Figure 5.** Effect of AOGL on TBARS and GSH levels of Wistar rats with gentamicin-induced nephrotoxicity.

\*Shows significant difference compared to the control at  $P < .05$ . <sup>γ</sup>Shows significant difference compared to the toxic control group at  $P < .05$ .

**Table 3.** Effects of Aqueous Extract of *Ocimum gratissimum* on Creatinine Clearance (mL/min) of Rats With Gentamicin-Induced Nephrotoxicity.

	Control	Toxic	Toxic Recovery	100 mg/kg AOGL	200 mg/kg AOGL	400 mg/kg AOGL
Creatinine clearance (mL/min)						
28 days treatment	53.70 ± 13.60	9.07 ± 0.50*	1.41 ± 0.26*†	0.81 ± 1.83*†	0.92 ± 0.99*†	0.39 ± 0.33*†
14 days recovery	53.70 ± 13.60	9.07 ± 0.50*	1.41 ± 0.26*†	2.03 ± 0.52* <sup>γ</sup>	1.68 ± 1.55*†	4.99 ± 2.51*

Abbreviation: AOGL, aqueous extract of *Ocimum gratissimum* leaf.

\*Shows significant difference compared to the baseline at  $P < .05$ .

†Shows significant difference compared to the gentamicin treatment at  $P < .05$ .

compared with the toxic group. However, at 2 weeks of recovery period there was no significant difference ( $P < .05$ ) in GSH levels of the AOGL-treated groups as well as the toxic recovery group when compared with the control (Figure 5).

### Creatinine Clearance

A significant decrease ( $P < .05$ ) in creatinine clearance was observed in the toxic and AOGL-treated groups when compared with the control (Table 3). The creatinine clearance of the AOGL-treated groups was significantly lower ( $P < .05$ ) than that of the toxic group. At the 2-week recovery period, the toxic recovery group and AOGL-treated groups had significantly lower ( $P < .05$ ) creatinine clearance when compared with the control (Table 3). Also, the AOGL-treated groups showed a significantly lower ( $P < .05$ ) creatinine clearance when compared with the toxic recovery group except for rats that received 400 mg/kg of AOGL, which showed no significant difference from the toxic recovery group (Table 3).

### Histopathological Examination

The control group shows evidence of intact renal corpuscles with normal appearing glomeruli and tubules, including the proximal convoluted tubule and distal convoluted tubule. There

is, also, evidence of intact Bowman's space and epithelial lining of bowman capsule (Figure 6).

The toxic group shows decreased cellularity in the glomeruli, loss of cellular constituents of tubules, densely eosinophilic (colloid) cast in the lumen of some tubules resulting in atrophy, loss of epithelia cells, as well as severe cloudy swelling/inflammation of the distal convoluted tubules.

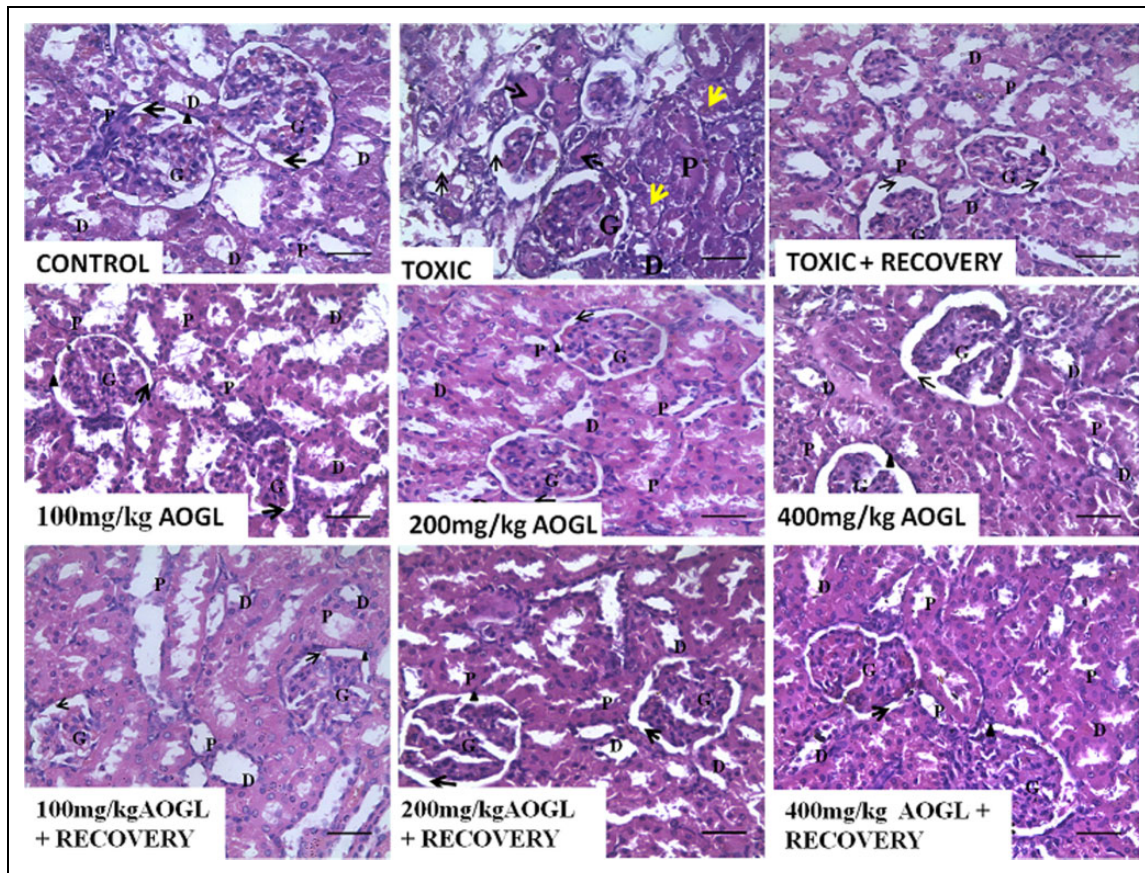
Toxic + recovery group depicts improvement in renal cortex histoarchitecture when compared to toxic. Glomeruli and surrounding Bowman's space are mostly intact with no apparent evidence of eosinophilic ("colloid") casts in the tubular lumen. Though, there is evidence of slight loss of tubular cellular constituents.

The 100 mg/kg AOGL-treated group shows histological improvement of the renal cortex. Glomeruli and surrounding Bowman's space are mostly intact. Apparently, no eosinophilic (colloid) casts are observed in the tubular lumen (Figure 6).

The 200 mg/kg AOGL-treated group shows apparently intact glomeruli and surrounding Bowman's space. There is slight loss of cellular constituents of tubules with no eosinophilic (colloid) casts in the lumen of the tubules.

The 400 mg/kg AOGL-treated group shows evidence of apparently intact glomeruli with surrounding Bowman's space. There is slight loss of cellular constituents of tubules





**Figure 6.** Photomicrographs showing the effects of AOGI on the kidney histoarchitecture of Wistar rats with gentamicin-induced kidney injury.

G, glomerulus; P, proximal convoluted tubule; D, distal convoluted tubule; black arrow, Bowman's space; arrow head, epithelial lining of Bowman's capsule; yellow arrow, evidence of tubular cloudy swelling/inflammation; dashed arrow, densely eosinophilic/colloid cast.

with no eosinophilic (colloid) casts in the tubular lumen (Figure 6).

Kidney histological integrity of the 100 mg/kg AOGI-treated group + 2-week recovery shows improvement that is comparable to the control. This is noted by clearly identified renal corpuscles with the glomeruli surrounded by narrow Bowman's space as well as intact capsule epithelia, and intact proximal convoluted tubule and distal convoluted tubule. Same is true for 200 mg/kg and 400 mg/kg AOGI-treated groups + 2-week recovery, respectively, but with appreciable improvement in their kidney histoarchitecture when compared with their 100 mg/kg counterpart (Figure 6).

## Discussion

The increase in food consumption and body weight that was associated with gentamicin administration contrasts the studies of Erdem et al<sup>15</sup> and El-Zawahry and Abu El Kheir et al,<sup>16</sup> who reported reductions in food consumption and body weight following gentamicin administration. Physiologic decline in food intake with aging has been described by Morley.<sup>17</sup> He explained that the expressed early satiation by aged people is a consequence of increased rate of antral filling as well as

progressive reduction in the adaptive relaxation of the stomach. Also, there is increased sensitivity to the satiating effects of the gut hormone "cholecystokinin" with ageing. Therefore, the different results obtained may be due to age and body weight-related differences of the rats that were used for the various studies; while this study engaged body weight of about 150 g, the former involved the use of about 210 to 230 g.<sup>16</sup> Also, "fat mass and leptin level" may be a further possible explanation for the contrasting evidence in food consumption and body weight. Leptin causes increase in resting metabolic rate while enhancing decrease in food consumption.<sup>18</sup> Both body leptin level and fat mass increases with ageing.<sup>19</sup> Li and coworkers<sup>19</sup> found that in aging male rats, an increase in leptin gene expression was found to be out of proportion to the increased adiposity seen with aging. Therefore, the recorded decrease in food consumption and body weight in previous studies may not be necessarily due to an apparent anorexic effect of gentamicin but also on the age and weight of the rats used.

The further AOGI-induced increase in food consumption and body weight may be a result of direct stimulation of the hypothalamic lateral nuclei (feeding center) and/or AOGI-induced inhibition of the hypothalamic ventromedial nuclei

(satiety center) with a consequent increase in food consumption. Also, a study had shown that AOGL administration in rats caused significant intestinal histological changes, revealing larger goblet cells as well as increased villi.<sup>20</sup> Increased intestinal villi facilitate increase in intestinal nutrient absorption due to increased intestinal surface area.<sup>21</sup> Also, acting via inhibition of muscarinic receptor, AOGL treatment evaluated for antidiarrhea effect by inhibiting intestinal motility<sup>22</sup> to bring about increase in intestinal nutrient absorption. These effects of AOGL on the gastrointestinal tract may be the explanation for the further increase in food consumption and body weight that was observed in this study. Nevertheless, this is in contrast with the report of Ajibade et al,<sup>23</sup> who stated that administration of graded doses of AOGL is associated with a significant decrease in body weight. The contrasting evidence may be due to differences in the doses of AOGL that were administered to the rats. This study engaged graded doses at 100, 200, and 400 mg/kg/day, while Ajibade et al used 400, 800, 1600, and 3200 mg/kg/day. This implies that relatively higher doses of AOGL administration may be associated with significant decrease in body weight. It has been reported that AOGL has hypoglycemic property,<sup>24</sup> an attribute that may have further contributed to increased food consumption with a consequent increase in body weight. The extract contains flavonoids and major mineral elements like calcium, chloride, manganese, magnesium, zinc, and potassium, which might also play a contributory role in enhancing its hypoglycemic property.<sup>24</sup> In rats with streptozotocin-induced diabetes, AOGL administration was found to be associated with a hypoglycemic effect.<sup>25</sup> Hypoglycemia inhibits the satiety center to bring about increased food consumption by activating the feeding centre.<sup>26</sup>

The gentamicin-induced polyuria that was observed in this study is in agreement with the study of El-Zawahry and Abu El Kheir.<sup>16</sup> However, following AOGL administration, a significant increase in water intake was observed without a corresponding increase in urine output. This may have resulted from AOGL-induced increase in plasma osmolarity with a consequent stimulation of the osmoreceptors that activates the thirst center in the hypothalamus. Also, the extract may have stimulated the release of antidiuretic hormone from the supraoptic nuclei of the hypothalamus to facilitate the water reabsorption by the distal convoluted tubules with a consequent decrease in urine output. This is, however, subject to further verifications.

The observed increase in relative kidney weight following gentamicin administration may be a result of inflammatory response to the drug-induced injury. This is supported by the representative photomicrograph, which depicts apparent swelling of the renal tubules. Similar observation was made by El-Zawahry and Abu El Kheir.<sup>16</sup> Nevertheless, in conformity with the report of Sahouo et al,<sup>27</sup> who stated that AOGL has anti-inflammatory effects on the kidney of rats, administration of AOGL was associated with a significantly lowered relative kidney weight when compared with the control.

An important index of renal function is creatinine determination.<sup>28</sup> Creatinine, a by-product of muscle metabolism and actively secreted by the proximal tubular cells, is excreted unchanged by the kidneys. Its level rises in the blood if there is deficiency in kidney filtration capacity, suggesting remarkable damage to the nephron. Our findings on creatinine levels support existing literatures, which showed that gentamicin toxicity is associated with increased creatinine concentration.<sup>29,30</sup> This was marked with a significant decrease in urine creatinine, a finding that is consistent with that of El-Zawahry and Abu El Kheir<sup>16</sup> and Parlakpinar et al.<sup>31</sup> This further buttresses the fact that gentamicin administration has nephrotoxic potentials.

Creatinine clearance is a measure of excretory function. It is also an index used to assess renal blood flow. Consequently, a decrease in creatinine clearance indicates marked reduction in glomerular filtration rate and renal blood flow. This impairment of glomerular function can result from a rise in renal vascular resistance and/or damage to the glomerular capillary endothelium. The gentamicin-induced decrease in creatinine clearance is indicative of reduced kidney perfusion as well as a significant tissue injury. This fact was supported by the representative photomicrograph, which shows loss of cellular constituents of the tubules. In this study, treatment with AOGL was accompanied by significant decrease in creatinine clearance, a report that contrasts the study of Ebeye et al,<sup>32</sup> who reported that administration of the plant extract caused no significant alteration in the serum levels of some indices of renal function. This evidence is indicative of the fact that, despite the restorative potential of AOGL on drug-induced kidney injury, prolonged administration may be deleterious to the kidney as evident by the increase in plasma creatinine and reduced creatinine clearance.

Urea, produced by the liver in the urea cycle as a waste product of metabolism of protein (either from the oxidation of amino acids or from ammonia), is dissolved into the blood and transported and excreted by the kidney as a component of urine. It is a sensitive biomarker used in the assessment of renal tissue damage. Therefore, in renal tissue injury, there is retention of urea. Increase urea level is associated with nephritis, renal ischemia, urinary tract obstruction, and extra-renal diseases.<sup>33</sup> The gentamicin-induced increase in plasma urea level, as observed in this study, is consistent with the findings of Pedraza-Chaverrí et al<sup>29</sup> and Maldonado et al.<sup>30</sup> It has been established that gentamicin causes inhibition of protein synthesis in renal cells with consequent abundance of amino acid in the kidney resulting in increased urea levels.<sup>2</sup> AOGL administration significantly attenuated the increased plasma urea levels, a result that is consistent with the findings of similar study on drug-induced nephrotoxicity.<sup>34</sup> The reduction in plasma urea is suggestive that AOGL activates/enhances protein synthesis from amino acids, thereby abating the apparently gentamicin-induced nephritis as depicted by the representative photomicrograph.

The gentamicin-induced significantly lowered plasma protein that was accompanied by a significantly increased urine



total protein may have resulted from damage to the filtration mechanism of the glomerular basement membrane as well as reabsorptive failure of the proximal convoluted tubules with consequent leaking of plasma protein into the urine.<sup>35</sup> This observed change is in accordance with the report of El-Zawahry and Abu El Kheir,<sup>16</sup> who stated that gentamicin administration to rats is associated with the excretion of protein. Worthy of note is the fact that apparently healthy rats express physiologic proteinuria.<sup>36-38</sup> Little wonder even the control group excreted some measure of protein in their urine. However, AOGL administration significantly reversed the deleterious alteration of plasma and urine total protein levels. The decrease in urine total protein is an indication that AOGL may have potentiated the recovery of the filtration barriers' integrity from injury that was induced by gentamicin. The extract may have also enhanced post-glomerular processing of plasma protein by the renal tubules, a fact supported by the representative photomicrograph.

Consistent with the study of Chinnapa Reddy et al<sup>39</sup> were a significant increase in TBARS as well as a significant decrease in GSH level following gentamicin administration. These are measures of lipid peroxidation and oxidative stress. The group that was left untreated with AOGL following gentamicin administration showed significant reversal of the drug-induced perturbation of the antioxidant system, an effect that may have been due to the release of reparative and pro-survival factors from the distal tubular cells.<sup>40</sup> Also, consistent with the findings of Chinnapa Reddy et al<sup>39</sup> was a significant reversal of gentamicin-induced deleterious alteration of the antioxidant system as evident by the levels of TBARS and GSH. This demonstrates the antioxidant potential of AOGL.

This study recorded a remarkable self-restorative ability of the kidney following exposure to gentamicin, a report that is consistent with existing literatures on self-regenerating potential of the kidney following injury.<sup>40,41</sup> Recent evidence showed that activated renal macrophages contribute to kidney tissue regeneration through induction of Wnt-7b, a protein associated with kidney tubule development, which initiates renal tubular repair and regeneration after injury.<sup>42</sup> Tubular regeneration also results from the release of reparative and pro-survival factors from the distal renal tubular cells<sup>43</sup> or repairing process achieved by migration of polarized mature cells into the damaged region, reconstituting a functional tubular epithelium.<sup>44</sup> This is supported by the representative photomicrograph, which shows appreciable improvement of the kidney histoarchitecture when compared with the toxic group.

As observed in this study, biochemical indices of the AOGL-treated groups after recovery showed no deleterious aftermath effect of the extract on the kidney function and histology. This is well depicted by improved integrity and clearly identified renal corpuscles, an appreciable improvement that appears to be dose-dependent, that is, more obvious in the groups that received 400 mg/kg and 200 mg/kg than that of 100 mg/kg.

Based on the results from this study, a note of caution is recommended in the application of the extract for therapeutic

purpose(s) against drug-induced kidney injury. Also, further study of the biochemical basis of its therapeutic potentials (particularly at a molecular level) is expedient in order to properly elucidate the extract's mechanism of action.

## Conclusion

From the results of this study, it is concluded that the aqueous extract of *Ocimum gratissimum* ameliorated gentamicin-induced kidney injury in rats. The ameliorative effects of *Ocimum gratissimum* is evident by a remarkable restoration of antioxidant enzymes, total protein, and urea concentration resulting from an improved renal function.

## Acknowledgments

The authors appreciate Mrs T. R. Olatoye, Department of Medical Pharmacology and Therapeutics, OAU, Ile-Ife; Mr K. Ilesanmi, Department of Physiological Sciences, OAU, Ile-Ife; Mr Afolayan, Animal Holdings, College of Health Sciences, OAU, Ile-Ife; and Dr E. M. Obuotor, Department of Biochemistry, for providing the required technical assistance and support for the success of this study.

## Author Contributions

DJO initiated the research and was involved in the bulk of the research work, analyses of data, and writing of the article. ROA was involved in the design of the experiment and supervised various stages of the work. He was also responsible for the collection of plant material. AAS was involved in the design of the experiment. He also proof-read the article. CEI was involved in carrying out the research work and writing of the article. OSO was involved in the writing and editing of article. AAO was responsible for tissue processing.

## Declaration of Conflicting Interests

The authors declared no potential conflicts of interest with respect to the research, authorship, and/or publication of this article.

## Funding

The authors received no financial support for the research, authorship, and/or publication of this article.

## Ethical Approval

The experiment procedures adopted in this study were in strict compliance with Experimental Animal Care and Use of Laboratory Animals in Biomedical Research, College of Health Sciences, Obafemi Awolowo University, Ile-Ife, Nigeria.

## References

1. Moulds RFW, Jeyasingham MS. Gentamicin: a great way to start. *Aust Prescr.* 2010;33:134-135.
2. Sundin DP, Meyer C, Dahl R, Geerdes A, Sandoval R, Mollitoris BA. Cellular mechanism of aminoglycoside tolerance in long-term gentamicin treatment. *Am J Physiol.* 1997;41:1309-1318.
3. Elfarra AA, Duescher RJ, Sausen PJ, O'Hara TM, Cooley AJ. Methimazole protection of rats against gentamicin-induced nephrotoxicity. *Can J Physiol Pharmacol.* 1994;72:1238-1244.

4. Abdel Raheem IT, Abdel Ghany AA, Mohamed G. Protective effect of quercetin against gentamicin-induced nephrotoxicity in rats. *Biol Pharm Bull.* 2009;32:61-67.
5. Mansour HH, Hafez HF, Fahmy NM. Silymarin modulates cisplatin-induced oxidative stress and hepatotoxicity in rats. *J Biochem Mol Biol.* 2006;39:656-661.
6. Bibu KJ, Joy AD, Mercey KA. Therapeutic effect of ethanolic extract of *Hygrophila spinosa* on gentamicin-induced nephrotoxicity in rats. *Indian J Exp Biol.* 2010;48:911-917.
7. Naghizadeh B, Boroushaki MT, Vahdati Mashhadian N, Mansouri MT. Protective effects of crocin against cisplatin-induced acute renal failure and oxidative stress in rats. *Iran Biomed J.* 2008;12:93-100.
8. Akinmoladun AC, Ibukun EO, Emmanuel A, et al. Phytochemical constituent and antioxidant activity of extract from the leaves of *Ocimum gratissimum*. *Sci Res Essay.* 2007;2:163-166.
9. Ijeh II, Omodamiro OD, Nwanna IJ. Antimicrobial effects of aqueous and ethanolic fractions of two spices, *Ocimum gratissimum* and *Xylopiya aethiopica*. *Afr J Biotech.* 2005;4:953-956.
10. Bartels H, Böhmer M, Heierli C. Serum creatinine determination without protein precipitation. *Clin Chem Acta.* 1972;37:193-197.
11. Lowry OH, Rosenbrough NJ, Farr A, Randallm RJ. Protein measurement with the folin phenol reagent. *J Biol Chem.* 1951;193:265-275.
12. Holme DJ, Peck H. *Analytical Biochemistry.* 3rd ed. New York, NY: Longman; 1998.
13. Beutler E, Duron O, Kelly BM. Improved method for determination of blood glutathione. *J Lab Clin Med.* 1963;61:882-888.
14. Ohkawa H, Ohishi N, Yagi K. Assay for lipid peroxidation in animal tissues by thiobarbituric acid reaction. *Anal Biochem.* 1979;95:351-358.
15. Erdem A, Gundogan N, Alp U, Kara A. The protective effect of taurine against gentamicin-induced acute tubular necrosis in rats. *Nephrol Dial Transplant.* 2000;15:1175-1182.
16. El-Zawahry BH, Abu El Kheir EM. The protective effect of curcumin against gentamicin-induced renal dysfunction and oxidative stress in male Albino rats. *Egyptian J Hosp Med.* 2007;29:546-556.
17. Morley JE. Decreased food intake with aging. *J Gerontol A Biol Sci Med Sci.* 2001;56 Spec No 2:81-88.
18. Morley JE, Perry HM III, Baumgartner RP, Garry PJ. Leptin, adipose tissue and aging—is there a role for testosterone? *J Gerontol A Biol Sci.* 1999;54:B108-B109.
19. Li H, Matheny M, Nicolson M, Turner N, Scarpace P. Leptin gene expression increases with age independent of increasing adiposity in rats. *Diabetes.* 1997;46(12):2035-2039.
20. Iweala EEJ, Obidoa O. Studies on some biochemical and histological changes associated with long term consumption of leaves of *Ocimum gratissimum* L. in male rats. *Am J Food Technol.* 2010;5:376-384.
21. Pappenheimer JR. Intestinal absorption of hexoses and amino acids: from apical cytosol to villus capillaries. *J Membr Biol.* 2001;184:233-239.
22. Offiah VN, Chikwendu UA. Antidiarrhoeal effects of *Ocimum gratissimum* leaf extract in experimental animals. *J Ethnopharmacol.* 1999;68:327-330.
23. Ajibade AJ, Fakunle PB, Ashamu EA, Owolabi SO. Some morphological changes on the kidney of adult Wistar rats following administration of crude extract of *Ocimum gratissimum*. *J Med Plants Res.* 2011;5:6435-6438.
24. Chen MD, Lin PY, Tsou CT, Wang JJ, Lin WH. Selected metal status in patients with non-insulin-dependent diabetes mellitus. *Biol Trace Elem Res.* 1995;50:119-124.
25. Egesie UG, Adelaiye AB, Ibu JO, Egesie OJ. Safety and hypoglycaemic properties of aqueous leaf extract of *Ocimum gratissimum* in streptozotocin induced diabetic rats. *Niger J Physiol Sci.* 2006;21:31-35.
26. Guyton AC, Hall JE. *Textbook of Medical Physiology.* 10th ed. Philadelphia, PA: Elsevier; 2000.
27. Sahouo GB, Tonzibo ZF, Boti B, et al. Anti-inflammatory and analgesic activities. *Chem Pathol.* 2003;12:63-66.
28. Howard TE. *Clinical Chemistry.* New York, NY: John Wiley; 1989.
29. Pedraza-Chaverri J, Maldonado PD, Medina-Campos ON, et al. Garlic ameliorates nephrotoxicity: relation to antioxidant enzymes. *Free Radic Biol Med.* 2000;29:602-611.
30. Maldonado PD, Barrera D, Rivero I, et al. Anti-oxidant S-allylcysteine prevents gentamicin induced oxidative stress and renal damage. *Free Radic Biol Med.* 2003;35:317-324.
31. Parlakpınar H, Tasdemir S, Polat A, et al. Protective role of caffeic acid phenethyl ester (CAPE) on gentamicin-induced acute renal toxicity in rats. *Toxicology.* 2005;24:33-37.
32. Ebeye OA, Ekundina OV, Wilkie IE. Histological and biochemical effects of aqueous extract of *Ocimum gratissimum* on the liver and kidney of adult Wistar rats. *Afr J Cell Pathol.* 2014;2:59-64.
33. Oyewole OI. Chemopreventive role of vitamin C and E on potassium bromated induced renal oxidative damage in rat. *J Med Med Sci.* 2011;2:1189-1192.
34. Adikay S, Kognati P, Prasad KV. Effect of alcoholic extract of roots of *Dichrostachys cinere* Wright and Arn. against cisplatin-induced nephrotoxicity in rats. *Nat Prod Radiance.* 2009;8(1):12-18.
35. Bonventre JV, Weinberg JM. Recent advances in the pathophysiology of ischemic acute renal failure. *J Am Soc Nephrol.* 2003;14:2199-2210.
36. Perry SW. Proteinuria in the Wistar rat. *J Pathol.* 1965;89:729-733.
37. Jeannette MA, Hackbarth H, Deerberg F, Stolte H. Proteinuria in rats in relation to age-dependent renal changes. *Lab Anim.* 1980;14:95-101.
38. Imafidon CE, Akomolafe RO, Oladele AA. Sexually dimorphic proteinuria in Wistar rats: relevance to clinical models. *Pathophysiology.* 2016;23:51-59.
39. Chinnapa Reddy V, Amulya V, Anusha Lakshmi CH. Effect of simvastatin in gentamicin-induced nephrotoxicity in albino rats. *Asian J Pharm Clin Res.* 2011;5(1):36-40.
40. Imafidon CE, Akomolafe RO, Abubakar SA, Ogundipe OJ, Olukiran OS, Oladele A, Ayowole OA. Amelioration of cadmium-induced nephropathy using polyphenol-rich extract of *Vernonia amygdalina* (Del.) leaves in rat model. *Open Access Maced J Med Sci.* 2015;3:567-577.

41. Akomolafe RO, Imafidon EC, Olukiran OS, Oladele AA, Ajayi AO. Livolin forte ameliorates cadmium-induced kidney injury. *Serb J Exp Clin Res.* 2016;17:107-116.
42. Lin SL, Li B, Rao S, et al. Macrophage Wnt7b is critical for kidney repair and regeneration. *Proc Natl Acad Sci U S A.* 2010;107:4194-4199.
43. Gobe GC, Johnson DW. Distal tubular epithelial cells of the kidney: potential support for proximal tubular cell survival after renal injury. *Int J Biochem Cell Biol.* 2007;39:1551-1561.
44. Bonventre JV. Dedifferentiation and proliferation of surviving epithelial cells in acute renal failure. *J Am Soc Nephrol.* 2003;14(suppl 1):S55-S61.