



THE UNIVERSITY *of* EDINBURGH

Edinburgh Research Explorer

Use of ultrasonographic examination in sheep veterinary practice

Citation for published version:

Crilly, JP, Politis, AN & Hamer, K 2016, 'Use of ultrasonographic examination in sheep veterinary practice' Small Ruminant Research. DOI: 10.1016/j.smallrumres.2016.12.021

Digital Object Identifier (DOI):

[10.1016/j.smallrumres.2016.12.021](https://doi.org/10.1016/j.smallrumres.2016.12.021)

Link:

[Link to publication record in Edinburgh Research Explorer](#)

Document Version:

Peer reviewed version

Published In:

Small Ruminant Research

General rights

Copyright for the publications made accessible via the Edinburgh Research Explorer is retained by the author(s) and / or other copyright owners and it is a condition of accessing these publications that users recognise and abide by the legal requirements associated with these rights.

Take down policy

The University of Edinburgh has made every reasonable effort to ensure that Edinburgh Research Explorer content complies with UK legislation. If you believe that the public display of this file breaches copyright please contact openaccess@ed.ac.uk providing details, and we will remove access to the work immediately and investigate your claim.



Accepted Manuscript

Title: Use of ultrasonographic examination in sheep veterinary practice

Author: J.P. Crilly A.N. Politis K. Hamer

PII: S0921-4488(16)30372-8

DOI: <http://dx.doi.org/doi:10.1016/j.smallrumres.2016.12.021>

Reference: RUMIN 5379

To appear in: *Small Ruminant Research*



Please cite this article as: Crilly, J.P., Politis, A.N., Hamer, K., Use of ultrasonographic examination in sheep veterinary practice. *Small Ruminant Research* <http://dx.doi.org/10.1016/j.smallrumres.2016.12.021>

This is a PDF file of an unedited manuscript that has been accepted for publication. As a service to our customers we are providing this early version of the manuscript. The manuscript will undergo copyediting, typesetting, and review of the resulting proof before it is published in its final form. Please note that during the production process errors may be discovered which could affect the content, and all legal disclaimers that apply to the journal pertain.

Use of ultrasonographic examination in sheep veterinary practice

J.P. Crilly^{a*}, A.N. Politis^{b,c}, K. Hamer^d

a FarmVets SouthWest, Unit 8, Sedgemoor Auction Centre, North Petherton, Somerset, TA6 6DF, UK

b Politis Veterinary Centre, Dimokratias 104, 26500 Patras, Greece

c Veterinary Faculty, University of Thessaly, 43100 Karditsa, Greece

d Farm Animal Practice, Royal (Dick) School of Veterinary Studies, University of Edinburgh, Easter Bush, Roslin, Midlothian, EH25 9RG, UK

* Corresponding author: jp.crilly@hotmail.co.uk

ABSTRACT

This review describes the current, emerging and potential applications of ultrasonography in the field of first-opinion sheep veterinary practice. The most widespread application is pregnancy diagnosis, where both transrectal and transabdominal ultrasonography offer a highly sensitive tool for, among others, detection of pregnancy, identification of foetal number and diagnosis of uterine abnormalities, e.g., metritis. The diagnostic applications of ultrasonography for imaging the lungs, heart, male genitourinary system and superficial swellings are also described. Through review of recent research in sheep and by analogy from applications in other animal species, the potential role of ultrasonography in screening programmes for cystic echinococcosis or ovine pulmonary adenocarcinoma, diagnosis of ocular and laryngeal disease and localisation of *Coenurus* cysts is explored.

Keywords: application, diagnosis, sheep, veterinary practice, ultrasonography

1. Introduction

Ultrasonography is a non-invasive, real-time, imaging modality, which poses no hazard to either operator or patient. Compared to advanced imaging techniques, like magnetic resonance imaging or computed tomography, it is cheap and widely available, with many veterinary practitioners having access to an ultrasound machine of some sort.

Unlike companion animal or equine practice, use of ultrasonographic examination in production animal practice is often restricted to reproductive management. Small rectum size, high fertility of ewes relative to cattle and low individual animal value means that ultrasonographic imaging of ovaries and the non-pregnant reproductive tract is rarely performed in sheep; reproductive ultrasonographic examinations are usually confined to pregnancy diagnosis. In some countries, e.g. the United Kingdom, ultrasonographic pregnancy diagnosis of sheep is usually performed by non-veterinary personnel, further limiting the use of ultrasonographic examination in sheep veterinary practice.

Objective of this article is to familiarise the reader with areas of sheep veterinary practice, where ultrasonographic examination has the potential to be a useful additional diagnostic tool, as well as to highlight some of the areas, where further information is required so that results of ultrasonographic examination can be interpreted by first-opinion practitioners.

2. Types of ultrasound equipment commonly used in sheep veterinary practice

The types of ultrasound equipment available to sheep practitioners would depend on type of practice within which he or she practices. Farm animal practitioners with a bovine, especially dairy cow, dominated workload, are likely to have access to linear array scanners designed for *per rectam*

examination of the female genital tract (Fig. 1). Frequency of linear array scanners is usually in the range of 3.5 to 8.0 MHz. These machines produce a rectangular image, often with a superimposed grid, allowing some estimation of size. More advanced functions, e.g., image callipers or Doppler modality, are not usually available in such equipment. Exclusively or largely small ruminant practitioners, especially if their caseload mainly consists of dairy sheep and goats, are more likely to have a portable scanner with a sector scanner probe. These machines provide a wider arc shaped field of view; often, their functionality beyond basic image capture is limited.

Some veterinary surgeons working in mixed practices would have access to more advanced machines. These are usually designed for human medicine and are often acquired second-hand from hospitals or clinics. Such machines are less portable, but often have interchangeable transducers, allowing use of linear, convex and, sometimes, more specialised transducers. These have greater functionality, allowing for image manipulation, on-screen measurement, Doppler examination etc. While such machines are undoubtedly superior diagnostic tools, their lack of portability and vulnerability to (expensive) damage in a farm environment limit their usefulness for farm veterinary practitioners. Finally, ultrasound machines used by lay scanners for pregnancy diagnosis are usually relatively simple and often have rotating scanner array. This provides a very wide arc field of view (often 270 °), allowing for simultaneous imaging of both uterine horns transabdominally, which improves capacity of the user to estimate foetal number during late stages of pregnancy.

All above types of machines can be useful in some capacity for diagnostic ultrasound investigation of sheep.

3. Current usage of ultrasonographic examination in sheep practice

3.1. Pregnancy diagnosis

Pregnancy diagnosis in small ruminants using ultrasonographic examination is an accurate, rapid and safe method to use and can be used to detect pregnancies from an early stage. A transrectal or transabdominal approach may be used, with a high sensitivity (nearly 100%).

The method chosen is constrained by the transducer type available, but, in practice, transabdominal scanning is favoured, because it is less painful for the animal, is quicker and provides a very wide field of view. A transrectal approach gives better results before 40th day of gestation. A range of 3.5 to 5.0 MHz is most often used. In the transrectal method, the probe is inserted in the rectum to an approx. 15 cm depth, until the bladder is imaged. A standard bovine linear array rectal probe may be used for larger ewes; use is often facilitated by using an introducing rod. The probe is then rotated 90 ° in both directions, left and right of the bladder, in order to identify both uterine horns (Karen et al., 2004). In transabdominal examination, the probe is placed in front of the mammary gland, directed caudodorsally, and is moved caudally (into the inguinum) to image the bladder. The

uterus is usually seen immediately cranial to the bladder. The right inguinum and perimammary area is preferred, as the left is often occupied by the rumen.

The pregnant uterus has the following ultrasonographic characteristics (Jones et al., 2016): anechoic fluid in the lumen of the uterus, which is divided into multiple parts, with placentomes that have a characteristic 'C' or '0' shape, depending on the orientation of the view, transverse/longitudinal and horizontal respectively, as well as imaging the embryo/foetus (Fig. 2). Therefore, total absence of any of the above indicates lack of pregnancy in that animal.

Findings change with stage of pregnancy: fluid may be seen very early, the foetus may be seen from approx. 20 to 28 days of gestation onwards, placentomes develop later (from day 33 of gestation). The sensitivity of pregnancy diagnosis by ultrasound increases as pregnancy advances; for the transrectal method, Jones et al. (2016) have found a 40% sensitivity at day 21 of gestation, which has increased to 100% at day 39. Transabdominal ultrasonographic examination has limited sensitivity in early pregnancy, when the uterus is still intrapelvic. Sensitivity of that method increases from day 40 of gestation, when the uterus becomes intra-abdominal in the majority of cases. In later pregnancy, sensitivity for detection of pregnancy is undiminished, but accurate estimation of foetal number is reduced. If date of mating is unknown or the diagnosis unclear, a second examination can be performed 15 days later.

Identification of non-pregnant females allows these animals to either be re-mated or culled. Also, identification of increased proportion of non-pregnant ewes at the time of the examination, requires an investigation into the cause. This investigation can thus be instigated earlier than if the problem had not been detected until lambing time.

Other benefits of scanning include identification of the number of foetuses in each ewe (White et al., 1984), a very important information for sheep flocks, as this allows nutritional management to be targeted to the different needs of each group of ewes (Russel, 1985). It also allows estimation of the stage of gestation (Sergeev et al, 1990; Doize et al., 1996; Ali and Hayder, 2007; Jones et al. 2016), helping to guide the timing of drying-off for lactating females, especially in cases in which rams are with the ewes for a prolonged period.

Finally, pregnancy diagnosis by ultrasonographic examination has the added advantage of potentially being able to identify pathological situations, e.g., dead or dying foetuses, pyometra or hydrometra (Fig. 3).

Around parturition, ultrasonographic examination can be used to detect uterine torsion (affected ewes show signs of stage 1 labour, but a hand cannot be advanced into the cervix and uterus; thickness of uterine wall is increased from 5 to over 10 mm) (Wehrend et al., 2002), which otherwise may be a difficult diagnosis in sheep and also to definitively detect presence of retained foetuses after cervical closure (Scott and Gessert, 2000).

3.2. Ram breeding soundness examination

Palpation of scrotal contents should form part of all ram breeding soundness examinations. Most abnormalities, which are likely to affect breeding soundness, can possibly be detected by clinical examination alone; however, ultrasonographic examination of scrotal contents is relatively easy and allows nature of palpated lesions to be assessed, e.g., allowing epididymitis and scrotal hernias to be more conclusively differentiated (Scott, 2012). This is of particular use when the palpated abnormality is subtle and its significance uncertain.

Before the examination, wool or thick hair overlying the scrotum should be shaved off (Fig. 4). The testis itself, tail and head of the epididymis and pampiniform plexus can all be examined ultrasonographically; sometimes, the body of the epididymis, parietal and visceral tunics can be imaged as well. Examining the testes in both longitudinal and horizontal planes is recommended. Scanning frequencies of 5.0 to 7.5 MHz are recommended for examination of the testes (Gouletsou et al., 2003).

Transrectal examination may have a role in assessing the accessory sex organs in valuable rams, where semen analysis or a poor breeding history, despite no other discernible abnormalities, is suggestive of accessory sex organ lesions. In bulls, the detection of seminal vesiculitis by this technique has been reported (Mickelsen et al., 1994), although no relevant work specific to rams has been published.

3.3. Investigation of chronic respiratory disease

Ultrasonographic examination of the ovine lung field can be performed with both sector and linear transducers, using 5.0 to 7.5 MHz. While the entire lung field caudal to the shoulder musculature can be imaged, most previous reports have described use of a shaved window over the 6th to 7th intercostal spaces, i.e., immediately caudal to the triceps muscle (Scott and Gessert, 1998). Ultrasonographic examination of the lung fields is indicated in the case of dyspnoeic sheep, where acute pneumonia does not appear likely from clinical findings. Fibrinous pleurisy or pleural abscesses, ovine pulmonary adenocarcinoma and *Lentivirus* infections all result in a similar clinical picture of weight loss, exercise intolerance, dyspnoea, hyperpnoea and tachypnoea. While auscultation profiles may differ for these problems: unilaterally reduced lung sounds, increased moist lung sounds and increased dry lung sounds, respectively, these changes can be subtle and hard for a clinician to appreciate (Scott et al., 2010). The ultrasonographic findings in each of these diseases are markedly different, hence the disorders can be more easily distinguished using this technique (Scott and Gessert, 1998; Scott et al., 2010). It should be stressed that by ultrasonographic examination it may not be possible to produce a definitive diagnosis, therefore when a diagnosis has implications for the flock as a whole, further investigation would be necessary.

It is recommended to perform ultrasonographic examination of the thorax in any investigation of weight loss in sheep, even without respiratory signs, once the more common causes have been

eliminated. Pleural abscesses, visible ultrasonographically but undetectable on auscultation, have been reported as a cause of weight loss in sheep.

3.4. Investigation of suspect cardiac disease

While ultrasonographic examination can be used to assess cardiac function, by determining fractional shortening and Doppler analysis of flow and contraflow through valves (Hallowell et al., 2012), such detailed diagnostic work is probably out-with the skillset and requirements of most first-opinion practitioners and also requires specialised ultrasound equipment. However, even with basic ultrasound machines gross abnormalities, e.g., pericarditis, and/or obvious changes of heart walls (Braun et al., 1995; Crilly et al., 2015) and valves may be detected. Changes due to congestive heart failure may also be visible, e.g., pericardial effusion, ascites and congestive changes to the liver parenchyma (Scott and Sargison, 2001). This can help to support a diagnosis of cardiac failure, as other clinical signs may be non-conclusive, especially if a heart murmur is not present (Buczinski et al., 2010).

3.5. Ultrasound-guided liver biopsy

Liver biopsy is considered to be a superior method of monitoring status of certain trace elements compared with results of blood biochemical examinations; this is especially true for copper (Bruere and West, 1993). Ultrasound-guided biopsy of the liver, performed by inserting the biopsy needle at intercostal spaces 9 to 11 on the right side of the animal, provides increased likelihood of retrieving a useful sample and reduces the risk of iatrogenic damage to other organs. Perhaps, most importantly, use of ultrasonographic examination during the procedure can increase confidence of the performing clinician who might be unfamiliar with the technique.

3.6. Assessment of urinary tract obstruction cases

Obstructive urolithiasis is a relatively common condition of rams and wethers. The combination of tenesmus, stranguria, vocalisation, obvious abdominal discomfort and crystals on the preputial hairs usually suffice to make the diagnosis. Demonstration of a dilated bladder and urethra on ultrasound can support the diagnosis (Braun et al. 1992); however, if the clinical picture is less typical, these findings can be an important diagnostic step (Fig. 5).

In cases in which surgical intervention is contemplated, e.g., in valuable breeding rams, ultrasonographic examination of kidneys can help to establish a likely prognosis for that animal; for example, in cases of hydronephrosis or uroabdomen, disorders which may only be confirmed pre-operatively by ultrasonographic examination, euthanasia would be a better course of action than surgery (Fig. 5) (Scott and Sargison, 2010). Other prognostic indicators are available, e.g. plasma

potassium concentration, but these do not provide an instantaneous result, as ultrasonographic examination does. Pre-surgical ultrasonographic examination may also detect presence cystitis (Braun et al. 1992) and/or blood clots in the bladder, which would be of help to the surgeon in determining their approach, protocol and post-surgical care.

Finally, post-surgical examination can be used to monitor progress, e.g., after tube cystostomy, the balloon of the Foley catheter can be inspected to check it is still inflated.

3.7. Investigation of superficial swellings

Superficial swellings can present a diagnostic challenge, especially when there is limited accompanying history. Haematomata, seromata, abscesses, cysts, diverticula and ruptures/hernias can all appear similar on initial presentation. While careful physical examination may be sufficient to allow the clinician to decide on the nature of the swelling, this may not always be the case. Needle aspiration runs a risk of damaging viscera or introducing infection, whereas ultrasonographic examination, by virtue of being non-invasive, is an extremely useful tool for determining the nature of superficial swellings with no risk of iatrogenic damage. Appearance on ultrasonographic examination of superficial swellings in farm animals has been described in detail by Magda and Abd El-Hakim (2012) and summarised herebelow.

- Abscesses have a distinct, hyperechoic capsule, while contents progress from hypoechoic to hyperechoic as abscesses mature (the exception being abscesses caused by *Corynebacterium pseudotuberculosis*, which are hyperechogenic even in the acute stage).
- Cysts have anechoic contents and may be divided by septa.
- Haematomata are hypoechoic in the acute stages, becoming more hypoechoic with thin, branching hyperechoic structures (fibrin strands), crossing the mass, as blood clot organises.
- Within swellings due to herniation, viscera can be observed; most commonly, these are loops of small intestine, in which case peristaltic contractions and swirling of intestinal contents can be visualised, while the transducer is stationary over the mass; layers of intestinal wall are often also visible. In cases where other viscera have herniated, the characteristic ultrasonographic findings of these viscera may be observed, e.g., rugal folds in the case of the abomasum.

Ultrasonographic examination can also be used to guide further diagnostic or therapeutic measures, e.g., ultrasound-guided fine needle aspiration or assessing the vitality of herniated viscera.

3.8. Examination of other structures

Given the number of vital structures in the neck (major vessels, trachea, nerve trunks, oesophagus and spine) when working in that part of the body, non-invasive procedures are particularly desirable; invasive procedures must be performed precisely to avoid excessive iatrogenic damage. Ultrasonographic examination is obviously non-invasive and can be used to assess structures of the neck.

The technique can be used, for example, in the neck to confirm identity and extent of abscesses prior to drainage or to demonstrate the presence of peri-vertebral abscesses potentially associated with neurological signs.

The technique can also be used to assess bruising and abscessation within muscle bodies, which otherwise might be difficult to assess (Magda and Abd El-Hakiem, 2014). Finally, ultrasonographic evaluation of internal structures of the teat has been described in sheep and might be of use when investigating milk flow problems in dairy sheep (Franz et al., 2003; Mavrogianni et al., 2004).

4. Emerging and potential uses of ultrasonographic examination in sheep practice

4.1. Testicular echotexture as a predictor of semen quality

Testicular parenchyma usually has a fine grained echotexture, but in some animals the echotexture can become coarser, with hyperechoic points within a less echogenic area. These changes appear to occur with increasing age (Gouletsou et al., 2003). A scoring system of 0 to 3 has been proposed by Vencato et al. (2014), with 0 indicating the most homogenous and 3 the most heterogenous echotexture; increased scores can take into account diffuse echogenic structures within a testis. These authors have reported that rams with testes that scored 3 have produced significantly fewer spermatozoa per electroejaculate than rams with testes that scored 0. However, gross and progressive motility of spermatozoa did not show a correlation with ultrasonographic findings. Further work would be required to elucidate whether any features of an ultrasonographic image, which are not discernible when palpating the testes, correlate consistently with decreased fertility. Currently, ultrasonographic examination cannot substitute for a thorough physical examination, alongside semen collection and analysis.

4.2. Ultrasonographic examination as a screening tool for ovine pulmonary adenomatosis

Recently, ultrasonographic examination of lungs has been proposed as a screening method for detection of ovine pulmonary adenomatosis in purchased sheep or entire flocks (Cousens and Scott, 2015). Whilst this method may be effective for detecting tumours above a certain size, it must be emphasised that it only detects affected sheep, not those with early infection that could go on to develop disease after being declared 'clear' during the examination; these animals still pose an infection risk to others in the flock (Cousens and Scott, 2015).

4.3. Laryngeal ultrasonographic examination

Laryngeal ultrasonographic examination has been described in horses for assessment of laryngeal chondritis (Chalmers et al., 2006; Garrett et al., 2013). Abscessation and deformation of cartilages can be detected. Laryngeal chondritis is a recognised problem in sheep, especially in rams of short-necked breeds, e.g., Texel and Beltex (Lane et al., 1987; Scott, 2007).

It is recognised that failure to respond to an initial treatment course is a negative prognostic indicator and that chances of success of each subsequent course of treatment are smaller (Scott, 2007). It has been theorised that presence of abscessation might be associated with a poorer prognosis (Lane et al., 1987). However, there is currently no way of assessing prognosis at initial presentation of the animals, nor whether treatment is proving successful or needs to be extended. Further work on the ultrasonographic appearance of the ovine larynx (Fig. 7), the changes seen in cases of laryngeal chondritis and their prognostic associations would be of great benefit to clinicians, who could then provide a more accurate prognosis to farmers, in the hope that this would increase compliance with subsequent treatment regimes.

4.4. Ultrasonographic examination as a screening tool for cystic echinococcosis

Ultrasonographic examination of the liver and lungs has been proposed as a screening method for cystic echinococcosis (Sage et al., 1998). The disease is a major zoonotic risk in several areas of the world (Eckert and Deplazes, 2004); while control programmes have been successful in eliminating it in some countries, e.g. New Zealand, they have failed in others, e.g. Wales, Cyprus. Reported sensitivities and specificities of ultrasonographic examination as a method of detecting cystic echinococcosis range between 54 to 89% and 76 to 98%, respectively (Sage et al., 1998; Dore et al., 2014). Although this is insufficient to diagnose affected animals, when applied as a flock screening measure, the technique may be employed to determine whether hydatid disease is widespread or not within a flock. The findings could then be used as aid in an elimination campaigns by way of highlighting flocks, farms and areas for intensive action and subsequently to monitor the course and success of the campaign (Lahmar et al., 2007). In any case, it is noteworthy that more sensitive and specific methods, e.g., abattoir screening, may render information provided by ultrasonographic examination redundant, depending on extent of local animal movements and record keeping.

*4.5. Ultrasonographic examination for location of *Coenurus* cysts*

Normally, the brain is not easily accessible to ultrasonographic examination, as it is encased within the skull. However, in cases of coenurosis the increased pressure of the cyst causes thinning of the overlying bone (Scott, 2012). Position of the cyst can often be determined from the clinical signs during neurological examination; ultrasonographic examination performed through the thinned skull may allow visualisation and precise localisation of cyst(s) (Biswas, 2013), which can be useful prior to surgical removal. A 6.0 MHz sector transducer can usefully employed, with cysts appearing as hypoechoic structures with acoustic enhancement at the distal edge.

4.6. Ocular ultrasonographic examination

Corneal oedema occurs with infectious keratoconjunctivitis, uveitis or direct corneal injury, making visual assessment of deeper structures of the eye difficult (El-Tookhy and Tharwat, 2013). Ultrasonographic examination of the globe can be possible, either through direct application of the transducer directly to the eyeball following application of a topical anaesthetic and ultrasound gel (El-Tookhy and Tharwat, 2013) or transpalpebrally (where the probe head is applied to the external aspect of the upper eyelid) (Potter et al., 2008). It is recommended to use a frequency of 20.0 MHz for good definition of structures of the anterior chamber; a frequency of 10.0 MHz is better for visualising structures of the posterior chamber. A lower frequency allows imaging of the retrobulbar structures, but gives poorer resolution of structures of the eye (Fig. 6). The corneal epithelium, Descemet's membrane, iris, ciliary body, anterior and posterior lens capsule and retina are all hyperechoic structures, whilst the lens body, corneal stroma and aqueous and vitreous humours are anechoic.

Ultrasonographic examination allows detection of hypopyon, iris thickening, cataract formation and abnormalities of the retrobulbar structures (El-Tookhy and Tharwat, 2013) (Fig. 6). Iris thickening and folding is known to occur with listerial uveitis ('silage eye') (Sargison, 1993); ultrasonographic examination may allow distinction between infectious keratoconjunctivitis IKC and listerial uveitis, when both have progressed to the stage of full corneal opacity, due to corneal oedema, but no specific studies have yet confirmed this hypothesis. The detection of significant changes to the ocular structures is a negative prognostic indicator for return to function with infectious diseases of the eye (El-Tookhy and Tharwat, 2013), hence results of ultrasonographic evaluation may be used to establish consequences of the disease for the welfare of affected animals.

4.7. Areas of more limited applicability of ultrasonographic examination

Ultrasonographic examination has been used to detect liver abscesses in cattle, but such lesions appear to be less common in adult sheep. In countries, where the visceral form of caseous lymphadenitis has been commonly reported, resultant liver abscesses could be detectable ultrasonographically (Scott and Sargison, 2010). Ultrasonographically detected changes associated with acute or subacute fasciolosis have been described (Gonzalo-Orden et al., 2003; Scott et al. 2005);

they include increased heterogeneity of the liver parenchyma, increased free abdominal fluid and presence of perihepatic fibrinous deposits. While diagnosis of acute fasciolosis is often made based on a combination of clinical signs, grazing history, time of year and weather conditions over the preceding months, ultrasonographic findings can potentially add further evidence for diagnosis of the disease and may be performed on farm and provide an immediate report, unlike serological, blood biochemical and parasitological test, which would require sending samples to respective laboratories and waiting some time before results become available. However, if levels of infection are not high, changes observed in images may be minimal, hence the technique is not as sensitive as laboratory methods (e.g., egg detection in faecal samples) provide.

Due to the complex nature of the ruminant gastrointestinal tract, results of ultrasonographic examination of this organ system may be hard to interpret. Some uses of ultrasonographic examination of the gastrointestinal tract of sheep include the following.

- Assessment of abdominal fill in newborn lambs as an indicator of colostrum intake (Scott and Sargison, 2010), although this may also be achieved by abdominal palpation of the neonate.
- Assessment of gut viability, i.e. level of peristalsis and dilation, in cases of abdominal catastrophe, although this disorder has a minute reported incidence risk in sheep; this, coupled with the difficulty of imaging distended gas-filled gut loops and given the low value of sheep, makes surgical intervention in such cases unlikely, hence results of imaging would be of little value to a practitioner.

Ultrasonographic assessment of the joints has been described (Macrae & Scott, 1999), but given that the joints most commonly affected by arthritis are palpable and that the technique requires particular expertise for application in the musculoskeletal system, ultrasonographic examination is unlikely to add much to the results of a thorough clinical examination.

Ultrasonographic examination of vaginal prolapses, to determine whether the bladder is present within the prolapse, has been described (Scott and Sargison, 2010). As the obstetrical technique for replacement and retention of the vaginal prolapse is not greatly altered by this information, the practical applications of the method in this instance are limited.

5. Current barriers to further use

Ultrasound equipment is available to most veterinary practitioners working with sheep, but diagnostic potential of ultrasonographic examination appears to be under-used at the current time. This may be partially due to lack of specialised knowledge by practitioners regarding capabilities of the technique and diagnostic deficiencies in interpreting findings, other than those related to pregnancy diagnosis. Moreover, reluctance of farmers, in some countries, to present individual sheep for veterinary assessment would also contribute to slowing the development of this expertise by the practitioner. Finally, where relevant work regarding a disorder in other animal species has indicated

ultrasonographic examination could be of value to practicing veterinarians, lack or reduced availability of specific reference work performed in sheep might hamper application of the technique.

6. Concluding remarks

In conclusion, ultrasonographic examination is widely used in small ruminant practice in pregnancy diagnosis, however the diagnostic capacity of the method stretches far beyond this. There are a variety of conditions, where evidence of the diagnostic applicability of ultrasonography in sheep health management exists, even where these techniques are not yet widely used, and others where the potential use of ultrasonography is clear, but further work is needed to provide practitioners with knowledge to fully utilise this versatile tool.

Conflict of interest statement

The authors have nothing to disclose.

References

- Ali, A., Hayder, M., 2007. Ultrasonographic assessment of embryonic, foetal and placental development in Ossimi sheep. *Small Rumin. Res.* 73, 277-282.
- Biswas, D., 2013. Ultrasound diagnosis and surgical treatment of coenurosis (Gid) in Bengal goat (*Capra hircus*) at Chittagong metropolitan area, Chittagong, Bangladesh. *Sci. J. Vet. Adv.* 2, 68-75.
- Braun, U., Schefer, U., Fohn, J., 1992. Urinary tract ultrasonography in normal rams and in rams with obstructive urolithiasis. *Can. Vet. J.* 33, 654-659.
- Braun, U., Hagen, A., Pusterla, N., Caplazi, P., 1995. Echocardiographic diagnosis of a cardiac fibrosarcoma in the right atrium of a sheep. *Schweiz. Arch. Tierheilkd.* 137, 187-192.
- Bruere, A.N., West, D.M., 1993. Clinical aspects of trace element requirements of grazing ruminants with particular reference to sheep and cattle. In: Bruere, A.N., West, D.M. (eds) *The Sheep: Health, Disease and Production*. Foundation for Continuing Education of the New Zealand Veterinary Association, Wellington, pp. 101-150.
- Buczinski, S., Rezakhani, A., Boerboom, D., 2010. Heart disease in cattle: diagnosis, therapeutic approaches and prognosis. *Vet. J.* 184, 258-263.
- Chalmers, H.J., Cheetham, J., Yeager, A.E., Ducharme, N.G., 2006. Ultrasonography of the equine larynx. *Radiol. Ultrasound* 47, 476-481.
- Cousens, C.R., Scott, P.R., 2015. Assessment of transthoracic ultrasound diagnosis of ovine pulmonary adenocarcinoma in adult sheep. *Vet. Rec.* 177, 366.
- Crilly, J.P., Morrison, L.R., Scott, P.R., 2015. Endocarditis and ventricular wall abscessation in a vasectomised Herdwick ram. *Vet. Rec. Case Rep.* 3:e000178.
- Doize, F., Vaillancourt, D., Carabin, H., Belanger, D., 1997. Determination of gestational age in sheep and goats using transrectal ultrasonographic measurement of placentomes. *Theriogenology* 48, 449-460.
- Dore, F., Varcasia, A., Pipia, A.P., Sanna, G., Pinna Parpaglia, M.L., Corda, A., Romig, T., Scala, A., 2014. Ultrasound as a monitoring tool for cystic echinococcosis in sheep. *Vet. Parasitol.* 203, 59-64.
- El-Tookhy, O., Tharwat, M., 2013. Clinical and ultrasonographic findings in some ocular conditions in sheep and goats. *Open Vet. J.* 3, 11-16.
- Franz, S., Hofmann-Parisot, M., Güttler, S., Baumgartner, W., 2003. Clinical and ultrasonographic findings in the mammary gland of sheep. *N. Z. Vet. J.* 51, 238-243.
- Garrett, K.S., Embertson, R.M., Woodie, J.B., Cheetham, J., 2013. Ultrasound features of arytenoid chondritis in Thoroughbred horses. *Eq. Vet. J.* 5, 598-603.
- Gonzalo-Orden, M., Millan, L., Alvarez, M., Sanchez-Campos, S., Jimenez, R., Gonzalez-Gallego, J., Tunon, M.J., 2003. Diagnostic imaging in sheep hepatic fascioliasis: ultrasound, computer tomography and magnetic resonance findings. *Parasitol. Res.* 90, 359-364.
- Gouletsou, P.G., Amiridis, G.S., Cripps, P.J., Lainas, T., Deligiannis, K., Saratsis, P., Fthenakis, G.C., 2003. Ultrasonographic appearance of clinically health testicles and epididymides of rams. *Theriogenology* 59, 1959-1972.
- Hallowell, G.D., Potter, T.J., Bowen, I.M., 2012. Reliability of quantitative echocardiography in adult sheep and goats. *BMC Vet. Res.* 8, 181-192.
- Jones, A.K., Gately, R.E., McFadden, K.K., Zinn, S.A., Govoni, K.E., Reed, S.A., 2016. Transabdominal ultrasound for detection of pregnancy, fetal and placental landmarks, and fetal age before day 45 of gestation in the sheep. *Theriogenology* 85, 939-945.
- Karen, A., Szabados, K., Reiczigel, J., Beckers, J-F., Szenci, O., 2004. Accuracy of transrectal ultrasonography for determination of pregnancy in sheep: effect of fasting and handling of the animals. *Theriogenology* 61, 1291-1298.
- Lahmar, S., Ben Chehida, F., Petavy, A.F., Hammou, A., Lahmar, J., Ghannay, A., Gharbi, H.A., Sarciron, M.E., 2007. Ultrasonographic screening for cystic echinococcosis in sheep in Tunisia. *Vet. Parasitol.* 143, 42-49.
- Lane, J.G., Brown, P.J., Lancaster, M.L., Todd, J.N., 1987. Laryngeal chondritis in Texel sheep. *Vet. Rec.* 121, 81-84.

- Macrae, A.I., Scott, P.R., 1999. The normal ultrasonographic appearance of ovine joints and the uses of arthrosonography in the evaluation of chronic ovine joint disease. *Vet. J.* 158, 135-143.
- Magda, A.M., Abd El-Hakiem, M.A.H., 2012. Ultrasonographic differential diagnosis of superficial swellings in farm animals. *J. Adv. Vet. Res.* 2, 292-298.
- Mavrogianni, V.S., Fthenakis, G.C., Burriel, A.R., Gouletsou, P., Papaioannou, N., Taitzoglou, I.A., 2004. Experimentally induced teat stenosis in dairy ewes: clinical, pathological and ultrasonographic features. *J. Comp. Path.* 130, 70-74.
- Mickelsen, W.D., Weber, J.A., Memon, M.A., 1994. Use of transrectal ultrasound for the detection of seminal vesiculitis in a bull. *Vet. Rec.* 135, 14-15.
- Potter, T.J., Hallowell, G.D., Bowen, I.M., 2008. Ultrasonographic appearance of the bovine eye. *Vet. Radiol. Ultrasound* 49, 172-175.
- Russel, A., 1985. Nutrition of the pregnant ewe. In *Pract.* 7, 23-29.
- Sage, A.M., Wachira, T.M., Zeyhle, E.E., Weber, E.P., Njoroge, E., Smith, G., 1998. Evaluation of diagnostic ultrasound as a mass screening technique for the detection of hydatid cysts in the liver and lung of sheep and goats. *Int. J. Parasitol.* 28, 349-353.
- Sargison, N. 1993. Health hazards associated with the feeding of big bale silage. In *Pract.* 2, 291-297.
- Scott, P.R., 2007. *Sheep Medicine*, Manson Publishing.
- Scott, P.R., 2012. Diagnosis and treatment of coenurosis in sheep. *Vet. Parasitol.* 189, 75-78.
- Scott, P.R., 2012. Ram breeding soundness - some common scrotal and testicular abnormalities. *Livestock* 17, 37-41.
- Scott, P.R., Collie, D., McGorum, B., Sargison, N., 2010. Relationship between thoracic auscultation and lung pathology detected by ultrasonography in sheep. *Vet. J.* 186, 53-57.
- Scott, P.R., Gessert, M.E., 1998. Ultrasonographic examination of the ovine thorax. *Vet. J.* 155, 305-310.
- Scott, P.R., Gessert, M.E., 2000. Application of ultrasonographic examination of the ovine foetus in normal sheep and those presenting with obstetrical problems. *Vet. J.* 159, 291-292.
- Scott, P.R., Sargison, N.D., 2001. Extensive ascites associated with vegetative endocarditis and *Sarcocystis* myositis in a shearling ram. *Vet. Rec.* 149, 240-241.
- Scott, P.R., Sargison, N.D., 2010. Ultrasonography as an adjunct to clinical examination in sheep. *Small Rumin. Res.* 92, 108-119.
- Scott, P.R., Sargison, N.D., Macrae, A., Rhind, S.R., 2005. An outbreak of subacute fasciolosis in Soay sheep: ultrasonographic, biochemical and histological studies. *Vet. J.* 170, 325-331.
- Sergeev, L., Kleeman, D.O., Walker, S.K., Smith, D.H., Grosser, T.I., Mann, T., Seamark, R.F., 1990. Real-time ultrasound imaging for predicting ovine fetal age. *Theriogenology* 34, 593-601.
- Vencato, J., Romagnoli, S., Stelletta, C., 2014. Trans-scrotal ultrasonography and testicular fine-needle aspiration cytology in the evaluation of ram sperm production. *Small Rumin. Res.* 120, 112-115.
- White, L.R., Russel, A.J., Fowler, D.G., 1984. Real-time ultrasonic scanning in the diagnosis of pregnancy and determination of foetal numbers in sheep. *Vet. Rec.* 115, 140-143.

Legends to figures

Fig. 1. Ultrasound scanner with linear array probe designed for bovine and equine *per rectam* reproductive tract ultrasonographic examination, which may also be used for a wide variety of uses in ovine ultrasonography.

Fig. 2. (a) At the earliest detectable stage of pregnancy, uterine lumen imaged distended with anechoic fluid and embryo imaged; (b) at day 40 of intrauterine life, head, eye and limb buds of foetus can be distinguished; (c) at day 45 of intrauterine life, foetus can be seen; (d) at day 45 of intrauterine life, imaging of twin foetuses, imaged at a single field; (e) at day 90 of intrauterine life, imaging of hindquarters of foetus.

Fig. 3. (a) Hydrometra in ewe, distinguished from true pregnancy by lack of foetus and/or placentomes and multiloculated appearance in images; (b) pyometra in ewes, characterised by distended uterine lumen full echoic fluid of fine-grained texture.

Fig. 4. Removal of the hair and/or fleece from the scrotum allows better contact of transducer and thus better image quality; epididymitis causing scrotal enlargement.

Fig. 5. (a) Visualisation of distended urinary bladder supporting diagnosis of urinary obstruction; (b) hydronephrosis; (c) imaging of uroabdomen indicative of adverse prognosis.

Fig. 6. A retrobulbar abscess identified by transpalpebral ultrasonographic examination, as causing exophthalmos in a ewe.

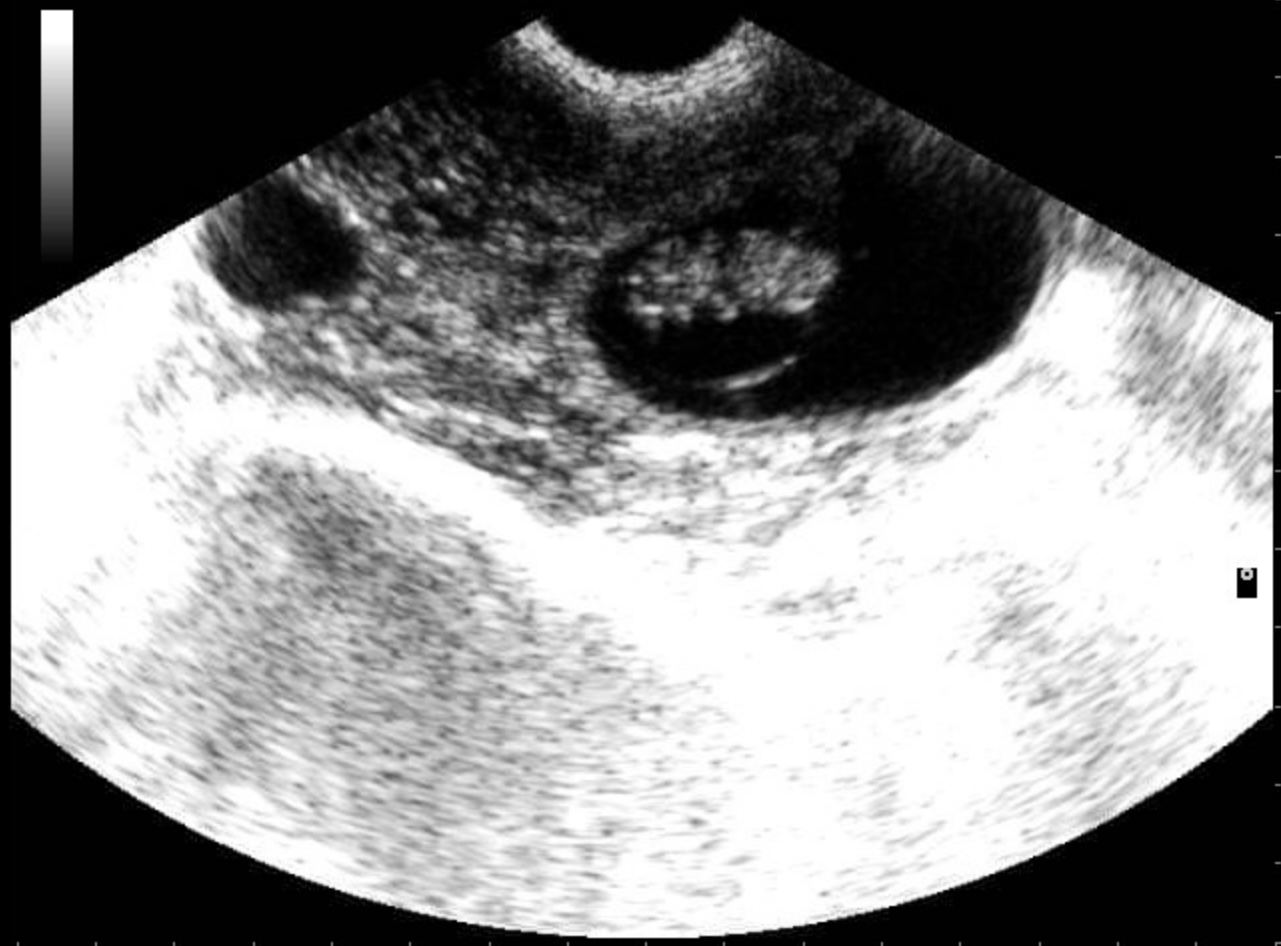Fig. 7. Ultrasonographic images of left (a) and right (b) arytenoid cartilages and associated soft tissues in sheep with clinical signs of laryngeal chondritis; architecture of the right side of the larynx imaged disrupted relative to the left.



B F 3.3 MHz G 52%
D 12 cm XV -
PRC 9-2-H PRS 3
PST 4

0:00:03.00

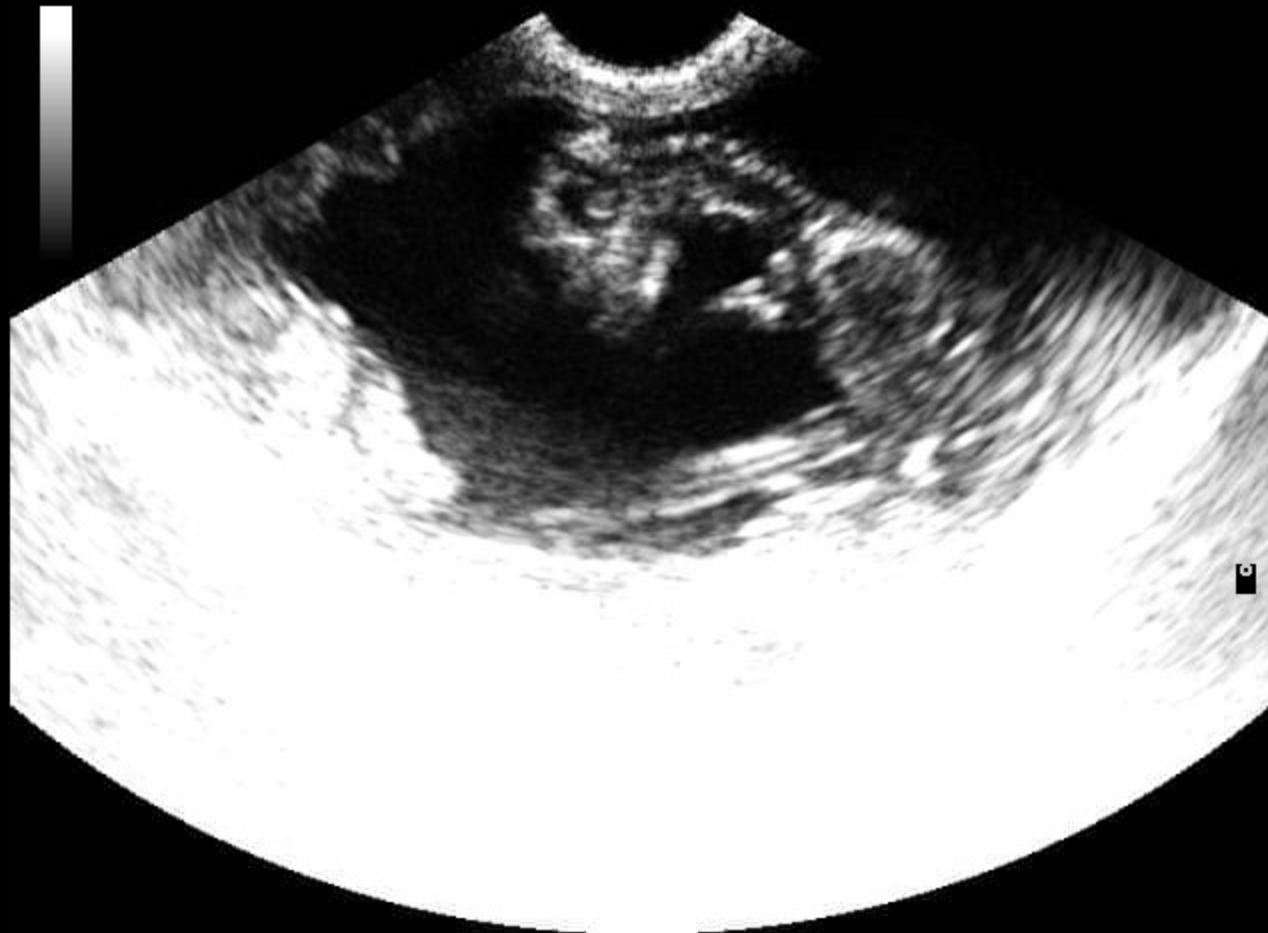FACTORY C5-2



B F 3.3 MHz G 94%
D 12 cm XV 2
PRC 10-2-H PRS 4
PST 4

0:00:01.35

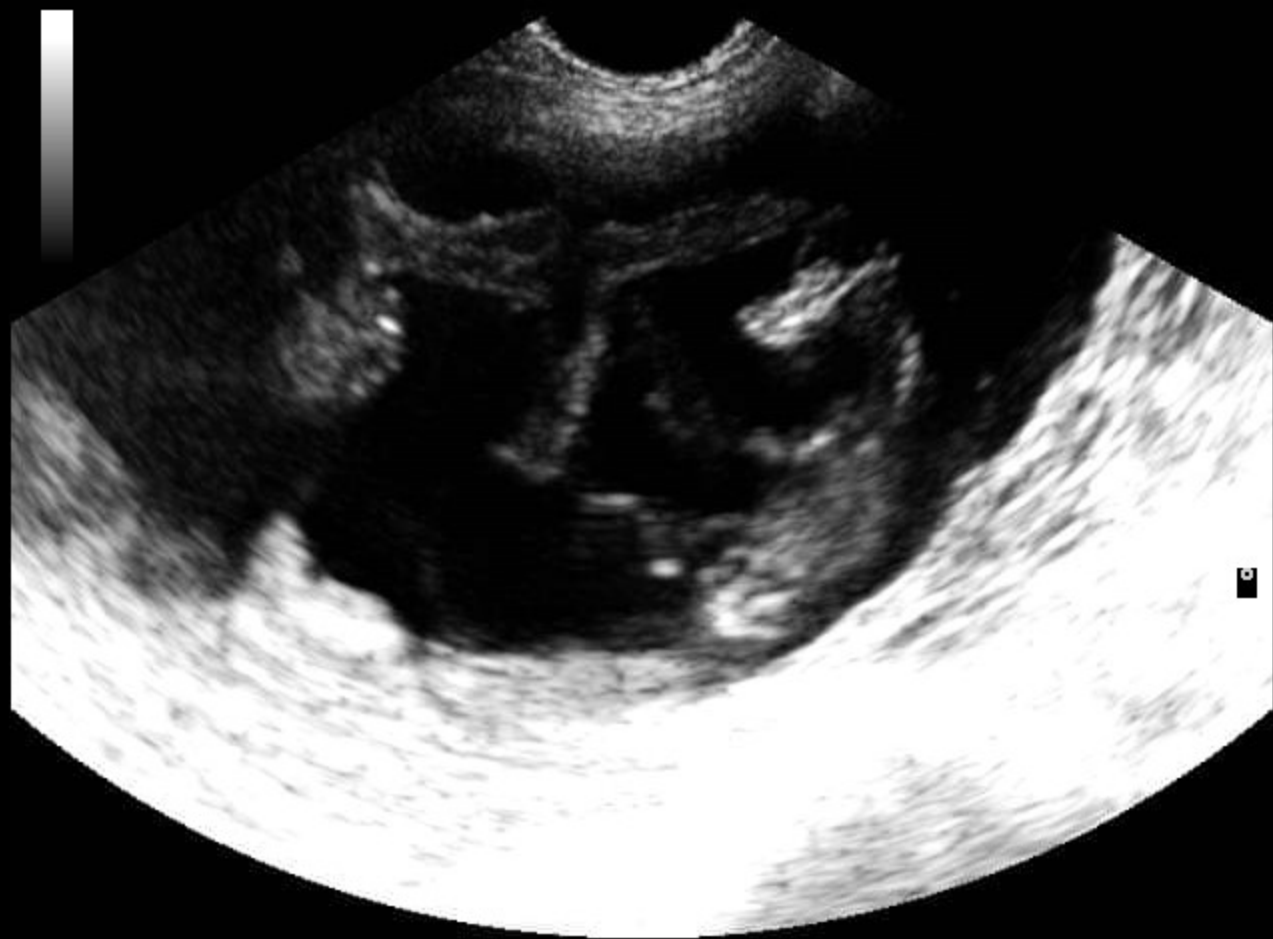FACTORY C5-2



B F 3.3 MHz G 28%
D 12 cm XV 2
PRC 10-2-H PRS 4
PST 4

0:00:00.29

FACTORY C5-2

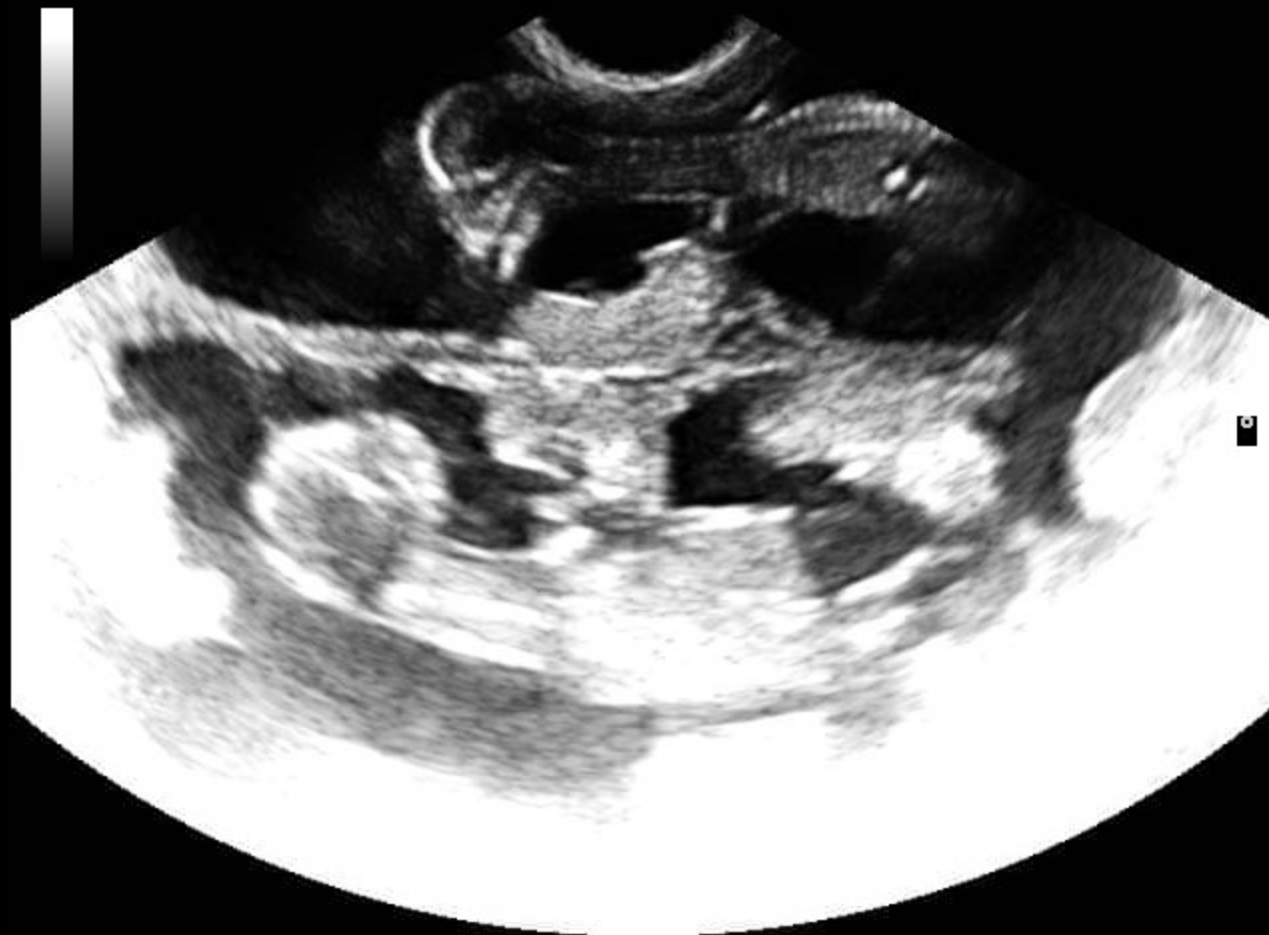

5

B F 3.3 MHz G 49%
D 12 cm XV C
PRC 10-2-H PRS 4
PST 4

0:00:03.00

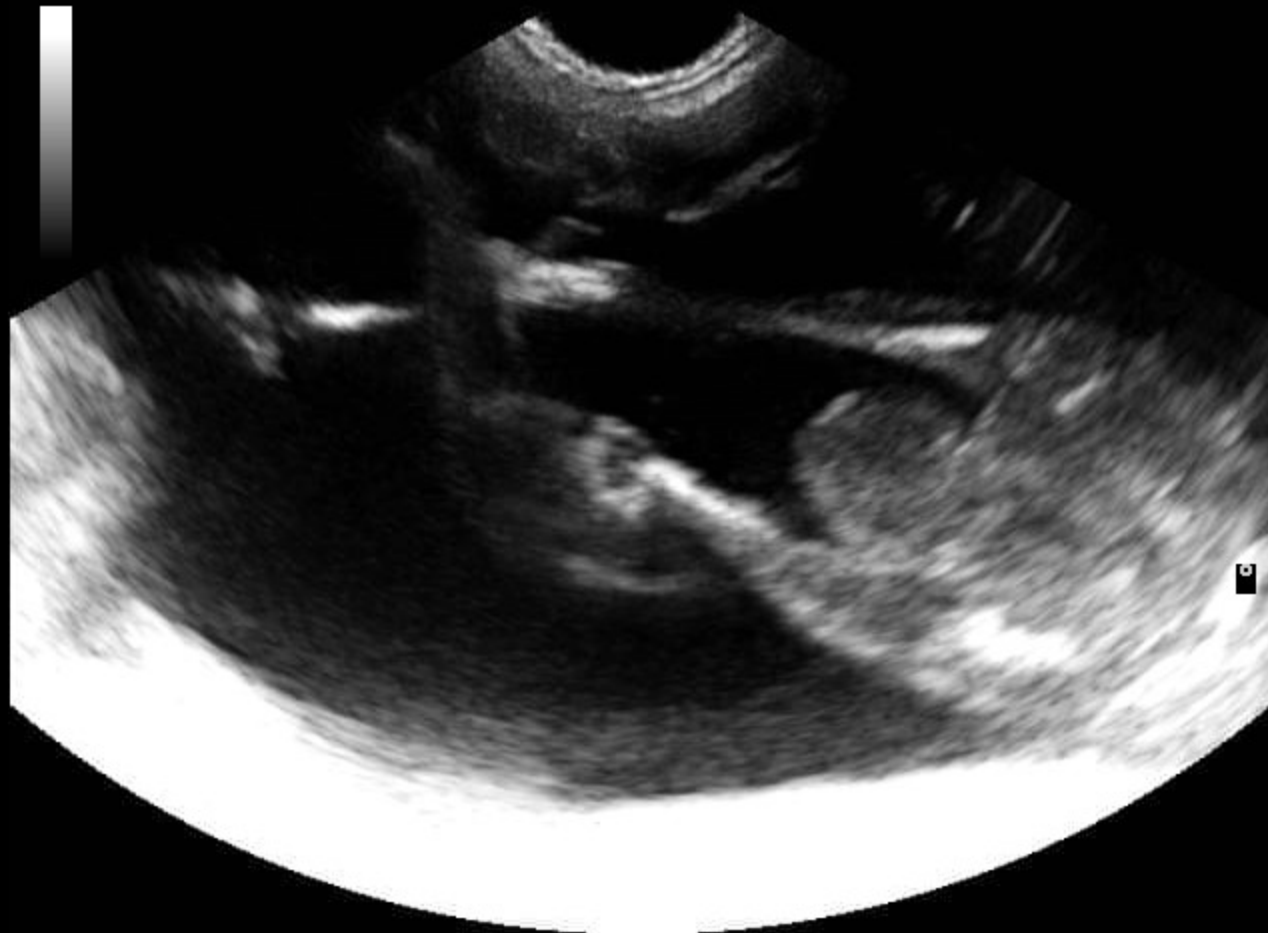PRESET31 C5-2



8

B F 3.3 MHz G 52%
D 12 cm XV C
PRC 10-2-H PRS 4
PST 4

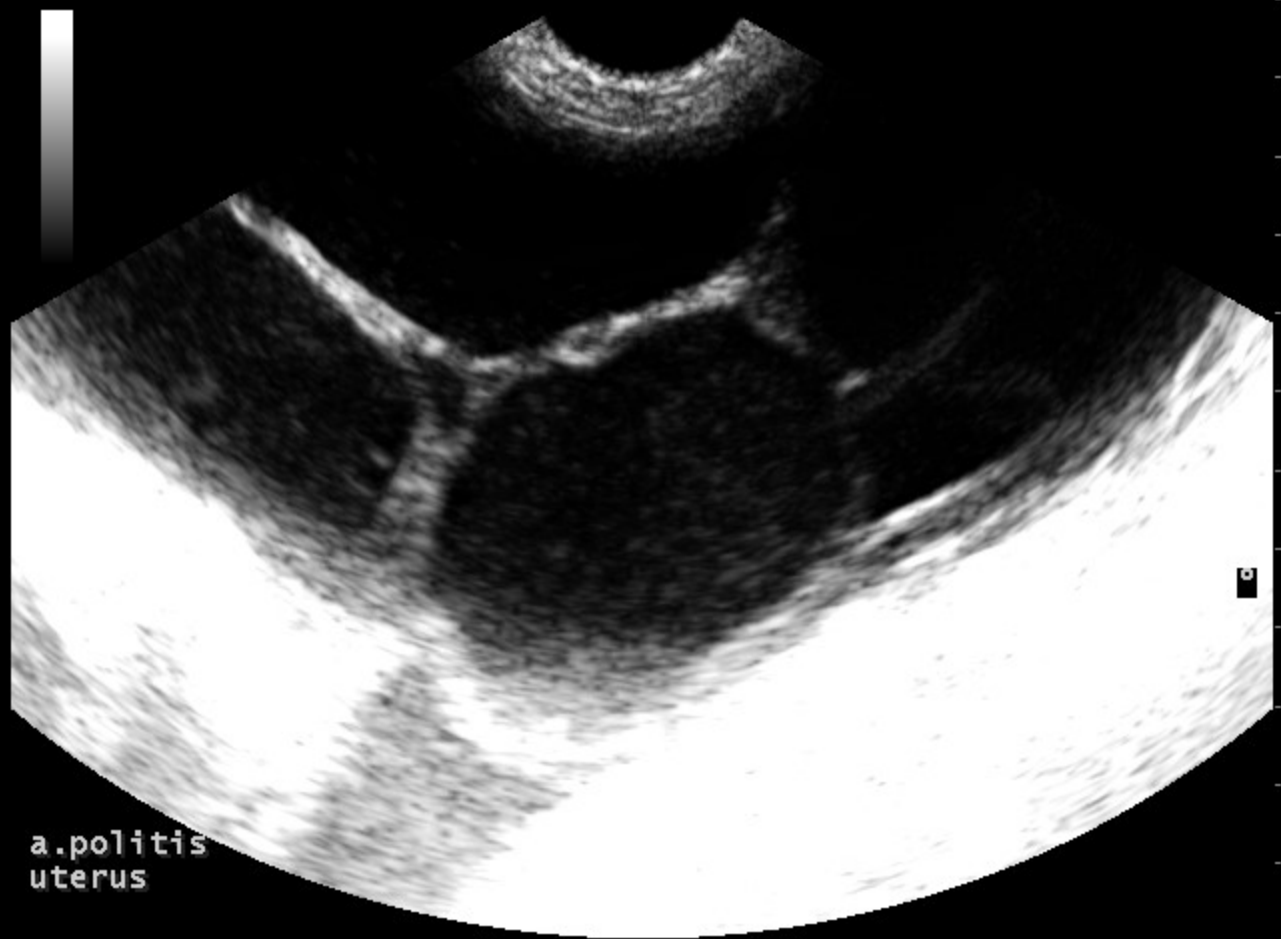PRESET31 C5-2



DARA YDROMITRA

N:No, , ,
B F 5.0 MHz G 40%
D 12 cm XV 2
PRC 9-2-H PRS 3
PST 4

FACTORY C5-2

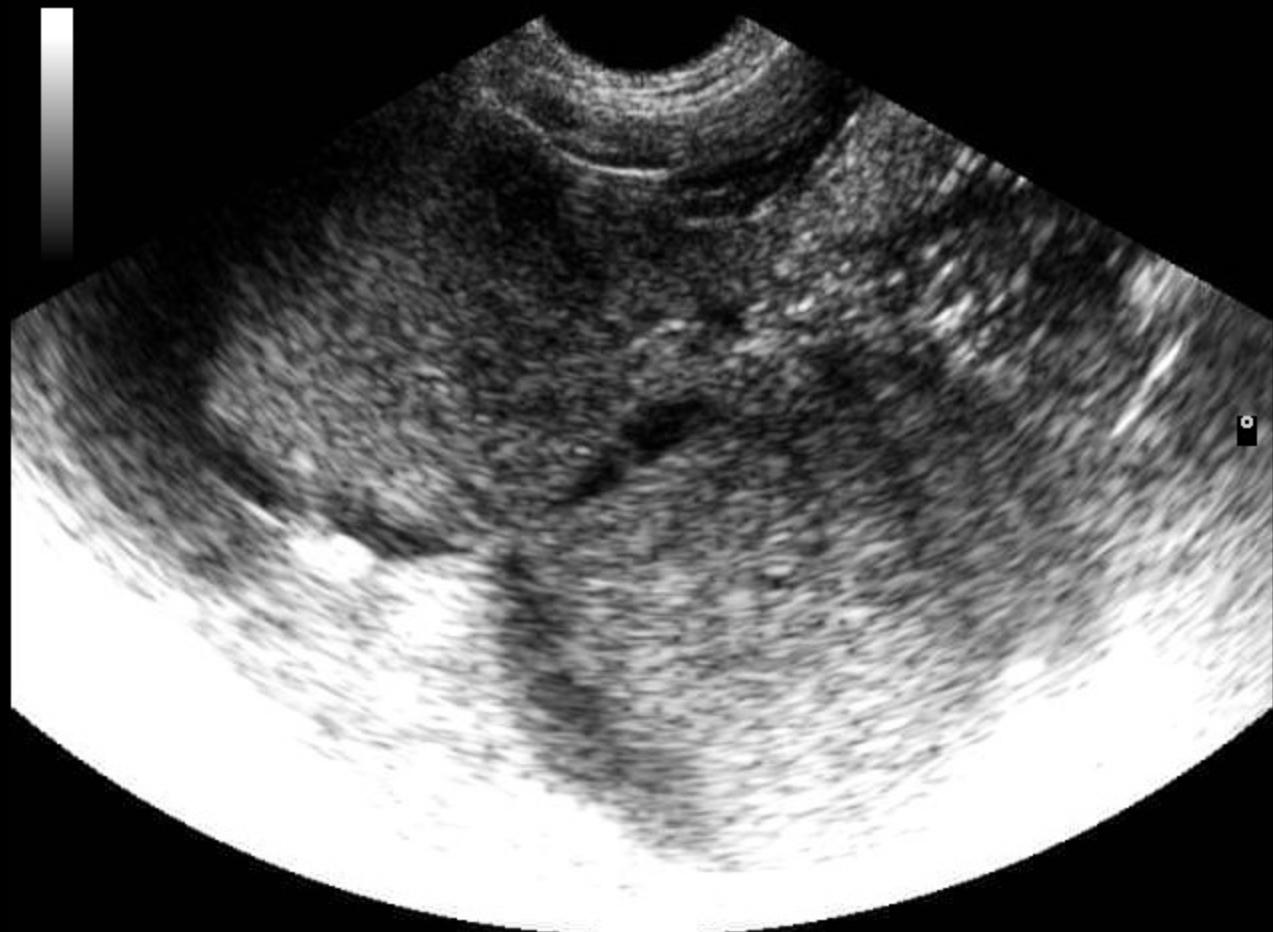

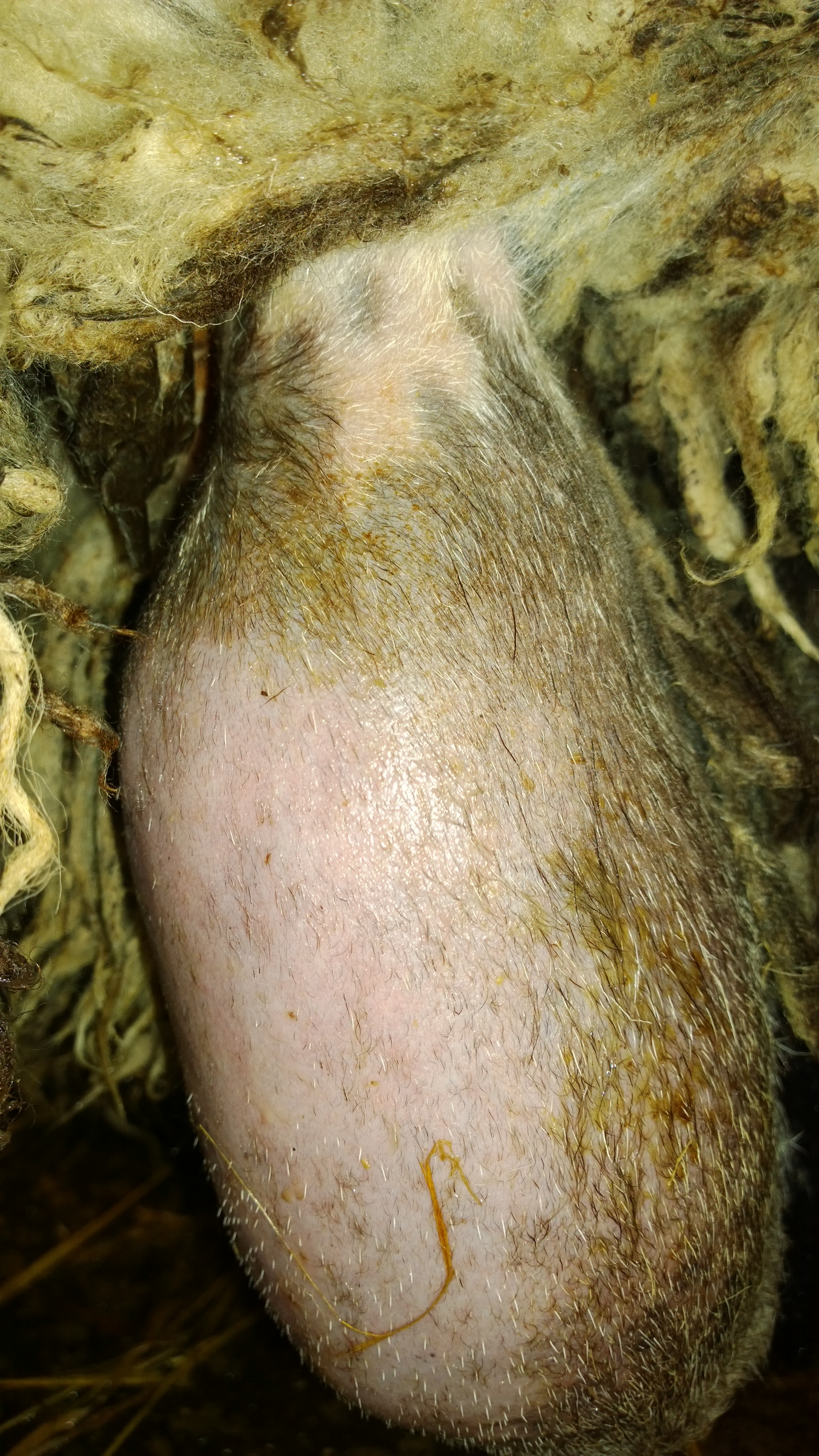a.politis
uterus

B F 3.3 MHz G 52%
D 12 cm XV -
PRC 10-2-H PRS 4
PST 4

0:00:01.99

FACTORY C5-2





65C15EA AP 100% MI 0.3 TIS 0.2

DP-50Vet

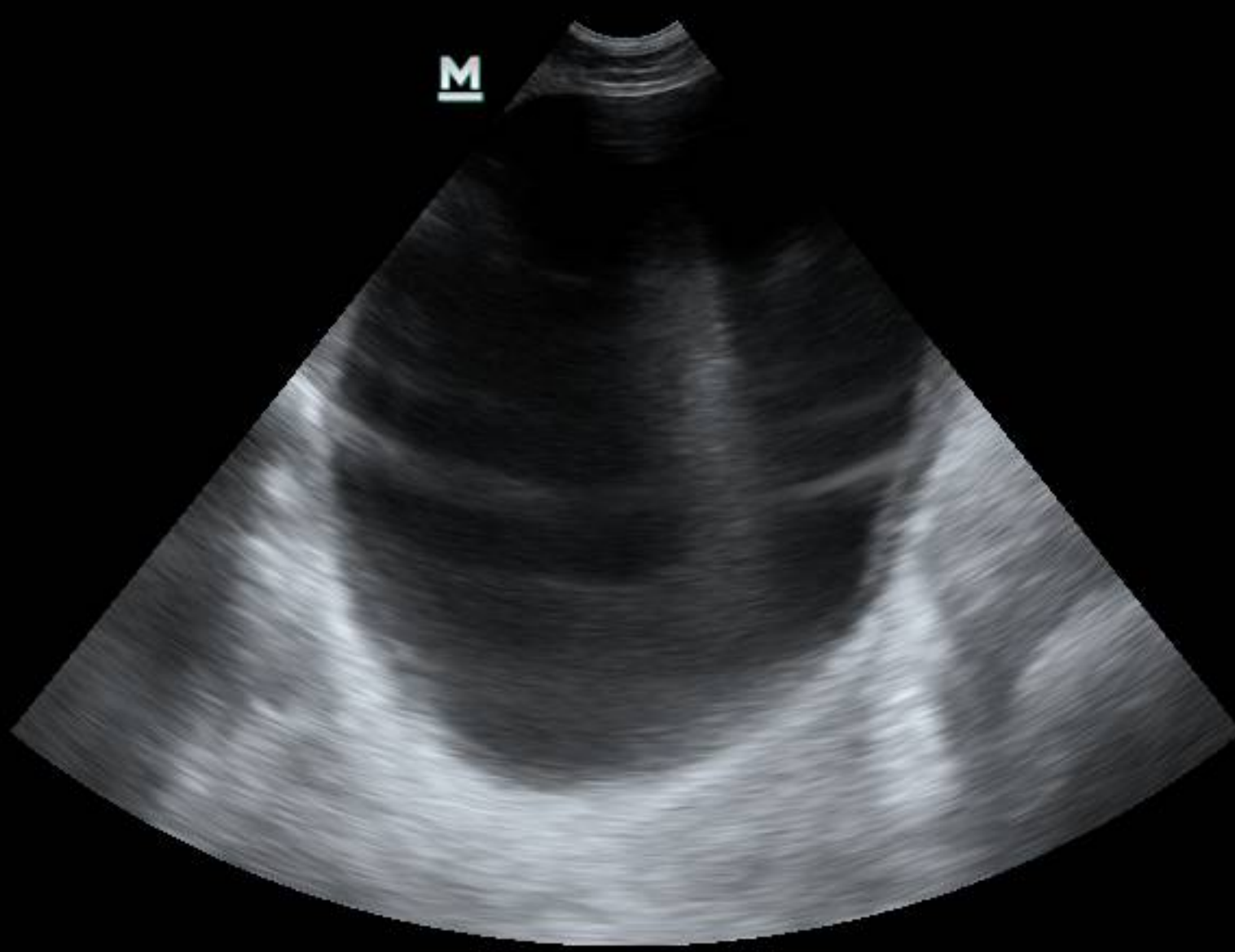
Dog Abdomen

B

F6.5M / D16.6

G62 / FR31

IP5 / DR110



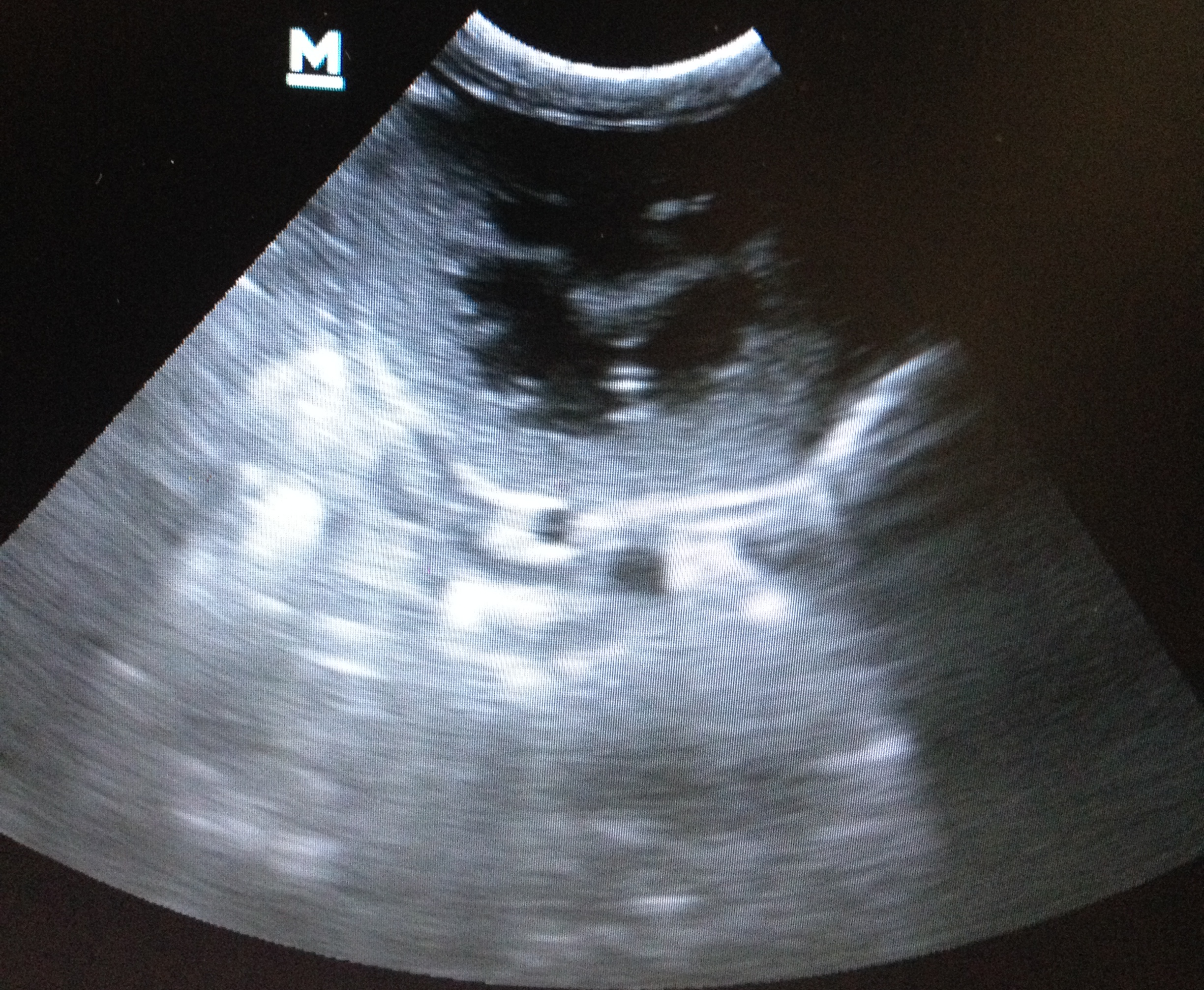
M

0
-
-
-
-
-
5
-
-
-
-
-
10
-
-
-
-
15
-

University of Edinburgh

100% MI 0.3 TIS 0.3

M

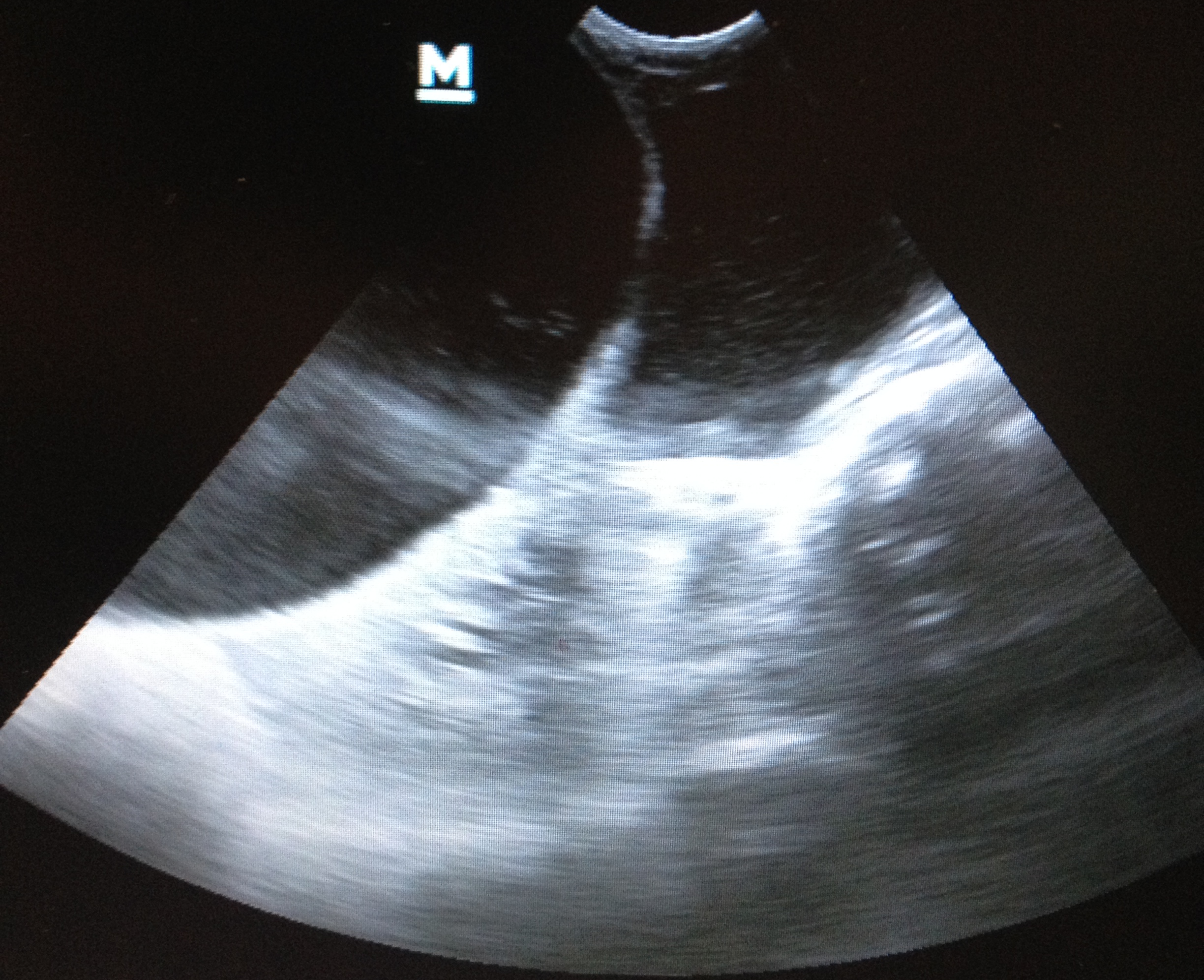


ay

University of Edinburgh

AP 100% MI 0.3 TIS 0.3

M



▲ ——— | 485/485



65C15EA AP 100% MI 0.3 TIS 0.3

DP-50Vet

Dog Abdomen

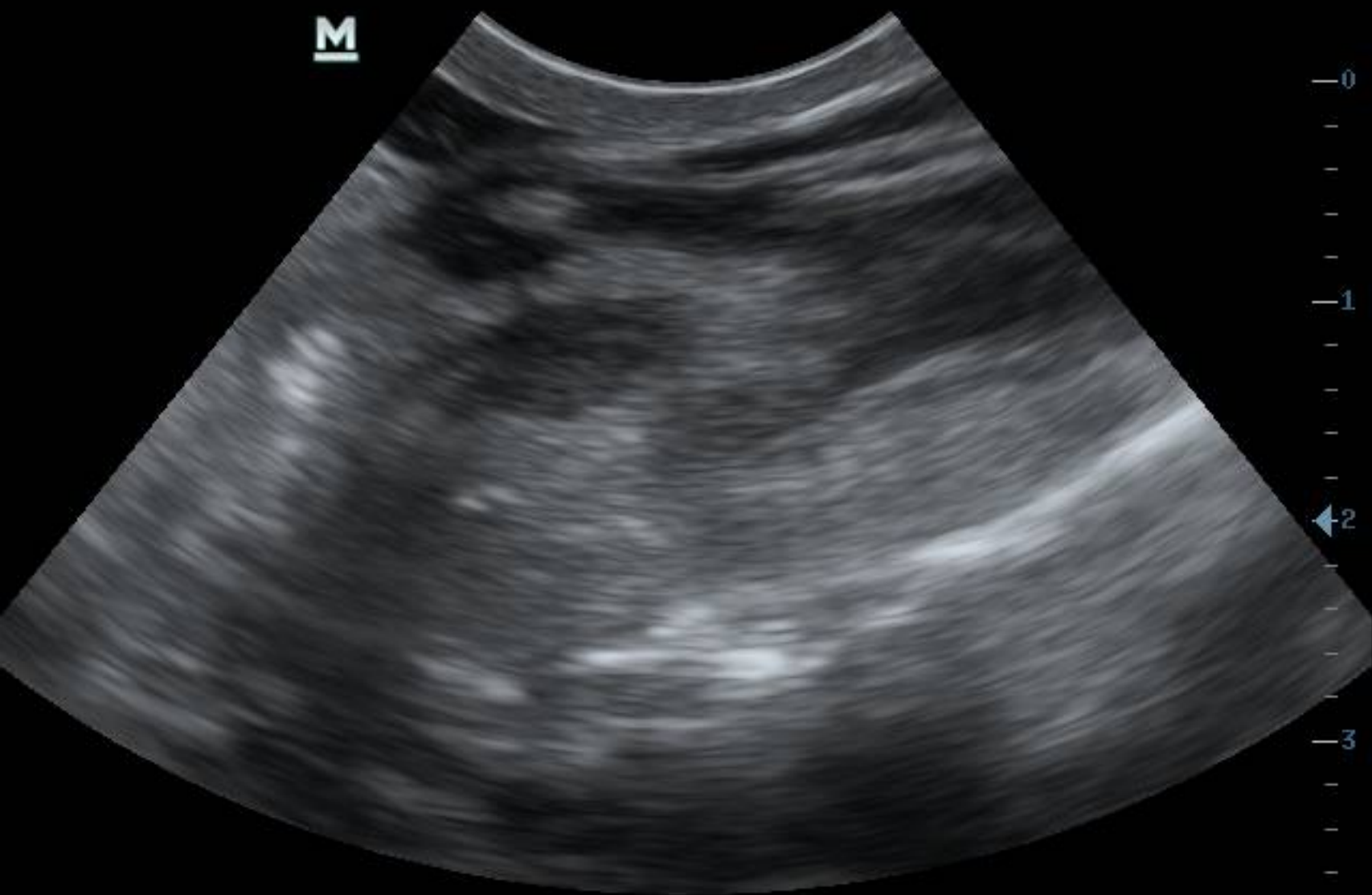B

F7.5M / D3.7

G62 / FR69

IP5 / DR110

M



0

1

2

3