

Journal section: Oral Surgery

Publication Types: Review

doi:10.4317/medoral.17078

<http://dx.doi.org/doi:10.4317/medoral.17078>

Ocular complications following dental local anesthesia

Jose-Maria Aguado-Gil ¹, Cristina Barona-Dorado ², Juan-Carlos Lillo-Rodríguez ³, David-Sebastian De la Fuente-González ⁴, Jose-Maria Martínez-González ⁵

¹ Dentist. Master's degree in Dental Sciences. Student in the Master's program in Oral Surgery and Implantology at the University Hospital of Madrid

² Associate Professor of Oral Surgery. School of Dentistry. Complutense University of Madrid

³ Dentist. Assistant Director of the Master's program in Oral Surgery and Implantology. University Hospital of Madrid

⁴ Dentist. Collaborating Professor. School of Dentistry. Complutense University of Madrid

⁵ Professor of Maxillofacial Surgery. School of Dentistry. Complutense University of Madrid. Head of the Department of Oral Surgery and Implantology. University Hospital of Madrid

Correspondence:

School of Dentistry

Pza Ramón y Cajal s/n

Madrid, Spain

hospimar@hotmail.com

Aguado-Gil JM, Barona-Dorado C, Lillo-Rodríguez JC, De la Fuente-González DS, Martínez-González JM. Ocular complications following dental local anesthesia. Med Oral Patol Oral Cir Bucal. 2011 Aug 1;16 (5):e688-93.

<http://www.medicinaoral.com/medoralfree01/v16i5/medoralv16i5p688.pdf>

Received: 27/04/2010

Accepted: 21/05/2010

Article Number: 17078 <http://www.medicinaoral.com/>
© Medicina Oral S. L. C.I.F. B 96689336 - pISSN 1698-4447 - eISSN: 1698-6946

eMail: medicina@medicinaoral.com

Indexed in:

Science Citation Index Expanded
Journal Citation Reports
Index Medicus, MEDLINE, PubMed
Scopus, Embase and Emcare
Índice Médico Español

Abstract

Objective: To determine the frequency of appearance and the factors most commonly associated with ocular complications following dental local anesthesia, also establishing the location and type of anesthesia used.

Study Design: An indexed search in the Pubmed and Compludoc databases was carried out with the keywords "oral anesthesia", "ocular", "ophthalmologic", "damage", "complications", "injection". We established a limitation that the literature had to have been published after the year 1970. A total of 19 articles were obtained, forming a total sample of 37 patients. The patient's sex, age, nerve anesthetized, type of anesthetic used, ophthalmological complication present, recovery time, treatment and side effects were analyzed.

Results: There is a higher involvement of females (77%). The average age was 34.2 years. There was no preference for an anesthetic technique. Diplopia was the most common complication (65%), which coincides with the data from other authors. Almost all of the complications were of a temporary nature, with an average recovery time of 68 minutes.

Conclusions: This is one of the few studies of its kind in dental literature, it thus being difficult to make precise conclusions. Ophthalmological complications are seldom a problem, diplopia being the most common among them. The authors appear to indicate an intravascular injection of the anesthetic as the cause of the problem, and therefore, it should be avoided in order to prevent accidents at the ocular level.

Key words: Accidents, ophthalmology, dental anesthesia.

Introduction

For many years, dental literature describes signs and symptoms at the ophthalmic level following injection of anesthesia into the oral cavity, both in regional techniques at a superior level, due to the proximity with the orbital region, as well as in the mandibular blocking of the inferior dental nerve.

The main complications that may occur in regards to intraoral anesthesia may include: temporary diplopia, transitory unilateral amaurosis, strabismus due to paralysis of the extrinsic muscles of the eye, and palpebral ptosis. To date, the mechanism that produces such complications is unclear, although the authors suggest an intravascular injection of the anesthetic, which would follow a retrograde path towards the infraorbital artery or the middle meningeal artery.

Despite being described as a local type of complication of anesthesia, the ocular alterations are quite uncommon, representing approximately 0.1% of the complications.

The purpose of this study was to determine the ocular complications that appear most frequently following administration of dental local anesthesia, seeking to determine the relationship with a certain common factor or variable, as well as the presence of such complications according to the anesthetic technique and type of anesthetic used, and finally, to determine the duration of the ocular complications.

Study Design

An indexed search in the Pubmed and Compludoc databases was carried out with the keywords "oral anesthesia", "ocular", "ophthalmologic", "damage", "complications", "injection". As inclusion criteria, we took into consideration that there had to be at least one case described of an ocular alteration following some type of anesthetic procedure carried out in the mouth; and that each and every one of the following variables was taken into account in the description of the case: age and sex of the patient, type and location of the anesthesia, main complication present and accompanying symptoms, duration of the event, treatment applied and whether or not the patient experienced any side effects. The search was limited to articles published after 1970.

With these criteria, we obtained a total of 22 articles (Table 1), considering in each and every one of them the variables that are described as follows, forming a total sample of 35 patients (1-19).

The method used consisted of a descriptive statistical analysis of the following variables:

1. Sex: male (M) or female (F), in percentage and ratio.
2. Age: the exact age of each patient described in each article was used, after which the different statistical variables within this section were calculated.
3. Ophthalmological complication: the ocular complica-

tion present in each case was recorded. The accompanying signs present were also noted.

4. **Technique:** the patients were distinguished according to whether the anesthesia was administered on the inferior dental nerve (IDN) or on the posterior superior alveolar nerve (PSAN).

5. **Anesthetic:** both the type of anesthetic and its concentration (in %) has been described, as well as the vasoconstrictor used and in what proportion.

6. **Recovery time:** expressed in minutes or hours.

7. **Treatment** carried out by the professional at the time that the ocular alteration occurs.

8. **Side effects:** if any complications remain after the time for recovering sensitivity after anesthesia.

Results

Sex: Of the 35 cases selected, 7 affected males (20%) and 28 affected females (80%), which results in a F/M ratio of 4:1.

Age: The average age of the patients included in the meta-analysis was 29.5 years old. The mean of the distribution of the data, 32 years, and the mode, which repeats on 3 occasions, is 25 years old. The range of age is from 4 to 73 years old (Fig. 1). The age interval with the highest number of patients was from 20-29 years old.

Anesthetic technique: a technique was practiced on the posterior superior alveolar nerve in 19 patients and a direct mandibular block was administered in 15 patients, as well as a case in which both techniques were practiced.

Ocular complication: The most common ocular complication was diplopia, present in 23 cases (66%), followed by palpebral ptosis in 12 cases (34%), midriasis in 5 cases (14%), unilateral transitory amaurosis and blurry vision in 4 patients (11%) and Horner syndrome and strabismus, affecting 9% and 6% of the patients, respectively (Fig.2). Other ocular complications, which are not included in the table due to being very uncommon, were ophthalmoplegia, myosis and sudden blackout, all present in a single case (3%), along with permanent amaurosis.

In terms of other signs and associated symptoms, the following is worth noting: ischemia or paleness of the area, which was present in 7 of the patients; numbing of the periorbital area and burning of the eye, both present in three patients.

Recovery time: The range of recovery time varied from 10 minutes to 24 hours. The average time was 63 minutes. For the calculation, the only case in which recovery from the side effects did not occur was not taken into account, nor was the case of 24 hours, due to being very far from the rest of the results, which would significantly modify the data. Thus, only 33 of the 35 patients were taken into account when calculating the recovery time (Fig. 3).

Table 1. Articles and selected cases. Variables analyzed.

AUTHOR	NO. CASES	SEX	AGE	OCCULAR COMPLICATION	TECHNIQUE	TIME (min.)
Rood JP (1) (1972)	1	F	24	Ptosis, diplopia	IDN	45
Campbell RL (2) (1979)	1	F	34	Ptosis, myosis	IDN	120
Petrelli EA (3) (1980)	1	F	42	Diplopia	PSAN	90
Norris L (4) (1982)	1	F	17	Diplopia	IDN	20
Goldenberg AS (5) (1983)	1	F	58	Diplopia, strabismus and unilateral transitory amaurosis	IDN	20
Kronman JH (6) (1984)	1	F	37	Diplopia	PSAN	50
Clarke JR (7) (1987)	1	F	10	Unilateral transitory amaurosis and diplopia	PSAN	30
Goldenberg A (8) (1990)	1	F	31	Diplopia, blurred vision	PSAN	180
Dryden JA (9) (1993)	1	F	33	Diplopia and ptosis	IDN	90
Marinho R (10) (1995)	1	M	25	Diplopia	PSAN	180
Van der Bijl P (11) (1996)	1	F	14	Diplopia	IDN	1440
Spierer A (12) (1999)	2	F	5	Diplopia, strabismus	IDN	15
		M	4	Ptosis	IDN	20
Peñarrocha M (13) (2000)	14	F	65	Palpebral ptosis, Enophthalmos, Myosis	PSAN	50
		F	29	Palpebral ptosis, Enophthalmos, Myosis	PSAN	20
		M	53	Palpebral ptosis, Enophthalmos, Myosis	PSAN	40
		F	49	Diplopia, ptosis, mydriasis	PSAN	45
		F	60	Diplopia, ptosis, mydriasis	PSAN	30
		F	25	Diplopia, ptosis, mydriasis	PSAN	60
		F	24	Diplopia	PSAN	30
		F	32	Diplopia	PSAN	45
		F	22	Diplopia	PSAN	60
		M	35	Diplopia	PSAN	90
		F	40	Diplopia	PSAN	120
		F	73	Diplopia	PSAN	120
F	65	Diplopia	PSAN	50		
F	40	Diplopia	PSAN	30		
Wilkie GJ (14) (2000)	1	M	45	Unilateral transitory amaurosis, mydriasis, ptosis, diplopia	IDN	30
Webber B (15) (2001)	1	F	33	Blurred vision	IDN	45
Rishiraj B (16) (2005)	1	M	73	Permanent amaurosis, midriasis	IDN, PSAN	Perm
Ngeow WC (17) (2006)	2	F	20	Blurred vision	IDN	15
		F	21	Blurred vision	IDN	15
Uckan S (18) (2006)	2	M	25	Burning sensation in the eye	IDN	20
		F	30	Unilateral transitory amaurosis	IDN	45
Scott JK (19) (2007)	1	F	28	Diplopia	IDN	120

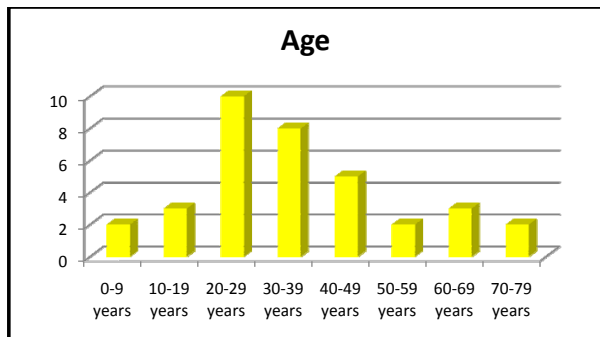


Fig. 1. Distribution of the patients according to their age group.

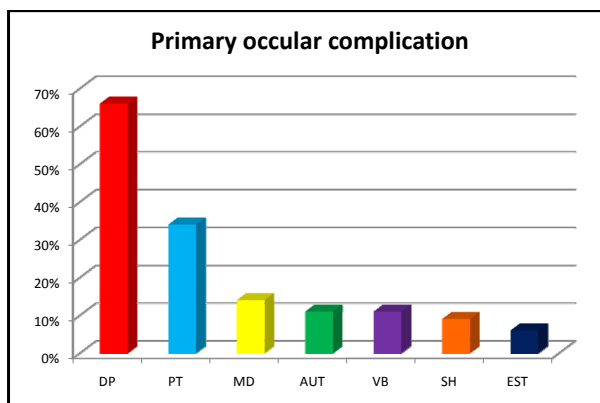


Fig. 2. Percentage of patients according to the ocular complication presented. Diplopia (DP), Ptosis (PT), Mydriasis (MD), Unilateral Transitory Amaurosis (AUT), Blurred Vision (VB), Horner Syndrome (SH), Strabismus (EST).

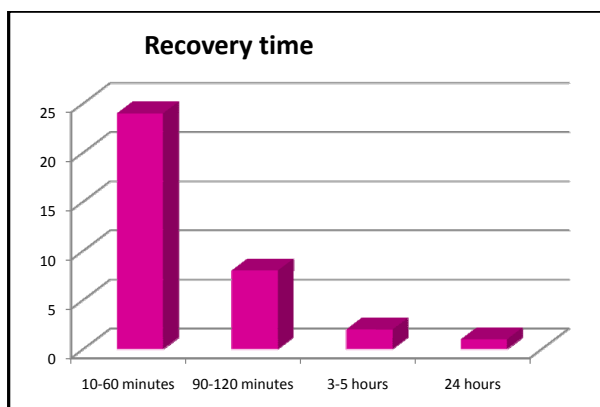


Fig. 3. Distribution of the patients according to their recovery time after the ocular complication.

Discussion

As aforementioned, ocular complications are an uncommon problem. Although there were authors that suggested a frequency of 0.1%, if a calculation is made based on the studies by Meyer (1999), who estimated ten years ago that there were 30 million cases in which anesthesia

was administered in Germany each year, we would be talking about one case of an ocular accident for every 500 million or 1 billion cases in which patients are administered anesthesia, which clearly indicates that these alterations are very uncommon. However, that does not mean that they do not occur, which requires researching the causes that may lead to these events, as well as their mechanism of production. Although the latter is not yet clear, all of the authors appear to suggest an intravascular injection of the anesthetic in the cases of troncular anesthesia of the inferior dental nerve, which would follow a retrograde mechanism until reaching the medium meningeal artery, through which it would connect with the lacrimal artery. In the case of anesthesia of the superior posterior alveolar nerve, this refers to diffusion to the orbit from the infratemporal and pterygopalatine fossa (13). This may be based, above all, on the troncular blocks of the maxillary nerve through the posterior palatine duct, as in the study by Sved et al. (20), carried out on 101 patients on whom this anesthetic technique was applied, up to 39% of the cases presented some type of ocular alteration, although they only speak of 8% of the cases in which an aspiration of blood in the anesthetic carpule was noted.

In terms of the sex of the patients, in our study, 77% of the cases affected females, which represents a large difference with respect to males. This data coincides with the data obtained by Peñarrocha et al. (13), in the study which we also took into account for our meta-analysis. Due to not having more articles which consider more than 2 or 3 cases, there is no study that contradicts these results, but in general, we can affirm that there is a higher inclination towards females.

With respect to age, the average age obtained was 34.2 years old, as well as a more common presentation in the 3rd and 4th decades of life. According to the studies conducted by Peñarrocha et al. (13), they obtained a higher average age (44 years old); although they concur that this phenomenon occurs most frequently during the 3rd decade of life. The average age of the patients of our study is influenced by the 2 cases that occurred at the dental pediatric level, although we also take into account the cases of patients over the age of 65, thus making our data rather objective.

In regards to the ocular complication most frequently described, the results are similar, with these authors indicating diplopia due to the paralysis of the extrinsic muscles of the eye as the most common complication that occurs at the ophthalmological level. Our data is also corroborated by Sved et al. (20), who spoke in their aforementioned study of diplopia as the most common complication, following by strabismus and ptosis. Palpebral ptosis, present in 3 cases studied by Peñarrocha et al. (13) as a syndrome similar to Horner, which concurs with our observation that it is the second most

common complication. The aforementioned mechanism of the possible retrograde passing or diffusion of the anesthetic will most commonly affect the III, IV and VI par than the optical nerve, due to its path closest to the place of injection, which generates the paralysis that causes double vision.

With respect to the nerve anesthetized, our data reveals a very slight difference in terms of the anesthetic technique on the inferior dental nerve and on the posterior alveolar nerve, with a slight inclination towards the latter. These data are contrasted by that shown by Peñarrocha et al. (13), who exclusively name the superior periapical anesthesia on the posterior alveolar nerve. Whereas there are authors that recommend the retrograde path of anesthetic by intravascular injection on the inferior dental artery, up to the medium meningeal artery and the connecting of this artery with the lacrimal artery, an anastomosis always appears between both, which enables the relationship between the arterial plexus of the medium meningeal and the ophthalmic artery (4, 11-12); others (3,7) suggest a connection at the pterygo-maxillary fossa, where the anesthetic would penetrate into the pterygoid venus plexus, being distributed to the ophthalmic vein at its connection in the orbital fissure. With the data that we have obtained in this study, we are unable to establish some clear conclusions on whether the mechanism of production is the first or the second, or whether both may be involved in the development of ocular complications. However, this does not concur with that described by authors such as Dryden et al. (9), in whose case they refer an infiltration with negative aspiration after using a Gow-Gates technique. This only serves to show the lack of unanimity in these mechanisms of producing the complications.

The anesthetic most often used was articain 2% with epinephrine 1:100,000, used on 35% of the patients. Despite this, this data does not appear entirely conclusive, as anesthesia has been practiced with many types of anesthetics (lidocain, mepivacain, procain, etc.) with ocular alterations present in the use of all of them. In addition, we must keep in mind that articain is currently one of the most commonly used anesthetics. Our study also coincided that the total of the ocular complications corresponds with that of the study conducted by Peñarrocha et al. (13), knowing the dedication of this group to the field of oral surgery, where the use of this anesthetic is even more frequent due to its higher plasma half-life and duration of the anesthetic effect.

The usual recovery time of these accidents was 70 minutes, although more than 60% of the patients recovered within the first hour. This concordance in our results is also evident in the study by Peñarrocha et al. (13). As has already been explained in the results, the only case of a permanent complication was not taken into account. With respect to the this case, Rhisiraj et al. (16)

state that it had to do with a patient who suffered a serious systemic alteration (endocarditis of the mitral valve due to *S. salivarius*, awaiting substitution), which may have played a role in producing this episode, as the only case of permanent amaurosis or that of any other type of permanent alteration after injection of local anesthesia was found in dental science publications.

In the majority of the cases of diplopia, the affected eye was covered for the duration of the symptom in order to prevent the patient from suffering the strain of double vision. Despite all of this, in the majority of the cases, dental treatment was continued with the mere observation and care of the patient. In certain cases, the patient was advised to visit the ophthalmologist if the symptoms were not relieved within a few hours, although the symptoms were always relieved within this time, except in the case of permanent blindness, in which ocular massage was even attempted.

The main limitation of our study was not having more articles in which various cases of ocular complications are contemplated so that we could establish a broader and more in-depth comparison of the results, which would have enabled us to make specific and clear conclusions.

We believe that it would be interesting for the authors to publish this type of experience encountered in the dental clinic, in order to conduct an exhaustive study on the mechanisms of production of the ocular complications, enabling the researchers to establish some protocols for preventing them, which, in turn, would result in better quality and comfort in treating our patients, given that oral anesthesia is probably the most common procedure practiced by stomatologists and dentists in their daily work, and these complications may lead to uncomfortable and unpleasant situations when treating the patients.

The best way of avoiding the appearance of complications, both ocular as well as clinical, is to examine the patient and use a careful and correct technique, especially being careful to avoid intravascular injection of the anesthetic. In the event that such a complication does occur, the most important step is to calm the patient. In cases of diplopia, it is recommended to cover the patient's affected eye in order to prevent the unpleasant sensation of double vision (21).

References

References with links to Crossref - DOI

1. Rood JP. Ocular complication of inferior dental nerve block. A case report. *Br Dent J.* 1972;132:23-4.
2. Campbell RL, Mercuri LG, Van Sickels J. Cervical sympathetic block following intraoral local anesthesia. *Oral Surg Oral Med Oral Pathol.* 1979;47:223-6.
3. Petrelli EA, Steller RE. Medial rectus muscle palsy after dental anesthesia. *Am J Ophthalmol.* 1980;90:422-4.
4. Norris L. Eye complications following Gow-Gates block technique. *Dent Anaesth Sedat.* 1982;11:59-60.
5. Goldenberg AS. Diplopia resulting from a mandibular injection. *J Endod.* 1983;9:261-2.

6. Kronman JH, Kabani S. The neuronal basis for diplopia following local anesthetic injections. *Oral Surg Oral Med Oral Pathol.* 1984;58:533-4.
7. Clarke JR, Clarke DJ. Hysterical blindness during dental anaesthesia. *Br Dent J.* 1987;162:267.
8. Goldenberg AS. Transient diplopia from a posterior alveolar injection. *J Endod.* 1990;16:550-1.
9. Dryden JA. An unusual complication resulting from a Gow-Gates mandibular block. *Compendium.* 1993;14:94,96,98.
10. Marinho RO. Abducent nerve palsy following dental local analgesia. *Br Dent J.* 1995;179:69-70.
11. Van der Bijl P, Lamb TL. Prolonged diplopia following a mandibular block injection. *Anesth Prog.* 1996;43:116-7.
12. Spierer A, Spierer S. Transient extraocular muscle palsy resulting from inferior alveolar nerve block in children. *J Clin Pediatr Dent.* 1999;24:29-30.
13. Peñarrocha-Diago M, Sanchis-Bielsa JM. Ophthalmologic complications after intraoral local anesthesia with articaine. *Oral Surg Oral Med Oral Pathol Oral Radiol Endod.* 2000;90:21-4.
14. Wilkie GJ. Temporary uniocular blindness and ophthalmoplegia associated with a mandibular block injection. A case report. *Aust Dent J.* 2000;45:131-3.
15. Webber B, Orlansky H, Lipton C, Stevens M. Complications of an intra-arterial injection from an inferior alveolar nerve block. *J Am Dent Assoc.* 2001;132:1702-4.
16. Rishiraj B, Epstein JB, Fine D, Nabi S, Wade NK. Permanent vision loss in one eye following administration of local anesthesia for a dental extraction. *Int J Oral Maxillofac Surg.* 2005;34:220-3.
17. Ngeow WC, Shim CK, Chai WL. Transient loss of power of accommodation in 1 eye following inferior alveolar nerve block: report of 2 cases. *J Can Dent Assoc.* 2006;72:927-31.
18. Uckan S, Cilasun U, Erkman O. Rare ocular and cutaneous complication of inferior alveolar nerve block. *J Oral Maxillofac Surg.* 2006;64:719-21.
19. Scott JK, Moxham BJ, Downie IP. Upper lip blanching and diplopia associated with local anaesthesia of the inferior alveolar nerve. *Br Dent J.* 2007;202:32-3.
20. Sved AM, Wong JD, Donkor P, Horan J, Rix L, Curtin J, et al. Complications associated with maxillary nerve block anaesthesia via the greater palatine canal. *Aust Dent J.* 1992;37:340-5.
21. Crean SJ, Powis A. Neurological complications of local anaesthetics in dentistry. *Dent Update.* 1999;26:344-9.