

Cowden's syndrome. Case report, with reference to an affected family

Verónica Blanco ¹, Verónica Keochgerián ²

(1) Doctor in Dentistry. Assistant Professor of Semiology and Maxillo-Facial & Oral Pathology, Assistant of Emergency Services

(2) Doctor in Dentistry. Associate Professor of Pathology, Coordinator of the Pathology Course in the Curricular Transformation Unit (UNSTRAC). School of Dentistry, UDELAR, Montevideo

Correspondence:

Dra. Verónica Blanco

School of Dentistry, UDELAR, Montevideo.

Fax: (5982) 487-3837

E-mail: verokeoc@hotmail.com

Received: 28-05-2004

Accepted: 11-05-2005

Blanco V, Keochgerián V. Cowden's syndrome. Case report, with reference to an affected family. *Med Oral Patol Oral Cir Bucal* 2006;11:E12-6.
© Medicina Oral S. L. C.I.F. B 96689336 - ISSN 1698-6946

[Click here to view the article in Spanish](#)

Indexed in:

-Index Medicus / MEDLINE / PubMed
-EMBASE, Excerpta Medica
-Indice Médico Español
-IBECs

ABSTRACT

Cowden's syndrome is a rare genodermatosis characterized by multiple hamartomas in several tissues and organs derived from all three embryonic layers.

Clinical features of Cowden's disease are explained by the mutation of the PTEN tumour suppressor gene, whose modification leads to an uncoordinated growth of tissues.

The importance of this disease lies in the increased susceptibility to malignization of some lesions, specially breast, thyroid and genito-urinary tract lesions. As a result, the disease has been considered a preneoplastic condition. Despite its varied phenotypic expression, this disease is generally unknown. Consequently, many cases are undiagnosed or diagnosis comes at a late stage, what points out the importance of an early diagnosis of the disease so the patient can have periodic check-ups to prevent malignant diseases.

A family case is presented here, whose diagnosis was based upon oral clinical findings and which most distinct systemic alteration is the presence of hamartomatous polyps in the digestive tract in several family members.

Key words: *Syndrome, multiple hamartomas, preneoplastic, tumour suppressor gen.*

RESUMEN

El síndrome de Cowden es una rara genodermatosis caracterizada por múltiples hamartomas ubicados en tejidos y órganos diversos derivados de las tres hojas embrionarias.

Las manifestaciones clínicas de la enfermedad de Cowden se explican especialmente por la mutación de un gen supresor tumoral, el PTEN cuyo cambio induce al crecimiento incoordinado de los tejidos.

La importancia de esta enfermedad radica en la tendencia a la malignización de algunas de sus lesiones especialmente las de mama, tiroides y tracto génito-urinario. Esto ha determinado que se la considere como una entidad preneoplásica. A pesar de su variada expresión fenotípica esta entidad es generalmente desconocida. Esto determina que muchos casos pasen desapercibidos o sean diagnosticados tardíamente, de ahí la importancia del diagnóstico precoz de esta enfermedad que lleve al paciente a revisiones periódicas para prevenir enfermedades malignas.

Se presenta aquí un caso familiar cuyo diagnóstico surge por los hallazgos clínicos detectados en la cavidad bucal y cuya alteración sistémica mas destacada es la presencia de pólipos hamartomatosos en el tracto digestivo en varios miembros de la familia.

Palabras clave: *Síndrome, hamartomas múltiples, preneoplásico, gen supresor tumoral.*

INTRODUCTION

Cowden's syndrome is an infrequent genodermatosis (1) clinically expressed in the skin, mucosas and multiple organs, with an autosomal dominant-inheritance pattern, of incomplete penetration and variable expressivity. It is part of the diseases known as "hamartosis" due to the presence of multiple hamartomas originated in any of the three embryonic layers (2). Some of the lesions are prone to malignization, therefore the disease belongs to the "preneoplastic hereditary syndromes" (3).

In 1963, Lloyd and Dennis (4) described its clinical features and named it "Cowden's disease", with the surname of the first (female) patient studied. Posterior synonyms include: "multiple hamartoma syndrome" (5), "multiple hamartoma syndrome and neoplasia" (6).

Up to now, approximately 200 cases have been published (1), most of them in dermatologic literature (2). Clinically, it is more frequent in women (60%) and in Caucasians (95%) (2). The first detectable signs normally appear in the second or third decade of life, with sporadic cases in older people (7). Signs are rarely observed at birth or in infancy (7,8).

Its clinical features are numerous and varied. Many tissues and organs of the economy are affected. Skin and oral lesions are early clinical signs and can be easily detected; Therefore they frequently facilitate the diagnosis.

In table 1, a summary of its main associated disorders is presented.

Communication of this case is considered important given the rarity of the disease, the pathological significance of its progression for affected patients and the responsibility of the dentist in its diagnosis through the clinical knowledge of the oral lesions.

CLINICAL CASE REPORT

Caucasian patient, 52-year-old man, who comes to surgery in the University School of Dentistry of UDELAR, Montevideo. He refers pain produced by an exophytic lesion in the right jugal mucosa.

The presence of occasional intestinal bleeding is noted in his medical history.

Significant data of familial medical history include: father died of intestinal tumour, brother underwent surgery for intestinal polyps, and sister has recently undergone hysterectomy with bilateral oophorectomy; the family do not know the reason for this surgical procedure.

The patient has three healthy sons.

Physical examination reveals large brain circumference, hyper-telorism, broad nasal bridge, prominent forehead and adenoid facies. Surrounding facial orifices, multiple asymptomatic flesh-coloured papules are observed. Careful clinical examination of the rest of the skin reveals the presence of palmar and plantar keratosis (figure 1), which give the impression of flat viral warts and papulo-non keratotic lesions in the armpits, groin and chest.

Oral examination reveals: partial loss of teeth in lower jaw, total loss of teeth in upper jaw (carries complete upper prosthesis), deep palate and fissured tongue. The mucosa is covered by

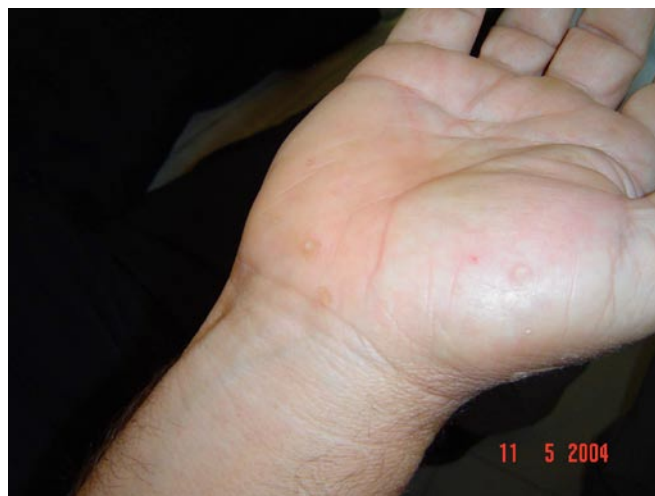

Fig.1. Palm keratotic lesions.

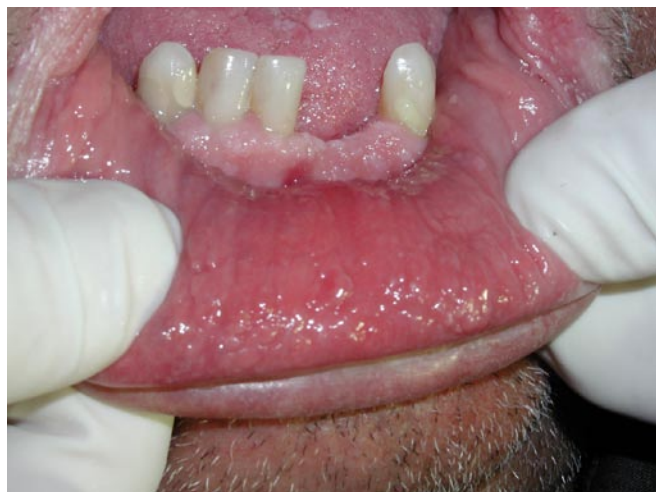

Fig. 2. Intraoral lesions in lip mucosa, low vestibular gum and back of tongue.

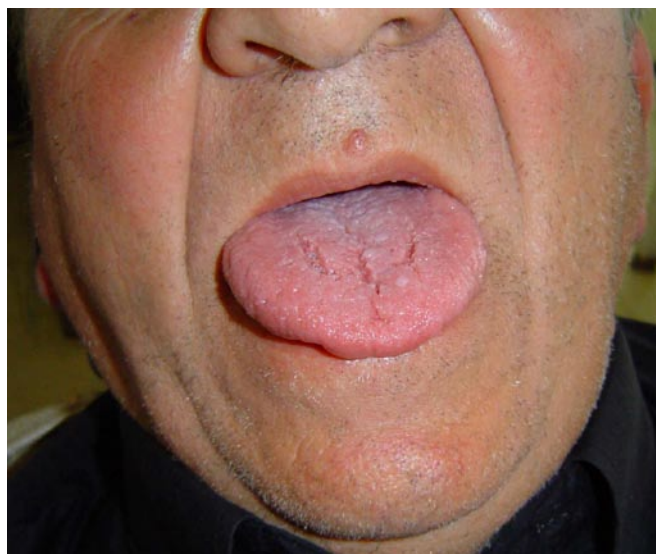


Fig. 3. Tongue with fissured appearance and papillar lesions in dorsal face. Dermal papule lesion on upper lip.

Table 1. Clinical findings – Cowden's disease

General clinical changes	Pectus excavatum
	Scoliosis
	Intestinal polyps*•
	Fibrocystic disease of the breast
	Goiter; Hashimoto disease
	Ovarian disorders and uterine abnormalities
	Central Nervous System (CNS) disorders
	Low intelligence*•
	Benign and/or malign neoplasias
Clinical changes Brain oral facial	Increase in head circumference*•
	Maxillary and mandibular hypoplasia*•
	Hypertelorism *•
	Broad nasal bridge*•
	Adenoid Facies*•
	Microstomy
	Oral papillomas and fibroids*•
	Fissured or scrotal tongue*•
	Root dwarfism•
	Periodontal disorders and premature dental loss*•
	Tooth mal positions•
Dermatological clinical changes	Multiple facial trichilemmomas*•
	Dermal fibroids*•
	Acral keratosis
	Palm and plantar keratosis
	Melanomas

* Disorders present in the father of the affected family.
 • Disorders present in the son of the affected family.

ders, no change in colour, smooth surface, sessile or pediculate and variable in size (1 cm. or less). They are found in the cheeks, rims, visible gingiva, lips and tongue (figures 2 and 3).

The lesion which prompted consultation is in the cheek, in the occlusal line; it is the largest in size and undergoes trauma due to the prosthesis. Exeresis biopsy shows an unspecific papillomatous type lesion.

With a presumptive diagnosis of Cowden's disease, the patient is referred to a multidisciplinary team formed by a geneticist, a dermatologist, a gastroenterologist and an internal medicine specialist.

No significant findings were achieved in the Brain computed tomogram (CT) performed. An intestinal endoscopy showed a myriad of polyps that carpeted the bowel mucosa. Pathology report refers to hyperplastic polyps of the "serreted" type associated with displastic changes.

Paraclinical exams and phenotypic features of the patient confirmed diagnosis of Cowden's disease by the geneticists. Until now, no studies of the genetic material have been performed. At the next stage, the children of the patient were scheduled appointments for examination. The middle son (21 years old) has some clinical features of the disease (see table 1). The 27-year-old son has weak expressions of the syndrome phenotype, whereas the youngest (13-year-old boy) has no evidence of the disorder, so far.

DISCUSSION

Cowden's disease is a little known disorder, both in the dental and medical fields. The case presented here belongs to a family whose members suffered general illnesses for years, with no

association made to this genetic and familial pathology.

This leads to the consideration that Cowden's syndrome is an under-diagnosed pathology; many cases go unnoticed as such, and the only medical care is palliative treatment of the lesions.

For the diagnosis of this case, changes observed in the oral mucosa and the skin were the first to be considered. These expressions are usually the first ones (2) and most of the time they precede tumour complications in other sites. Porter (1) mentions oral lesions in 80% of the published cases. Carcinomatous complications of these lesions are rare (1).

Oral signs are very remarkable, therefore the dentist may be the first professional to come up with a presumptive diagnosis. Multiple papillomatous lesions are not common clinical findings in the oral cavity. Few other diseases present them; an example being Heck's disease, which has papillomatous lesions only in oral mucosa, it is etiologically and pathogenically linked to papilloma virus infection and generally observed in young people.

In Cowden's disease, the most significant dermal lesions are multiple facial trichilemmomas, typically occurring around natural orifices, as it occurred in this family members. As well as acral keratosis (1,2,6) is another common finding.

Multiple skin lesions enable differential diagnosis with Darier's disease.

Digestive endoscopy is equally important for the confirmation of this disease. The presence of polyps in the gastrointestinal tract is a common finding; they have been documented in 1/3 of the patients (6). Intestinal polyps may be of a diverse nature: inflammatory, hamartomatous (in this disease) or neoplastic (adenomas).

They can be found in the oesophagus, stomach, intestine and anus. Generally speaking, there is consensus that malignization of these polyps is low (9). In the studied family, gastrointestinal disease is evident in four of its members: one died of a neoplasia (presumably malignant) and three have benign polyps so far, though dysplastic changes have already been detected in one of them.

A remarkable fact is that in Cowden's syndrome, progression to colo-rectal carcinoma is consistent with the model proposed by Fearon and Vogelstein (10); in which environmental factors add up to genetic changes already present, towards the phenotypical determination of carcinoma development in the intestine. Several subsequent stages take place: from normal to hyperplastic epithelium, followed by adenomatous transformation and eventually to a malignant neoplasia.

Several associated CNS tumours have been reported: meningiomas (4,8), medulloblastomas (11) and gliomas (12). Brain CT scan is therefore an important diagnostic tool in these patients.

In 1981, Russel Jones et al (6) described the association of the L'hermitte-Duclos' and Cowden's syndromes, a rare syndrome affecting the cerebellum. It is a hamartomatous disorder of unknown origin, characterized by the hypertrophic proliferation of ganglion cells and excessive myelinization of cerebellar molecular layer. Granular and Purkinje cells are substituted by atypical neuronal cells, arranged in a disorderly pattern (6,8).

Other authors (8,9) consider that both syndromes are a different phenotype expression of the same entity, with many common clinical signs. According to Albrecht (6) L'hermitte-Duclos patients must be examined for signs of Cowden's disease and vice versa.

Another alteration observed in Cowden's syndrome are breast lesions. Breast cancer is one of the most frequent complications and it is usually bilateral (4,12,13). According to Ball (13), the risk of developing a malignant neoplasia in women with Cowden's disease is 30 to 50%, against 8.3% of the healthy women population. Different authors point out, however, that there has been no long-term follow-up to confirm these data (5,13).

The reproductive system is involved in a large number of affected women (55%) (14). Ovarian cysts, fibroids, uterus adenocarcinomas, cervical carcinomas and benign vaginal and vulvar lesions have been reported. Other neoplasias are detected in the urinary tract: bladder and renal pelvis cancer and urethra polyps.

Also thyroid abnormalities are a common finding. In 70% of the patients, goiter, carcinoma or both can be found; cases have been reported with associated Hashimoto disease. Thyroid malignant tumour is frequent in women but not in men (1).

Over the past few years, progress has been made in the knowledge of Cowden's disease pathogenicity. In 1996, Nelen et al (4) identified the genetic disorder responsible of this syndrome in the 10q chromosome, 22-23 loci. The responsible gene was named PTEN, a family of tumour suppressor genes that facilitate apoptosis, and inhibit cell invasion (4,12). Its mutation determines the loss of tissue cell proliferation control, with the result of diverse hamartomatous growths and neoplasias either benign or malignant. Most affected tissues are those composed by cells with a life-long ability to proliferate, like skin, mucosa, thyroid, breast, intestinal and gastric mucosa.

Nevertheless, a subgroup of patients also associate CNS tumours, mainly cerebellar in location, where it was shown that the external granular cell layer remains in the process of post-natal neuronal proliferation for six months in humans (6).

PTEN mutation has also been confirmed in Bannayan-Riley-Ruvalcaba syndrome (12) which Wilson et al (15) consider associated to Cowden's syndrome.

In summary, we have seen a pathologic syndrome with oral phenotype associated to several other lesions, deeply seated, less accessible. Recognition of changes in the oral craniofacial area involve the dental practitioners directly. In this particular disease, it is of vital importance due to possible malignant transformation of some extra-oral lesions. Through the knowledge of oral pathology, the diagnosis of an unnoticed disorder can be made. Its early detection benefits the healthy outcome of the patients involved by the syndrome.

REFERENCES

1. Porter S, Cawson R, Scully C, Eveson J. Multiple hamartoma syndrome presenting with oral lesions. *Oral Surg Oral Med Oral Pathol* 1996;82:295-301.
2. Seoane J, Aguado A, Vázquez J, Romero A, Iglesias P. Síndrome de Cowden: manifestaciones orales. Estudio clínico patológico de un caso. *Quintessence (Ed esp)* 1996;9:462-5.
3. Marra G, Armelao F, Vechio FM, Percepe A, Anti M. Cowden disease with extensive gastrointestinal polyposis. *J Clin Gastroenterol* 1994;18:42-7.
4. Fistarol SK, Anliker MD, Itin PH. Cowden disease or multiple hamartoma syndrome – cutaneous to internal malignancy. *Eur J Dermatol* 2002;12:411-21.
5. Schrager CA, Schneider D, Gruener AC, Tsou HC, Peacocke M. Clinical and Pathological Features of Breast Disease in Cowden's Syndrome. An underrecognized Syndrome with an Increased Risk of Breast Cancer. *Hum Pathol* 1998;29:47-53.
6. Albrecht S, Haber RM, Goodman JC and Duvic M. Cowden Syndrome and L'hermitte-Duclos Disease. *Cancer* 1992;70:869-76.
7. Salem OS, Steck WD. Cowden disease (multiple hamartoma and neoplasia syndrome). A case report and review of the English literature. *J Am Acad Dermatol* 1983;8:686-96.
8. Thomas DW, Lewis M. L'hermitte-Duclos disease associated with Cowden's disease. *Int J Oral Maxillofac Surg* 1995;24:369-71.
9. Frayling I, Bodmer W, Tomlinson I. Allele loss in Colorectal Cancer disease/ Juvenile Polyposis Locus on 10q. *Cancer Genet Cytogenet* 1997;97:64-9.
10. Fearon ER, Vogelstein BA. Genetic model colorectal tumorigenesis. *Cell* 1990;61:759-67.
11. Bagan JV, Peñarocha M, Vera-Sempere F. Cowden's syndrome: clinical and pathological considerations in two new cases. *J Oral Maxillofac Surg* 1989;47:291-4.
12. Reifenberg J, Rauch L, Beckmann MW, Megahed M, Ruzicka T, Reifenberg GR. Cowden Disease: clinical and molecular genetic findings in a patient with a novel PTEN germline mutation. *Br J Dermatol* 2003;148:1040-6.
13. Ball S, Arolker M and Purushotham AD. Breast cancer, Cowden disease and PTEN Mutchers syndrome. *Eur J Surg Oncol* 2001;27:604-6.
14. Williard W, Borgen P, Bol R, Tiwari R, Osborne M. Cowden's disease. A case report with analyses at the molecular level. *Cancer* 1992;69:2969-74.
15. Wilson PH, MacDonlad DG, Felix DH. Bannayan-Riley-Ruvalcaba Syndrome: report of a family. *Oral Dis* 2001;7:310-4.