

Brachytherapy in lip cancer

Ángeles Roviroso Casino ¹, Isabel Planas Toledano ², Jorge Ferre Jorge ³, José María Oliva Díez ⁴, Carlos Conill Llobet ¹, Meritxell Arenas Prat ⁵

- (1) Radiation Oncologist, Consultant at the Radiation Oncology Department, ICMHO, IDIBAPS. Hospital Clínic of Barcelona
- (2) Medical doctor in training, Radiation Oncology Department, ICMHO. Hospital Clínic de Barcelona
- (3) Medical doctor and dentist, Radiation Oncology Department, ICMHO and Fundació Privada Clínic per la Investigació Biomèdica. Hospital Clínic de Barcelona
- (4) Medical doctor and dentist, Centro de Atención Primaria La Pau, Barcelona
- (5) Radiation Oncologist, Radiation Oncology Department, ICMHO, Hospital Clínic de Barcelona, Spain.

Correspondence:

Dra. Angeles Roviroso Casino
Servicio de Oncología Radioterápica
Hospital Clínic
Cl Villarroel nº 170
08036 Barcelona
E-mail: roviroso@clinic.uib.es

Received: 12-03-2005
Accepted: 22-01-2006

Roviroso-Casino A, Planas-Toledano I, Ferre-Jorge J, Oliva-Diez JM, Conill-Llobet C, Arenas-Prat M. Brachytherapy in lip cancer. *Med Oral Patol Oral Cir Bucal* 2006;11:E223-9.
© Medicina Oral S. L. C.I.F. B 96689336 - ISSN 1698-6946

Indexed in:

-Index Medicus / MEDLINE / PubMed
-EMBASE, Excerpta Medica
-Índice Médico Español
-IBECs

[Click here to view the article in Spanish](#)

ABSTRACT

Lip cancer is one of the most prevalent skin tumours of the head and neck. The characteristics of the tumour relate to their exophytic growth in an area of easy visual access which allows their diagnosis in early stages. As a result, there is a better prognosis with the present treatments. In early stages the treatment can be performed by surgery or by brachytherapy, and the results are similar on local control; nevertheless brachytherapy offers the best functional and esthetic results. We are reporting on a review of the literature in relation to indications, techniques and results of brachytherapy for lip cancer.

Key words: *Lip cancer, radiotherapy, interstitial brachytherapy.*

RESUMEN

El cáncer de labio es de los más prevalentes entre los tumores cutáneos de cabeza y cuello. Las características del tumor, por su crecimiento exofítico en una zona de fácil acceso visual, permite un diagnóstico en estadios incipientes y, por tanto, un mejor pronóstico con los actuales tratamientos. En estadios iniciales se puede realizar tratamiento con cirugía o braquiterapia, siendo los resultados similares en cuanto al control local; sin embargo la braquiterapia ofrece mejores resultados estéticos y funcionales. Presentamos un trabajo de revisión bibliográfica al respecto de las indicaciones, técnicas y resultados de la braquiterapia en el cáncer de labio.

Palabras clave: *Cáncer de labio, radioterapia, braquiterapia intersticial.*

INTRODUCTION

Lip cancer is the second most common type of skin cancer in the head and neck area. There are 3.600 new cases per year recorded in USA (1,8 persons per 100.000 habitants per year.) (1). It normally affects men over the age of 50 and in 95% of the cases the majority of the tumours are located in the lower lip. Tobacco habits, similar to what happens in the superior aerodigestive neoplasms, are an important aethiologic factor, and principally their frequency is increased in pipe smokers. Exposure to the sun also increases the risk, and it is probably the most important aetiologic factor, which is reflected by the high prevalence in farmers and other professionals exposed to the sun. The patients more genetically susceptible to developing skin cancer after sun exposure have also an increased risk of developing lip cancer (1-3). They can also be related to immunosuppression situations, and as a consequence there is an increased incidence in patients who have had renal or hepatic transplants (3). The most frequent pathological type is the squamous carcinoma and with much lower frequency is the basal cell carcinoma type, and other pathologies are exceptional (1-3). In the majority of cases the clinical manifestation is as an exophytic or scab lesion in the lower lip, and occasionally it can also bleed and be painful. Its growth is normally slow and, due to that there are visible lesions, their diagnosis is done when they are small tumours. When diagnosed, 90% are located in the lower lip, they are well differentiated and their size should be approximately 1 cm; 5% affect the upper lip and 1-2% affect commissure and the adjacent lip (3). As their growth and progression is local, in advanced tumours their largeness cause the invasion of the neighborhood structures, as the trigeminal nerve, destruction of the mandibular bone or inferior alveolar orifice, and the infiltration of the cheek and floor of the mouth. Also as a consequence, patients can have alterations in the sensitivity of the face or pain, and are possible relevant esthetic defects caused by the tumour destruction of the adjacent tissues (2). Lymphatic spreading is infrequent and only 5-10% develop node metastasis at diagnosis. In lower lip tumours the more frequently affected lymph nodes are the submandibular and submental and after these the following node level is the upper jugular one. Moreover, the bilateral lymph node dissemination can appear in lip cancer. In tumours affecting the upper lip and the commissure, the lymphatic spread can be more extensive and can disseminate to preauriculars, infraparotids, buccinator of homolateral cheek and submandibulars nodes; and from there to the upper jugular ones. The incidence of node metastasis principally depends on the pathological degree and the stage, and they are more frequent in advanced stages and in undifferentiated cases (2,3). At diagnosis those tumours well differentiated present 7% of node metastasis, moderately differentiated make up 23% and those undifferentiated represent 35%; depending on the tumor size the node metastasis appear in 5% of T1, in 52% of T2 and can reach up to 73% in T3. Distant metastasis in lip cancer are very rare and they appear in those cases of extensive tumors without local control. In table 1

TMN classification of lip cancer is reflected (4).

The prognosis of these tumours principally depend on the size of the tumor size; T1 tumours have 5 year survival rates of 90%-95%, T2 cases of 75%-85%, while in T3-T4 there is a more drastic decrease in survival depending on the existence of node involvement. In stages I & II the local control at 5 years is 94%, in stage III it is 90% and for stage IV it is 47% (5). Other influencing factors on prognosis are the node metastasis when present there is a decrease in survival of 50%, the presence of vascular and lymphatic space invasion and the perineural invasion; age has also been considered as having an influence on prognosis, where the younger patients have a worse outcome related to a more aggressive disease (6).

TREATMENT OF LIP CANCER

In early stages surgery and radiotherapy are the elective treatment. Surgery allows to maintain the lip structure in displasias and in situ carcinoma; when these lesions affect less than 30% of the lip they can be treated by a V excision and primary closure (2,3,5). T1-T3 squamous carcinomas can be treated by surgery or radiotherapy. The choice of which treatment depends on the size of the tumour, the location in the lip and the expected functional and esthetic results with each therapeutic option. In the smaller lesions with easy excision, surgery can be the elective treatment if the size of the open mouth has not visibly reduced, although brachytherapy offers the same results in local control and survival; nevertheless, in lesions near to commissure brachytherapy is indicated to better preserve the esthetic results and lip function. In advanced stages (III-IV), surgery can be the treatment of choice that is frequently in need of plastic reconstruction, and in these cases radiotherapy is administered postoperatively. T3-T4 N0 tumours and in those with clinical node involvement a neck lymphadenectomy is recommended; when the pathologic study show node metastasis radiotherapy should be administered on the tumor and on the lymph node areas. In very advanced tumours where surgery is not possible, external beam irradiation alone or associated with chemotherapy is the unique therapeutic option; in these patients, brachytherapy administered after external beam irradiation (EBI) allows an increased dose in a smaller volume. Patients with T1-T3 tumours, microscopic residual disease after surgery and those cases having perineural involvement should receive EBI or brachytherapy depending on the characteristics of each case. When the tumour involves the bone, local control and survival are poor despite the treatment. In those cases treated for local relapse where surgery or radiotherapy is performed with a curative aim, the local control is obtained in 50% and the specific overall survival at 5 years is of 30%; in this situation surgery is chosen when the patient has been previously irradiated, and radiotherapy is usually administered when surgery is not possible due to the size of the tumour or a loss of lip function. (2,3,5,7,8).

Tx	Primary Tumour cannot be assessed
T0	No evidence of primary tumour.
Tis	Carcinoma in situ
T1	Tumour 2 cm or less in greatest dimension.
T2	Tumour more than a 2 cm but not more than 4 cm in greatest dimension.
T3	Tumour more than 4 cm in greatest dimension.
T4	Direct extension to other structures. T4a: Tumour invades through cortical bone, inferior alveolar nerve, floor of the mouth or skin (chin or nose). T4b: Tumour invades masticator space, pterigoid plates, or skull base, or encases internal carotid artery.
NX	Regional lymph nodes cannot be assessed.
N0	No regional lymph node metastases.
N1	Metastases in a single ipsilateral lymph node, 3 cm or less in the greatest dimension.
N2	Metastasis in a single ipsilateral lymph node, more than 3 cm but not more than 6 cm in greatest dimension; or in multiple ipsilateral lymph nodes, none more than 6 cm in greatest dimension; or in bilateral or contralateral lymph nodes, none more than 6 cm in greatest dimension. N2a: Metastasis in a single ipsilateral lymph node, more than 3 cm but not more than 6 cm in greatest dimension. N2b: Metastasis in multiple ipsilateral lymph nodes, none more than 6 cm in greatest dimension. N2c: Metastasis in bilateral or contralateral lymph nodes, none more than 6 cm in greatest dimension.
N3	Metastasis in a lymph node more than 6 cm in greatest dimension.
MX	Distant metastasis cannot be assessed.
M0	No distant metastasis.
M1	Distant metastasis.

Table 1. TMN clinical classification for lip cancer.

BRACHYTHERAPY

Brachytherapy is a kind of radiotherapy where radioactive sources are placed inside or in contact with the tumour or inside natural cavities. In the case of lip cancer the radioactive sources are introduced inside the tumour using specifically designed applicators that will be described further on, and usually are comfortable and unpainful for the patient.

The most usual radioactive source is low dose rate (LDR) ¹⁹²Ir, and recently, treatments with high dose rate (HDR) ¹⁹²Ir sources have been introduced. These radioactive materials are miniaturized and allowed to administer a high tumour dose. Brachytherapy is considered by their defenders as the best conformation possible in lip cancer treatment; the irradiated volume is small and adapted to the tumour requirements; by the treatment of the tumour with a small

safety margin brachytherapy offers a smaller treatment volume in comparison to external beam irradiation. Another advantage is while the dose inside the tumour is high a quick decrease exists in the periphery of the implant avoiding the irradiation of healthy neighbouring tissues. This kind of treatment has been performed for approximately 100 years and the main advantage it offers is that it maintains the esthetics and function of the lip. (Fig. 1) (8).

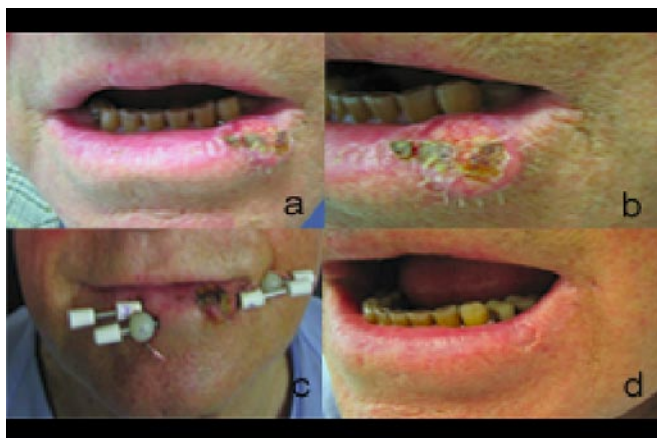


Fig. 1. 1a y 1b: T1 squamous carcinoma, manifesting an ulcerous and crusty tumour affecting an external third of the inferior lip. 1c: Brachytherapy using Delclos rigid needles technique for LDR ^{192}Ir sources. 1d: Disappearance of the tumour 2 months after brachytherapy with excellent esthetic and functional results.

1- INDICATIONS.

Brachytherapy alone or combined with external beam irradiation, offers the same results in local control and survival than surgery. Different authors refer to the esthetic and functional benefits of brachytherapy in comparison to surgery. That is the reason why in some European hospitals brachytherapy is the treatment of choice in lip cancer. The majority of lip cancer cases are diagnosed in early stages, and while surgery ensures good functional and esthetic results in superficial tumours and in those having less than 0,5 cm, brachytherapy as an exclusive treatment is indicated in practically 90% of T1-T2 lip cancer (8). In a study performed in 1993 by the GEC-ESTRO Society (Groupe Européen de Curietherapie, of the European Society for Therapeutic Radiology and Oncology), in 1870 patients treated by brachytherapy the results were 98,4% local control at 5 years of 98,4% for T1, 96,6% for T2 and 89,9% for T3 (10). The results of local control, esthetics and complications for brachytherapy in lip cancer in different studies are shown in table 2.

The treatment recommended for the tumours with a size bigger than 5 cm. is external beam irradiation followed by brachytherapy as a boost. Brachytherapy is contraindicated in those cases with bone involvement, and in those cases with an important loss of tissues; in these cases a wide excision with plastic reconstruction is of preference (2,3,5,8,9).

2-TÉCHNIQUE.

The placement of vectors or applicators for ^{192}Ir sources on the lip is usually performed using local anesthetic on the upper and lower alveololabial groove and only occasionally it is necessary to use local anesthesia of the infraorbital nerve; in some cases a general anesthesia is essential for the placement of the applicators (10).

There are different types of applicators and the technique of their placement can vary in the function of each one. Hypodermic needles, guide needles, plastic tubes, silk threads, small vascular catheters and guide gutters have been used along the years. The use of one vector or another depends on the size of the tumor, their morphological characteristics, the lip anatomy and of the extension to the commissure. The plastic tube technique is recommended in those cases where the tumour affects the commissure or the cheek, and in those cases where the size of the tumour causes an anatomical distortion; moreover it is a comfortable technique for the tumours of the upper lip. The rigid or guide needles technique offers better geometric conditions for the implant, it is the most commonly used technique for lower lip cancer and, this technique is highly recommended for HDR treatments (3,8,11).

As a main characteristic, the implant should have a geometry in parallelism and homogeneous distance between the radioactive sources, and independently of the treatment technique. The Paris System rules recommend distances between the sources of 9 to 12 mm; this last point allows an optimized implant avoiding overdosing areas responsible for complications and underdosing areas that condition relapses (8,11-13).

The ^{192}Ir applicators can cause lip oedema after their placement, principally in big tumours or in lips with lax tissue; sometimes, slight pain can also appear but it disappears using minor analgesics. If lip oedema causes an increase of the distance between the sources the result is underdosing areas in the tumour; in this situation the administration of corticoids are useful. Usually the applicators are very well tolerated by the patient during the 3-5 days that the treatment takes (8,10).

The lip implant is frequently in contact with the opposite healthy lip and also with the teeth; sometimes it can be in contact with the maxillar bone and it principally happens in patients without teeth or in tumours that exceed the inferiority of the vermillon. To avoid the irradiation of these healthy tissues they should be constructed personalized protectors of acrylic material containing 2 mm of lead, which avoid the irradiation of neighborhood tissues of a factor of 2, and as a result of their use the sequelae in the healthy tissues should be practically non existent. Prior to the placement of the implant, it is necessary to check the adaptation and the comfort of the protector, preferably by a dentist, to avoid the risk of patient intolerance during the treatment. Throughout the treatment it is necessary to be vigilant with the correct position of the protector and to maintain the correct geometry of the implant. Before the brachytherapy it is strongly advisable that the patient is evaluated by a dentist to eliminate or restore the teeth in order to avoid infection during brachytherapy or in the

Table 2. Brachytherapy results: local control, esthetics and complications.

AUTHOR	N°CASES	DOSE (Gy)	5 YEARS LC	FUNCTIONAL AND ESTHÉTICS	COMPLICATIONS
Beauvois et al. (13)	237 (T1-T4)	65- 68	99%	198 Sligth telangiectasia, 5 moderate retraction and depigmentation.	11% ulceración, 0.5% necrosis
Farrús et al. (12)	72 (T1-T3)	62-67	85%	-	-
Finestres (21) HDR	56 (T1-T3)	60-70 1.8 Gy/day, 5 days / week	96,5% mean follow-up: 46 months	Good and excelent 94%, Moderate 6%	4 ulceration 4 hyperpigmentation 2 telangiectasia 2 fibrosis
Fongione et al. (14)	69 (T1-T3)	65	99%	-	-
Gerbaulet et al. (22)	231 (T1-T3)	Mean of 76 Gy	95%	Good 70%, moderate 16%, poor 4%	13% necrosis (T3)
Guinot et al. (20) HDR	39 (T1-T4)	40.5-45, 8-10 fx,2 fx / day , 6 hours. interval	87%	Similar to LDR	Similar to LDR
Mazeron et al. (9)	1870(T1-T3)	60-70	T1 98.4%, T2 96.6%, T3 89.9%	Normal: T1 82%, T2 51%, T3 27%. Acceptable:T1 17%, T2 44%, T3 64% Unfavorable: T1 1%, T2 5%, T3 9%	-
Petrovich et al. (23)	91 (T1-T3)	7000 rads	95,5%	-	4 % necrosis 11% pigmentation 1% localized edema 5% slight retraction

LC: Local Control. HDR: High dose rate. Fx: fraction.

future; it is also advisable to give instructions relating to measures of oral hygiene (8,10,11).

The length of the treated lip is variable in the function of the size of the tumour. Normally, the length of the implanted area is those of the tumour plus a margin of security of 0,5-1 cm. It should be taken into account that these treatments need special care with the implant technique, determination of the number of the sources and the active ¹⁹²Iridium length that would be introduced inside the vectors in order to avoid relapses in the edge of the treated area; because of that some authors recommend the treatment of the whole length of the lip (8,11-13). Once vectors are introduced in the lip, a personalized dosimetric study is necessary. This is computerised and a Computerised Tomography (CT) can be necessary depending on the cases in order to correctly evaluate the dose distribution in the healthy tissues and in the tumour. Brachytherapy in lip cancer is in need of performing the orthogonal X-rays or CT for the dosimetric study using a copy of the acrylic protector without lead in the patients mouth; this allows the reproduction of the geometry implant in the dosimetric study as it would be during the treatment (8,10,11,13-15). During the whole of the treatment using low dose rate (LDR) ¹⁹²Ir, the patient is isolated in a radiation protected room that should have external television monitors in order for nurses to exercise patient control. Once the treatment is finished the ¹⁹²Ir and vectors are taken out of the patient without problems. In those cases where pain was expected during the removal of the implant the administration of an analgesic and a sedative is useful (8,10).

The patients that can not tolerate the isolation are special candidates for HDR ¹⁹²Ir treatments. In this therapy several treatment fractions are administered during a few minutes a day, usually during a week.

3- COMPLICATIONS AND ESTHETIC RESULTS.

During the first 3 weeks after treatment a progressive mucositis appears in the treated area, it usually disappears in 1-1,5 months and rarely lasts longer than 2 months. The treatment is based on topic measures and anagesics / anti-inflamatories of variable potency depending on the needs of the patient. Lip cancer disappears during the first 2 months after brachytherapy (Fig. 1d) (8,10).

The dose of brachytherapy depends on the size and characteristics of the tumour. For T1 tumours doses of 60-65 Gy in the 85% isodosis are considered adequate and 65-70 Gy for T2. Advanced tumours, when tumour characteristites permit it, are treated by external beam irradiation followed by a brachytherapy boost; after a dose of 45-50 Gy by external beam irradiation a brachytherapy dose of 20-25 Gy is recommended. Total dose after combined treatment higher than 70-75 Gy can be related to an unacceptable risk of sequelae. Although there is no clear influence of the dose rate in local control, 45-90 cGy / hour are considered the most adequate; nevertheless, more than 6% of lip ulceration are described when the dose rate is higher than 80 cGy / hour. These lip ulcerations disappear in the majority of the cases with topic measures (8,16,17).

The more frequent late complications, depending on the study, are slight depigmentation in 2,5-17%, slight tel-

angiectasias in 15% and different degrees of fibrosis in 8%. These are evaluated for the esthetic results and their low relevance means that they are well accepted by the patient. The most relevant late complication is the superficial necrosis that provokes lip ulceration; it appears in less than 10% of the cases, their health is usually spontaneous and in only 5% of them a surgical treatment is required depending on the series. The incidence of lip ulceration is related to the total dose and the rate of the dose and their apparition is rare if the geometry of the implant and the total dose and the dose rate have not been high. In brachytherapy with LDR sources esthetic results are related to the total dose and dose rate; they are considered as good or excellent in 91% of cases when the total dose is lower than 70 Gy and they are described as poor in 8,6% of the cases when the dose rate is higher than 80 cGy / hour (1,8,11). Beauvois et al. (13) also report that late complications are related to the healthy tissues included in the 85% isodosis. Fongione et al. (14), showed poor esthetic results when multiplanar implants were used. The results of both authors make relevance to the fact that the bigger the tumour, the higher the number of ¹⁹²Ir sources and as a consequence the implant volume, the healthy tissue included in it and probably the total dose is higher; the worse esthetic results are a consequence of these factors. A study performed in our hospital in patients treated by T1-T2 tongue carcinoma found that complications were increased in those patients with the highest treatment volume. (18). This increase in complications in patients that required a higher treatment volume is also reported in other tumour sites.

The GEC-ESTRO study, on 2794 patients, showed the following esthetic results: excellent in 94,9% of T1, in 84,3% of T2, in 72,5% of T3 and in 60% of T4; results were poor in 1,4% of T1, in 4,1% of T2, in 10,1% of T3 and in 20% of T4. Deformity and retraction of the lip was present in 6% of the patients with the tumour affecting commissure and it was more frequent in those cases of large tumours extended to the commissure (6).

Mazeron et al. (19) described, in 1870 patients with lip cancer treated by brachytherapy, the presence of relevant functional and esthetic sequelae in 1% of T1, in 5% of T2 and in 9% of T3.

There is not much experience in the treatment of lip cancer using HDR sources, and the lack of wide series makes it difficult to establish definitive conclusions in different aspects related to the total dose, optimal number of fractions and dose per fraction. Moreover, the lack of long follow-up in the series makes it difficult to define the effectiveness in local control, survival and esthetic and functional results. The largest series published in the literature and with the longest follow-up is by Guinot et al. (20); These authors studied 39 patients having a mean follow-up of 18 months (range between 1 and 36 months), and they reported a local control of 100% (21/39) in T1, 83% (6/39) in T2 and 75% (12/39) in T4, with an overall survival in this series of 91%. Treatment was administered twice a day, 6 hours between fractions, the total dose ranged between 40.5 Gy and 45 Gy

in 8 to 10 fractions and the dose per fraction was between 5 Gy and 5.5 Gy in the majority of the cases. The authors also report that the seriousness and the time that mucositis need to health was the same as in LDR treatments. Functional results were maintained in all the patients and as late sequelae indicate slight pain and diffuse atrophy. Although these preliminary results are encouraging in obtaining local control, avoiding patient isolation and permitting radioprotection of the staff, in HDR treatments special attention should be paid to the treatment technique. The rigid vectors with an external fixed system to ensure a good implant geometry are mandatory. Finestres, in 2003 (21), reported the results of a study, in 49 patients with T1 tumours and 7 with T2 tumours using ¹⁹²Ir HDR sources; in these patients a total dose of 60-70 Gy was administered by personalized mould technique, 1,8 Gy / day, 5 days / week. Disease free-survival at 5 years was 96,5%, esthetic results were considered as good or excellent in 53/56 (94.6%) and the mean follow-up of the patients was 46 months (range between 13 and 106 months). The dose per day used in this study is similar to the external beam treatments and as a consequence the patients finish the treatment in a period of nearly two months. The advantages of HDR treatments in lip cancer mean that the patient does not need to be isolated, the staff do not need radioprotection measures and it costs less in comparison to LDR treatments.

Brachytherapy is an excellent treatment in lip cancer, principally in the early stages, where it can offer similar results to surgery in local control and survival. Its requires a careful treatment technique and treatment planning. Relevant related complications are scarce and offer a good lip function maintaining the size of the mouth opening. The most frequent late effects are slight atrophy, telangiectasias and acromy. Trained staff, a careful patient evaluation and a good implant geometry will minimize these problems, and as a consequence the esthetic results are frequently superior to those obtained by surgery.

REFERENCES

1. Meck HR, Garfinkel L, Dodd GD. Preliminary report of the National Cancer Data Base. *CA Cancer J Clin* 1991;41:7.
2. Stimson P, Schantz Louis B, Harrison, Arlene A, Forastiere E. Lip cancer. In: De Vita T, Hellman JRH, Rosenberg SA Ed. *Cancer. Principles & Practice of Oncology*. Philadelphia-New York: Lippincot Williams & Wilkins Inc.; 1997. p. 773-5
3. Wang CC. Cancer of the oral cavity. In: Wang CC, Ed. *Radiation therapy for head and neck neoplasms*. Toronto, Canada: Wiley-Liss Ed.; 1997. p. 107-85.
4. Sobin LH, Wittekind Ch. TNM classification of malignant tumours. NY: Wiley-Liss Ed.; 2002. p. 22.
5. Million RR, Cassisi NJ, Mancuso AA. Oral cavity. In: Million RR, Cassisi NJ, Ed. *Management of Head and Neck Cancer*. Philadelphia: J.B Lippicott Company; 1994. p. 329-59.
6. Boddie HW, Fisher EP, Byers RM. Squamous carcinoma of the lower lip patients under 40 years of age. *South Med J* 1977;70:711.
7. Ang KK, Garden AS. Oral cavity. In: Ang KK, Garden AS. Ed. *Radiotherapy for head and neck cancers. Indications and techniques*. Philadelphia: Lippincot Williams & Wilkins; 2002. p. 49-50.
8. Gerbaulet A, Vanlimbergen E. Lip cancer. In: *The GEC-ESTRO handbook of brachytherapy*. Gerbaulet A, Pötter R, Mazon JJ, Meertens H, VanLimbergen E, Ed. Leuven, Belgium: ACCO Ed.; 2002. p. 227-36.
9. Mazon JJ, Richaud P. Lip cancer, report of the 18 th annual meeting of European Curietherapy Group. *J Eur Radiotherapy* 1984;5:50-6.
10. Roviroso A. Abordaje terapéutico en braquiterapia. En: Biete A, Verger E. Ed. *Abordaje integral del dolor en radioterapia*. Madrid: You & Us SA; 2004. p. 127-34.
11. Gerbaulet A, Maher M. Brachytherapy in the treatment of head and neck cancer. In: Joslin CAF, Flynn A & Hall ES Ed. *Principles and practice of brachytherapy using afterloading systems*. NY: Arnold Ed.; 2001. p. 284-95.
12. Farrús B, Pons F, Sánchez-Reyes A, Ferre F, Roviroso A. Biete A. Quality assurance of interstitial brachytherapy technique in lip cancer: comparison of actual performance with the Paris system recommendations. *Radiotherapy & Oncology* 1996; 38:145-51.
13. Beauvois S, Hoffstetter S, Peiffert D, Luporsi E, Carolus JM, Dartois D, et al. Brachytherapy for lower lip epidermoid cancer: tumoral and treatment factors influencing recurrences and complications. *Radiotherapy & Oncology* 1994;33:195-203.
14. Fongione S, Signor M, Beorchia A. Interstitial brachytherapy in carcinoma of the lip. *Radiol. Med (Torino)* 1994;17:45-9.
15. Roviroso A, Berenguer J, Sánchez-reyes A, Pujol T, Ferre J, Biete A. Real-size CT slices to optimize brachytherapy in the plastic tube technique for oral cavity cancer. *Medical dosimetry* 1998;23:109-11.
16. Gerbaulet A, Chassagne D, Hayen M. L'epiteliome de la lèvre. Une serie de 335 cas. *J Radiol Electrol* 1978;59:603-10.
17. Gerbaulet A, Grande C, Chirat E. Braquiterapia intersticial con Iridio en el carcinoma de labio: análisis de 231 casos tratados en el Institut Gustave Roussy. *Oncologia* 1994;17:45-9.
18. Roviroso A, Hernández V, Osorio JL, Sánchez-Reyes A, Bascón N, Güell J y cols. Analysis of major complications in guide gutter technique for early oral tongue and floor of the mouth neoplasms. *Radiotherapy & Oncology* 2000;55:69.
19. Mazon JJ, Richaud P. Lip cancer, report of 18th annual meeting of the European Curietherapy Group. *J Eur Radiother* 1984;5:50-6.
20. Guinot JL, Arribas L, Chust ML, Mengual JL, García E, Carrascosa M et al. Lip cancer treatment with high dose rate therapy. *Radiotherapy & Oncology* 2003;69:113-5.
21. Finestres F. Tratamiento del cáncer de labio mediante alta tasa de dosis. Ed. Electronica TDX. URL: <http://www.tdcat.es>.
22. Gerbaulet A, Haie-Meder C, Mrsiglia H, Kumar U, Lusinci A, Habrand JL. et al. Role of brachytherapy in treatment of head and neck cancers: Institut Gustave Roussy experience with 1140 patients. In: Mould RF, Batterman JJ, Martínez AA, Speiser BL, Ed. *Brachytherapy: from radium to optimization*. Leersum, The Netherlands: Veenman, Drukkers, Wageningen; 1994. p. 101-20.
23. Petrovich Z, Kuisk H, Tobochnik N, Hittle RE, Barton R, Jose L. Carcinoma of the lip. *Arch Otolaryngol* 1979;105:187-91.