

**U. PORTO**INSTITUTO DE CIÊNCIAS BIOMÉDICAS ABEL SALAZAR  
UNIVERSIDADE DO PORTO

Artigo tipo “Case Report”

Mestrado Integrado em Medicina

**TOTAL KNEE REPLACEMENT IN NAIL-PATELLA SYNDROME**  
*PRÓTESE TOTAL DO JOELHO NO SÍNDROME UNHA-RÓTULA*

António José Girão de Caires

**Orientador:****Dr. Adélio Justino Machado Vilaça****Porto, junho de 2017**

## **Orientador**

Dr. Adélio Justino Machado Vilaça,

Assistente Hospitalar no Serviço de Ortopedia do  
Departamento de Ortofisiatria – Hospital Geral  
Santo António – Centro Hospitalar do Porto;  
Largo do Prof. Abel Salazar, 4099-001 Porto,  
Portugal.

Assistente Convidado de Ortopedia e Docente  
Externo do Departamento de Anatomia do Instituto  
de Ciências Biomédicas Abel Salazar da  
Universidade do Porto;  
Rua de Jorge Viterbo Ferreira, nº 228, 4099-313  
Porto, Portugal

Laboratório de Biomecânica do Porto – LABIOMEPE;  
Rua Dr. Plácido Costa, 91, 4200-450  
Porto, Portugal

## **Afiliação**

Instituto de Ciências Biomédicas Abel Salazar da Universidade do Porto

## **Agradecimentos**

A todos os intervenientes directa ou indirectamente relacionados com o desenvolvimento desta tese de mestrado.

Um especial agradecimento ao Dr. Adélio e ao engenheiro Pedro, pelo ensino de qualidade, pela disponibilidade constante e pelo empenho e eficácia.

Aos meus patrocínios e ao meu irmão, pela educação e formação incessante.

À Mariana e aos meus eternos companheiros, pelo apoio e compreensão e imprescindíveis momentos de relaxamento.

**ÍNDICE**

<b>ORIENTADOR.....</b>	<b>II</b>
<b>AGRADECIMENTOS .....</b>	<b>III</b>
<b>ÍNDICE.....</b>	<b>IV</b>
<b>LIST OF ABBREVIATIONS .....</b>	<b>V</b>
<b>LIST OF FIGURES .....</b>	<b>V</b>
<b>LIST OF TABLES .....</b>	<b>V</b>
<b>LIST OF GRAPHICS .....</b>	<b>VI</b>
<b>TOTAL KNEE REPLACEMENT IN NAIL-PATELLA SYNDROME .....</b>	<b>VII</b>
<b>Summary .....</b>	<b>vii</b>
<b>Resumo .....</b>	<b>vii</b>
<b>BACKGROUND.....</b>	<b>8</b>
<b>CASE PRESENTATION .....</b>	<b>8</b>
<b>INVESTIGATIONS .....</b>	<b>9</b>
<b>TREATMENT .....</b>	<b>10</b>
<b>OUTCOME AND FOLLOW-UP .....</b>	<b>10</b>
<b>Gait Analysis Protocol .....</b>	<b>11</b>
<b>Isokinetic Dynamometry Protocol.....</b>	<b>12</b>
<b>DISCUSSION .....</b>	<b>13</b>
<b>CONCLUSION .....</b>	<b>15</b>
<b>LEARNING POINTS/ TAKE HOME MESSAGES .....</b>	<b>15</b>
<b>CONCLUSÃO .....</b>	<b>16</b>
<b>MENSAGENS A RETER .....</b>	<b>16</b>
<b>REFERENCES .....</b>	<b>17</b>

### List of Abbreviations

- NPS** – Nail-patella Syndrome.  
**TKR** – Total Knee Replacement.  
**PTJ** – Prótese Total do Joelho.  
**LL** – Lower Limb.  
**KOOS** – Knee injury and Osteoarthritis Outcome Score.  
**Spt** – Symptoms.  
**ADL** – Function in daily living.  
**QoL** – Quality of life.  
**RoM** – Range of motion.  
**PE** – Polyethylene.  
**EMG** – Electromyography.  
**MVC** – Maximal Voluntary Contraction.

### List of Figures

- Figure 1** – Nail abnormalities.  
**Figure 2** – ‘Swan neck’ fingers.  
**Figure 3** – Nail dysplasia.  
**Figure 4** – Elbow arthrodysplasia.  
**Figure 5** – Patellar aplasia.  
**Figure 6** – Treated club foot.  
**Figure 7** – Pre-operative X-rays; Long-leg – Left, Side view – Top right, Axial view – Bottom right.  
**Figure 9** – Pre-operative CT-Scan measuring the angle between the inter-epicondylar line of the femur and posterior condylar line – 5.1°.  
**Figure 10** – Pre-operative 3D reconstruction of the knee joint showing a 32mm lateral translation of the tibial anterior tubercle.  
**Figure 11** – Pre-operative 3D reconstruction of the pelvis revealing the iliac horns.  
**Figure 12** – Post-operative X-rays; Front view – Top left, Side view – Top right, Axial view – Bottom right.

### List of Tables

- Table 1** – KOOS pre-op and 3 years postop for left knee; Graded 0-100.  
**Table 2** – RoM of the knee joints, hips and ankles; (L – Left, R – Right, Ext. – Extension, Flex. – Flexion, IR – Internal Rotation, ER – External Rotation, N – Normal).  
**Table 3** – Spatio-temporal parameters of the patient; Standard values of J. Perry and J.M. Burnfield (2010); values shown in percentage; Right and Left sides standardized.

### List of Graphics

**Graphic 1** – KOOS profiles prior to and up to 5 years after TKR. Mean KOOS scores ( $n=80$ ) at the preoperative, 6 months, 12 months and 5 year assessments after TKR (Nilsson et al, 2009); The colored lines represent the preop and 3 years after the TKR of this patient.

**Graphic 2** – Hip joints angular kinematic of the gait; Standard data – grey, Right side – blue, Left side – red; Vertical blue and red lines: right and left toe off, respectively; Horizontal axis: gait cycle time in percentage.

**Graphic 3** – Knee joints angular kinematic of the gait; Standard data – grey, Right side – blue, Left side – red; Vertical blue and red lines: right and left toe off, respectively; Horizontal axis: gait cycle time in percentage.

**Graphic 4** – Antero-posterior, medial-lateral and vertical ground reaction forces; Standard data – grey, Right side – blue, Left side – red; Horizontal axis: duration of a single stand in percentage; Vertical axis: force in percentage of body weight.

**Graphic 5** – Strength values for isotonic muscle contraction; 0-1.5s –Extensor movement, 1.5-3s – Flexor movement.

**Graphic 6** – Average muscle activation (vertical bars) and maximum activation (lines) of the extensor muscles in the LL.

## TOTAL KNEE REPLACEMENT IN NAIL-PATELLA SYNDROME

### Summary

51 years old female patient with Nail-Patella Syndrome (NPS) affecting several organs is followed by orthopedics for knee pain and absent patella. 30 years after the diagnosis, this patient presented with severe knee function reduction and the decision to undergo a left total knee replacement (TKR) was taken. In this case report, radiological studies are analyzed, functional capacity of the knee joints are evaluated and gait analysis and strength pattern is discussed. The final analysis will allow the assessment of gait disorders and the effects of the corrective orthopedic surgery and this way compare the knee undergoing surgery with the contralateral. Since this is a rare syndrome, there is not many information about the progression of the disease and the appropriate treatment to sustain the quality of life of these patients. Thereby we are providing more information about NPS, as well as the outcome and technical considerations of the TKR.

### Resumo

Mulher de 51 anos com Síndrome Unha-Rótula e atingimento multiorgânico é seguida pela Ortopedia por gonalgia e aplasia rotuliana bilateral. 30 anos após o diagnóstico e gonartrose progressiva, a paciente apresenta-se com redução severa da função articular e é tomada a decisão de realizar-se uma Prótese Total do Joelho (PTJ) esquerdo. Neste artigo, são analisados os estudos imagiológicos, a capacidade funcional da articulação dos joelhos e é discutido a análise da marcha bem como o padrão de força. A análise final permitirá o acesso a distúrbios da marcha, aos efeitos da cirurgia de correcção e desta forma, comparar o joelho submetido a cirurgia com o contra lateral. Tendo em conta que se trata de um síndrome raro, não se encontra disponível muita bibliografia acerca da progressão da doença e do seu correto tratamento de forma a manter a qualidade de vida destes pacientes. Desta forma, tentamos fornecer informação adicional sobre a NPS, bem como o resultado e considerações técnicas da PTJ.

**BACKGROUND**

Nail-patella syndrome is an autosomal dominant condition resulting from a heterogeneous loss of function in the LMX1B gene.<sup>1</sup> It is characterized by the classical tetrad of nail dysplasia, patellar aplasia-hypoplasia, elbow arthrodysplasia, and the pathognomonic sign of iliac horns.<sup>1,2</sup> However, NPS is not restricted to these 4 symptoms and this way can affect other systems such as the eye or the kidneys.<sup>1,3,4</sup> It has been recognized for more than 100 years and has an estimated prevalence of 1 per 50,000 live births.<sup>1</sup> The knees may be involved with a hypoplastic and/or dislocated patella, and premature osteoarthritis may develop causing recurrent patellar dislocations, deformity of knee joint, instability and pain.<sup>1,5,6,7</sup>

Since this is a rare syndrome, there is not many information about the progression of the disease and the appropriate treatment to sustain the quality of life of these patients. Thereby we are providing more information about NPS, as well as the outcome and technical considerations of the TKR.

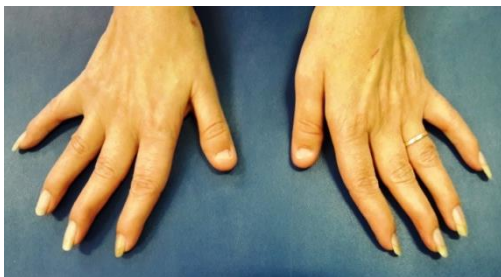**CASE PRESENTATION**

A 51 years old female patient with Nail-Patella Syndrome (NPS) affecting several organs is followed by orthopedics for knee pain and absent patella.

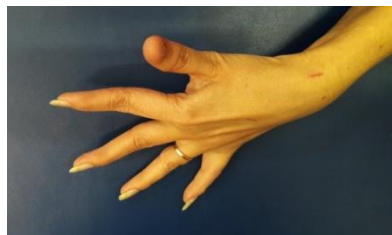This patient was diagnosed in her youth with this rare syndrome and besides fulfilling all of the criteria of the classical tetrad, has also affected kidneys and some limb deformities such as bilateral talipes equinovarus (club foot) and ‘swan neck fingers’.<sup>1</sup> The club foot was surgically treated during her first year of life. The findings from the physical examination are shown in figures 1 to 6.

In spite of being a hereditary disease, there is no previous record of affected family members.

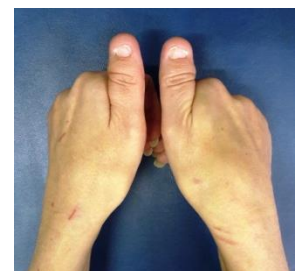30 years after the diagnosis, this patient presented with severe left knee function reduction and pain which did not responded to physical rehabilitation nor pain killers and the decision to undergo a left total knee replacement (TKR) was taken.



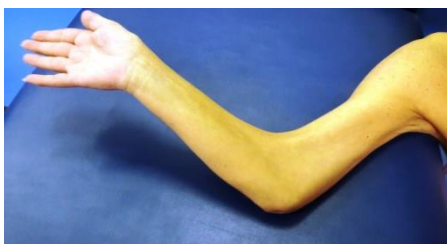**Figure 1** – Nail abnormalities.



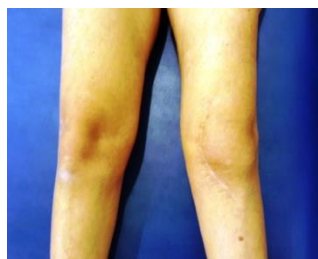
**Figure 2** – ‘Swan neck’ fingers’.



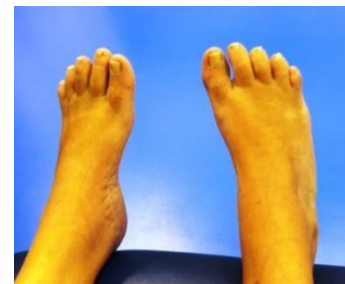**Figure 3** – Nail dysplasia.



**Figure 4** – Elbow arthrodysplasia.



**Figure 5** – Patellar aplasia.

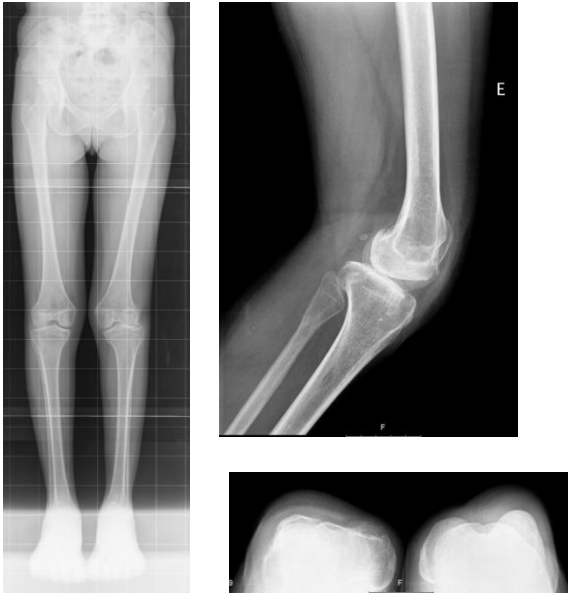

**Figure 6** – Treated club foot.



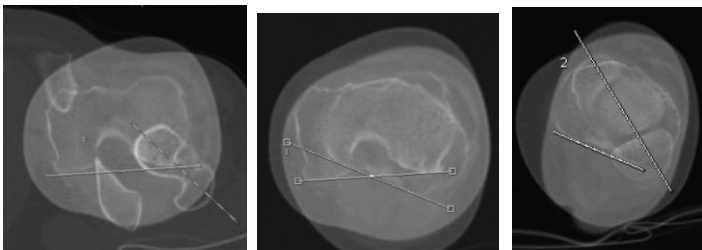
**INVESTIGATIONS**

To analyze the knee joint and to check the presence of osteoarthritis, imaging studies were performed. Pre-operative X-rays (figure 7) reveal a valgus alignment of the left (LL) – 3.5°; knee arthrosis Kelgreen-Lawrence IV, essentially of the external condyle and patellar aplasia.



**Figure 7** – Pre-operative X-rays; Long-leg – Left, Side view – Top right, Axial view – Bottom right.

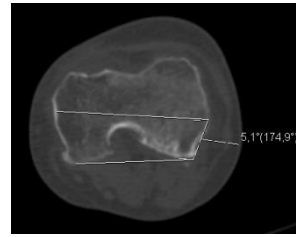
Besides, CT-scan was made, showing an important rotation malalignment: femoral anteversion of 47°, femorotibial rotation of 23° and external tibial torsion of 36°. Study in Figure 8.



**Figure 8** – Pre-operative CT-Scan with important rotation malalignment.

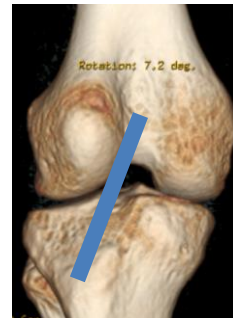
With the aim of putting the femoral component of the prosthesis with the correct rotation, the angle between the

inter-epicondylar line of the femur and posterior condylar line – 5.1°; was also determined (figure 9).



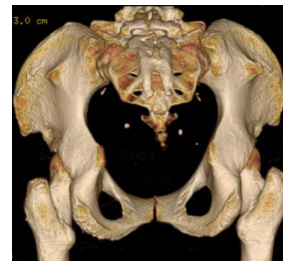
**Figure 9** – Pre-operative CT-Scan measuring the angle between the inter-epicondylar line of the femur and posterior condylar line – 5.1°.

In the 3D reconstruction of the knee joint (figure 10), a lateral translation of the tibial anterior tubercle is noted: the transverse plane distance between the trochlear groove and the tibial anterior tubercle was 32mm.



**Figure 10** – Pre-operative 3D reconstruction of the knee joint showing a 32mm lateral translation of the tibial anterior tubercle.

This patient has the pathognomonic sign of NPS – Iliac horns; and these are shown in figure 11.



**Figure 11** – Pre-operative 3D reconstruction of the pelvis revealing the iliac horns.

The left knee function was scored using the Knee Injury and Osteoarthritis Outcome

# TOTAL KNEE REPLACEMENT IN NAIL-PATELLA SYNDROME

## Prótese Total do Joelho no Síndrome Unha-Rótula

Score (KOOS). The results are shown in table 1 and are graded from 0 to 100 in which 100 represents the maximum function of the joint.

	Preop	Postop
<b>Pain</b>	36	28
<b>Symptoms (Spt)</b>	43	21
<b>Daily living (ADL)</b>	21	26
<b>Sports/Recreation</b>	15	0
<b>Quality of life (QoL)</b>	31	19

**Table 1** – KOOS pre-op and 3 years postop for left knee; Graded 0-100.

### TREATMENT

The patient was placed in dorsal decubitus under spinal anesthesia with tourniquet at the root of the left LL.

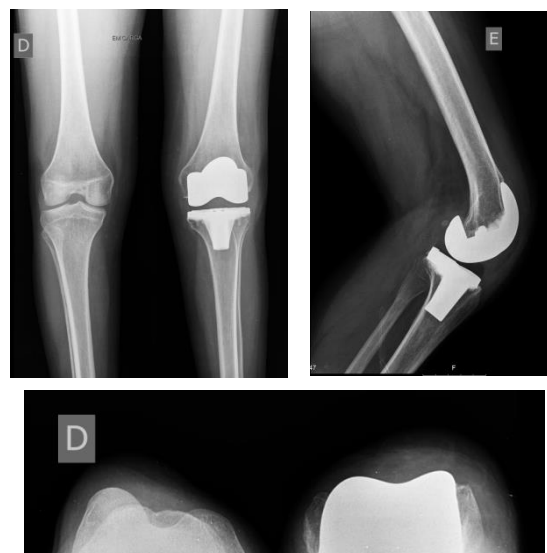
Internal paramedian incision in the left knee. Progression by planes and arthrotomy of the knee medially to the extensor apparatus. Preparation of the tibia with extramedullary guide, with cut of the tibial plate with 7 ° of posterior slope. Preparation of the femur, with intramedullary guide, with posterior cruciate sacrifice, with 5 ° of external rotation with 6 ° of valgus.

After checking the ligament balance, a femur size c and a tibia size 2 were implanted with 10 mm of polyethylene (PE). The extensor apparatus was left in its previous position, untouched.

Normal closing sutures were made. Although the lateralization of the tibial anterior tubercle, it was decided not to interfere with native extensor mechanism alignment, as the patient lacked a proper patella bone.

### OUTCOME AND FOLLOW-UP

6 months after the TKR, X-Rays studies were repeated and are shown in figure 12.



**Figure 12** – Post-operative X-rays; Front view – Top left, Side view – Top right, Axial view – Bottom right.

The following studies were made 3 years after the TKR. Clinically, the patient reported not feeling better when compared to her previous situation, disappointed with the surgical outcome.

She referred pain during the normal day activities, locating it essentially to the anterolateral aspect of the knee.

When asked if she would be submitted to surgery again, she declined it.

To more objectively check the results of the TKR, the patient was asked to submit a new KOOS questionnaire 3 years after the procedure. The results are shown in table 1 and are graded from 0 to 100 in which 100 represents the maximum function of the joint.

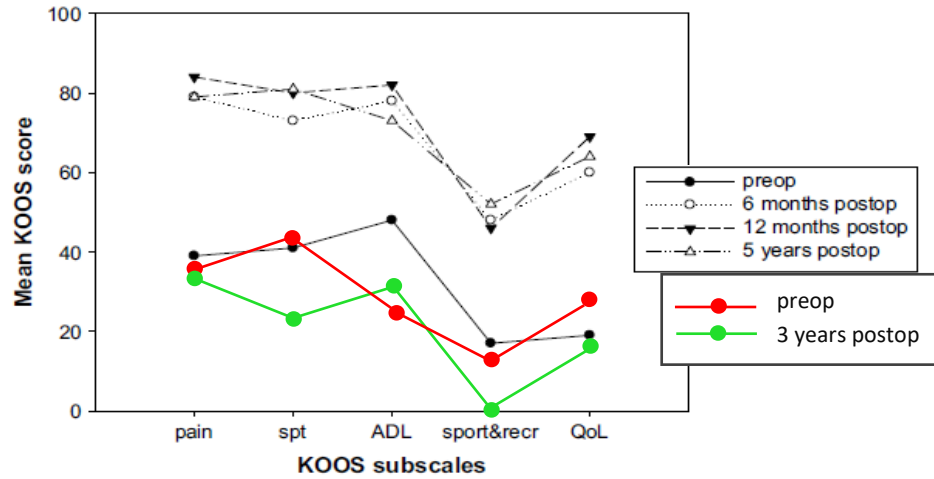
Range of Motion (RoM) was measured in the knee joints, hips and ankles and the results are shown in table 2.

	Knees		Hips		Ankles	
	L	R	L	R	L	R
<b>Ext.</b>	-10°	N	N	N	50°	40°
<b>Flex.</b>	100°	135°	N	N	0°	0°
<b>IR</b>	–	–	30°	40°	–	–
<b>ER</b>	–	–	70°	70°	–	–

**Table 2** – RoM of the knee joints, hips and ankles; (L – Left, R – Right, Ext. – Extension, Flex. – Flexion, IR – Internal Rotation, ER – External Rotation, N – Normal).

In order to understand the meaning of the results, these were arranged in graphic 1 in which the expected results of a TKR,

according to Nilsdotter et al (2009), are shown in 4 KOOS profiles: prior to and at three time points following TKR.



**Graphic 1** – KOOS profiles prior to and up to 5 years after TKR. Mean KOOS scores (n=80) at the preoperative, 6 months, 12 months and 5 year assessments after TKR (Nilsdotter et al, 2009); The colored lines represent the preop and 3 years after the TKR of this patient.

### Gait Analysis Protocol

For the purpose of analyzing the gait, a set of retroreflective markers were placed in relevant anatomical points of the subject and the movements of the body segments were tracked and registered by 12 infrared motion capture cameras (Qualisys AB, Sweden) operating at a sampling rate of 200 Hz. Simultaneously, the ground reaction forces were recorded with five extensometric (Bertec, USA) and one piezoelectric (Kistler, USA) force platforms operating at a sampling frequency of 2000 Hz and synchronized with the motion capture system.

The marker setup used to model the lower limbs was based on the IORGait application and the feet were modelled with the Oxford marker setup.

The patient was instructed to walk in a natural way, barefoot, at a comfortable pace along a 10m gait corridor, with the platforms and motion capture recording area situated in the middle of this path. At least 10 valid data collections were recorded for further analysis.

The gait data was then processed in a biomechanical data analysis software (Visual 3D, C-Motion, USA) to extract spatial and temporal gait parameters, as well as lower limbs and feet joint angles, and force reaction information.

The reference data provided for comparison was collected from a healthy sample of population, from both gender, by LABIOMEPE – Laboratório de Biomecânica do Porto.

# TOTAL KNEE REPLACEMENT IN NAIL-PATELLA SYNDROME

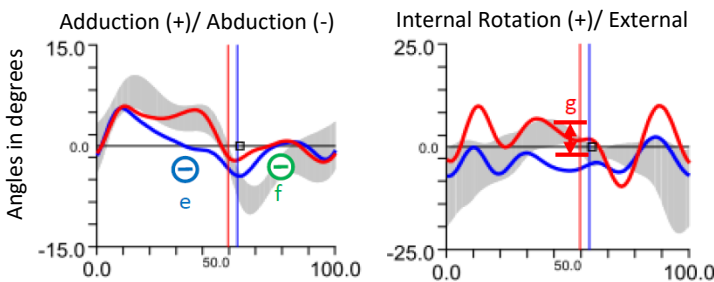
## Prótese Total do Joelho no Síndrome Unha-Rótula

Spatio-temporal parameters compared with J. Perry and J.M. Burnfield (2010) are shown in table 3.

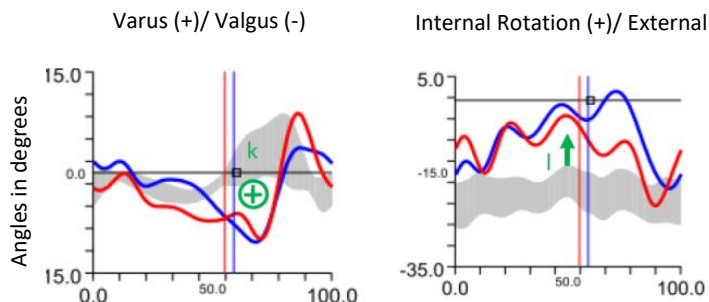
	Standardized		Standard
<b>Double stance phase</b>	14.4		20
	<b>Right Side</b>	<b>Left Side</b>	<b>Standard</b>
<b>Stance phase</b>	58.5	55.6	60
<b>Swing phase</b>	41.5	44.4	40

**Table 3** – Spatio-temporal parameters of the patient; Standard values of J. Perry and J.M. Burnfield (2010); values shown in percentage; Right and Left sides standardized.

The results of the angular kinematic of the gait relatively to the hip and knee joints are shown in graphic 2 and 3.

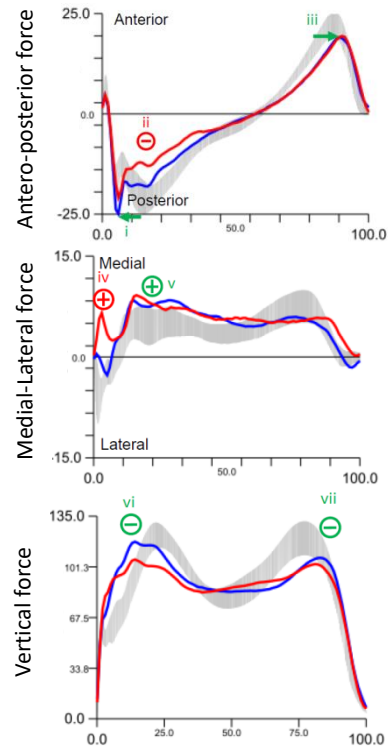


**Graphic 2** – Hip joints angular kinematic of the gait; Standard data – grey, Right side – blue, Left side – red; Vertical blue and red lines: right and left toe off, respectively; Horizontal axis: gait cycle time in percentage.



**Graphic 3** – Knee joints angular kinematic of the gait; Standard data – grey, Right side – blue, Left side – red; Vertical blue and red lines: right and left toe off, respectively; Horizontal axis: gait cycle time in percentage.

Ground reaction forces are shown in graphic 4 in which 3 different vectors are demonstrated: anteroposterior, medial-lateral and vertical.



**Graphic 4** – Antero-posterior, medial-lateral and vertical ground reaction forces; Standard data – grey, Right side – blue, Left side – red; Horizontal axis: duration of a single stand in percentage; Vertical axis: force in percentage of body weight.

### Isokinetic Dynamometry Protocol

A isokinetic dynamometer Biodex 4 (Biodex Medical Systems, Inc. USA) was used to assess the muscular function of the knee. The calibration of the device was checked before performing any measurement.

After a 5-minute warm-up period with the free dynamometer, a bilateral isokinetic protocol was performed to assess differences between right and left LL. The protocol consisted in 5 repetitions of knee extension/flexion at 60 °/s in concentric/concentric mode, with a range

# TOTAL KNEE REPLACEMENT IN NAIL-PATELLA SYNDROME

## Prótese Total do Joelho no Síndrome Unha-Rótula

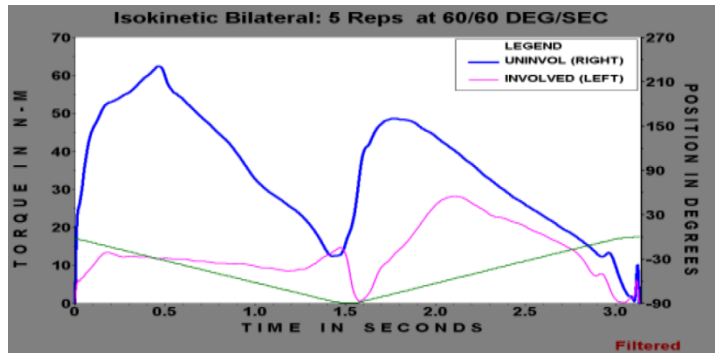
of motion of 90° starting from 90° of knee flexion to full knee extension. The patient was positioned on the device according to the recommendations of the manufacturer, the trunk and waist immobilized with the respective straps as well as the LL under evaluation. The protocol was initiated by the right limb with strong verbal encouragement.

Simultaneously, a surface electromyography (EMG) system was synchronized with the Biodex in order to measure the electromyographic activity of the Vastus medialis, Vastus lateralis and Retus femoris muscles during the protocol. Beforehand, skin was prepared according to Surface ElectroMyoGraphy for the Non-Invasive Assessment of Muscles – SENIAM; recommendations, which included the detection of the muscle belly, the light abrasion of the skin and cleaning the skin with 70% alcohol. After these steps, pairs of silver/silver-chloride electrodes Dormo&Blayco (Telic SA, Spain) were placed over the muscles and connected to an amplifier with a gain of 1100 times and a 2000Hz sampling frequency. Three attempts of Maximal Voluntary Contraction (MVC) were given to the patient in order to normalize the data.

EMG data processing was performed with a custom Matlab program which included a band-pass filter between 20-500 Hz, full-wave rectification and the calculation of the linear envelope of the signal by means of a Root Mean Square with a window of 150ms. This envelope was then normalized with the previously recorded MVC information. The data extracted includes the average and maximum values for each muscle activation during the isokinetic protocol.

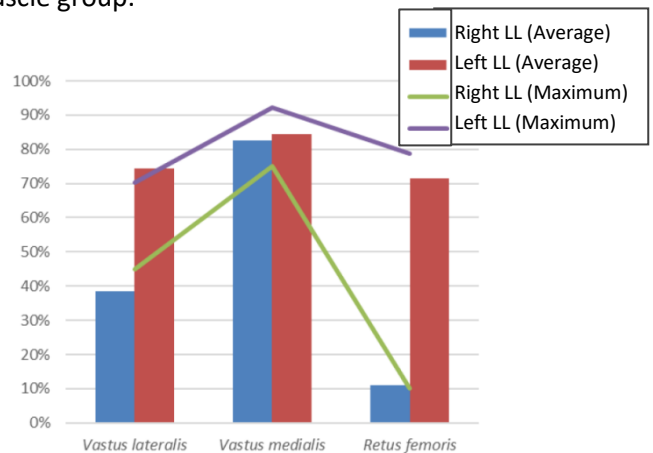
The isokinetic evaluation reveals smaller amplitude of motion of the left LL (73.0°) compared to the right (88.9°).

Muscle contraction differences between LL and muscle groups are shown in graphic 5.



**Graphic 5** – Strength values for isotonic muscle contraction; 0-1.5s –Extensor movement, 1.5-3s – Flexor movement.

The following graphic (6) represents the average and maximum activation of each muscle group.



**Graphic 6** – Average muscle activation (vertical bars) and maximum activation (lines) of the extensor muscles in the LL.

## DISCUSSION

Table 2 shows the left knee joint with a RoM extension of -10° and 100° of flexion, compared to the right knee joint with normal extension and higher flexion (135°). Both hip joints have normal RoM extension and flexion and are similar in rotation, presenting with 70° of external rotation

and 30 °(L) and 40 °(R) of internal. The ankles are also similar in RoM with 50 °(L) and 40 °(R) of extension and 0 ° of flexion, probably due to the club foot.

Analyzing graphic 1 it is clear that the TKR did not have the expected results, with the patient only improving in the ADL parameter. However, this increase is still lower than the preop average results.

Table 3 shows that along the gate there is a reduction in the stance phase and an increase in the swing phase in both lower limbs, being more marked in the left. The double stance phase is also greatly reduced in both lower limbs.

By graphic 2, the coronal plane of the right LL reveals a reduction in the adduction of the hip during the stance phase and, along with the left LL, a reduction in the abduction during swing phase. The hip rotation in both LL has a great variability, with the left LL showing the highest amplitude variation. The right LL tends to remain in external rotation while the left LL in internal.

Construing graphic 3, there is an increase in the valgus of both knees, which has its maximum value in the beginning of the swing phase, rapidly changing to a varus knee in equal value. Both knees show an increased rotation in a complete cycle, tending to the internal rotation.

The analysis of the ground reaction forces in graphic 4 reveals an anticipation of the first force peak in the antero-posterior direction, as well as vertically, indicating that the ground load is being applied early in the stance phase. Likewise, the last force peak occurs later during the preparation of the LL to leave the ground. Also, in the antero-posterior direction, the

posterior force performed by the left LL is inferior to the contralateral and to the reference values. Besides, the left LL shows an excessive force applied during the initial stance, contrarily to what expected. The force applied vertically is inferior to the reference in both first and second peak.

The strength values registered for both lower limbs in graphic 5 are inferior to the ones reported in scientific literature. While the right LL shows a balance between flexors and extensors coherent with a wounded knee according to Gibson et al (2000), the left LL reveals an extensor musculature with nearly half of the flexor, in contrast to what was expected.

Thus, besides a considerable strength deficit between the right and the left LL (being the left worse in both flexion and extension), the left LL has an extensor musculature severely compromised and incapable to promote a correct balance with the flexor one.

Although only the extensor muscles were analyzed, the electromyographic analysis (graphic 6) enhances these observations. The right LL shows a considerably greater activation of the *vastus medialis* than the other muscles, thus indicating a disproportion in terms of muscle activation. The left LL, on the other hand, does not present a disproportion in the activation of the three extensor muscles, but all of them show high activation values (close to 100% of the maximal voluntary contraction). This fact, associated with reduced production of momentum of concentric force indicates that the patient has great difficulty in translating the muscular activation in the production of extensor force.

### CONCLUSION

Knee-replacement surgery is frequently done and highly successful. It relieves pain and improves knee function in people with advanced arthritis of the joint.<sup>11</sup>

On this patient, however, this wasn't the case- she got worse after surgery.

These results may be explained by the patient's syndrome which may be responsible for other musculoskeletal comorbidities and predisposing to premature osteoarthritis.<sup>8,13</sup>

Careful planning has been made to ensure proper placement of the knee implants, with CT planning of the surgical technique.

Since the patient's pain locates mainly in the anterolateral part of the joint which is

compatible with the tibial anterior tubercle region, fixing this malalignment of the extensor muscles could probably change the patient's outcome.

Besides, the obtained results in the LL strength evaluation showing an extensor mechanism deficit as well as poor RoM outcome are also related to failure of the TKR.<sup>12</sup>

This might be the case of this patient, referring post-operative anterolateral knee pain, with established quadriceps function deficit of the operated limb, maintaining high values of voluntary contraction. By this way, the pain is working as a negative stimulus for the normal use of the joint and, if having an appropriate control of the inflammation, we believe muscular rehabilitation may have an important part in reducing its disability.

### LEARNING POINTS/ TAKE HOME MESSAGES

- NPS can present with musculoskeletal changes and several limb malformations. Patients with this syndrome require a more careful planning due to their comorbidities.
- Gait analysis and isokinetic dynamometry are important tools which can provide additional and crucial information to a patient's pre-op and post-op study, as well as to treatment.
- Bear in mind the possible outcomes of non-fixing the malalignment of the extensor muscles even though the absent patella.

#### **CONCLUSÃO**

A PTJ é uma cirurgia frequentemente feita e altamente bem-sucedida. Esta alivia a dor e melhora a função do joelho em pessoas com artrose avançada da articulação.<sup>11</sup>

Nesta paciente, no entanto, este não foi o caso – os seus sintomas pioraram após a cirurgia.

Esses resultados podem ser explicados pela síndrome do paciente, que pode ser responsável por outras comorbilidades musculoesqueléticas e predispondo a osteoartrose prematura.<sup>8,13</sup>

Um planeamento cirúrgico pré-operatório baseado em TC foi cuidadosamente efectuado de forma a assegurar o correto posicionamento dos implantes.

Uma vez que a dor da paciente localiza-se principalmente na porção anterolateral da articulação que é compatível com a região

da tuberosidade anterior da tibia, a correcção do alinhamento do aparelho extensor da doente provavelmente poderia alterar o resultado clínico da cirurgia.

Para além disso, os resultados obtidos na avaliação de força do membro inferior que mostram um défice do mecanismo extensor, bem como um fraco resultado de RoM, também estão, por si próprios, relacionados com falências de PTJ's.<sup>12</sup>

Este poderá ser o caso desta paciente, referindo dor pós-operatória na região anterolateral do joelho, com défice estabelecido de função do quadríceps do membro operado, mantendo altos valores de contracção voluntária. Desta forma, a dor funciona como um estímulo negativo para o normal uso da articulação e, tendo um adequado controlo da inflamação, acreditamos que a reabilitação muscular pode ter uma parte importante na redução de sua deficiência.

#### **MENSAGENS A RETER**

- O Síndrome Unha-Rótula pode manifestar-se com alterações músculo-esqueléticas e malformações severas dos membros. Pacientes com este síndrome carecem de um planeamento mais cuidadoso devido às comorbilidades existentes.
- A análise da marcha e a dinamometria isocinética são ferramentas importantes que podem fornecer informação adicional e informação crucial para o estudo pré e pós-operatório do doente, bem como para o tratamento.
- Relembrar os possíveis resultados de não alterar o mau alinhamento dos músculos extensores apesar da ausência de rótula.



## REFERENCES

1. Sweeney E. Nail patella syndrome: a review of the phenotype aided by developmental biology. *Journal of Medical Genetics*. 2003;40(3):153-162.
2. Lemley K. LMX1B mutations with nails and kneecaps: a new paradigm?. *Nephrology Dialysis Transplantation*. 2013;29(1):9-12.
3. Towers A, Clay C, Sereika S, McIntosh I, Greenspan S. Skeletal Integrity in Patients with Nail Patella Syndrome. *The Journal of Clinical Endocrinology & Metabolism*. 2005;90(4):1961-1965.
4. Tigchelaar S, Rooy J, Hannink G, Koeter S, van Kampen A, Bongers E. Radiological characteristics of the knee joint in nail patella syndrome. *The Bone & Joint Journal*. 2016;98-B(4):483-489.
5. Bongers E, Gubler M, Knoers N. Nail-patella syndrome. Overview on clinical and molecular findings. *Pediatric Nephrology*. 2002;17(9):703-712.
6. Beguiristáin J, de Rada P, Barriga A. Nail-patella syndrome: long term evolution. *Journal of Pediatric Orthopaedics B*. 2003;12(1):13-16.
7. Gong Y, Yang C, Liu Y, Liu J, Qi X. Treatment of patellar instability in a case of hereditary onycho-osteodysplasia (nail-patella syndrome) with medial patellofemoral ligament reconstruction: A case report. *Experimental and Therapeutic Medicine*. 2016.
8. Nilsdotter A, Toksvig-Larsen S, Roos E. A 5 year prospective study of patient-relevant outcomes after total knee replacement. *Osteoarthritis and Cartilage*. 2009;17(5):601-606.
9. Perry J, Burnfield J, Cabico L. *Gait analysis*. 1st ed. Thorofare, N.J: Slack; 2010.
10. St Clair Gibson A, Lambert M, Durandt J, Scales N, Noakes T. Quadriceps and Hamstrings Peak Torque Ratio Changes in Persons With Chronic Anterior Cruciate Ligament Deficiency. *Journal of Orthopaedic & Sports Physical Therapy*. 2000;30(7):418-427.
11. Carr A, Robertsson O, Graves S, Price A, Arden N, Judge A et al. Knee replacement. *The Lancet*. 2012;379(9823):1331-1340.
12. Lombardi Jr A, Berend K, Adams J. Why knee replacements fail in 2013: patient, surgeon, or implant?. *The Bone & Joint Journal*. 2014;96-B(11\_Supple\_A):101-104.
13. Vince K. The problem total knee replacement: systematic, comprehensive and efficient evaluation. *The Bone & Joint Journal*. 2014;96-B(11\_Supple\_A):105-111.