

2016

# Comparison of management and treatment options for recurrent breast fibroadenomas in adolescent females

---

<https://hdl.handle.net/2144/17045>

*Boston University*

BOSTON UNIVERSITY  
SCHOOL OF MEDICINE

Thesis

**COMPARISON OF MANAGEMENT AND TREATMENT OPTIONS FOR  
RECURRENT BREAST FIBROADENOMAS IN ADOLESCENT FEMALES**

by

**ALISHA SHERWANI**

B.S., Boston University, 2014

Submitted in partial fulfillment of the  
requirements for the degree of  
Master of Science

2016

© 2016 by  
ALISHA SHERWANI  
All rights reserved

Approved by

First Reader

---

R.J. Rushmore III, Ph.D.  
Assistant Professor of Anatomy and Neurobiology

Second Reader

---

Gwynneth D. Offner, Ph.D.  
Director M.S. Medical Sciences Program  
Associate Professor of Medicine

## **ACKNOWLEDGMENTS**

I would like to thank my family for their continued support throughout my entire academic journey; I can never say enough times how much I appreciate you all. I want to give special thanks to my parents, who have pushed me forward during the times where I felt as though I wanted to give up. Your continued love and support is a large factor in who I am and where I am today. Thank you very much, and I love you.

I would also like to extend my gratitude towards my readers, Dr. Rushmore and Dr. Offner for all of their support and guidance throughout my time here at BU MAMS. I could not have gotten through without you! Thank you for all of your help.

**COMPARISON OF MANAGEMENT AND TREATMENT OPTIONS FOR  
RECURRENT BREAST FIBROADENOMA IN FEMALE ADOLESCENTS**

**ALISHA SHERWANI**

**ABSTRACT**

Breast fibroadenomas account for approximately 25% of all lesions in asymptomatic women, resulting in large health care costs every year. There are 3 different variations of the disease: simple, juvenile giant and multiple. Patients may have different management and treatment options available to them depending on which variation they have. Of particular interest are female adolescents, who are at most risk for developing these lesions. With this age group not only is it important to pursue options that are minimally invasive and effective, but there are psychosocial implications to consider regarding the cosmetic changes that may occur with the disease, as well as generalized anxiety over having a breast lump. These issues are important to consider for physicians when recommending a treatment or management option. After a systematic review of all options available, it appears the best management method is the conservative treatment as it minimizes invasive intervention and operates on the principle that 10-40% of lesions regress on their own; however, there may be times that adolescents are uncomfortable with this treatment due to anxiety and other uneasiness about having a lesion remain in their breasts, despite the low chance of malignancy associated with breast fibroadenomas. Minimally invasive procedures are being developed in order to minimize possible iatrogenic injury to the developing breasts as

well as maintain efficiency and good cosmesis post-procedure. Cryoablation is a minimally invasive technique utilizing extreme cold temperatures for lesion excision that is not currently widely used, however it has great potential to replace traditional open surgical excision.

## TABLE OF CONTENTS

TITLE.....	i
COPYRIGHT PAGE.....	ii
READER APPROVAL PAGE.....	iii
ACKNOWLEDGMENTS .....	iv
ABSTRACT.....	v
TABLE OF CONTENTS.....	vii
LIST OF TABLES .....	x
LIST OF FIGURES .....	xi
LIST OF ABBREVIATIONS.....	xii
INTRODUCTION .....	1
Monitoring Options.....	3
Treatment Options .....	4
SPECIFIC AIMS AND OBJECTIVES .....	6
FIBROADENOMA BASIC INFORMATION .....	8
Simple Fibroadenoma .....	10
Multiple Fibroadenoma.....	11
Juvenile Giant Fibroadenoma .....	12
Calcifications .....	17



Complex vs. Non-Complex .....	19
LESION CLASSIFICATION SYSTEMS .....	20
ANDI Classification.....	20
Mammography BI-RADS.....	22
Ultrasound BI-RADS.....	23
Category 0: Prior to Imaging .....	23
Category 1: Negative .....	24
Category 2: Benign .....	24
Category 3: Probably Benign.....	24
Category 4: Suspicious .....	25
Category 5: Highly Suggestive of Malignancy.....	25
Category 6: Known Malignancy.....	26
EVALUATIONS OF MONITORING OPTIONS.....	28
IMAGING.....	28
MAMMOGRAM .....	30
ULTRASOUND .....	31
BIOPSY .....	35
OPEN BIOPSY.....	35
FINE NEEDLE ASPIRATION .....	37
PERCUTANEOUS BIOPSY.....	38
OTHER TEQNIQUES IN DEVELOPMENT .....	47
CONSERVATIVE MANAGEMENT .....	48

PALPABLE VS NON-PALPABLE LESIONS.....	50
EVALUATION OF TREATMENT OPTIONS .....	52
OPEN SURGERY .....	54
LUMPECTOMY.....	54
MASTECTOMY.....	58
ENDOSCOPIC SURGERY .....	58
MINIMALLY INVASIVE ALTERNATIVES .....	59
VACUUM-ASSISTED EXCISION.....	60
ABLATION .....	63
CONCLUSION.....	69
ASSESSMENT OF MANAGEMENT AND TREATMENT COMBINATIONS .....	69
SIMPLE FIBROADENOMA .....	69
JUVENILE GIANT FIBROADENOMA.....	70
MULTIPLE FIBROADENOMA .....	71
OPINIONS IN LITERATURE REGARDING FUTURE STUDIES .....	72
REFERENCES .....	74
CURRICULUM VITAE.....	84

## LIST OF TABLES

Table	Title	Page
1	Comparison of Fibroadenomas and Phyllodes Tumors	15
2	Ultrasound BI-RADS Assessment Categories	26
3	Comparison of Diagnostic Accuracy Between LCNB and VAB	40
4	Comparison of Treatment Methods	53

## LIST OF FIGURES

Figure	Title	Page
1	Breast Fibroadenoma	2
2	Simplified Anatomy of the Female Breast and its Lesions	8
3	Juvenile Giant Fibroadenoma Present in Adolescent Female	13
4	MRI Image of Juvenile Giant Fibroadenoma	14
5	Excised Juvenile Giant Fibroadenoma in Adolescent Female	16
6	ANDI Classification of Benign Breast Lesions	22
7	Imaging Characteristics of Lesions	29
8	Mammographic Image of a Breast Fibroadenoma	31
9	Comparison Between B-mode Sonography and THI	34
10	Percutaneous Biopsy Instruments	39
11	Percentage of Fibroadenoma Recurrence using US-Guided VAE	62
12	Visualization of Iceball on Ultrasound in Cryoablation Procedure	66
13	Reduction of Lesion Size Post-Cryoablation	67

## LIST OF ABBREVIATIONS

ACR.....	American College of Radiology
ACS.....	American Cancer Society
ANDI.....	Aberrations of Normal Development and Involution
ATEC.....	Automated Tissue Excision and Collection
BI-RADS.....	Breast Imaging-Reporting and Data System
CI.....	Compound Imaging
FNA.....	Fine Needle Aspiration
LAD.....	Lymphadenopathy
LCNB .....	Long/Large Core Needle Biopsy
MRI.....	Magnetic Resonance Imaging
THI.....	Tissue Harmonic Imaging
US.....	Ultrasound
VACB.....	Vacuum-Assisted Core Biopsy
VAE.....	Vacuum-Assisted Excision

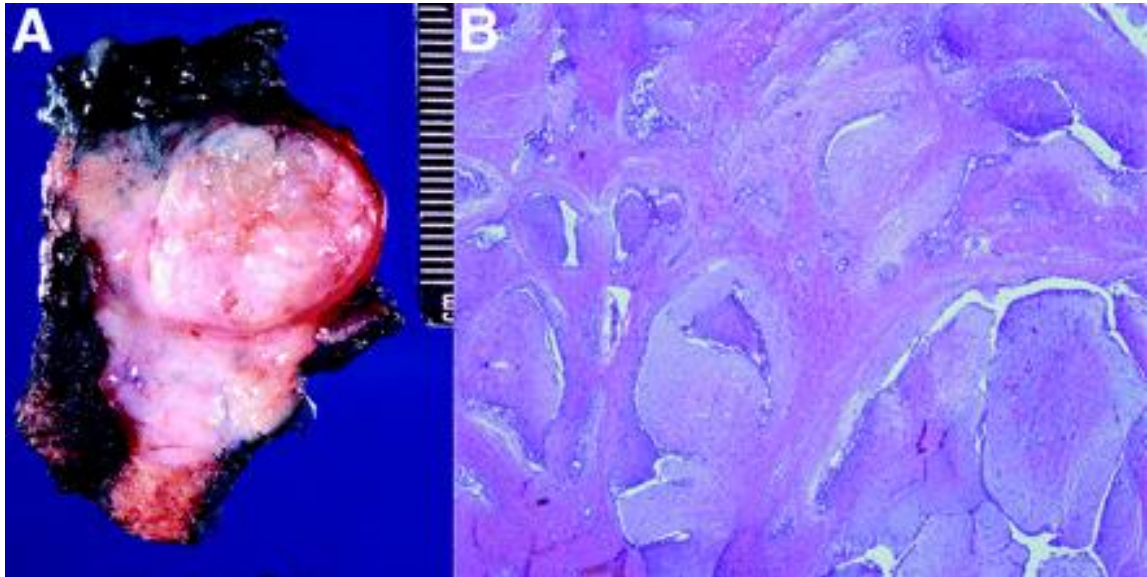
## INTRODUCTION

Benign breast lesions are one of the most common growth disorders in women (Duflos, Plu-Bureau, Thibaud, & Kuttann, 2012). The most common lesions in this category are fibroadenomas, accounting for nearly 25% of women (El-Wakeel & Umpleby, 2003). In adolescent females this number is even higher, ranging between 54%-94% of all cases (Ezer et al., 2013) It is second only to carcinoma in overall frequency of breast tumors (Nagasue, 2002), signifying its clinical relevance.

Fibroadenomas are defined by Guray & Sahin (2006) as a palpable breast mass that may be mobile and firm, often palpable under the skin. They are usually unilateral in 90% of the cases (C. A. Park, David, & Argenta, 2006) however it may be present bilaterally and may be either singular or multiple per breast (ACS, 2015). They can range in size from less than 5cm to larger, with the largest ones, typically seen as a giant juvenile fibroadenoma, greater than 10cm during puberty or pregnancy (Santen, 2000).

Macroscopically, fibroadenomas are well-circumscribed with the excised lesion appearing characteristically lobulated and bulging (Guray & Sahin, 2006).

Microscopically, fibroadenomas consist of a proliferation of connective and epithelial tissue. The stroma proliferates around tubular glands or compressed cleft-like ducts (Guray & Sahin, 2006). Both views can be seen in figure 1.



**Figure 1: Breast Fibroadenoma.** (A) This depicts an excised fibroadenoma. Note the gray-white color and size, ranging from 14-17cm, indicating that this is perhaps a juvenile giant fibroadenoma. (B) Microscopic view of a fibroadenoma. Note the compressed cleft-like ducts. (Figure from Guray & Sahin, 2006).

The peak age of incidence is between the ages of 15-35 (Guray & Sahin, 2006), further emphasizing the role of fibroadenomas on adolescent life. Especially important to the adolescent age group are the associated psychosocial implications of this disease, such as psychological and physical embarrassment, as it is mainly viewed as a cosmetic disease due to the low chance for malignancy (Duflos et al., 2012). This, in combination to its prevalence, is why it is critical for physicians to be aware of the various management options and treatments currently available and recommended, as well as which is most cost-effective for the patient's individual type and size of fibroadenoma (Jayasinghe & Simmons, 2009).

Palpation, breast imaging and biopsy are currently the methods used to monitor fibroadenomas, with treatment options including surgical removal, vacuum-assisted core biopsy (VACB), ablation and a more conservative observation approach.

### **Monitoring Options**

Discovery of the breast lumps is typically first done via physical palpations, either by the physician finding them during routine breast exams or the patient themselves discovering the lumps with self-examinations or simply feeling a difference in their breasts. These palpations are used, along with sonography and biopsy to determine whether it is indeed a fibroadenoma, other benign breast tumor, or possibly, albeit rare in adolescents, breast cancer (Greenberg, Skornick, & Kaplan, 1998a).

Imaging is used as a next step upon finding an unidentifiable breast mass. Mammography is known to be the most informative, however since the high adolescent breast density interferes with detection of masses, mammography is not recommended for this age group (Chung et al., 2009). Instead ultrasound (US) is the most efficient method of imaging, and is rapidly becoming the imaging method of choice for certain procedures or biopsies. Upon observing the mass, or masses in case of multiple, there may be a biopsy procedure done to confirm the nature of the lesion if anything appears to be suspicious. This is typically done in adolescents due to patient or family member anxiety, however if a breast mass is shown to be benign via imaging and following other strict criteria, there may not be a need for biopsy and instead the physician will recommend less invasive monitoring, such as the conservative method (Jawahar, Vade, Ward, Okur,



& Subbaiah, 2015). According to the study done by Jawahar et al. (2015), any change in dimension, volume, or appearance in sonography must be recorded in order to determine whether or not biopsy should be performed to confirm identification of the mass.

### **Treatment Options**

Due to the predominately benign diagnosis of a breast tumor, or fibroadenoma in particular, there have been recent controversies over which treatment is most effective (Ezer et al., 2013). As Ezer et al.(2013) explains, due to a variety of opinions, the ultimate decision is up to the patient and their family on which route they prefer. One method is conservative management, in which there are frequent sonography checkups to monitor the tumor for growth and no other invasive procedures done (Greenberg et al., 1998a). The decision to pursue this method is supported the knowledge that approximately 10-40% of masses regress completely after a certain period of time (Jayasinghe & Simmons, 2009; Neinstein, Atkinson, & Diament, 1993). The procedure that dominates the field at the moment is surgical removal of the tumor, also known as a lumpectomy (Kaufman et al., 2002). As noted by Kaufman et al., (2002) this method is not the most ideal due to its longer recovery stage, potential for cosmetic scarring and the daunting task of undergoing surgery. The current direct alternative is vacuum-assisted biopsy, in which tumors up to 3cm may be removed with less cosmetic damage (Kolkman & Zonderland, 2011). This is achieved with a cannula under the guidance of US, though it requires sedation and can often be difficult to remove the entire fibroadenoma, leading to recurrent cases if there is any malignancy involved (Nurko et

al., 2005). Newer studies on cryoablation have been shown to be cost-effective alternatives to current convention, though there is a long follow-up time, particularly for the larger mass sizes (Nurko et al., 2005).

There may be times where one or more new fibroadenomas grow after one is removed (ACS, 2015), leading to another important factor to be considered when different treatment modalities are considered: chance of recurrence. While this recurrence is typically due to a new formation or growth of pre-existing fibroadenoma, and not regrowth of the previously excised lesion (ACS, 2015), it can still mean multiple treatments for a patient. For adolescents, this may mean continuous surgeries, biopsies or other treatments that may impede normal developmental growth of the breast buds. Even the least invasive methods still have a chance for iatrogenic injury, as well as psychosocial complications for the multiple treatments. The focus of this thesis therefore is to look into the most cost-effective options available for such cases in adolescents, while also paying special attention to patient satisfaction and chance for cosmetic defects.

## **SPECIFIC AIMS AND OBJECTIVES**

There are a number of treatment options available for fibroadenomas that need to be considered for adolescents, particularly because of the patient's young age. The focus of this thesis is to pinpoint which options are more cost-effective and catered to the younger population by analyzing the existing practices.

The specific aims of this thesis are to:

1. Identify key components of the different types of adolescent fibroadenomas and their importance, such as the risk factor for future malignancy, cosmetic damage, and the psychosocial implications specific to this age group.
2. Evaluate the current Breast Imaging- Reporting and Data System (BI-RADS) system of classification for fibroadenomas and how the system corresponds to adolescents, as well as assess available treatment methods and current recommendations regarding the individual categories of classification.
3. Assess the various management methods in the following categories: accuracy in diagnosis, cost-effectiveness, patient compliance, and cosmetic damage and patient satisfaction.
4. Assess the various treatment methods in the following categories: cost-effectiveness, accessibility of treatment, chance of recurrence,

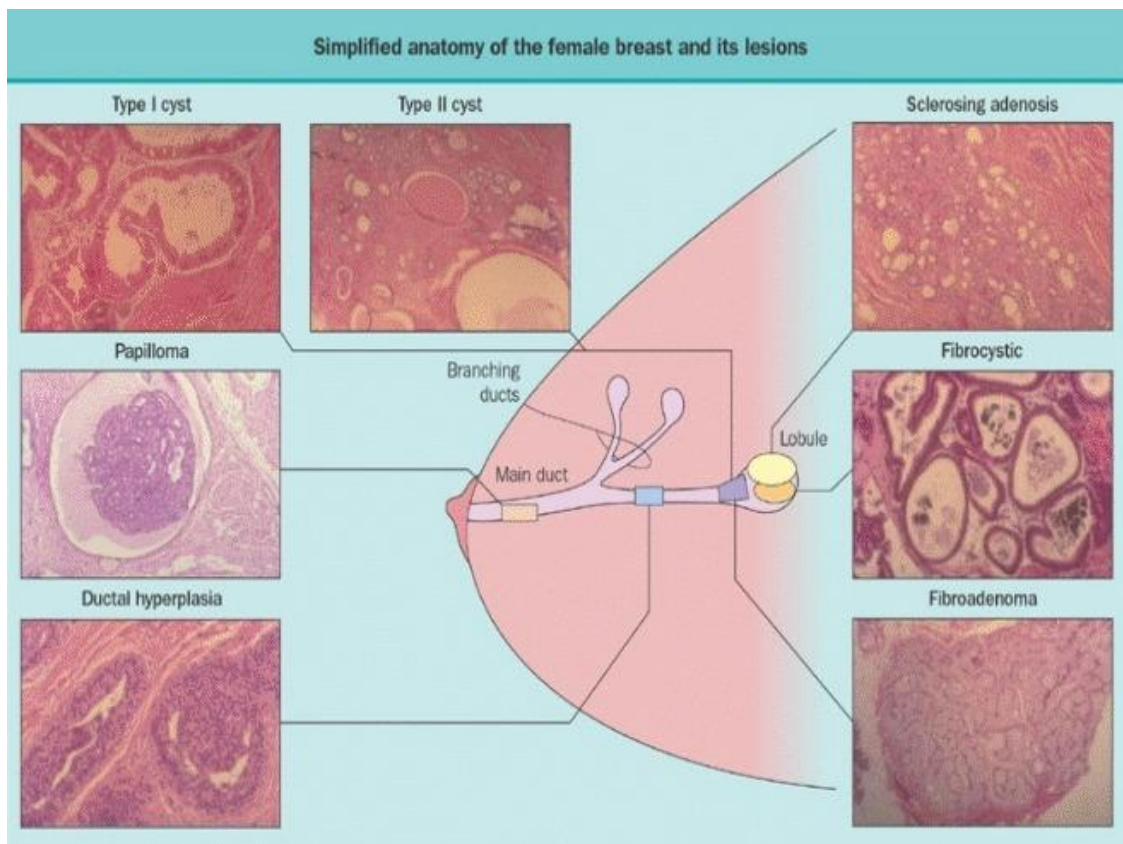
undesirable elements, cosmetic damage and patient satisfaction, and cosmesis.

5. Determine the most effective treatment and management methods to date for the various types of fibroadenomas in adolescents and what future procedures might improve upon.

The goal of this literary review is to assess the available management options and treatments and determine which of the options might most effectively treat the disease in female adolescents.

## FIBROADENOMA BASIC INFORMATION

Fibroadenomas develop from the stroma of the mammary gland lobule (Figure 2) and, due to their typical superficial locations in the breast, are often palpable (ACS, 2015). During breast examination the patient, or provider, may press in the area and feel a firm, spherical mass that appears rubbery and non-tender (Guray & Sahin, 2006). Patients may report it feels like a marble within the breast that you can freely move around under the skin (ACS, 2015), a helpful indicator for providers upon initial consultation. In up to 20% of the cases there may be multiple palpable lesions in a single breast or even several on both sides (Guray & Sahin, 2006).



**Figure 2: Simplified Anatomy of the Female Breast and its Lesions.** Due to their spherical shapes and similar locations, fibroadenomas and cysts are often suspected together upon palpation of an abnormal mass. Typically imaging or histology can differentiate between the two as cysts are fluid-filled and fibroadenomas are solid. (Figure from Santen, 2000).

The exact etiology of fibroadenomas is currently unknown; however there are many speculations in literature that it may be related to changes in the levels of reproductive hormones. To begin with, fibroadenomas are typically detected during the early stages of reproductive life when these hormones play vital roles in development (Matz et al., 2013). Epithelial components within the lesion have also been shown to be hormone responsive, as they are stimulated by various factors including estrogen, progesterone, pregnancy, and lactation (Santen, 2000). Fibroadenomas are known to expand in size during the menstrual cycle (Cerrato & Labow, 2013; Lee & Soltanian, 2015), lactate during pregnancy, and shrink with the rest of the breast in perimenopause (El-Wakeel & Umpleby, 2003; Hughes, Mansel, & Webster, 1987). Despite the influence of estrogen on fibroadenomas, conservative therapy with progesterone and danazol does not work as the fibroadenomas fail to respond to the antiestrogen medications (Greenblatt, Nezhat, & Ben-Nun, 1980). Aside from the reproductive hormones, studies have also shown that fibroadenomas may also be linked to body mass index (Lee & Soltanian, 2015) and underlying or acquired genetic components (Santen, 2000). Further investigation is underway to pinpoint more definitive causes, however at this time they are not preventable.

As of now there are two types of fibroadenomas, simple and giant juvenile fibroadenomas (Cerrato & Labow, 2013). Both of these types may be either singular or

multiple, leading to a separate class known in literature as multicentric fibroadenomas. Simple fibroadenomas are the most common type and account for approximately 70-90% of all cases (Lee & Soltanian, 2015). Giant juvenile fibroadenomas are rare, only accounting for approximately 0.5-8% of cases (Divasta et al., 2012; Lee & Soltanian, 2015) and typically occurring in earlier ages. Multicentric fibroadenomas account for approximately 10-25% of all cases, and have no specific age range of its own. Each case varies from individual to individual, and similarly the treatment and management options vary depending on the types.

### **Simple Fibroadenoma**

Simple fibroadenomas are, as their name suggests, the most basic type in terms of composition and management. Simple fibroadenomas are not associated with any risk of breast cancer (Guray & Sahin, 2006) and is therefore most often watched conservatively. If there are any significant changes in size or composition over time, the fibroadenoma may be biopsied, however this is quite rare. Typically these fibroadenomas remain static at 2-3cm in size; however they may spontaneously regress or enlarge regardless of hormonal factors (Guray & Sahin, 2006). For a simple fibroadenoma 10-40% of cases result in complete regression without any sort of intervention (Jayasinghe & Simmons, 2009; Neinstein et al., 1993) which is another reason why conservative treatment is the commonly used pathway for this type. Aside from rapid enlargement, suspected malignancy or symptoms including pain in rare cases, the only reason for surgical intervention in this type is due to patient or family member anxiety, despite the fact that

there is less than a 1% chance for malignancy (Lee & Soltanian, 2015). This is especially true in the adolescent population, for which this type is most commonly seen. There is typically little change in outward appearance of the breasts for this type, as they are too small to be seen in even the early developmental stages; however there have been cases reported where the fibroadenoma was so superficial it was visible as a lump protruding from the skin.

### **Multiple Fibroadenoma**

Multiple fibroadenomas typically occur with the simple type; multiple giant fibroadenomas are rare and mainly occur in adolescent and young adult African American females (Musio, Mozingo, & Otchy, 1991). There appears to be a strong genetic component in the majority of reported cases in both multiple giant fibroadenomas and multiple simple fibroadenomas (Williamson, Lyons, & Hughes, 1993). There are usually only one or two fibroadenomas unilaterally, however there have been cases reported with multiple bilaterally or even up to four in a single patient (Williamson et al., 1993). The chance for malignancy in this type may be higher than simple fibroadenomas though an exact determination has yet to be identified. Due to the spontaneous changes in size of fibroadenomas, it is not inconceivable that after an enlarged lesion is removed, one of the previously small lesions may grow to an uncomfortable size and require more intervention. While there is little cosmetic damage to the breast in this type, as with simple fibroadenomas, after multiple surgical interventions or biopsies there may be iatrogenic injury. For this reason most multiple fibroadenomas are watched

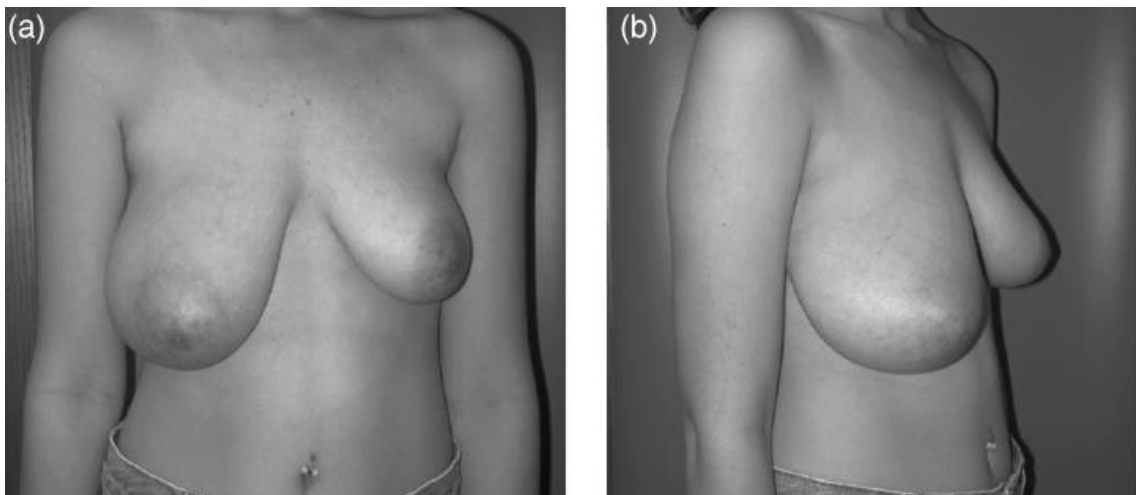


conservatively until a reason to remove them arises. In adolescents there may be cause for anxiety; however surgical intervention is less likely due to its chance of recurrence.

### **Juvenile Giant Fibroadenoma**

Juvenile fibroadenoma is a variant of simple fibroadenoma that presents earlier in adolescents at the onset of puberty, typically between 10 and 18 years of age, and are usually painless, solitary, and unilateral masses greater than 5cm in size (Guray & Sahin, 2006; Ng, Mrad, & Brown, 2011). They are usually located in the outer upper quadrant of the breast (Thuruthiyath, Das, Avabratha, Mascarenhas, & Marla, 2012) and are the most common cause of unilateral enlargement of the breast tissue in excess of normal proportion, also known as macromastia, in adolescents (Musio et al., 1991). Juvenile giant fibroadenomas are rapidly growing lesions with associated skin ulcerations, erythema, venous engorgement, and stretched overlying skin (Chepla, Armijo, Ponsky, & Soltanian, 2011; Divasta et al., 2012). Other changes can include both stretching of the areola complex and distortion of the dermal tissue underneath (Matz et al., 2013). They compress adjacent tissue, distort lobular architecture, and create pea d'orange, nipple inversion, and skin dimpling (C. A. Park et al., 2006). Unlike the simple fibroadenomas, giant fibroadenomas are often associated with significant cosmetic damage and, consequently, psychosocial implications. Giant fibroadenomas are known to cause unpleasant interactions with the patient's peers and have a considerable impact on self-esteem, confidence and other psychological and emotional states (Sosin et al., 2015). Interestingly, if there is minimal cosmetic change between the breasts aside from the

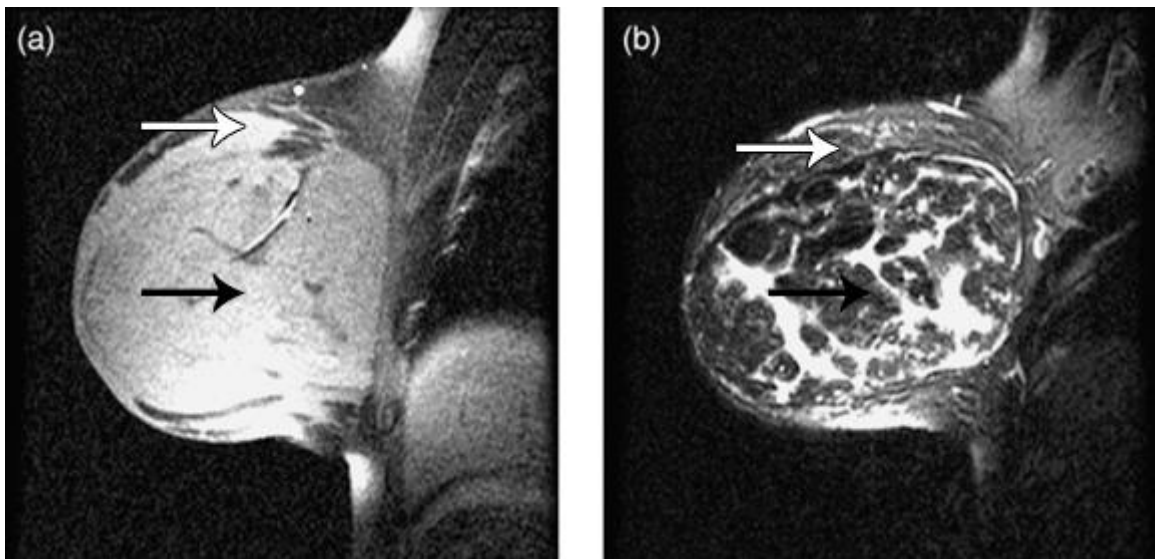
enlarged size patients report in initial consultation they believe the contralateral, smaller breast is the problem. They are relatively at ease with the pathologically enlarged breast, particularly if there is significant difference in size between the two (C. A. Park et al., 2006). It is therefore important they are referred to a specialist with experience in this field to facilitate a more focused evaluation and treatment strategy incorporating the psychosocial and sensitive elements involved (Sosin et al., 2015). Figure 3 illustrates a case in which the patient may have preference to the larger breast, as there is little difference aside from the size of the areola complex.



**Figure 3: Juvenile Giant Fibroadenoma Present in Adolescent Female.** Adapted from (C. A. Park et al., 2006).

Aside from outward appearance, there is also significant concern from the patient or their family regarding the malignant potential or altered breast development due to these giant fibroadenomas (Chepla et al., 2011). This is not unwarranted, as it has been shown that giant fibroadenomas are considered indicators of malignancy and almost always biopsied (Neinstein, 1999). Malignancy is not the only reason giant juvenile

fibroadenomas are biopsied initially; giant fibroadenomas have a tendency to compress and possibly replace normal breast tissue, causing the giant fibroadenoma to be confused for normal tissue (Choo et al., 2008). As a result, it is difficult to differentiate between a giant fibroadenoma and juvenile hypertrophy without histologic evidence, even with imaging. The only other helpful indicator is that juvenile hypertrophy is typically bilateral and even (Divasta et al., 2012). Figure 4 shows an MRI image taken of a juvenile giant fibroadenoma. If possible, note in 4A the faint lines outlining the fibroadenoma; this can be difficult to detect in an untrained eye without T2-weighting to enhance the septations and encapsulation, which is shown in 4B. There it is easier to see the encapsulated fibroadenoma and the differences in composition between the lesion and surrounding tissue that would otherwise be difficult to tell apart. Of interest, with the T2-weighted image (4B) it is also clear to see how severely the surrounding normal breast tissue has been compacted and replaced by the lesion.



**Figure 4: MRI Image of Juvenile Giant Fibroadenoma.** (A) Baseline MRI image. (B) T2-weighted image of the same breast. Adapted from (C. A. Park et al., 2006). The white arrow points to normal breast tissue, while the black arrow points to the center of the lesion.

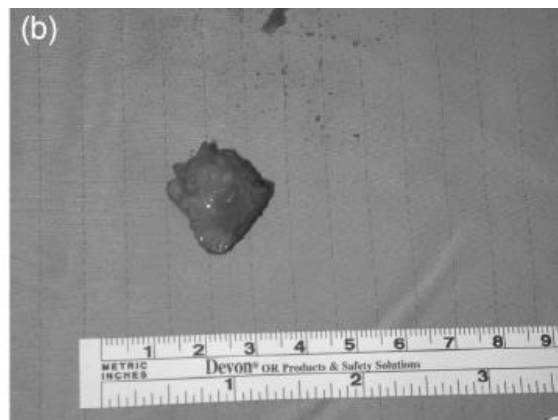
Another lesion that is often confused with giant fibroadenomas is the phyllodes tumor. Breast phyllodes tumors do not typically present in adolescents, as they arise during the ages of 35-55 (Celik et al., 2015), however it is not impossible. They are similar to giant fibroadenomas; however they have increased cellularity and tendency to recur and metastasize (Celik et al., 2015). Phyllodes tumors are often associated with malignancy, particularly if the lesion is as large as giant fibroadenomas, so differentiating the pathology is important prior to surgical excision (Celik et al., 2015; Sosin et al., 2015). Table 1 illustrates the macroscopic and microscopic differences between simple fibroadenomas, juvenile giant fibroadenomas and phyllodes tumors. Note the macroscopic similarities necessitate microscopic evaluation to differentiate between the juvenile giant fibroadenoma and the benign phyllodes tumor.

**Table 1: Comparison of Fibroadenomas and Phyllodes Tumors.** Adapted from Méndez Ribas, 2010.

	Macroscopic	Microscopic
Simple Fibroadenoma	Pseudo-capsule Bright white clefts	Fibrous connective tissue Proliferation of variable ducts and acini
Juvenile Giant Fibroadenoma	Pseudo-capsule Pale brownish-grey clefts Foliaceous	Relaxed connective tissue Abundant proliferation ducts and acini
Benign Phyllodes	Well delimited Brownish-grey clefts and cavities Foliaceous aspect	Aberrant fibro-plastic connective tissue with mild atypia and scarce mitosis Dilated ducts
Malignant Phyllodes	Irregular contour	Connective tissue featuring

	Large brownish-grey clefts and cavities	atypia and mitosis Adjacent tissue infiltration Duct proliferation
--	---	--

Once biopsied and diagnosed, juvenile giant fibroadenomas are benign lesions that may reach up to 15 or 20cm in size (Carter et al., 2001). The treatment options vary, though general consensus until this point has been surgical excision with subsequent reconstruction of the remaining breast (Celik et al., 2015). Due to the potentially large size of the lesion (figure 5) and resulting asymmetry of the breasts, aesthetic reconstruction can be difficult to achieve to patient satisfaction (C. A. Park et al., 2006). Depending on the situation, conservative measures or subcutaneous mastectomy may also be appropriate, however not as commonly used. There have been reports of recurrence after complete excision of the lesion, though this chance drops to a negligible level after the patient reaches the age of 30 (Thuruthiyath et al., 2012). Due to the extent of tissue distortion large juvenile giant fibroadenomas cause there are limited options for treatment, despite the emergence of new techniques.



**Figure 5: Excised Juvenile Giant Fibroadenoma in Adolescent Female.** Image from (C. A. Park et al., 2006).

Although not as common in adolescents, lesions with indwelling calcifications or other complications are termed ‘complex fibroadenomas.’ Complex fibroadenomas may occur in fibroadenomas of all types, and are associated with increase in chance of malignancy development, higher levels in categorization per the BI-RADs classification, and it may alter the means of biopsy or treatment as certain techniques are limited in their ability to assess calcifications. In particular, giant juvenile fibroadenomas that are complex are subjected to surgical excision immediately due to their increased risk of malignancy development. There still exist little other options for excision of complex fibroadenomas, particularly for the giant type.

### **Calcifications**

Breast calcifications refer to calcium deposits within breast tissue that are not identified without radiographic imaging, in which they appear as white spots or flecks (Mayo Clinic, 2016). Calcifications typically arise after menopause, during which a lesion that has regressed will often leave behind a fibrous mass that may calcify (Hughes, 1991; Mayo Clinic, 2016). Calcifications are therefore uncommon in adolescents (G. M. Tse, Tan, Pang, Tang, & Cheung, 2008); however, there have been cases where fibroadenomas in adolescents contain calcifications. Calcifications may be formed in two different ways: secretory type and necrotic type. In the secretory type the calcium that are released by the surrounding breast tissue cells accumulates, which is most often seen in

benign lesions or low-grade malignancies (Gary M. Tse, Tan, Cheung, Chu, & Lam, 2008). The necrotic type is associated with rapidly proliferating tumor cells that are depleted of their vascular supply. The necrotic type is typically associated with malignancy (Gary M. Tse et al., 2008).

Calcifications are also classified based on size and shape. Macrocalcifications are benign, scattered over a large area and appear as smooth, round and dense objects on mammogram (Muttarak, Kongmebhol, & Sukhamwang, 2009; G. M. Tse et al., 2008). Calcifications typically seen within shrinking fibroadenomas in particular are coarse, or “popcorn” shaped calcifications that are totally benign (G. M. Tse et al., 2008). Malignant calcifications, or large necrotic types, appear in clusters or with linear morphologies that can be large and pleomorphic (Muttarak et al., 2009; G. M. Tse et al., 2008). Microcalcifications are also typically benign; however they have been associated with the start of cancer (Mayo Clinic, 2016). Studies have shown that the number of calcifications per area is also important in indicating malignancy, where calcifications that are clustered tightly together are more likely to be malignant (Egan, McSweeney, & Sewell, 1980; J. M. Park et al., 2000; Powell, McSweeney, & Wilson, 1983).

The traditional way to visualize calcifications is through mammogram as they are poorly characterized in US; however, with the development of high-frequency, high-resolution modern transducers calcifications may be recognized as echogenic foci within fibroadenomas or other masses in ultrasound (ACR, 2013). These modern transducers have the ability to depict intraductal calcifications that are superficial, as well as groups of microcalcifications when concentrated in fibroglandular tissue (ACR, 2013). These

transducers allow a way to characterize calcifications in adolescents using ultrasound; however, when adults are given an option mammogram is still the preferred method.

### **Complex vs. Non-Complex**

Approximately 50% of simple fibroadenomas may contain some other sort of proliferative change in the breast tissue such as adenosis, calcifications, duct epithelial hyperplasia, florid fibrocystic disease, and sclerosing adenosis (Guray & Sahin, 2006; Shabtai et al., 2001). These fibroadenoma-associated pathology complexes are classified as complex fibroadenomas. The average age of patients with complex fibroadenomas, around 47 years, is significantly higher than that of non-complex fibroadenomas, approximately 28.5 years (Ohashi et al., 2015). While very rare in adolescents, complex fibroadenomas have been linked to slightly higher risk for subsequent cancer (Carter et al., 2001). The literature for complex fibroadenomas is still limited, particularly in comparison to non-complex fibroadenomas, however the complex phenotype has been universally classified in the Breast Imaging-Reporting and Data System (BI-RADS) as an immediate category 4, or ‘suspicious,’ due to its link to malignancy. As with all other category 4 lesions, biopsy is *strongly* recommended. If the sample confirms the fibroadenoma to be complex, the most common next step will be surgical excision.



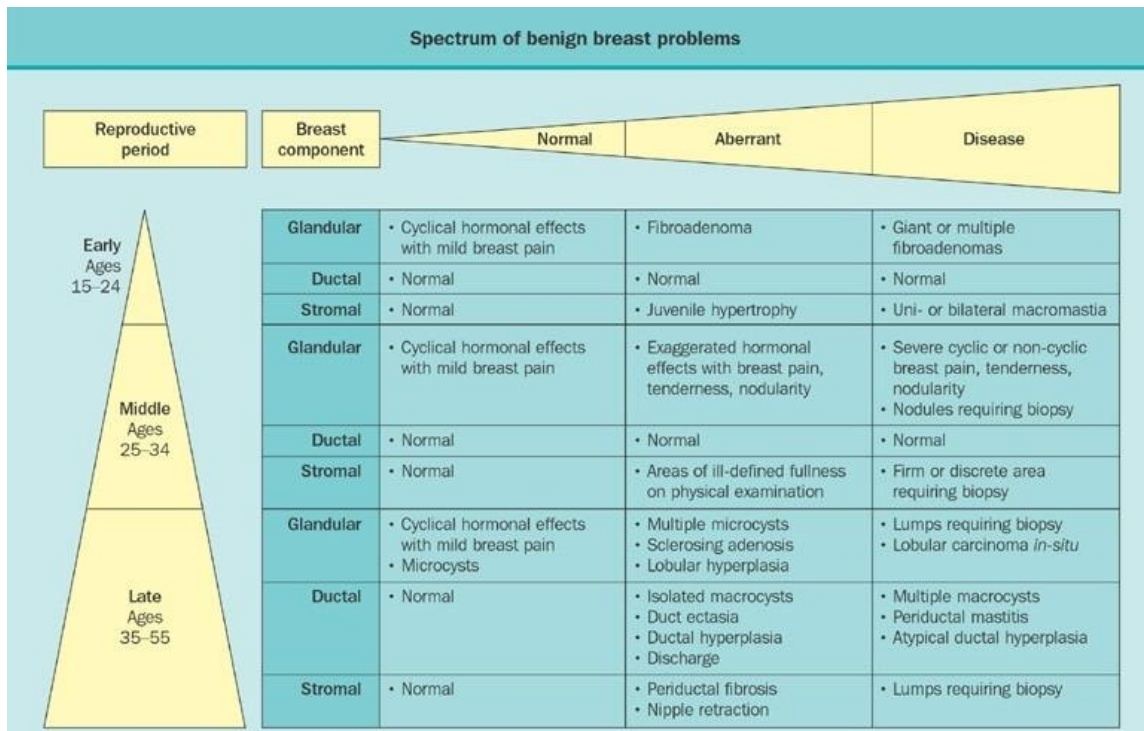
## **LESION CLASSIFICATION SYSTEMS**

In order to facilitate communications between providers and unify treatment options globally, classification systems were devised. The most commonly used is the Mammography BI-RADS system developed by the American College of Radiology (ACR). For adolescents there is a similar Ultrasound BI-RADS system that was recently developed, as mammography is not useful in adolescents due to their dense breast mass. These two classification systems are used after imaging to classify the extent of disease. The categories are used to determine which treatment option is best, as well as the chance of malignancy. The BI-RADS system runs from category 0 to category 6, with category 6 being the most malignant. In order better classify benign breast lesions in regards to their etiology and location, the Aberrations of Normal Development and Involution (ANDI) classification system was developed. The ANDI classification system was first published in 1982, though a finalized table including all of the known lesions was not published until 1991 (Hughes, 1991).

### **ANDI Classification**

The ANDI classification allows adjustments in therapeutic strategies between conservative and aggressive options (Duflos et al., 2012) depending on whether the lesion is classified as ‘benign,’ ‘aberrant,’ or ‘disease.’ One of the reasons this classification was developed was to incorporate fibroadenomas as an option, as the fibroadenoma presents features different than that of most benign tumors (Hughes, 1991). Simple fibroadenomas of small, non-palpable size are considered benign while palpable simple fibroadenomas,

or multiples of 3 or less, were instead considered an aberration of normal lobule development rather than a true neoplasm (Duflos et al., 2012; Hughes, 1991; Hughes et al., 1987). Multicentric, simple fibroadenomas of more than 5 or juvenile giant fibroadenomas were both placed on the ‘disease’ end of the spectrum and thus treated more aggressively (Duflos et al., 2012; Hughes, 1991). An example of the ANDI classification table is shown in figure 6. Reading from the left, there is a column with the 3 reproductive periods: early (adolescence), middle, and late. Next is a column containing the 3 main breast components: glandular, ductal, and stromal elements divided within each reproductive period. Throughout each breast component within its respective reproductive period are the separations between normal development, aberrant development and disease. Of interest is the glandular component in the early reproductive period containing the fibroadenoma.



**Figure 6: ANDI Classification of Benign Breast Lesions.** Figure from Hughes et al., 1987.

Excess cyclical hormonal stimuli to the glandular component of the breasts as seen in the menstrual cycle of the early reproductive period in females have been shown to be a cause for fibroadenoma development (Santen, 2000). The lobules grow to a larger size than normal, forming fibroadenoma that may change in size from slightly abnormal to large, palpable lesions (Santen, 2000).

### Mammography BI-RADS

Mammography is the most common form of imaging for breast lesions. As a result, the ACR developed the BI-RADS system in order to universally describe mammogram findings and results (ACS, n.d.). It ranges from category 0, which indicates

a palpable lesion as detected via breast examination but the imaging has not yet taken place or there are no prior exam results, to category 6 that indicates known breast cancer or malignancy. For women over 35 this is the preferred method as it is more detailed, precise and comprehensive.

### **Ultrasound BI-RADS**

Ultrasound BI-RADS was recently developed for adolescents and other groups that are unable to undergo mammography. The system follows the same categories and criteria as the mammogram BI-RADS system however it is more specialized to what is visualized in ultrasound versus what is seen in mammography. The patient would undergo an ultrasound procedure and depending on what was visualized, a category is assigned to that patient's lesion and noted in the chart for subsequent encounters. The categories are useful in determining the most appropriate path of management or treatment, though the final decision is ultimately up to the patient and their family members.

#### ***Category 0: Prior to Imaging***

This category is used prior to imaging or if additional imaging or prior examinations are required (ACS, n.d.). This category is almost never utilized as imaging is done almost immediately after the discovery of a possible palpable lesion.

### ***Category 1: Negative***

This category is reserved for when there are no lesions found during either routine ultrasound imaging for a different reason, or per patient request. There is no management or treatment options necessary for this category, instead routine follow-up should continue for developing changes.

### ***Category 2: Benign***

In this category a lesion was found, however there are no apparent malignant features and is therefore classified as benign. This includes diagnoses such as simple cysts, intra-mammary lymph nodes, breast implants, stable postsurgical changes and simple fibroadenomas that are noted to be stable on successive US studies for a period no less than 2 years (ACR, 2013). The fibroadenomas also need to be of small size and be non-complex.

### ***Category 3: Probably Benign***

This category is used for solid masses with circumscribed margins, oval shapes, and horizontal orientations that are most likely to be fibroadenomas. This is also used for isolated, nonpalpable complicated cysts that have a likelihood of malignancy in the less than 2% range, as well as clustered microcysts (ACR, 2013). Suggested management includes either biopsy or initial short-interval follow-up of approximately 6 months where the study will be repeated to observe for any changes (ACR, 2013).

Fibroadenomas that continue to be stable are re-classified as category 2 after the 2 year

mark. Biopsy is ideally avoided in favor of the more conservative approach; however in adolescents it may be requested by the family to confirm the diagnosis of the lesion.

***Category 4: Suspicious***

This category is used for lesions that show malignant properties such as those seen in complex fibroadenomas; however it is not necessarily indicative of cancer. There is, however, a chance for cancer of upwards to 94%, indicating a strong recommendation for biopsy, particularly in women older than 35 (ACR, 2013). Included in this category are sonographic findings of a solid mass without all the criteria for a fibroadenoma or any other benign lesions (ACR, 2013) such as irregular outlines or abnormally large size. Until a biopsy is done to confirm the diagnosis, a juvenile giant fibroadenoma will fall into this category.

***Category 5: Highly Suggestive of Malignancy***

This category is used when the lesion is almost certainly cancer, with a 95% chance (ACR, 2013). Masses with irregular, difficult to define boundaries and very dark centers in US are typically indicative of cancer. Patients with these types of masses are immediately sent for biopsy and appropriate actions are taken from there, including most likely surgical excision. It is quite rare for an adolescent to be in this category, as they are of low risk for cancer or other malignancies; however there have been cases where this has happened.

**Category 6: Known Malignancy**

This category is used for a lesion that has already been biopsied and confirmed to be cancer. It will remain a category 6 until it is surgically excised, or prior to the institution of therapy. As with category 5, it is rare for an adolescent to be in this stage.

**Table 2: Ultrasound BI-RADS Assessment Categories.** Created using information from Zonderland & Smithuis, 2013.

Category		Management	Likelihood of Cancer
0	Need additional imaging or prior examinations	Recall for additional imaging and/or await prior examinations	N/A
1	Negative	Routine Screening	Essentially 0%
2	Benign	Routine Screening for age, possible conservative management	Essentially 0%
3	Probably Benign	Short interval follow-up (6 months) or tissue diagnosis	More than 0% but less than 2%
4	Suspicious Category 4A: <i>Low suspicion</i> for malignancy Category 4B: <i>Moderate suspicion</i> for malignancy Category 4C: <i>High suspicion</i> for malignancy	Tissue diagnosis strongly recommended	More than 2% but less than 95% 4A: More than 2% but less than 10% 4B: More than 10% but less than 50% 4C: More than 50% but less than 95%
5	Highly suggestive of malignancy	Tissue diagnosis required	More than 95% likelihood of malignancy
6	Known biopsy-proven malignancy	Surgical excision when clinically appropriate	N/A (100%)

Table 2 above summarizes the ultrasound BI-RADS assessment categories. The mammography BI-RADS categories are nearly identical, with the difference being the criteria in which the decisions are made based on mammographic findings instead of sonographic findings. Note category 4 is split into 3 parts in the mammography BI-RADS: 4A, 4B, and 4C indicating low suspicion (2-10%), moderate suspicion (11-50%) and high suspicion (51-94%) in order. This is because of the large range of possible malignancy between 2% and 94%. With these subdivisions more targeted strategies and treatments may be employed. Juvenile giant fibroadenomas typically fall into the 4A category.



## **EVALUATIONS OF MONITORING OPTIONS**

Unless there are underlying comorbidities or symptoms that warrant imaging of the breasts, the first clue to the appearance of a fibroadenoma is a palpable mass that either the patient feels or the physician finds during routine breast examinations. Upon finding the mass, the previous recommendations called for what was called ‘The Triple Test,’ which included palpation, imaging and percutaneous biopsy (Santen, 2000). With the emergence of the conservative method, current recommendations, particularly for younger females, include palpation and ultrasound imaging to evaluate the characteristics of the lesion for benign findings. If it meets criteria to be classified as benign, or ‘probably benign’ in the category 3 of BI-RADS, standard practice at this time is to follow the lesion conservatively with annual or bi-annual ultrasound imaging (Graf et al., 2004). If after approximately 2-3 years, a stable fibroadenoma will be re-classified as a category 2 lesion in BI-RADS, or ‘benign.’

## **IMAGING**

Traditionally suspected fibroadenomas are evaluated using mammography as it is more detailed and provides a more specific clue into the nature of the mass. Due to the density of a young female’s breasts, it is often difficult to view the mass with sufficient accuracy. Thus, in order to combat this drawback, ultrasound imaging became the most used diagnostic tool for discovering fibroadenomas in adolescents. While not as accurate or specific as mammography, studies have shown that sonography is sufficient enough to be used alone when strict criteria are met to diagnose a lesion as benign. Figure 7

illustrates the differences between the two imaging methods in regards to visible characteristics used to describe a lesion.

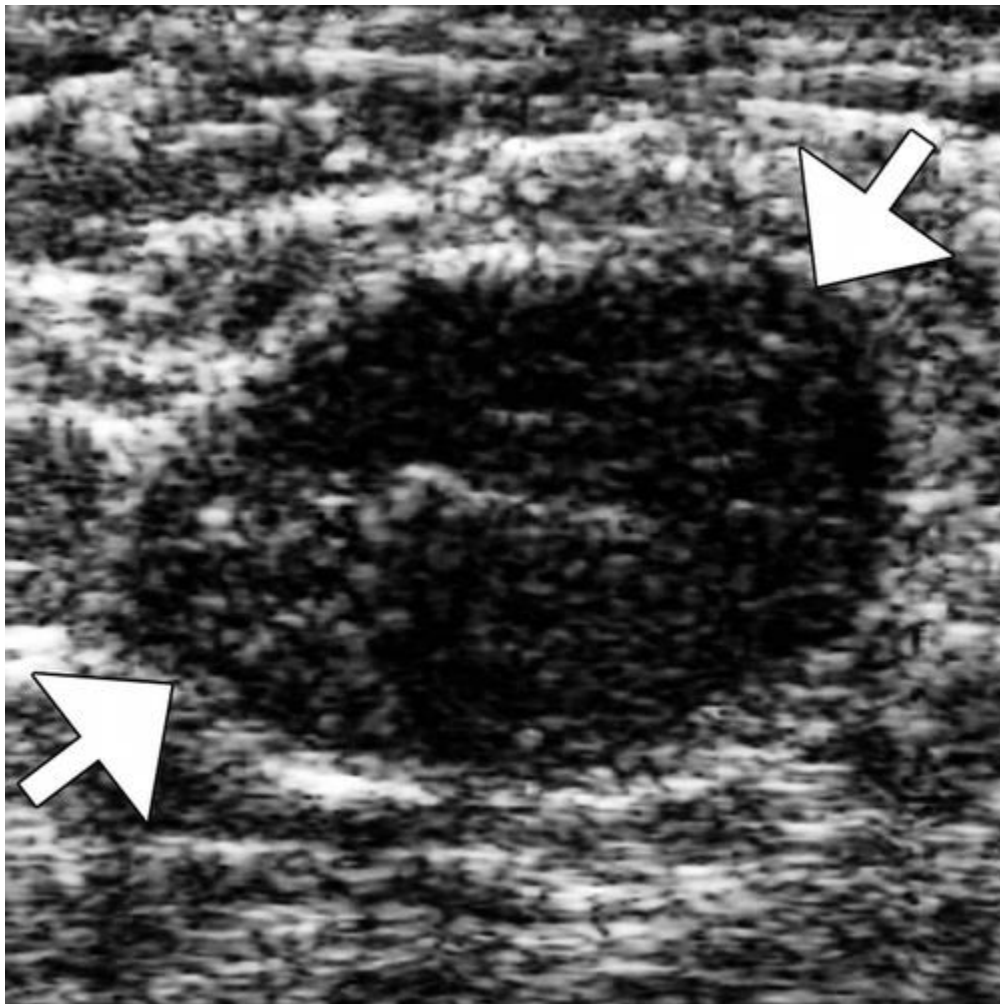
Mammography Lexicon			Ultrasound Lexicon			
Breast composition	A. entirely fatty B. scattered areas of fibroglandular density C. heterogeneously dense, which may obscure masses D. extremely dense, which lowers sensitivity		Breast composition a. homogeneous - fat b. homogeneous - fibroglandular c. heterogeneous			
	Mass	shape	oval - round - irregular	Mass	shape	oval - round - irregular
margin		circumscribed - obscured - microlobulated - indistinct - spiculated	margin		Circumscribed or Not-circumscribed: indistinct, angular, microlobulated, spiculated	
density		fat - low - equal - high	orientation		parallel - not parallel	
Asymmetry	asymmetry - global - focal - developing		echo pattern		anechoic - hyperechoic - complex cystic/solid hypoechoic - isoechoic - heterogeneous	
Architectural distortion	distorted parenchyma with no visible mass		posterior features		no features - enhancement - shadowing - combined pattern	
Calcifications	morphology	typically benign	suspicious		1. amorphous 2. coarse heterogeneous 3. fine pleomorphic 4. fine linear or fine linear branching	Calcifications
		distribution		diffuse - regional - grouped - linear - segmental	Associated features	architectural distortion - duct changes - skin thickening - skin retraction - edema - vascularity (absent, internal, rim) - elasticity
Associated features	skin retraction - nipple retraction - skin thickening - trabecular thickening - axillary adenopathy - architectural distortion - calcifications		Special cases <i>(cases with a unique diagnosis)</i>	simple cyst - clustered microcysts - complicated cyst - mass in or on skin - foreign body (including implants) - intramammary lymph node - AVM - Mondor disease - postsurgical fluid collection - fat necrosis		

**Figure 7: Imaging Characteristics of Lesions.** Table from Zonderland & Smithuis, 2013.

Note ultrasound's inability to accurately observe asymmetry, architectural distortion and calcifications when compared to mammogram [Figure 1].

## ***MAMMOGRAM***

In women older than 35 years old, mammography is the most widely used imaging technique. This is further supported by the fact that mammography alone is sufficient to demonstrate lesion stability without other intervention due to its validity established over many studies (Graf et al., 2004). Ultrasound is now able to directly diagnose lesions as well, however only for a small amount of lesions that follow strict criteria such as small size, distinct encapsulation characteristic of fibroadenomas and lack of calcification or other complex elements.



**Figure 8: Mammographic Image of a Breast Fibroadenoma.** Adapted from Graf et al., 2004.

Figure 8 shows an example image of a fibroadenoma that is clear enough to be sufficient evidence for diagnosis and conservative follow-up.

### ***ULTRASOUND***

Ultrasound, as opposed to mammography, does not use ionizing radiation and captures real-time, non-invasive images (ACR, n.d.). It is usually painless, can be completed in less than 30 minutes, is widely available, and is significantly cheaper than other method. US imaging is relatively easy to use for radiology techs and physicians, however it requires an expertise in breast US for accurate detection, as the images are captured in real-time and masses may be missed if not properly recognized (ACR, n.d.).

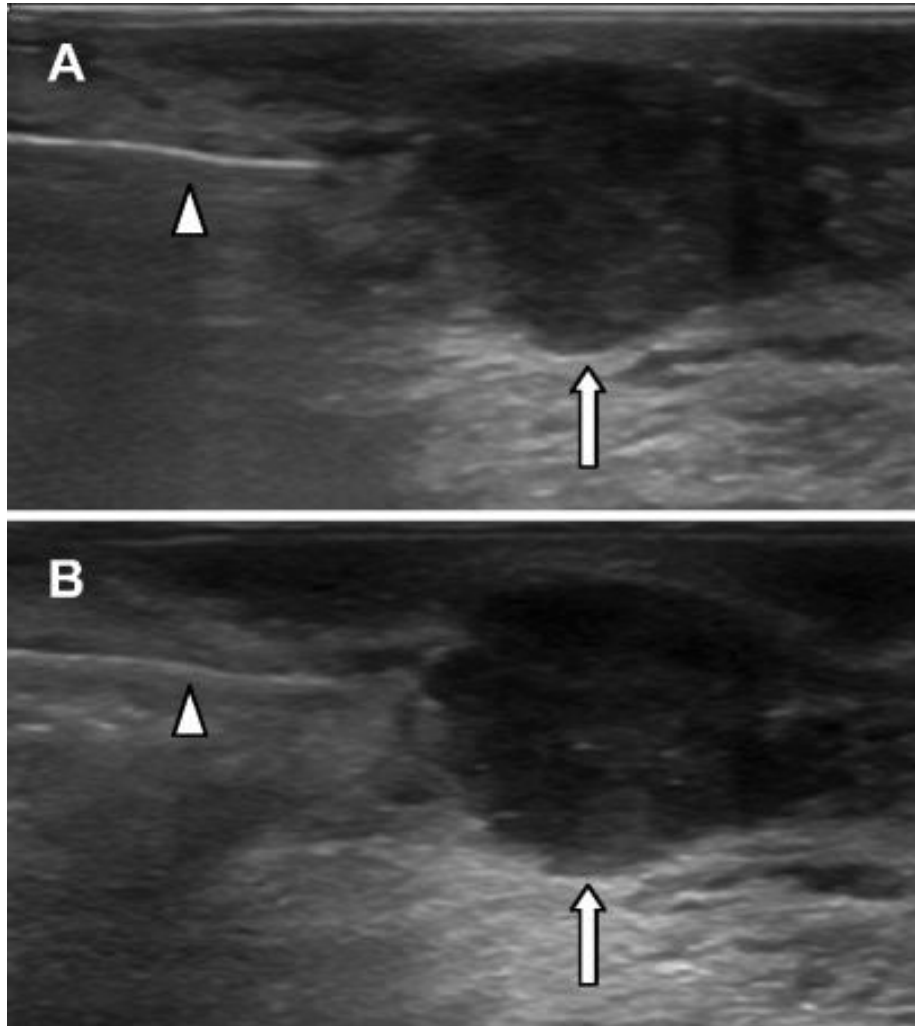
US imaging has been shown to be a confident diagnostic tool for both benign and malignant solid breast masses without additional intervention such as biopsy. Studies done by Stavros et al. (1995) and others have shown nearly a 99% accuracy rate in its predictive capabilities (Vade, Lafita, Ward, Lim-Dunham, & Bova, 2008); however, US remains limited in its ability to differentiate between fibroadenomas and phyllodes tumors, which are potentially malignant and typically category 4 or even category 5 lesions (Yilmaz, Sal, & Lebe, 2002). Ultrasound imaging also provides limited visibility of many cancers and calcifications, however in regards to adolescents this limitation is

not as significant as the incident rate for cancers or calcifications are very low in this age group.

While limited in its ability to tell solid masses apart, ultrasound excels in its ability to detect cystic masses and is often used along with the fine needle aspiration (FNA) biopsy technique (Yilmaz et al., 2002). The advantages it provides as a guidance technique over mammography, x-ray or MRI includes accessibility of all areas of the breast and axilla, real-time visualization of the needle, multi-directional sampling, lack of ionizing radiation, low cost and patient comfort (Helbich, Matzek, & Fuchsjäger, 2004). It is becoming more standard to use ultrasound-guidance during biopsy techniques, as well as minimally invasive treatments.

Traditionally for breast ultrasounds, B-mode sonography, also known as 2D mode, is used during procedures (Schueller, Schueller-Weidekamm, & Helbich, 2008). It is called 2D sonography because it transmits the signal in a single direction, giving a flat image. Studies have also shown that other ultrasound modes may be useful for specific purposes, such as Tissue Harmonic Imaging (THI) or Compound Imaging (CI). THI is designed to visualize the lesion against a fatty background but is not very useful in visualizing needles used in biopsy (Mesurole, Bining, El Khoury, Barhdadi, & Kao, 2006; Sehgal, Weinstein, Arger, & Conant, 2006). It increases the signal-to-noise ratio, causing the lesion to be more hypoechoic and thus darker in contrast to the surrounding breast tissue, thus improving lesion detectability (Cha et al., 2007; Helbich et al., 1999; Saleh et al., 2001). CI is also able to enhance visibility of the lesion, though against a glandular background as opposed to a fatty one. It is also more adept at visualizing the

needles used in biopsy when compared to THI (Mesurole et al., 2006; Sehgal et al., 2006). It works by taking multiple frames of different frequencies and angles and combining them into a single image to better visualize the lesion margins and internal architecture (Mesurole et al., 2006). Figure 9 shows an example of B-mode sonography versus THI. Note B-mode sonography reveals a clearer image of the biopsy needle, pointed out by the arrowhead. In contrast, THI shows a clearer image of the fibroadenoma, pointed out by the arrows, with sharper margins and contrast between the lesion and surrounding breast tissue.



**Figure 9: Comparison between B-mode Sonography and THI.** (A) B-mode sonography depicting better visualization of the biopsy needle. (B) THI depicting better visualization of the fibroadenoma. Figure adapted from Schueller et al., 2008.

If the lesion were within a glandular region of the breast, CI imaging would be used instead of THI.

## **BIOPSY**

With the modern push for conservative management in female adolescents, biopsy is not utilized as often as it was in the past. However, biopsy is often indicated when a lesion is categorized in BI-RADS as category 4 or category 5, resulting in a level of risk that is too high to simply passively monitor (Graf et al., 2004; C. A. Park et al., 2006). In young females the discovery of a category 4 or category 5 lesion is unusual and fairly rare, though such a discovery would almost certainly result in an automatic request for biopsy. Unless circumstance requires it as previously discussed, biopsies on young females are typically avoided as they may cause iatrogenic risks on the developing breasts, resulting in possible aesthetic deformity (Chung et al., 2009; Lee & Soltanian, 2015). Even the smallest of procedures may potentially cause damage, thus it is critical to weigh all the options prior to deciding whether to go ahead with further intervention or just observe (Lee & Soltanian, 2015). Should biopsy be deemed necessary, or at the request of the patient or her family, there are several techniques that can be utilized. There is the traditional open biopsy, which is quickly losing popularity particularly in this age group, FNA, and other emerging percutaneous techniques that are minimally invasive.

### ***OPEN BIOPSY***

Open biopsy, or surgical biopsy, of fibroadenomas has been reported to account for approximately 50% of total open surgical biopsies (Greenberg, Skornick, & Kaplan,



1998). Open biopsy is traditionally the most commonly used biopsy method for adolescents; however there have been large pushes towards alternatives as the biopsy creates an additional surgery that may ultimately damage developing breast tissue. Aside from direct requests from the patient or the family, open biopsy is typically reserved only for solid lesions that are very large, have no regression on follow-up, are suspicious for malignancy, show progressive growth in patients with a known history of primary malignant tumors, or for patients with a family history of cancer, especially that of the breast (Ezer et al., 2013; Jawahar et al., 2015). The procedure involves an incision made into the breast tissue from which either a small portion of the lesion is removed, also known as ‘incisional biopsy,’ or the entire lesion is removed, or ‘excisional biopsy’ (Johns Hopkins Medicine Health Library, n.d.). If the lesion is small, deep or otherwise difficult to locate, then a technique called ‘wire localization’ may be used. In this technique, a special wire is placed into the lesion during surgery to locate the lump under x-ray guidance (Johns Hopkins Medicine Health Library, n.d.). These types of lesions are typically difficult to locate on imaging devices, particularly if obscured by other masses or densities, thus warranting open biopsy rather than needle biopsies (“Breast Biopsy,” Choosing Wisely, 2014). The cost of the procedure itself can range from anywhere between \$750 - \$1,200 depending on the region, however it often includes an additional charge for anesthesia, bringing the total up to approximately \$2, 500 - \$3,500 (“Biopsy procedures of breast, insured,” FH Consumer Cost Lookup, 2016). While the procedure is often insured, it can still include a considerable out-of-pocket cost that many families may be unable to afford, particularly if there are multiple lesions or lesions in both

breasts. Open biopsy is the preferred method of biopsy for patients with juvenile giant fibroadenomas as other methods are currently not as efficient in sampling the large mass; juvenile giant fibroadenomas are also associated with other skin deforming effects, such as skin dimpling or nipple inversion, that make sampling difficult with other methods (C. A. Park et al., 2006).

Aside from the mentioned exceptions, surgical biopsy is often avoided if possible due to the cost, time spent and subsequent cosmetic damage the procedure may induce. During the biopsy the physician is required to cut into the breast to take out large pieces of suspicious tissue. This may lead to bleeding, wound infection, longer recovery times, scars or even distortion of the breast tissue (“Breast Biopsy,” Choosing Wisely, 2014). In young adolescents, unless paired together with lumpectomy or other surgical removals, open biopsies should be avoided.

### ***FINE NEEDLE ASPIRATION***

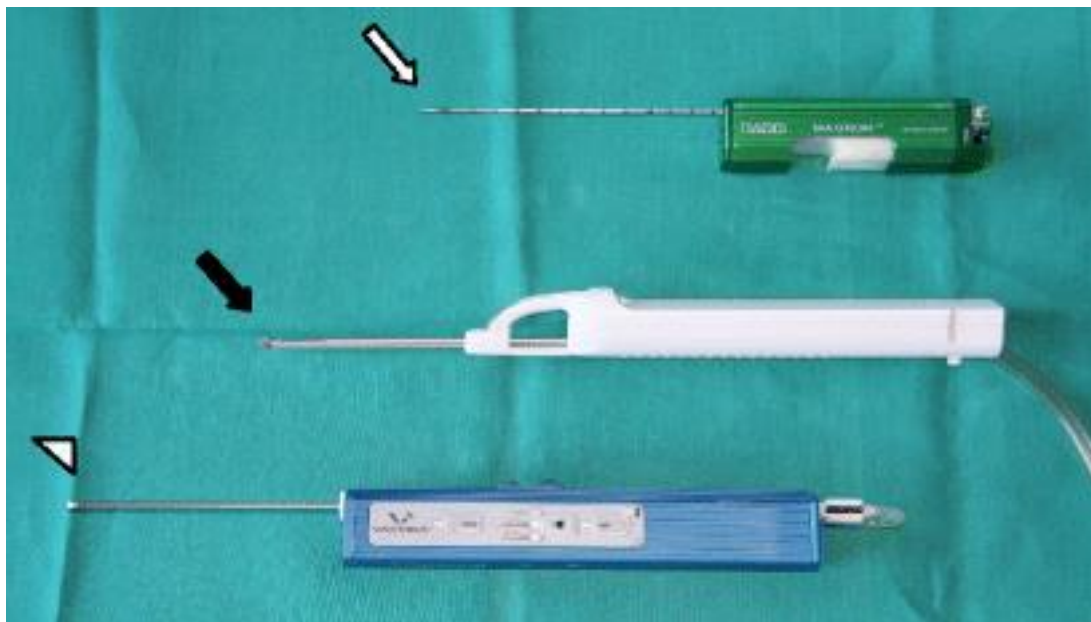
FNA is a type of percutaneous biopsy that involves placement of a very thin needle into the lesion or suspicious area in question to remove a small sample of the fluid and/or tissue in the area (Johns Hopkins Medicine Health Library, n.d.). It does not require an incision, has reduced morbidity, quicker procedure time and less side effects or complications in comparison to surgical/open biopsy (Lacambra et al., 2012). As its name implies this technique is particularly adept at aspirating fluid out of cysts or other fluid collections during the biopsy procedure (Helbich et al., 2004), an advantage that removes

an additional step that would have otherwise been taken in the treatment process. Upon the introduction of other percutaneous biopsy techniques, FNA is no longer considered the standard of care for benign breast lesions such as fibroadenomas; however it is often used for cysts. The reason for this includes the procedure's many flaws, including difficulty in differentiating between fibroadenomas and phyllodes tumors (Celik et al., 2015), particularly when complex fibroadenomas are involved (Ohashi et al., 2015). Atypical elements within complex fibroadenomas result in erroneous diagnoses of fibroadenoma lesions, having a higher chance of falling into an 'indeterminate' or 'suspicious for malignancy' categorization as compared to non-complex fibroadenomas (Ohashi et al., 2015). With the movement towards imaging detection and screening of early diseases or cancers there are more and more nonpalpable lesions being discovered in women; however, FNA is not as efficient as other percutaneous biopsy techniques in retrieving samples for diagnosis (Lacambra et al., 2012). While FNA is certainly still a viable technique, it has been overshadowed by advancements in the field (Helbich et al., 2004).

### ***PERCUTANEOUS BIOPSY***

Percutaneous biopsy is minimally invasive and designed to reduce the numbers of open biopsies for lesions such as fibroadenomas. Histologic testing of the samples obtained from biopsy offers sufficient evidence for diagnosis of benign breast lesions such as fibroadenomas, particularly when used in concordance with US or

mammography, and surgery may be avoided depending on the individual (Helbich et al., 2004). On the other hand, if surgery is ultimately required or requested there will only be one invasive procedure done as opposed to both the open biopsy and open excisional surgery done in the traditional route (“Breast Biopsy,” Choosing Wisely, 2014). It has also been shown to have better accuracy and handling when compared to FNA, further solidifying its role in the field of breast biopsy. Two of the most used techniques in particular are Long/Large Core Needle Biopsy (LCNB) and Vacuum-Assisted Core Biopsy (VACB).



**Figure 10: Percutaneous Biopsy Instruments.** White arrow: standard LCNB device. Black arrow: 8-gauge VAB device. Arrowhead: 11-gauge VAB device, rapidly becoming the preferred size for the biopsy procedure. Figure is adapted from Schueller et al., 2008.

Both of these techniques involve the use of a hand-held device containing a spring-loaded mechanism with an attached needle that has a small compartment within it to store a ‘core.’ The ‘core’ is essentially the sample of tissue obtained during the

procedure [see figure 10]. Using this method, the sample sizes are large enough for appropriate histological analysis of the lesion and surrounding tissue, resulting in higher diagnostic accuracy and sensitivity (Lacambra et al., 2012).

**Table 3: Comparison of Diagnostic Accuracy between LCNB and VAB.** PPV positive predictive value, NPV negative predictive value. Table adapted from Lacambra et al., 2012.

	LCNB	VACB
False Positive	1	0
False Negative	7	0
True Negative	118	75
True Positive	159	10
Total	285	85
PPV (%)	98	100
NPV (%)	94	100
Sensitivity (%)	96	100
Specificity (%)	99	100
Accuracy (%)	96	100

Percutaneous biopsy has two major drawbacks: underestimation of disease and history of false-negative results, particularly when complex fibroadenomas are evaluated

(Helbich et al., 2004). Underestimation of disease occurs when high-risk lesions or carcinoma are present in the breasts, however they are poorly characterized in the pathology of the sample retrieved from the biopsy and therefore a confident diagnosis may not be made (Helbich et al., 2004). Underestimation of disease can result in delays when diagnosing a more complex fibroadenoma as extensive analysis is used to rule out malignancy in suspicious lesions as the tissue histology appears less concerning. Underestimation may be caused due to the location from which the sample was obtained, meaning multiple samples are often required. The rates of false-negative and false-positive results in these two percutaneous methods were evaluated by Lacambra et al., (2012; Table 3). Their study involved comparing the diagnostic accuracies and sensitivity of LCNB and VACB, with special emphasis placed on false-negative results. Of note, VACB was shown to have higher diagnostic accuracy with little to no evidence of false-negative or false-positive results. This is most likely because VACB techniques involve multiple samples being retrieved at once, allowing a larger and more comprehensive view of the lesion in question in comparison to LCNB.

While fibroadenomas with complex elements or epithelial abnormalities typically require excision, many fibroadenomas that are diagnosed as benign by core biopsy are eligible for conservative follow-up due to the negligible incidence of malignancy regardless of the false-negative results (Sanders & Sara, 2015).

#### *LONG-CORE NEEDLE BIOPSY*

LCNB procedures involve removing small samples of breast tissue with the use of a hollow ‘large-core’ needle and spring-loaded mechanism (Lacambra et al., 2012). It may be done manually where the lesion is fixed with one hand, with stereotactic mammography where the breasts are compressed and held in place by a machine, or with US image guidance (Lacambra et al., 2012). The biopsy device contains a spring-loaded system with a single needle, meaning only one sample can be obtained each time the device is inserted (Lacambra et al., 2012). To have a sufficient amount of breast tissue for analysis, multiple samples are taken by the device that may result in bruising of the breast tissue, however the bruising typically resolves in a few days. No incision is necessary for the procedure, meaning there is no chance of the patient developing scars or marks on the surrounding breast tissue as a result of the biopsy (“Breast Biopsy,” Choosing Wisely, 2014). When compared to open biopsy, LCNB is faster, involves less patient discomfort, and has better cosmetic outcomes with no scarring in subsequent mammograms when the patient is older (“Breast Biopsy,” Choosing Wisely, 2014; Mainiero et al., 2002). It has also been shown to yield more tissue for better diagnostic accuracy and ancillary studies when compared to FNA, as well as allow assessment of stromal invasion from malignant lesions that would otherwise not be depicted (Lacambra et al., 2012). Depending on the region LCNB procedures may cost anywhere between \$500 to \$200 without insurance, approximately 56% less than open biopsy (“Biopsy procedures of breast, insured,” FH Consumer Cost Lookup, 2016; Liberman, 2000). This cost is even lower if US-guided LCNB is used as opposed to the stereotactic method, which involves obtaining x-ray imaging throughout the procedure for accuracy (Liberman, 2000). LCNB, whether using

US or stereotactic methods, is also a simple enough procedure where it can be done within a radiology or breast-imaging center, or in the doctor's office ("Breast Biopsy," Choosing Wisely, 2014).

As was previously mentioned, percutaneous biopsies in general have a small risk of false-negative results. With LCNB the risk has been determined to be approximately within 0-9% (Schueller et al., 2008). Reasons for these results have been shown to arise from multiple elements, including technical difficulties, which results in inaccurate tissue sampling (Schueller et al., 2008). These difficulties may arise from targeting errors due to poor lesion or needle visualization (particularly if no imaging is used in accompaniment with the procedure), lesion mobility upon compression, deeply located lesions, central lesions in a large breast, dense fibrotic tissue resistant to needle traversing, small sized lesions under 5mm, or poor lesion visibility due to small pools of blood formation after the needle punctures (Schueller et al., 2008). Another difficulty to note with the adolescent population in particular is movement or noncompliance with the procedure (Schueller et al., 2008) due to fear, lack of trust with the provider, or other situations that may make the patient uncomfortable or irrational. Younger pediatric patients in particular may be negatively impacted by the procedure and undergo psychological or emotional distress (Sosin et al., 2015). It is important to explain the procedure at length with the patient and their guardians to ensure an understanding before undergoing biopsy, as well as involve the guardian throughout the procedure for emotional support. If required, and available, procedural sedation is also recommended for cases such as these. LCNB, similar to FNA, also has difficulties in obtaining calcification samples as they are almost



always performed in solid masses. This may lead to underestimation of disease and holds a potential for false-negative results (Schueller et al., 2008).

LCNB procedures may be complimented by US or stereotactic maneuvers, allowing for more accurate and specific retrieval of samples. In particular, 3D US-guided LCNB has been shown to allow a better comprehension of topography, which in turn reduces the number of false-negative results (Lell, Wenkel, Aichinger, Schulz-Wendtland, & Bautz, 2004; Surry et al., 2002; Weismann, Forstner, Prokop, & Rettenbacher, 2000). 3D US-guided LCNB is accomplished with a multi-planar transducer that allows for precise post-firing positioning, meaning the number of samples that are needed for a reliable diagnosis may be reduced (Lell et al., 2004; Surry et al., 2002; Weismann et al., 2000). With stereotactic maneuvering the patient lies prone on a special table that has a hole near the middle for the breast to extend through, which is then compressed against the image acquisition device. A probe is inserted between the breast and the x-ray tube that will take still-image captures throughout the procedure to ensure accuracy (Wunderbaldinger, Wolf, Turetschek, & Helbich, 2002). While these tables are fairly expensive, they allow for more working room, decreased likelihood of patient motion and create a barrier between the patient and the procedure, often alleviating some of the stress involved.

#### *VACUUM-ASSISTED CORE BIOPSY*

VACB, also referred to as the Mammotome breast biopsy system or ATEC (Automated Tissue Excision and Collection), is one of the newest procedures to emerge

onto the breast biopsy field (Johns Hopkins Medicine Health Library, n.d.). While the initial insertion of the needle is the same procedure as LCNB, VACB differs in that the probe contains a vacuum that draws tissue in from a side hole. After the sample is obtained, instead of retreating to prepare for the next insertion, a rotating blade advances over the tissue and cuts a core from the breast and withdraws the specimen, making room for another. Thanks to this method the device only needs to be inserted once to obtain multiple samples, though there is a slightly increased risk of a developing hematoma post-procedure when compared to LCNB (Schueller et al., 2008). However, this risk has been shown to be less than 1% (Gwinnett Medical Center Imaging, n.d.-c) and there is little to no architectural distortion or other characteristic changes to the breast that may otherwise be present in open biopsy (Huber, Wagner, Medl, & Czembirek, 2003). The cost to purchase an 11-gauge VACB device (which is the most commonly used size) is approximately 10 times greater than purchasing a LCNB device, though the procedure itself is still less expensive than surgical biopsy and approximately 71% faster, according to some studies (Alonso-Bartolomé et al., 2004). VACB shares with LCNB the difficulties with adolescents during the procedure, and has been reported to be more successful with adults for this reason.

In a study done by Lacambra et al. (2012), it was shown that in VACB the diagnostic accuracy is independent of the number of cores sampled, however in LCNB the accuracy correlates positively with the number of cores sampled. This discrepancy between the number of samples required can be due to the fact that VACB allows for larger samples with more accurate tissue acquisition, as the probe does not need to be

removed and reinserted (Ouyang et al., 2015; Schueller et al., 2008). The larger samples allow for a reduction in underestimation of disease or false-negative rates, which is as low as between 0-2.6% for VACB (Schueller et al., 2008). It is also more sensitive in detecting any underlying malignancy in non-palpable breast lesions upon analyzing the sample acquired (Lacambra et al., 2012). The larger samples sizes also point to a possibility of completely removing the benign lesion during the procedure when under local anesthesia, removing the need for surgery altogether (Fine et al., 2003). This notion is also the reason why VACB is more capable of detecting calcifications in both palpable and nonpalpable lesions, further lowering the rates of underestimation and increasing the diagnostic accuracy (Choo et al., 2008; Li, Wang, Su, Liu, & Tang, 2010; Penco et al., 2010; Su et al., 2010).

As with LCNB, there are multiple imaging techniques that may be used alongside VACB, including US, stereotactic maneuvering, and Magnetic Resonance Imaging (MRI). Of these US-guided VACB is the most commonly used technique, especially with adolescents, however there may be situations that warrant stereotactic maneuvering or MRI as well. The US-guided method is preferred as it is faster, less expensive, avoids ionizing radiation and allows samples to be retrieved from otherwise hard-to-reach areas such as the axillary region. US imaging is also done in real-time, meaning the radiologist may follow the motion of the biopsy needle as it moves through the breast tissue (Gwinnett Medical Center Imaging, n.d.-c). MRI-assisted VACB is typically performed when the lesion, or abnormal area, is non-palpable and not able to be seen on mammogram or ultrasound. It uses a high-powered magnet to guide the probe to the site

of the abnormal growth. The procedure is generally not painful and has results that are as accurate as when the tissue is removed surgically. It may be performed in an outpatient imaging center (Gwinnett Medical Center Imaging, n.d.-a). Stereotactic maneuvering in VACB is typically used when imaging shows a breast abnormality such as suspicious masses, microcalcifications, distortion in the structure of the breast tissue, or a new area/mass of calcium deposits present at previous surgery sites. The method is the same for that used in LCNB (Gwinnett Medical Center Imaging, n.d.-b).

The procedure is rarely painful due to local anesthesia, though it does carry a risk of infection or puncturing of the chest wall if the lesion is located very deep in the tissue, though this is very rare. Recovery time is brief and any post-procedure pain is controlled with non-prescription pain medication (Gwinnett Medical Center Imaging, n.d.-c).

### **OTHER TECHNIQUES IN DEVELOPMENT**

To this day other techniques are constantly being studied, including the most recent to be published called ‘ductal lavage’ from “Breast Biopsy” in the Johns Hopkins Medicine Health Library. The technique is still under investigation, however it is directed towards women who show no symptoms but have a high risk for breast cancer. It includes a small catheter being inserted through the nipple into the milk duct of the breast, where saline is gently flushed through. It is then withdrawn back through the catheter along with a collection of ductal cells in the fluid that are subsequently examined for cancer, precancerous changes or benign breast lesions such as fibroadenomas.

## **CONSERVATIVE MANAGEMENT**

Conservative management is a method reserved for benign fibroadenomas that are asymptomatic, not of significant size or rapidly enlarging, do not cause cosmetic distortion, lack complexity or have any other risk factors that may indicate malignancy in the near future (Lee & Soltanian, 2015). Conservative management involves annual or bi-annual follow-ups with a provider with accompanying sonography and will only include surgery or other intervention if there is a significant change in the lesion, or if the family requests it (“Treatment Options for Fibroadenoma,” Breast Health Options, n.d.). Even upon request, however, it has been recommended to observe the lesions for at least 3-4 months prior as there is a chance it may regress on its own (Lee & Soltanian, 2015). If the lesion is less than 3cm in size and does not expand in volume greater than 16% from the initial size, biopsy will not be necessary (Jawahar et al., 2015). Studies have shown that short-term follow up of every 6 months or 12 months is less expensive than a one-time procedure of needle biopsy by a factor of 8 (Helbich et al., 2004). This management method is particularly effective for young females with multiple fibroadenomas, particularly if they are of small size or even regress slightly. Removing all of the fibroadenomas in such females might entail the removal of surrounding, otherwise healthy breast tissue and may lead to scarring, disfiguration of the breast and other emotional trauma (ACS, 2015). Conservatively observing the masses with bi-annual US imaging is sufficient in most cases with the hope that the lesions regress in size on their own, or remain stable.

The conservative therapy method hinges on compliance with follow ups and sonography appointments to document stability (Grady, Gorsuch, & Wilburn-Bailey, 2008), however a large number of women fail to do so due to financial or time restraints (Cant, Madden, Coleman, & Dent, 1995; Kaufman et al., 2002). Another proportion of women undergo surgical excision of their lesions or other interventional methods despite the demonstrated safety, either due to anxiety and discomfort or because the mass fails to regress or progressively enlarges (Cant et al., 1995; Dent & Cant, 1989; Dixon, Dobie, Lamb, Walsh, & Chetty, 1996; Greenberg et al., 1998b). With adolescents, conservative management may induce some anxiety, as the fibroadenoma will remain untreated, however it is important to effectively communicate the risks and benefits of treatment options, provide consistent reassurance that malignancy is rare in this population, and emphasize the importance of regular follow-up and imaging (Cerrato & Labow, 2013; Kaufman et al., 2002). However, despite multiple attempts of reassurance, discovery of a breast lump in an adolescent female will undoubtedly incite anxiety and concern for both the patient and the family (Cerrato & Labow, 2013). Teaching self-breast examinations for monitoring the size of the lesion may be ineffective, and may even backfire and induce obsessive behavior (Méndez Ribas, 2010). A reason for this is due to the average psychological state of a female adolescent; mammae are the most obvious secondary sex characteristics for these females, and it identifies them with their feminine role, socially positions them as women and may make them desirable to the opposite sex, something that is especially important in this age due to the excess of hormones in both sexes (Méndez Ribas, 2010). Slight alterations or deviations from what is considered ‘normal’

cause a great deal of emotional and psychological stress, and often warrant requests for immediate fixes for the problem. This inhibits the use of the conservative method, as it will only cause further anxiety. Therefore during the decision making process for steps moving forward, patients or families that show continued signs of anxiety, regardless of the less than 1% chance of malignancy or risk of compromising breast development, should be offered the option for either excisional surgery or any other interventional method (Lee & Soltanian, 2015).

### ***PALPABLE VS NON-PALPABLE LESIONS***

One factor that may influence the decision to enter the conservative method is whether or not the mass in question is palpable or not. While it may not seem particularly important, follow up of a palpable mass with benign morphology may be more risky than follow up of a nonpalpable lesion (Graf et al., 2004). If a mass is revealed to be malignant with biopsy and it is already at a palpable size, the risk for metastasis and further complications are significantly higher (Tabár, Duffy, Vitak, Chen, & Prevost, 1999). A minimum of two years of follow up that have shown benign morphology and stable size of a nonpalpable mass is an accepted indicator of benignity (Graf et al., 2004). The amount of time required for palpable masses is longer due to the risks they carry. This is why it is essential for the patient to speak with his or her provider about the risks and chance of malignancy should they have a palpable mass to ease any anxieties that may appear (Graf et al., 2004).

Data presented by Graf et al. (2004) has shown that cancer that has progressed to a palpable size but is still showing benign morphology is quite rare. Women with palpable abnormalities but negative results at both imaging (BI-RADS category 1) are at very low risk for cancer but they should still be followed up at short-term intervals. Furthermore, results of Graf et al.'s study indicate palpable, circumscribed, non-calcified, solid breast masses that are placed in BI-RADS 3 has the same probability of cancer as nonpalpable lesions in the same category, alleviating the urgency for biopsy and asserting probable benignity (Graf et al., 2004).



## EVALUATION OF TREATMENT OPTIONS

Upon completion of imaging and diagnosis, as well as biopsy if warranted, the patient faces two options: the conservative method, or further intervention. While there is a modern push towards the conservative method with adolescents, intervention is recommended for fibroadenomas that are complex, greater than 5cm, rapidly increasing in size or causing considerable pain. Moreover, the presence of a high risk genetic mutation or syndrome, cosmetic deformity of the breast or the existence of other risks towards normal development may suggest a treatment other than the conservative method (Jayasinghe & Simmons, 2009). These are all situations in which the conservative method may not be appropriate or will cause the patient, or family members, anxiety due to its associated risk that cannot be otherwise reassuring. Traditionally, when further intervention is recommended, the recommended method was open surgical excision to completely remove the fibroadenoma and some surrounding breast tissue. Similar to the situation with breast biopsy, there has now been an emergence of minimally invasive techniques that show great promise for safe, effective and cosmetic treatment of fibroadenomas (Lakoma & Kim, 2014). These techniques are targeted towards older patients with smaller fibroadenomas, typically less than 3-4cm (Matz et al., 2013); however they may be viable for adolescents as well. This includes endoscopic surgery, thermal and cryoablation, and the vacuum-assisted biopsy technique for removal of entire lesions. During the initial consultation between the patient and physician, discussions regarding which treatment option best suits the patient's particular case of fibroadenoma,

as well as what they are most comfortable with doing, are done in order to get a clearer picture of the path ahead.

**Table 4: Comparison of Treatment Methods.** Adapted by Nurko et al., 2005.

Technique	Open Surgical Excision	Vacuum-assisted excision	Cryoablation	Conservative Method
Efficacy*	Recurrence is 'infrequent'	98% at 6 months	54% at 6 months; 65% at 12 months	38%
Time to achieve effect	Immediate	Immediate	6-12 months	60 months**
Patient Satisfaction	Variable	92% at 6 months	91% at 6 months; 88% at 12 months	Variable
Requires prior biopsy	No	No	Yes	Recommended
Typical location	Outpatient Center	Office	Office	Office
Approximate cost	\$2,500 - \$6,500	Approximately \$1,000	\$1,500 - \$3,400	Minimal beyond initial biopsy, however it may increase over time with bi-annual physician visits and imaging

\* Defined as the percentage of time a palpable lesion is converted to a nonpalpable lesion.

\*\* Not all fibroadenomas regress on its own with time, this is reflected in the large time period.

Table 4 contains a simplified look into the four most commonly used treatment methods: open surgical excision, vacuum-assisted biopsy/excision, cryoablation and the conservative method.

## **OPEN SURGERY**

Open surgical excision has been the most commonly used treatment method for fibroadenomas for a long time, particularly for adolescents. It includes the traditional lumpectomy, mastectomy for more extreme cases and the modern, less invasive method of endoscopic surgery.

### ***LUMPECTOMY***

Lumpectomy, also known as partial mastectomy, is the most commonly used procedure for adolescents as it removes the lesion completely with a negligible rate of recurrence (Greenberg et al., 1998b). Once removed, the patient and her family will have peace of mind as the lesion will be removed and no longer a cause of concern despite its low chance of malignancy (Matz et al., 2013). The technique is recommended above all else for lesions that are particularly large, such as juvenile giant fibroadenomas, or have associated skin ulceration, musculoskeletal effects or significant psychological trauma in young females (C. A. Park et al., 2006). It may also be offered if the lesion is fixed to overlying skin or the nipple areolar complex, associated with axillary or supraclavicular lymphadenopathy (LAD) or if the lesion is especially tender (Divasta et al., 2012). The surgery removes the lesion as well as a small ring of surrounding normal breast tissue, however the goal is to avoid causing iatrogenic deformity to the breast whenever possible (Lee & Soltanian, 2015). When the lesion is smaller than 4cm the optimal incision site is circumareolar or in the inframammary crease, as these spots are the least visible for scar

formation and the most aesthetically pleasing (Cerrato & Labow, 2013; Méndez Ribas, 2010). The post-operation check-up is approximately 4-8 weeks after the surgery in order to check the incision site for any damage, scarring or underlying infection (Cerrato & Labow, 2013). After this the patient may be checked bi-annually to re-assess for any recurrence or lesion formation in another spot (Cerrato & Labow, 2013). Once the breast tissue has stabilized over 2 years there may only be an annual screening if the patient so chooses.

Open surgical excision is one of the most expensive procedures, coming at around an average of \$2,500 – \$6,500 depending on region and number of lesions being removed. The surgery itself may only cost as little as \$1,000-\$2,500 however it requires the use of general anesthesia or procedural sedation, increasing the total cost a significant amount (“Lumpectomy, insured,” FH Consumer Cost Lookup, 2016). If the patient has multiple fibroadenomas on the bilateral breasts being removed the cost may also increase, at times even doubling, due to the increased procedure time and labor involved.

As breast fibroadenomas are almost always completely benign, the main goal of treatment is cosmesis and avoidance of iatrogenic injury as it may hinder breast development or cause breast asymmetry (Lee & Soltanian, 2015). Open surgical excision, while effective in removing the lesion, has an unfortunate side effect of causing visible scars that may result in contour deformities (Grady et al., 2008). It may also result in loss of breast volume, nipple areolar distortion or displacement or other changes in the shape of the breast depending on the size of the fibroadenoma being removed (Lakoma & Kim, 2014; “Treatment Options for Fibroadenoma,” Breast Health Options n.d.). These are all

especially problematic for females with multiple breast fibroadenomas, particularly if they are bilateral, as they may be facing multiple surgeries and scars if the lesions continue to expand (Grady et al., 2008; Kaufman et al., 2002). Those that undergo one surgery are often hesitant to do another, for fear of more scars or increased damage to their breasts (Kaufman et al., 2002). Ultimately, for adolescent females with developing breasts the risks often outweigh the benefits of surgery if there are no other complications that necessitate the immediate removal of the lesion (Cerrato & Labow, 2013).

#### *SPECIFICS TO JUVENILE GIANT FIBROADENOMA*

While the procedure is typically not recommended for most benign fibroadenomas, adolescents with juvenile giant fibroadenomas have few other options when it comes to treatments. With larger lesions like these, treatments that also remove surrounding breast tissue may be unavoidable and necessary (Grady et al., 2008), leaving open surgical excision the treatment of choice for giant fibroadenomas (Lee & Soltanian, 2015). As these lesions exhibit rapid growth it is crucial to remove them as soon as possible to avoid any physical or psychosocial damage. For giant fibroadenomas the goal of open surgical excision is to preserve the breast parenchyma and nipple areolar complex as much as possible in order to achieve superior aesthetic results (Sosin et al., 2015). In order to combat poor cosmesis there are three commonly used approaches to surgery, as well as the option for reconstruction after removal. The periareolar approach is simple and leaves the least visible scar as it blends in with the tissue of the areola;

however it is associated with loss of sensation of the nipple (C. A. Park et al., 2006). The inframammary approach is the most commonly used as it provides good exposure for removal and the scar is less visible in the crease, however it limits the correction of additional deformities (C. A. Park et al., 2006). The inverted 'T' incision, or 'anchor,' provides excellent exposure for removal of mastopexy, or breast lift, if necessary (C. A. Park et al., 2006). It involves the areola, inframammary crease as well as a line straight down in between them, leading to the most noticeable scar.

As juvenile giant fibroadenomas more often than not result in significant breast volume loss and deformity, a key element in excision is also reconstruction of the breast. There is current debate on whether to reconstruct the breast at the same time as the lumpectomy or to do it after a period of time. Many surgeons recommend waiting up to a year after the lumpectomy for the ptotic breast skin envelope to retract before doing any further surgery (Chepla et al., 2011). Once the skin has retracted, it will be easier to restore the breast shape and remove the need for further reduction or augmentation (Chepla et al., 2011). However, if the skin envelope is distorted significantly by the size of the giant fibroadenoma, skin retraction is unlikely and it may cause significant distress to the patient (Lee & Soltanian, 2015). In order to improve patient satisfaction and avoid poor cosmesis, reshaping techniques such as mastopexy and reduction were employed at the same time as the initial excision of the fibroadenoma (Lee & Soltanian, 2015). A study by Chepla et al., (2011) has shown that this immediate technique results in a superior outcome with stable long-term results. It also minimizes subsequent surgeries and reduces the psychosocial comorbidity that is associated with the waiting period due

to the postoperative appearance of the breast. However if something goes wrong during the reconstruction, either due to technique or unwanted skin retraction post-procedure, the backlash will be two-fold as it may include a compromised aesthetic result or breast asymmetry, resulting in further surgery and the loss of the benefit to this approach (Sosin et al., 2015).

### ***MASTECTOMY***

Mastectomy, or total removal of the breast, is an extreme measure against a breast fibroadenoma that is commonly reserved only for unusual or recurrent giant fibroadenomas that cause significant distress (Park et al., 2006). While reconstruction will more than likely follow the procedure, it is a daunting surgery that is not typically recommended for adolescents for the anxiety it may cause. If it must be done, immediate reconstruction is frequently recommended in order to limit the number of procedures and psychosocial consequences of the breast deformity (Park et al., 2006).

### ***ENDOSCOPIC SURGERY***

Endoscopic surgery is a variation of open surgery, as it utilizes 3 small incisions in the mid axillary line as opposed to a large incision in the center of the breast (Lee & Soltanian, 2015). The fibroadenoma is dissected from the surrounding tissue through an endocatch bag that is inserted into the breast, where lesions smaller than 3cm is pulled directly through the larger incision into the bag and lesions larger than 3cm are cut within

the bag removed piecemeal (Lakoma & Kim, 2014). Postoperative complications include subcutaneous emphysema to the neck or a small skin burn; however, the procedure has been shown to yield excellent cosmetic results, approximately 89.5%, with small scars that are not on the breast itself and easily concealed by the arm (Lakoma & Kim, 2014). Juvenile giant fibroadenomas are also able to be removed using the endoscopic technique, though it requires a periareolar incision instead of the 3 small incisions in the mid-axillary line (Lakoma & Kim, 2014).

### **MINIMALLY INVASIVE ALTERNATIVES**

Minimally invasive alternatives were developed in order to combat the flaws of open surgical excision. The goal of minimally invasive alternatives is to provide treatment options that are effective, fast, and have the best cosmesis possible in order to ensure psychosocial stability after the procedure. While many of the current techniques are targeted towards adult females, typically older than 35, they may also be used on adolescents. As these techniques generally do not require procedural sedation, they may cause stress on the adolescent and trigger anxiety that will be counterproductive. Generally, explaining the procedure in the initial consultation with the adolescents and their families give a good indication on whether or not the minimally invasive alternatives are appropriate to use.



## ***VACUUM-ASSISTED EXCISION***

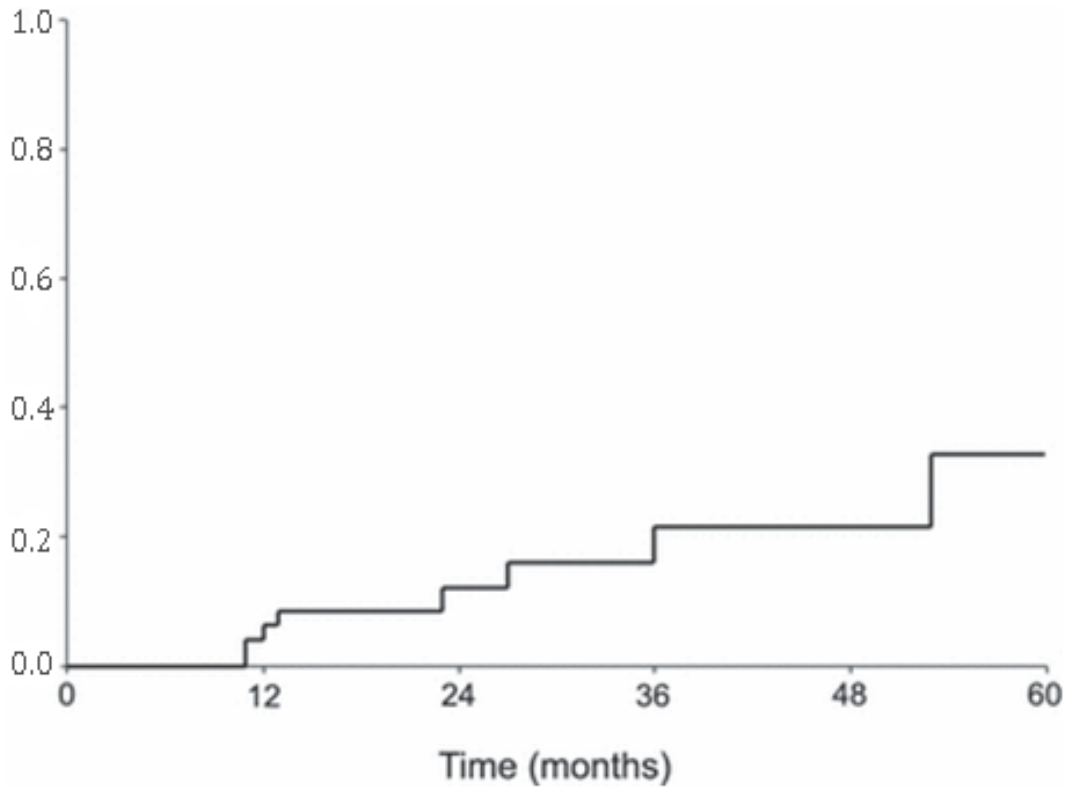
Vacuum-assisted excision (VAE) is the same procedure as vacuum-assisted core biopsy, however in this case the goal is not to retrieve tissue samples but to remove the lesion in its entirety. Its advantages over VACB include reduction of sampling error, decreased likelihood of histological underestimation or imaging-histological discordance, and decreased re-biopsy rate (H.-L. Park & Kim, 2011). It is minimally invasive and uses the assistance of imaging, meaning it is able to remove all image-based evidence of a lesion up to 3cm in size (Fine et al., 2002; Lee & Soltanian, 2015; Ouyang et al., 2015). Lesions less than 2cm in size have been shown to be associated with complete removal and negligible chance of recurrence in various studies (Lee & Soltanian, 2015). For women that are uncomfortable with or deny conservative management, VAE is an effective alternative that leaves no scars and requires little to no follow-up after the procedure (Grady et al., 2008). For benign breast lesions like fibroadenomas it has the potential to replace open surgical excision, especially for older females (Grady et al., 2008). Studies with 6-month follow ups revealed VAE is associated with high patient satisfaction and reduced levels of anxiety when compared to open surgical excision (Fine et al., 2003). The only known side effects of the procedure are the same as VACB- a small ecchymosis, approximately 0-13% chance for hematoma formation and 40% chance for mild pain that may be treated with over the counter acetaminophen (Grady et al., 2008).

VAE's ability to completely remove lesions and its chance for recurrence has been a topic of controversy for many years. Lesion remnants have been found post-

procedure in the surgical excision site in some studies (Reiner et al., 2009), leading surgeons to believe that it is not a viable procedure for patients with a malignant lesion or breast cancer (Lakoma & Kim, 2014); however, residual, nonpalpable masses are often not a concern for benign breast fibroadenomas. It has been suggested that VAE not used as a treatment measure on its own to combat this risk, even in the case of complete removal of microcalcifications (Penco et al., 2010). There are several possibilities for residual masses, including the following: local anesthesia or hematoma masked the ability of US to image the entire lesion at the time of the procedure or the residual mass is due to post-procedural scarring or fibrosis (Fine et al., 2003). It was also initially thought that the initial mass was not completely removed and resulted in the residual mass; however recent studies have shown that it may in fact be due to an additional mass that was initially too small to be detected using imaging during the procedure that has grown and caused a new lesion (Ouyang et al., 2015). This is backed by further evidence with malignant lesions, showing that often the recurred lesion has no evidence of residual disease (Grady et al., 2008 and Ouyang et al., 2015).

The relapse rate for patients with any benign breast disease in a study using 1,578 participants has been reported to be approximately 4% subsequent to VAE treatment (Ouyang et al., 2015). The overall recurrence rate has been reported to be approximately 33% after 60 months for fibroadenomas specifically (Grady et al., 2008). It has been shown that fibroadenomas that were initially less than 1.5 – 2cm in diameter were successfully excised with little to no chance for recurrence after a period of up to 2 years (Grady et al., 2008; Sperber et al., 2003). Most, if not all recurrences were shown to be

with fibroadenomas that were originally more than 2 cm in diameter, suggesting that larger lesions require supplementary treatment (Grady et al., 2008).



**Figure 11: Percentage of Fibroadenoma Recurrence using US-Guided VAE.** Figure taken from Grady et al., 2008. The y-axis depicts the percentage of recurrence in decimals.

Figure 11 shows the results of a study done by Grady et al., highlighting the percentage of recurrence of breast fibroadenomas after 60 months. As the initial sightings of recurrent lesions are shown to be around 10-11 months after the procedure it has been hypothesized that there may be an additional lesion that was too small to initially be seen using ultrasound. This lesion most likely grew in size and caused a relapse in these patients. Despite the risk for recurrence, VAE is still associated with high patient satisfaction.

## ***ABLATION***

Ablation has been a valid technique for tumors in other locations of the body including the liver, kidneys and lungs; however, it is relatively new to the field of breast lesions (Lakoma & Kim, 2014). Fibroadenomas are relatively superficial lesions and are especially suitable for minimally invasive ablation techniques (Kovatcheva et al., 2015). There are two types, thermal ablation and cryoablation, which utilize both extreme heat and extreme cold respectively. Thermal ablation of breast tissue is still being tested in the United States and not widely available; however, cryoablation has been FDA approved since 2001 (Lakoma & Kim, 2014).

## ***THERMAL ABLATION***

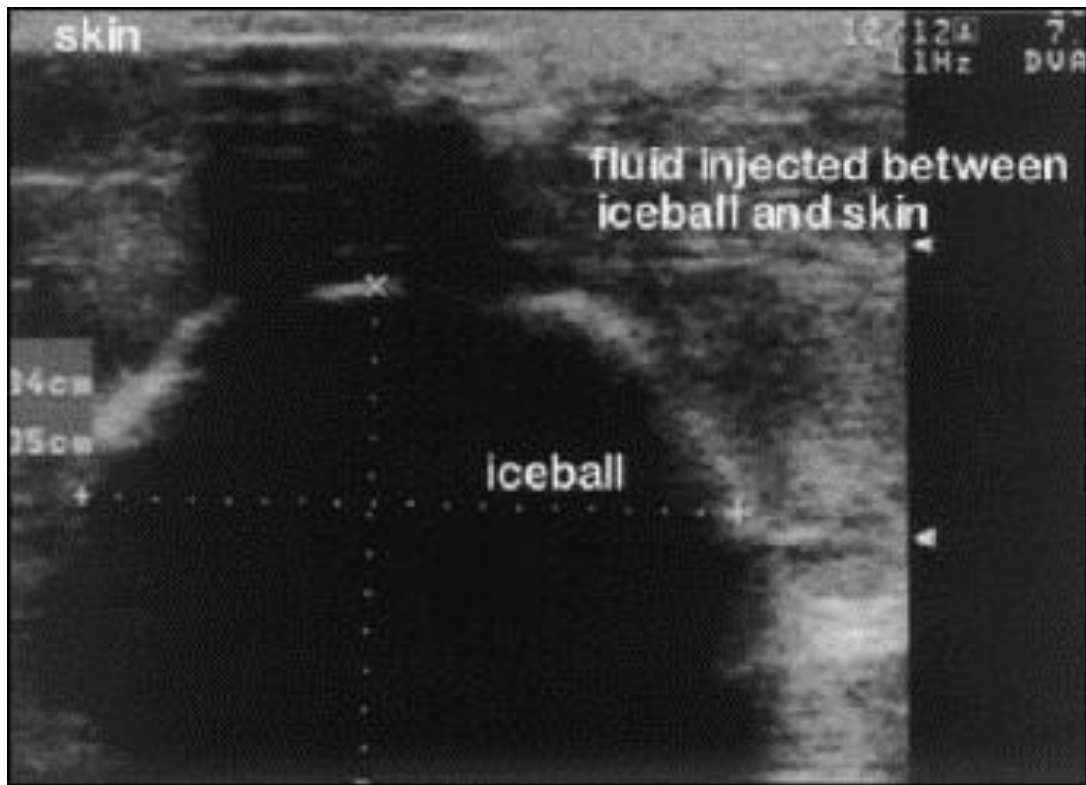
Thermal ablation procedures use heat from three different sources: radiofrequency, high-intensity focused ultrasound and lasers. They function by causing tissue-wide necrosis of the targeted lesion and a rim of normal breast tissue around it (Dowlathshahi, Wadhwani, Alvarado, Valadez, & Dieschbourg, 2010). The coagulated tissue is then partially liquefied and aspirated like a cyst, and the lesion subsequently shrinks over time (Dowlathshahi et al., 2010). There may be internal scars that appear on mammogram; however this does not interfere with annual evaluations (Dowlathshahi et al., 2010). These procedures are typically done in outpatient centers under conscious sedation or local anesthesia if that patient so chooses, reducing costs compared to open

surgical excision (Kovatcheva et al., 2015). Thermal ablation procedures are effective in reducing the volume and clinical symptoms, if any, of breast fibroadenomas without any serious side effects (Kovatcheva et al., 2015). Radiofrequency ablation is the most popular as it has the ability to target lesions that are up to 3-5cm in diameter (Lakoma & Kim, 2014). High intensity-focused ultrasound are essentially non-invasive, making it a current subject of interest, however further studies are required to assess long-term efficacy (Kovatcheva et al., 2015). Laser ablation may be done in doctor's offices under local anesthesia with minimal pain and discomfort (Dowlatshahi et al., 2010), though it may be more expensive than radiofrequency ablation.

Thermal ablation procedures may include side-effects such as superficial burns, hyperpigmentation over the treatment area, skin indurations, recurrence, incomplete removal and inability to obtain clear surgical margins (Lee & Soltanian, 2015). The technique may also cause considerable discomfort to some patients, requiring the use of conscious sedation or even general anesthesia (Kaufman et al., 2002). Radiofrequency or laser ablation techniques are poorly visualized on ultrasound for real-time monitoring as there are no visible changes occurring causing estimation of negative margins to be difficult (Lakoma & Kim, 2014). The patient is then at risk for thermal injury, which may include muscle or skin burns.

### *CRYOABLATION*

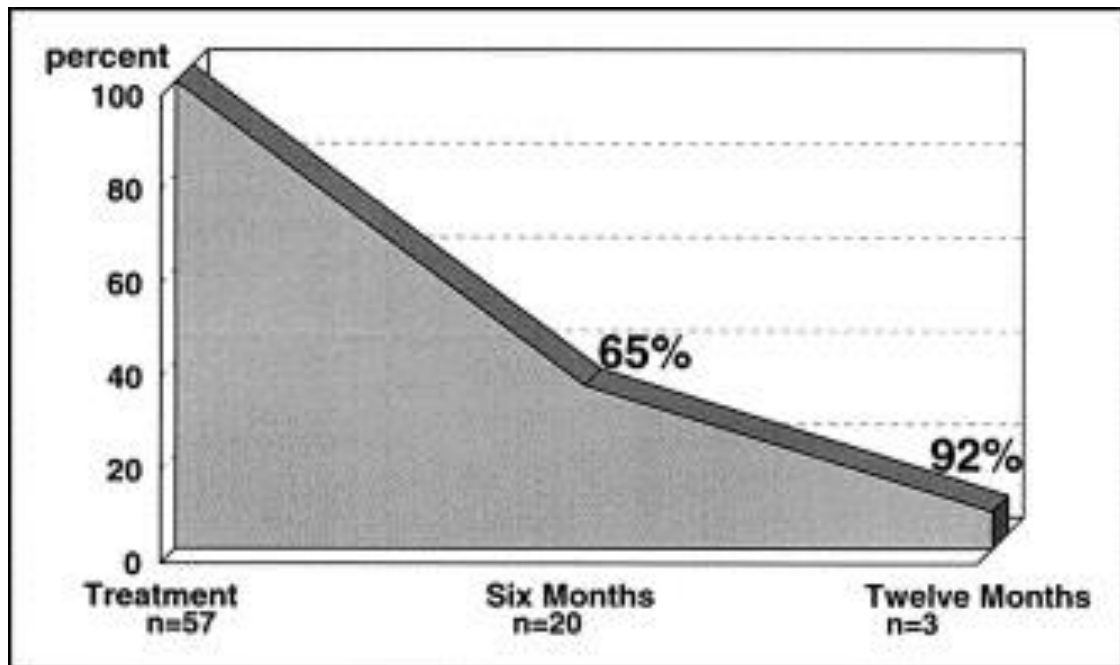
Cryoablation uses extreme cold to completely destroy the tissue of the targeted lesion. Like thermal ablation, it is a less-invasive treatment compared to open surgical excision that does not result in mammographic changes, breast deformation or scarring (“Treatment Options for Fibroadenoma” Breast Health Options, n.d.). It has been used successfully in both adults and adolescents; however it is less common in adolescents (Cerrato & Labow, 2013; Jolesz & Hynynen, 2002; Kaufman et al., 2002). It is reported to be comfortable and painless, as the cold acts along with the local anesthesia to numb the area (“Treatment Options for Fibroadenoma” Breast Health Options, n.d.). The procedure is often completed in doctor offices and includes a small, 3mm incision that may be closed without sutures, resulting in no scars (Kaufman et al., 2002 and Chepla et al., 2011). A small probe is then inserted into the targeted fibroadenoma with the assistance of US through the incision site, where the lesion cells are destroyed with extremely cold temperatures, creating an ‘iceball’ that may be visualized in figure 12 (“Treatment Option for Fibroadenoma” Breast Health Option, n.d.). The body then naturally absorbs the destroyed cells over time, which may vary depending on the initial size of the fibroadenoma (“Treatment Options for Fibroadenoma” Breast Health Options, n.d.). Lesions less than 2cm in size are associated with better outcomes in both reabsorption and non-palpability post-procedure (Nurko et al., 2005). Kaufman et al. conducted a study using 57 patients that had undergone cryoablation therapy in the past 12 months, collecting data on the reduction size of their lesion, shown in figure 13. They reported that after six months approximately 65% of the lesion had reduced, while at 12 months it had gone up to 92%.



**Figure 12: Visualization of Iceball on Ultrasound in Cryoablation Procedure.** Iceball containing fibroadenoma viewed on ultrasound. Note the fluid injected between the iceball and skin, used to prevent any further necrotic damage aside from the targeted lesion. Figure taken from Kaufman et al., 2002.

Cryoablation has several distinct advantages: excellent visualization under ultrasound permitting real-time monitoring and precise procedural control and skin protection that is not granted using thermal ablation (Lakoma & Kim, 2014), minor procedural and postoperative discomfort, excellent cosmesis without tissue removal and minimal scarring, and elimination of the need for sedation due to its inherent anesthetic properties (Kaufman et al., 2002 and Nurko et al. 2005). Of note, if a patient had multiple fibroadenomas adjacent to the initial target, they may be treated as one large lesion and treated simultaneously with a single pass of the probe (Kaufman et al., 2002). The

procedure usually takes approximately 10-15 minutes and the patient may return to normal activities very quickly post-procedure (“Treatment Options for Fibroadenoma” Breast Health Options, n.d.). As the destruction of the fibroadenoma is in situ, there is reduced risk of breast distortion or poor cosmesis, resulting in high patient satisfaction (Lee & Soltanian, 2015). Cryoablation is also less technically challenging when compared to VAE, making it easier on physicians to perform (Kaufman et al., 2002).



**Figure 13: Reduction of Lesion Size Post-Cryoablation.** Figure taken from Kaufman et al., 2002.

As evidenced in figure 13, cryoablation does not provide immediate results, particularly for patients that have lesions larger than 2cm (Nurko et al., 2005). It is still a viable treatment option for larger lesions; however patients should be warned ahead of time that the mass may not fully resolve for several months after the cryoablation. While cryoablation generally costs less than open surgical excision, it is still currently one of the



more expensive alternatives in the market (“Treatment Options for Fibroadenoma” Breast Health Options, n.d.). Of note, insurances may cover the cost of the open surgical excision however, as cryoablation is still relatively new, it may not be covered and thus the patients are forced to pay out of pocket.

## CONCLUSION

### **ASSESSMENT OF MANAGEMENT AND TREATMENT COMBINATIONS**

With the ever growing list of management and treatment options available for fibroadenomas, it is important to evaluate which methods are most effective for the specific type of fibroadenoma the patient has. Of particular interest are female adolescents, as there are more intricate details at play concerning psychosocial implications that need to be considered with as much importance as the effectiveness and reliability of any procedures or testing.

#### ***SIMPLE FIBROADENOMA***

Simple fibroadenomas are the most common variation of the disease, affecting as many as 70-90% of all cases (Lee & Soltanian, 2015). This is especially true with the adolescent population, as complications such as calcifications and other changes in breast tissue that signify malignancy are less common in the younger age groups. Simple fibroadenomas may be palpable or nonpalpable, however they typically do not cause any concerning cosmetic changes of the breast aside from the basic anxiety of having a lump in the breast due to their small size. As such, the most commonly accepted practice for these types of patients is the conservative method (Ng et al., 2011). Approximately 10-40% of all cases regress spontaneously without any intervention (Jayasinghe & Simmons, 2009), and many others remain stable without any concerning changes. For simple fibroadenomas in adolescents, avoiding any sort of invasive intervention, whether it is

simple biopsy or surgical excision, is the main goal as there will always be a chance of iatrogenic damage to the developing breast. While this method is ideal, there may be patients or family members that are unable to participate in the conservative method due to excessive anxiety despite all reassurances of the benignity of the disease. Further imaging, surveillance or biopsy may be ordered to build a case around the disease and its benign nature, however there may be times the patient and/or family are still uncomfortable with the conservative method. If this is the case, minimally invasive procedures are encouraged to avoid open surgery, as it may cause cosmetic damage and further aggravate the anxiety and stress the situation gives the adolescent. VAE or cryoablation are good techniques that may be used, however it is important to explain the process to the patient and family thoroughly to ensure the patient is able to undergo such a procedure. If there may be complications, however the patient and/or family members wish to go ahead with these methods, procedural sedation may be requested to make the situation less stressful. Open surgical excision should be reserved only for adamant requests and emergency situations.

### ***JUVENILE GIANT FIBROADENOMA***

Juvenile giant fibroadenoma look remarkably similar to phyllodes tumors, which are most often malignant, thus imaging via US is strongly recommended along with tissue biopsy for histological evaluation (Sosin et al., 2015). The type of biopsy to be performed depends on the future treatment strategy, conservative or further invasive

intervention, which is to be discussed with the patient and the family prior to beginning any further intervention after the imaging. Observation may be recommended if the lesion is not causing significant cosmetic change or discomfort, or if the patient prefers to avoid any surgical procedures, however this is most often not the case with adolescents. Juvenile giant fibroadenomas typically cause enough cosmetic change to cause psychosocial implications for younger patients, and it is therefore recommended that excision be considered first. If surgical procedures are recommended, such as lumpectomy or mastectomy, biopsy procedures should be avoided to minimize any iatrogenic injuries or invasive procedures (Sosin et al., 2015).

### ***MULTIPLE FIBROADENOMA***

Patients with multiple fibroadenoma, particularly adolescents, face a choice that is more difficult than other cases. It may be possible to excise each lesion as they appear, or grow; however, multiple procedures may lead to scarring, iatrogenic damage or other cosmetic deformities of the breast (Williamson et al., 1993). Another suggestion may be to treat the fibroadenoma conservatively, as if they were multiple simple fibroadenoma, granted the cytology and typical clinical/US appearance is consistent with a benign lesion (Williamson et al., 1993). This method will avoid multiple surgeries and complications for the patient, however as with simple fibroadenoma it may not ease the anxiety the patient has for the disease. Biopsy is certainly recommended in these patients as the multiple lesions may represent a risk for malignancy, albeit rare. LCNB is recommended

for adolescents, unless VAE will be performed as both a biopsy procedure and treatment option. Open surgical excision is to be avoided, as one excision may ultimately lead to several more that may cause more harm than benefit, or even deform the breast. Of the minimally invasive procedures cryoablation is particularly recommended, due to its ability to target multiple fibroadenoma at the same time without added excision or treatments. Procedural sedation may be required to ease any patient anxiety during the procedure; however, studies have shown cryoablation to be successful in adolescents, though not often done.

Patients with multiple giant fibroadenomas are left with few options, and most tend to undergo open surgical excision. There is also a high incidence of recurrence associated multiple giant fibroadenoma, though this rate may decrease as the patient becomes older (Musio et al., 1991). Faced with possibly multiple open surgical excisions, the most important factor in these patients are the reconstructions that are to be completed alongside, or after, the procedural excision. These reconstruction procedures may include reduction mammoplasty and simple mastectomy with reconstruction, though mastectomy is to be reserved for extreme cases (Musio et al., 1991).

### **OPINIONS IN LITERATURE REGARDING FUTURE STUDIES**

The general consensus for a treatment option for females, adolescent or older, with fibroadenoma is the less invasive and efficient, the better (Grady et al., 2008). Multiple trials are conducted testing various other alternatives to surgical procedures, with a few omitting invasive intervention entirely such as with high intensity-focused

ultrasound. As one of the largest concerns for the conservative method is long-term surveillance noncompliance and associated anxiety, it is important to emphasize as little post-procedural observation as possible. Techniques that limit recurrence and are able to completely remove the lesion are ideal, and something that is constantly being worked on. It is predicted that in the future conservative management will develop and ultimately replace open surgical treatment, particularly for female adolescents with benign fibroadenoma (El-Wakeel & Umpleby, 2003). Should the conservative method cause further anxiety, or is otherwise not accepted by the patient and/or family members, minimally invasive procedures such as cryoablation appear to be excellent alternatives that include minimal side-effects and have great cosmesis. The biggest downfall to this procedure is its long observation period and time to take effect, however if properly discussed with the patient and family members prior to the procedure it may not pose as much of a problem.

## REFERENCES

- ACR. (2013). ACR BI-RADS® Atlas. Retrieved January 28, 2016, from <http://www.acr.org/Quality-Safety/Resources/BIRADS>
- ACR. (n.d.). Breast Ultrasound. Retrieved February 8, 2016, from <http://www.radiologyinfo.org/en/info.cfm?pg=breastus>
- ACS. (2015, March 16). Fibroadenomas. Retrieved January 20, 2016, from <http://www.cancer.org/healthy/findcancerearly/womenshealth/non-cancerousbreastconditions/non-cancerous-breast-conditions-fibroadenomas>
- ACS. (n.d.). Understanding your mammogram report – BI-RADS categories. Retrieved January 25, 2016, from <http://www.cancer.org/treatment/understandingyourdiagnosis/examsandtestdescriptions/mammogramsandotherbreastimagingprocedures/mammograms-and-other-breast-imaging-procedures-mammo-report>
- Alonso-Bartolomé, P., Vega-Bolívar, A., Torres-Tabanera, M., Ortega, E., Acebal-Blanco, M., Garijo-Ayensa, F., ... Muñoz-Cacho, P. (2004). Sonographically guided 11-G directional vacuum-assisted breast biopsy as an alternative to surgical excision: utility and cost study in probably benign lesions. *Acta Radiologica (Stockholm, Sweden: 1987)*, 45(4), 390–396.
- Biopsy procedures of breast, insured. (n.d.). Retrieved January 24, 2016, from [http://fairhealthconsumer.org/medical\\_cost.php](http://fairhealthconsumer.org/medical_cost.php)
- Breast Biopsy. (2014, March). Retrieved January 20, 2016, from <http://www.choosingwisely.org/patient-resources/breast-biopsy/>
- Cant, P. J., Madden, M. V., Coleman, M. G., & Dent, D. M. (1995). Non-operative management of breast masses diagnosed as fibroadenoma. *The British Journal of Surgery*, 82(6), 792–794.
- Carter, B. A., Page, D. L., Schuyler, P., Parl, F. F., Simpson, J. F., Jensen, R. A., & Dupont, W. D. (2001). No elevation in long-term breast carcinoma risk for women with fibroadenomas that contain atypical hyperplasia. *Cancer*, 92(1), 30–36.
- Celik, M. F., Dural, A. C., Unsal, M. G., Akarsu, C., Alim, E. R., Kapan, S., ... Alis, H. (2015). Giant juvenile fibroadenoma. *Turkish Journal of Surgery*, 31(2), 96–98. <http://doi.org/10.5152/UCD.2014.2574>

- Cerrato, F., & Labow, B. I. (2013). Diagnosis and Management of Fibroadenomas in the Adolescent Breast. *Seminars in Plastic Surgery*, 27(1), 23–25.  
<http://doi.org/10.1055/s-0033-1343992>
- Cha, J. H., Moon, W. K., Cho, N., Kim, S. M., Park, S. H., Han, B.-K., ... Im, J.-G. (2007). Characterization of benign and malignant solid breast masses: comparison of conventional US and tissue harmonic imaging. *Radiology*, 242(1), 63–69.  
<http://doi.org/10.1148/radiol.2421050859>
- Chepla, K. J., Armijo, B. S., Ponsky, T. A., & Soltanian, H. T. (2011). Benefits of immediate dermoglandular preserving reconstruction following giant fibroadenoma excision in two patients. *Journal of Plastic, Reconstructive & Aesthetic Surgery: JPRAS*, 64(9), e244–247.  
<http://doi.org/10.1016/j.bjps.2011.04.005>
- Choo, K. S., Kwak, H. S., Tae Bae, Y., Lee, J.-Y., Lee, S. J., Seo, H. I., & Nam, S. B. (2008). The value of a combination of wire localization and ultrasound-guided vacuum-assisted breast biopsy for clustered microcalcifications. *Breast (Edinburgh, Scotland)*, 17(6), 611–616.  
<http://doi.org/10.1016/j.breast.2008.05.010>
- Chung, E. M., Cube, R., Hall, G. J., González, C., Stocker, J. T., & Glassman, L. M. (2009). From the archives of the AFIP: breast masses in children and adolescents: radiologic-pathologic correlation. *Radiographics: A Review Publication of the Radiological Society of North America, Inc*, 29(3), 907–931.  
<http://doi.org/10.1148/rg.293095010>
- Dent, D. M., & Cant, P. J. (1989). Fibroadenoma. *World Journal of Surgery*, 13(6), 706–710.
- Divasta, A. D., C. Weldon, and B. I. Labow. "The breast: examination and lesions." *Pediatric and Adolescent Gynecology*. 6th ed. Philadelphia, PA: Lippincott, Williams and Wilkins (2012): 405-20.
- Dixon, J. M., Dobie, V., Lamb, J., Walsh, J. S., & Chetty, U. (1996). Assessment of the acceptability of conservative management of fibroadenoma of the breast. *The British Journal of Surgery*, 83(2), 264–265.
- Dowlatshahi, K., Wadhvani, S., Alvarado, R., Valadez, C., & Dieschbourg, J. (2010). Interstitial laser therapy of breast fibroadenomas with 6 and 8 year follow-up. *The Breast Journal*, 16(1), 73–76. <http://doi.org/10.1111/j.1524-4741.2009.00830.x>



- Duflos, C., Plu-Bureau, G., Thibaud, E., & Kuttenn, F. (2012). Breast diseases in adolescents. *Endocrine Development*, *22*, 208–221. <http://doi.org/10.1159/000326690>
- Egan, R. L., McSweeney, M. B., & Sewell, C. W. (1980). Intramammary calcifications without an associated mass in benign and malignant diseases. *Radiology*, *137*(1 Pt 1), 1–7. <http://doi.org/10.1148/radiology.137.1.7422830>
- El-Wakeel, H., & Umpleby, H. C. (2003). Systematic review of fibroadenoma as a risk factor for breast cancer. *Breast (Edinburgh, Scotland)*, *12*(5), 302–307.
- Ezer, S. S., Oguzkurt, P., Ince, E., Temiz, A., Bolat, F. A., & Hicsonmez, A. (2013). Surgical Treatment of the Solid Breast Masses in Female Adolescents. *Journal of Pediatric and Adolescent Gynecology*, *26*(1), 31–35. <http://doi.org/10.1016/j.jpag.2012.09.004>
- Fine, R. E., Boyd, B. A., Whitworth, P. W., Kim, J. A., Harness, J. K., & Burak, W. E. (2002). Percutaneous removal of benign breast masses using a vacuum-assisted hand-held device with ultrasound guidance. *American Journal of Surgery*, *184*(4), 332–336.
- Fine, R. E., Whitworth, P. W., Kim, J. A., Harness, J. K., Boyd, B. A., & Burak, W. E. (2003). Low-risk palpable breast masses removed using a vacuum-assisted hand-held device. *American Journal of Surgery*, *186*(4), 362–367.
- Grady, I., Gorsuch, H., & Wilburn-Bailey, S. (2008). Long-term outcome of benign fibroadenomas treated by ultrasound-guided percutaneous excision. *The Breast Journal*, *14*(3), 275–278. <http://doi.org/10.1111/j.1524-4741.2008.00574.x>
- Graf, O., Helbich, T. H., Fuchsjaeger, M. H., Hopf, G., Morgun, M., Graf, C., ... Sickles, E. A. (2004). Follow-up of palpable circumscribed noncalcified solid breast masses at mammography and US: can biopsy be averted? *Radiology*, *233*(3), 850–856. <http://doi.org/10.1148/radiol.2333031845>
- Greenberg, R., Skornick, Y., & Kaplan, O. (1998a). Management of breast fibroadenomas. *Journal of General Internal Medicine*, *13*(9), 640–645.
- Greenblatt, R. B., Nezhat, C., & Ben-Nun, I. (1980). The treatment of benign breast disease with danazol. *Fertility and Sterility*, *34*(3), 242–245.
- Guray, M., & Sahin, A. A. (2006). Benign Breast Diseases: Classification, Diagnosis, and Management. *The Oncologist*, *11*(5), 435–449. <http://doi.org/10.1634/theoncologist.11-5-435>

- Gwinnett Medical Center Imaging. (n.d.-a). MRI-Guided Vacuum-Assisted Core Biopsy. Retrieved January 24, 2016, from <http://gmcimaging.org/women%E2%80%99s-imaging/mri-guided-vacuum-assisted-core-biopsy>
- Gwinnett Medical Center Imaging. (n.d.-b). Stereotactic-Guided Vacuum-Assisted Core Biopsy. Retrieved January 24, 2016, from <http://gmcimaging.org/women%E2%80%99s-imaging/stereotactic-guided-vacuum-assisted-core-biopsy>
- Gwinnett Medical Center Imaging. (n.d.-c). Ultrasound-Guided Vacuum-Assisted Core Biopsy. Retrieved January 24, 2016, from <http://gmcimaging.org/women%E2%80%99s-imaging/ultrasound-guided-vacuum-assisted-core-biopsy>
- Helbich, T. H., Matzek, W., & Fuchsjäger, M. H. (2004). Stereotactic and ultrasound-guided breast biopsy. *European Radiology*, *14*(3), 383–393. <http://doi.org/10.1007/s00330-003-2141-z>
- Helbich, T. H., Rudas, M., Böhm, G., Huber, S., Wagner, T., Taucher, S., ... Mostbeck, G. H. (1999). Randomized in vitro and in vivo evaluation of different biopsy needles and devices for breast biopsy. *Clinical Radiology*, *54*(1), 56–62.
- Huber, S., Wagner, M., Medl, M., & Czembirek, H. (2003). Benign breast lesions: minimally invasive vacuum-assisted biopsy with 11-gauge needles patient acceptance and effect on follow-up imaging findings. *Radiology*, *226*(3), 783–790. <http://doi.org/10.1148/radiol.2271011933>
- Hughes, L. E. (1991). Classification of benign breast disorders. The ANDI classification based on physiological processes within the normal breast. *British Medical Bulletin*, *47*(2), 251–257.
- Hughes, L. E., Mansel, R. E., & Webster, D. J. (1987). Aberrations of normal development and involution (ANDI): a new perspective on pathogenesis and nomenclature of benign breast disorders. *Lancet (London, England)*, *2*(8571), 1316–1319.
- Jawahar, A., Vade, A., Ward, K., Okur, G., & Subbaiah, P. (2015). Biopsy Versus Conservative Management of Sonographically Benign-Appearing Solid Breast Masses in Adolescents. *Journal of Ultrasound in Medicine*, *34*(4), 617–625. <http://doi.org/10.7863/ultra.34.4.617>

- Jayasinghe, Y., & Simmons, P. S. (2009). Fibroadenomas in adolescence. *Current Opinion in Obstetrics & Gynecology*, 21(5), 402–406. <http://doi.org/10.1097/GCO.0b013e32832fa06b>
- Johns Hopkins Medicine Health Library. (n.d.). Breast Biopsy Procedures. Retrieved February 1, 2016, from [http://www.hopkinsmedicine.org/healthlibrary/test\\_procedures/gynecology/breast\\_biopsy\\_92,P07763/](http://www.hopkinsmedicine.org/healthlibrary/test_procedures/gynecology/breast_biopsy_92,P07763/)
- Jolesz, F. A., & Hynynen, K. (2002). Magnetic resonance image-guided focused ultrasound surgery. *Cancer Journal (Sudbury, Mass.)*, 8 Suppl 1, S100–112.
- Kaufman, C. S., Bachman, B., Littrup, P. J., White, M., Carolin, K. A., Freman-Gibb, L., ... Simmons, R. (2002). Office-based ultrasound-guided cryoablation of breast fibroadenomas. *The American Journal of Surgery*, 184(5), 394–400. [http://doi.org/10.1016/S0002-9610\(02\)01010-3](http://doi.org/10.1016/S0002-9610(02)01010-3)
- Kolkman, S., & Zonderland, H. M. (2011). [Removal of fibroadenomas by vacuum-assisted biopsy]. *Nederlands Tijdschrift Voor Geneeskunde*, 155(40), A3393.
- Kovatcheva, R., Guglielmina, J.-N., Abehsera, M., Boulanger, L., Laurent, N., & Poncelet, E. (2015). Ultrasound-guided high-intensity focused ultrasound treatment of breast fibroadenoma—a multicenter experience. *Journal of Therapeutic Ultrasound*, 3(1), 1. <http://doi.org/10.1186/s40349-014-0022-3>
- Lacambra, M. D., Lam, C. C., Mendoza, P., Chan, S. K., Yu, A. M., Tsang, J. Y. S., ... Tse, G. M. (2012). Biopsy sampling of breast lesions: comparison of core needle- and vacuum-assisted breast biopsies. *Breast Cancer Research and Treatment*, 132(3), 917–923. <http://doi.org/10.1007/s10549-011-1639-3>
- Lakoma, A., & Kim, E. S. (2014). Minimally invasive surgical management of benign breast lesions. *Gland Surgery*, 3(2), 142–148. <http://doi.org/10.3978/j.issn.2227-684X.2014.04.01>
- Lee, M., & Soltanian, H. T. (2015). Breast fibroadenomas in adolescents: current perspectives. *Adolescent Health, Medicine and Therapeutics*, 6, 159–163. <http://doi.org/10.2147/AHMT.S55833>
- Lell, M., Wenkel, E., Aichinger, U., Schulz-Wendtland, R., & Bautz, W. (2004). [3D ultrasound in core breast biopsy]. *Ultraschall in Der Medizin (Stuttgart, Germany: 1980)*, 25(2), 126–130. <http://doi.org/10.1055/s-2004-813103>

- Liberman, L. (2000). Clinical management issues in percutaneous core breast biopsy. *Radiologic Clinics of North America*, 38(4), 791–807.
- Li, J. L., Wang, Z. L., Su, L., Liu, X. J., & Tang, J. (2010). Breast lesions with ultrasound imaging-histologic discordance at 16-gauge core needle biopsy: Can re-biopsy with 10-gauge vacuum-assisted system get definitive diagnosis? *The Breast*, 19(6), 446–449. <http://doi.org/10.1016/j.breast.2010.04.003>
- Lumpectomy, insured. (n.d.). Retrieved January 24, 2016, from [http://fairhealthconsumer.org/medical\\_cost.php](http://fairhealthconsumer.org/medical_cost.php)
- Mainiero, M. B., Gareen, I. F., Bird, C. E., Smith, W., Cobb, C., & Schepps, B. (2002). Preferential use of sonographically guided biopsy to minimize patient discomfort and procedure time in a percutaneous image-guided breast biopsy program. *Journal of Ultrasound in Medicine: Official Journal of the American Institute of Ultrasound in Medicine*, 21(11), 1221–1226.
- Matz, D., Kerivan, L., Reintgen, M., Akman, K., Lozicki, A., Causey, T., ... Reintgen, D. (2013). Breast Preservation in Women With Giant Juvenile Fibroadenoma. *Clinical Breast Cancer*, 13(3), 219–222. <http://doi.org/10.1016/j.clbc.2012.10.003>
- Mayo Clinic. (2016, February 2). Breast calcifications. Retrieved February 5, 2016, from <http://www.mayoclinic.org/symptoms/breast-calcifications/basics/definition/sym-20050834>
- Méndez Ribas, J. M. (2010). Breast problems and diseases in puberty. *Best Practice & Research. Clinical Obstetrics & Gynaecology*, 24(2), 223–242. <http://doi.org/10.1016/j.bpobgyn.2009.09.011>
- Mesurolle, B., Bining, H. J. S., El Khoury, M., Barhdadi, A., & Kao, E. (2006). Contribution of tissue harmonic imaging and frequency compound imaging in interventional breast sonography. *Journal of Ultrasound in Medicine: Official Journal of the American Institute of Ultrasound in Medicine*, 25(7), 845–855.
- Musio, F., Mozingo, D., & Otchy, D. P. (1991). Multiple, giant fibroadenoma. *The American Surgeon*, 57(7), 438–441.
- Muttarak, M., Kongmebhol, P., & Sukhamwang, N. (2009). Breast calcifications: which are malignant? *Singapore Medical Journal*, 50(9), 907–913; quiz 914.
- Nagasue, N. (2002). Sabiston review of surgery C.M. Townsend Jr, R. D. Beauchamp, K. L. Mattox and B. M. Evers (eds) 275 × 210 mm. Pp 167. Not Illustrated. 2001.

Philadelphia, Pennsylvania: WB Saunders. *British Journal of Surgery*, 89(4), 502–503. <http://doi.org/10.1046/j.0007-1323.2001.t-04-02010.x>

- Neinstein, L. S. (1999). Breast disease in adolescents and young women. *Pediatric Clinics of North America*, 46(3), 607–629.
- Neinstein, L. S., Atkinson, J., & Diament, M. (1993). Prevalence and longitudinal study of breast masses in adolescents. *The Journal of Adolescent Health: Official Publication of the Society for Adolescent Medicine*, 14(4), 277–281.
- Ng, W. K., Mrad, M. A., & Brown, M. H. (2011). Juvenile fibroadenoma of the breast: Treatment and literature review. *The Canadian Journal of Plastic Surgery = Journal Canadien De Chirurgie Plastique*, 19(3), 105–107.
- Nurko, J., Mabry, C. D., Whitworth, P., Jarowenko, D., Oetting, L., Potruch, T., ... Edwards, M. J. (2005). Interim results from the Fibroadenoma Cryoablation Treatment Registry. *The American Journal of Surgery*, 190(4), 647–652. <http://doi.org/10.1016/j.amjsurg.2005.06.033>
- Ohashi, R., Matsubara, M., Watarai, Y., Yanagihara, K., Yamashita, K., Tsuchiya, S.-I., ... Naito, Z. (2015). Cytological features of complex type fibroadenoma in comparison with non-complex type fibroadenoma. *Breast Cancer (Tokyo, Japan)*. <http://doi.org/10.1007/s12282-015-0632-9>
- Ouyang, Q., Li, S., Tan, C., Zeng, Y., Zhu, L., Song, E., ... Su, F. (2015). Benign Phyllodes Tumor of the Breast Diagnosed After Ultrasound-Guided Vacuum-Assisted Biopsy: Surgical Excision or Wait-and-Watch? *Annals of Surgical Oncology*. <http://doi.org/10.1245/s10434-015-4990-5>
- Park, C. A., David, L. R., & Argenta, L. C. (2006). Breast Asymmetry: Presentation of a Giant Fibroadenoma. *The Breast Journal*, 12(5), 451–461. <http://doi.org/10.1111/j.1075-122X.2006.00303.x>
- Park, H.-L., & Kim, L. S. (2011). The Current Role of Vacuum Assisted Breast Biopsy System in Breast Disease. *Journal of Breast Cancer*, 14(1), 1–7. <http://doi.org/10.4048/jbc.2011.14.1.1>
- Park, J. M., Choi, H. K., Bae, S. J., Lee, M. S., Ahn, S. H., & Gong, G. (2000). Clustering of breast microcalcifications: revisited. *Clinical Radiology*, 55(2), 114–118. <http://doi.org/10.1053/crad.1999.0220>
- Penco, S., Rizzo, S., Bozzini, A. C., Latronico, A., Menna, S., Cassano, E., & Bellomi, M. (2010). Stereotactic vacuum-assisted breast biopsy is not a therapeutic

procedure even when all mammographically found calcifications are removed: analysis of 4,086 procedures. *AJR. American Journal of Roentgenology*, 195(5), 1255–1260. <http://doi.org/10.2214/AJR.10.4208>

Powell, R. W., McSweeney, M. B., & Wilson, C. E. (1983). X-ray calcifications as the only basis for breast biopsy. *Annals of Surgery*, 197(5), 555–559.

Reiner, C. S., Helbich, T. H., Rudas, M., Ponthold, L., Riedl, C. C., Kropf, N., & Fuchsjäger, M. H. (2009). Can galactography-guided stereotactic, 11-gauge, vacuum-assisted breast biopsy of intraductal lesions serve as an alternative to surgical biopsy? *European Radiology*, 19(12), 2878–2885. <http://doi.org/10.1007/s00330-009-1502-7>

Saleh, A., Ernst, S., Grust, A., Fürst, G., Dall, P., & Mödder, U. (2001). [Real-time compound imaging: improved visibility of puncture needles and localization wires as compared to single-line ultrasonography]. *RöFo: Fortschritte Auf Dem Gebiete Der Röntgenstrahlen Und Der Nuklearmedizin*, 173(4), 368–372. <http://doi.org/10.1055/s-2001-12467>

Sanders, L. M., & Sara, R. (2015). The growing fibroadenoma. *Acta Radiologica Open*, 4(4). <http://doi.org/10.1177/2047981615572273>

Santen, R. J. (2000). Benign Breast Disease in Women. In L. J. De Groot, P. Beck-Peccoz, G. Chrousos, K. Dungan, A. Grossman, J. M. Hershman, ... M. O. Weickert (Eds.), *Endotext*. South Dartmouth (MA): MDText.com, Inc. Retrieved from <http://www.ncbi.nlm.nih.gov/books/NBK278994/>

Schueller, G., Schueller-Weidekamm, C., & Helbich, T. H. (2008). Accuracy of ultrasound-guided, large-core needle breast biopsy. *European Radiology*, 18(9), 1761–1773. <http://doi.org/10.1007/s00330-008-0955-4>

Sehgal, C. M., Weinstein, S. P., Arger, P. H., & Conant, E. F. (2006). A review of breast ultrasound. *Journal of Mammary Gland Biology and Neoplasia*, 11(2), 113–123. <http://doi.org/10.1007/s10911-006-9018-0>

Shabtai, M., Saavedra-Malinger, P., Shabtai, E. L., Rosin, D., Kuriansky, J., Ravid-Megido, M., ... Ayalon, A. H. (2001). Fibroadenoma of the breast: analysis of associated pathological entities--a different risk marker in different age groups for concurrent breast cancer. *The Israel Medical Association Journal: IMAJ*, 3(11), 813–817.

Sosin, M., Pulcrano, M., Feldman, E. D., Patel, K. M., Nahabedian, M. Y., Weissler, J. M., & Rodriguez, E. D. (2015). Giant juvenile fibroadenoma: a systematic review

with diagnostic and treatment recommendations. *Gland Surgery*, 4(4), 312.  
<http://doi.org/10.3978/j.issn.2227-684X.2015.06.04>

- Sperber, F., Blank, A., Metser, U., Flusser, G., Klausner, J. M., & Lev-Chelouche, D. (2003). Diagnosis and treatment of breast fibroadenomas by ultrasound-guided vacuum-assisted biopsy. *Archives of Surgery (Chicago, Ill.: 1960)*, 138(7), 796–800. <http://doi.org/10.1001/archsurg.138.7.796>
- Stavros, A. T., Thickman, D., Rapp, C. L., Dennis, M. A., Parker, S. H., & Sisney, G. A. (1995). Solid breast nodules: use of sonography to distinguish between benign and malignant lesions. *Radiology*, 196(1), 123–134.  
<http://doi.org/10.1148/radiology.196.1.7784555>
- Su, K.-L., Xu, H.-B., Hu, Z.-J., He, J.-L., Yang, O.-O., & Hu, W.-H. (2010). [Vacuum-assisted biopsy and wire localization for the diagnosis of non-palpable breast lesions]. *Zhonghua Zhong Liu Za Zhi [Chinese Journal of Oncology]*, 32(6), 472–475.
- Surry, K. J. M., Smith, W. L., Campbell, L. J., Mills, G. R., Downey, D. B., & Fenster, A. (2002). The development and evaluation of a three-dimensional ultrasound-guided breast biopsy apparatus. *Medical Image Analysis*, 6(3), 301–312.
- Tabár, L., Duffy, S. W., Vitak, B., Chen, H. H., & Prevost, T. C. (1999). The natural history of breast carcinoma: what have we learned from screening? *Cancer*, 86(3), 449–462.
- Thuruthiyath, N., Das, P. C., Avabratha, K. S., Mascarenhas, V., & Marla, N. (2012). Giant Fibroadenoma of Breast in an Adolescent Girl. *Oman Medical Journal*, 27(4), 314–315. <http://doi.org/10.5001/omj.2012.77>
- Treatment Options for Fibroadenoma. (n.d.). Retrieved January 20, 2016, from <http://breasthealthoptions.com/education/treatment-options-for-fibroadenoma/>
- Tse, G. M., Tan, P.-H., Cheung, H. S., Chu, W. C. W., & Lam, W. W. M. (2008). Intermediate to highly suspicious calcification in breast lesions: a radio-pathologic correlation. *Breast Cancer Research and Treatment*, 110(1), 1–7.  
<http://doi.org/10.1007/s10549-007-9695-4>
- Tse, G. M., Tan, P.-H., Pang, A. L. M., Tang, A. P. Y., & Cheung, H. S. (2008). Calcification in breast lesions: pathologists' perspective. *Journal of Clinical Pathology*, 61(2), 145–151. <http://doi.org/10.1136/jcp.2006.046201>

- Vade, A., Lafita, V. S., Ward, K. A., Lim-Dunham, J. E., & Bova, D. (2008). Role of Breast Sonography in Imaging of Adolescents with Palpable Solid Breast Masses. *American Journal of Roentgenology*, *191*(3), 659–663. <http://doi.org/10.2214/AJR.07.3390>
- Weismann, C. F., Forstner, R., Prokop, E., & Rettenbacher, T. (2000). Three-dimensional targeting: a new three-dimensional ultrasound technique to evaluate needle position during breast biopsy. *Ultrasound in Obstetrics & Gynecology: The Official Journal of the International Society of Ultrasound in Obstetrics and Gynecology*, *16*(4), 359–364. <http://doi.org/10.1046/j.1469-0705.2000.00182.x>
- Williamson, M. E., Lyons, K., & Hughes, L. E. (1993). Multiple fibroadenomas of the breast: a problem of uncertain incidence and management. *Annals of the Royal College of Surgeons of England*, *75*(3), 161–163.
- Wunderbaldinger, P., Wolf, G., Turetschek, K., & Helbich, T. H. (2002). Comparison of sitting versus prone position for stereotactic large-core breast biopsy in surgically proven lesions. *AJR. American Journal of Roentgenology*, *178*(5), 1221–1225. <http://doi.org/10.2214/ajr.178.5.1781221>
- Yilmaz, E., Sal, S., & Lebe, B. (2002). Differentiation of phyllodes tumors versus fibroadenomas. *Acta Radiologica (Stockholm, Sweden: 1987)*, *43*(1), 34–39.
- Zonderland, H. M., & Smithuis, R. (2013). The Radiology Assistant : Bi-RADS for Mammography and Ultrasound 2013. Retrieved January 28, 2016, from <http://www.radiologyassistant.nl/en/p53b4082c92130/bi-rads-for-mammography-and-ultrasound-2013.html>



## CURRICULUM VITAE

**ALISHA MAGDALENA SHERWANI**

alishams@bu.edu / aestivas@gmail.com | Birth Year: 1992

<b>CONTACT INFORMATION</b>	142A Redstone Hill Plainville CT, 06062 Home#: (860) 793-8557 Cell#: (860) 965-3201
<b>EDUCATION</b>	BOSTON UNIVERSITY, Boston, MA <b>Bachelor of Science in Human Physiology</b> , May 2014 BOSTON UNIVERSITY SCHOOL OF MEDICINE, Boston, MA <b>Masters of Science in Medical Sciences</b> , May 2016
<b>GENERAL EXPERIENCE</b>	<b>Sargent College Health Science Department</b> , Boston University, Boston, MA <u>Office Assistant</u> – September, 2010 to May 2014 <ul style="list-style-type: none"> <li>• Update student/faculty database, create advertising posters for upcoming seminars, research and maintain alumni relations and contact, trouble-shoot various software/hardware issues for members of the office, fax/copy/shred documents, sort mail and various other miscellaneous office tasks.</li> </ul> <b>Boston University Biology Department</b> , Boston University, Boston, MA <u>Undergraduate Assistant</u> – January, 2013 to May 2013 <ul style="list-style-type: none"> <li>• Assisted the Teaching Fellow in order to provide help and guidance to the assigned lab’s students. Gave background seminar and teach how to perform lab procedures. Took part in an education course to learn techniques and methods to better instruct the students.</li> </ul>
<b>CLINICAL EXPERIENCE</b>	<b>Bristol Hospital, Ingraham Manor, Dementia Unit</b> Bristol, CT <u>Certified Nursing Assistant</u> – February 2016 to current <ul style="list-style-type: none"> <li>• Assist residents with activities of daily living, including feeding, showering, toileting and ambulation. Maintain a safe, interactive environment for residents in long-term care with dementia. Take resident vitals and report</li> </ul>

any changes in mental status or health to supervising nurse.

**Middlesex Hospital, Emergency Department, Middletown, CT**

Medical Scribe, Chief scribe -- May 2015 to current

- Documentation and medical chart completion at provider's discretion in accordance with ICD-10 for billing/coding. Keep tabs on radiology and lab orders, bringing critical results to the attention of the provider immediately. Misc. clerical tasks to improve the efficiency of the provider. Maintain quality and efficiency of other scribe staff, including weekly educational emails, monthly calls with supervisor and documentation regarding quality of the program

**Beth Israel Deaconess, Emergency Department, Boston, MA**  
Research Intern – January 2014 to May 2014 – 140 Hours

- Collect discarded blood and flu samples, centrifuge, and label and put them away into a freezer for further analysis. Screen patients in the ICU or ED for those that meet study criteria. Inputting study data into databases, collecting information for CRF forms and other misc. tasks assigned by the research teams.

**Boston Medical Center, Cardiac Rehabilitation, Boston, MA**  
Student Intern – September 2013 to December 2013 -- 320 Hours

- Take patient vitals, including: blood glucose, blood pressure, and pulse and EKG analysis. Educate patients following guidelines outlined by the American Heart Association for Rehabilitative care. Monitor exercise and adjust according to patient's abilities and limitations. Instruct on proper form and management for strength training.

**Manchester Family Care, Wethersfield, CT**

Student Intern/Shadow – July 2013 to August 2013 – 120 Hours

- Assisted medical assistants with administrative and lab analysis (urine, blood). Took patient vitals and triaged to see the doctor. Assisted physician with preparing injections, patient documentation, various clinical procedures and observed overall patient visit.

	<p><b>Brigham and Women’s Hospital</b>, Boston, MA  <u>Medical Career Exploration Program Participant</u> – August 2012 to September 2013 – 60 Hours</p> <ul style="list-style-type: none"> <li>Worked as a patient ambassador to assist with directions and escorting patients to and from their rooms to either discharge them or move them to another area of the hospital. Delivered and received organic specimens such as blood transfusions and urine samples to and from the main laboratory to a patient’s room.</li> </ul> <p><b>The Hospital of Central Connecticut</b>, New Britain, CT  <u>Nurse Concierge/Patient Ambassador</u> – May 2012 to August 2012 – 40 Hours</p> <ul style="list-style-type: none"> <li>Assisted with overall paperwork for patient death or discharge, assisted nurses for basic procedures and accommodated patients and relatives with whatever was required.</li> </ul>
<b>ACTIVITIES</b>	<p><b>Boston University</b>, Boston, MA</p> <ul style="list-style-type: none"> <li><b>Organization of Pakistani Students</b>, <u>Treasurer 2011-2012, Secretary 2012-2014</u>: A cultural group that strives to make a comfortable and interactive environment for students both of Pakistani descent and not. Serves as a social hangout spot that also occasionally holds fundraisers or other events to raise awareness of the country and its culture.</li> <li><b>MISHAAL</b>, <u>Secretary 2011-2012, Treasurer 2012-2013</u>: A student group who is dedicated to fundraising in order to raise money for various non-profit organizations to improve education for children in South Asia.</li> <li><b>Global Medical Brigades</b>, <u>Member/Brigader 2011-2014</u>. Attended a brigade in January; went to Honduras to provide free medical/dental services in a small clinic. Collect medications, funds and medical professionals to attend the brigade along with us throughout the school year.</li> </ul>
<b>CERT-IFICATIONS</b>	<ul style="list-style-type: none"> <li><b>CPR</b> certified by the <b>American Red Cross</b></li> <li><b>CNA</b> certification per the <b>State of Connecticut</b></li> </ul>