

## RVC OPEN ACCESS REPOSITORY – COPYRIGHT NOTICE

This is the peer-reviewed, manuscript version of an article published in *Veterinary Record*. The final version is available online via <http://dx.doi.org/10.1136/vr.j5449>.

The full details of the published version of the article are as follows:

TITLE: Differentiating between food bloat and gastric dilatation and volvulus in dogs

AUTHORS: Karen Humm, MA, VetMB, MSc, CertVA, DACVECC, DipECVECC, FHEA, MRCVS and Dominic Barfield, BSc, BVSc, MVetMed, DACVECC, DECVECC, FHEA, MRCVS

JOURNAL TITLE: *Veterinary Record*

PUBLISHER: BMJ Publishing Group

PUBLICATION DATE: 24 November 2017 (online)

DOI: 10.1136/vr.j5449

## Clinical importance to practitioners

- GDV and GD due to food engorgement cannot be differentiated by presentation and/or blood results. A right lateral abdominal radiograph is required for diagnosis (see Figure 1)
- Simple medical therapy with analgesia and fluid therapy is generally sufficient for dogs with GD due to food engorgement. Trying to decompress the stomach with a stomach tube risks aspiration.
- The prognosis for dogs with food engorgement is excellent.

Gastric dilatation and volvulus (GDV) is a surgical emergency in dogs which has been extensively studied, with virtually all aspects of patient management reviewed and examined. Breed predisposition (Evans and Adams, 2010), risk factors for development of the condition (Sartor and others, 2013; Pipan and others, 2012) including specific allele genetic analysis (Harkey and others, 2017), the association between lactate and other biomarkers and outcome (Beer and others, 2013; Israeli and others, 2012; Green and others, 2011; Zacher and others, 2010; Adamik and others, 2009), diagnostic imaging findings (Tomlinson and others, 2016), the use of different drug and fluid therapies alongside surgery (Bruchim and others, 2012; Haak and others, 2012) and even analysis of the composition of the gas within the stomach of the GDV patient (Van Kruiningen and others, 2013) are just some of the topics that have been researched. Canine food engorgement, also often referred to as food bloat, causes gastric dilatation and fairly similar presenting clinical signs to GDV. However, it is much less well described in the veterinary literature despite being, anecdotally a fairly common presentation to first opinion veterinary practitioners.

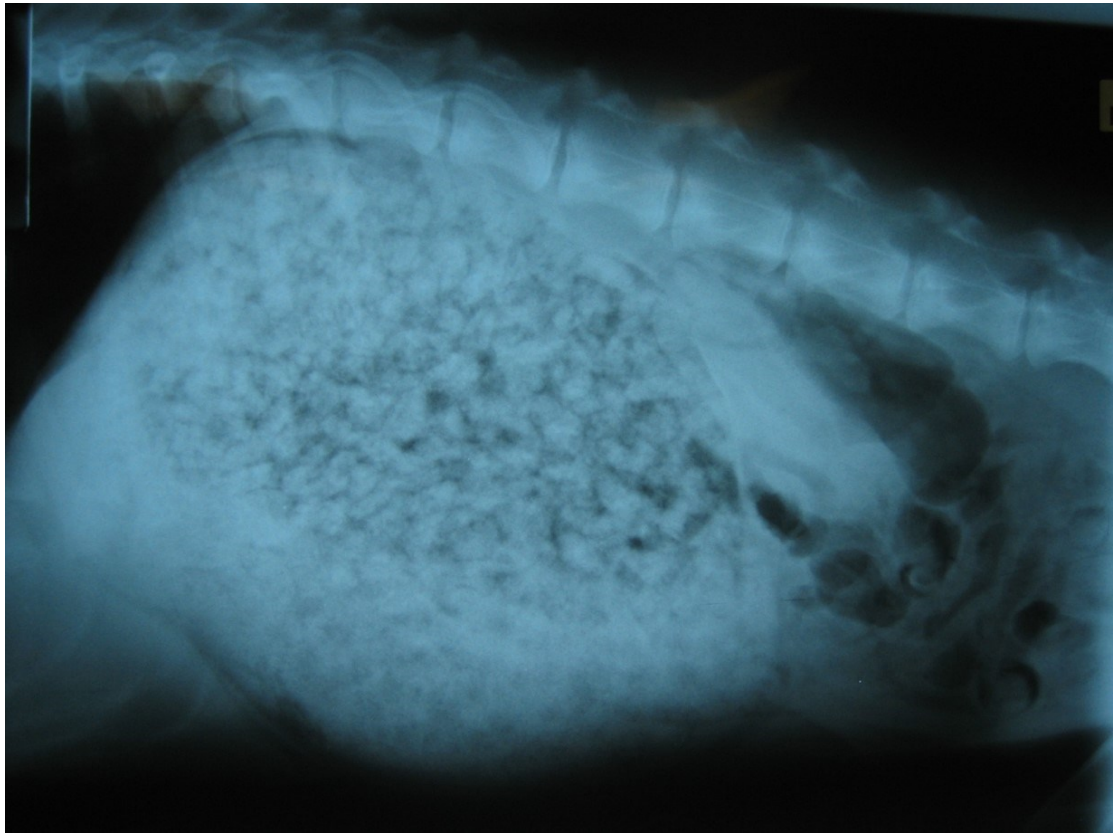
In a study by Brockman and others (1995), gastric dilation (GD) was considered alongside GDV and the mortality of the GD patients was found to be 0.9% compared to 15% for the GDV patients (although the GD group did include some dogs where it was unproven whether volvulus was present or not). In this study it was unclear whether the GD patients had stomach dilation due to air or food. In this issue of *The Veterinary Record* Dr Smart and colleagues have presented an interesting retrospective study regarding dogs with gastric dilation due to food engorgement, providing information on their presentation, diagnostic test findings, treatment and outcome. They compare their findings in the food engorgement dogs to a population of dogs presenting with GDV allowing differences and similarities between these patient groups to be explored. A novel and useful method of measuring gastric distension is described which, as well as being useful for this study, may well have a role in future studies. This method highlighted that GD secondary to food engorgement can be marked and, although the average caudal margin of the stomach was not as caudally displaced as that of GDV patients, there was a large degree of overlap between the two patient groups. Interestingly, Dr Smart and colleagues found that in food engorgement patients, the degree of gastric dilation was not associated with increased blood lactate concentration, unlike their findings in GDV patients, and they suggest that GD secondary to food engorgement, unlike GDV, does not significantly compromise oxygen delivery to the tissues (Smart and others, 2017).

There were marked similarities between the food engorgement and the GDV patient populations. Both were primarily made up of large breed dogs, with German

shepherd dogs, rottweilers and Labrador retrievers being noted as breeds represented more than once in each group. Abdominal distension was commonly noted on physical examination of the food engorgement dogs, and although its frequency is not noted for the GDV dogs, it is safe to assume this was also true for this population. Tachycardia and tachypnoea were also often present in both groups, though the tachycardia was, on average, more severe in the GDV patients. Even the historical finding of food engorgement may not be helpful in differentiating the two groups, given that only 11/35 owners of the food engorgement dogs in this study noted missing food and that dogs that eat rapidly have been shown to be predisposed to GDV (Glickman and others, 1997). Certainly, the initial blood work described by Smart and others (2017), although interesting, and revealing some statistically significant differences between the groups, cannot aid the clinician in differentiating the two disease processes. This means determining whether a dog has a surgical condition requiring expensive treatment, a GDV, or whether much simpler therapy is all that is required as they have a GD secondary to food engorgement, is not possible without appropriate diagnostic testing i.e. a right lateral abdominal radiograph.

The treatment of the food engorgement patients in this study was not uniform. In some cases emesis was induced, or gastric lavage performed. It would be useful to have a clinical understanding of the decision making for why differing treatment methods were used, but this is difficult in a retrospective study. The authors comment however that they feel that more conservative therapy consisting of analgesia and fluid therapy is generally sufficient for these patients. Given this was the case for 24 of the 35 dogs, and all 35 survived to discharge, this advice seems sensible. A concern that dogs affected by GD due to food engorgement may be predisposed to GDV is not supported by this study, as none of the affected dogs were found to develop GDV when follow up was performed. However, the follow up sample size was small (12 of the 35 dogs) and the follow up time fairly short (2-3 years), so it may be that a predisposition is present, but was not detected. It is also worth noting that of the 35 dogs with food engorgement, one had previously been diagnosed with this disease and in the follow up telephone calls to 12 owners a further 3 dogs had had a repeat food engorgement episode. This shows that some dogs (and owners) do not learn from their prior behaviour!

FIG 1: Right lateral abdominal radiographs showing gastric dilation due to food engorgement and due to gastric dilatation and volvulus (GDV). The GDV can be recognised by the compartmentalisation of the stomach shown by the arrow



## References

Adamik, K. N., Burgener, I. A., Kovacevic, A., Schulze, S. P. and Kohn, B. (2009), Myoglobin as a prognostic indicator for outcome in dogs with gastric dilatation-volvulus. *Journal of Veterinary Emergency and Critical Care*, 19: 247–253.

[Evaluation of plasma lactate concentration and base excess at the time of hospital admission as predictors of gastric necrosis and outcome and correlation between those variables in dogs with gastric dilatation-volvulus: 78 cases \(2004-2009\).](#)

Beer KA, Syring RS, Drobatz KJ.  
*J Am Vet Med Assoc.* 2013 ;242(1):54-8

Brockman, D. J., Washabau, R. J., & Drobatz, K. J. (1995). Canine gastric dilatation/volvulus syndrome in a veterinary critical care unit: 295 cases (1986-1992). *Journal of the American Veterinary Medical Association*, 207(4), 460-464.

[Evaluation of lidocaine treatment on frequency of cardiac arrhythmias, acute kidney injury, and hospitalization time in dogs with gastric dilatation volvulus.](#)

Bruchim Y, Itay S, Shira BH, Kelmer E, Sigal Y, Itamar A, Gilad S.  
*J Vet Emerg Crit Care* 2012 22(4):419-27

[Mortality and morbidity due to gastric dilatation-volvulus syndrome in pedigree dogs in the UK.](#)

Evans KM, Adams VJ.  
*J Small Anim Pract.* 2010 51(7):376-81

[J Am Anim Hosp Assoc.](#) 1997 May-Jun;33(3):197-204.

**Multiple risk factors for the gastric dilatation-volvulus syndrome in dogs: a practitioner/owner case-control study.**

[Glickman LT<sup>1</sup>](#), [Glickman NW](#), [Schellenberg DB](#), [Simpson K](#), [Lantz GC](#).

Green, T. I., Tonozzi, C. C., Kirby, R. and Rudloff, E. (2011), Evaluation of initial plasma lactate values as a predictor of gastric necrosis and initial and subsequent plasma lactate values as a predictor of survival in dogs with gastric dilatation-volvulus: 84 dogs (2003–2007). *Journal of Veterinary Emergency and Critical Care*, 21: 36–44. doi:10.1111/j.1476-4431.2010.00599.x

[Comparison of Hb-200 and 6% hetastarch 450/0.7 during initial fluid resuscitation of 20 dogs with gastric dilatation-volvulus.](#)

Haak CE, Rudloff E, Kirby R.  
*J Vet Emerg Crit Care (San Antonio).* 2012 Apr;22(2):201-10

[Associations between gastric dilatation-volvulus in Great Danes and specific alleles of the canine immune-system genes DLA88, DRB1, and TLR5.](#)

Harkey MA, Villagran AM, Venkataraman GM, Leisenring WM, Hullar MAJ, Torok-Storb BJ.  
*Am J Vet Res.* 2017 Aug;78(8):934-945

[Serum pepsinogen-A, canine pancreatic lipase immunoreactivity, and C-reactive protein as prognostic markers in dogs with gastric dilatation-volvulus.](#)

Israeli I, Steiner J, Segev G, Kass PH, Suchodolski JS, Sattasathuchana P, Bruchim Y, Yudelevitch S, Aroch I.  
J Vet Intern Med. 2012 Jul-Aug;26(4):920-8.

[An Internet-based survey of risk factors for surgical gastric dilatation-volvulus in dogs.](#)

Pipan M, Brown DC, Battaglia CL, Otto CM.  
J Am Vet Med Assoc. 2012

[Association between previous splenectomy and gastric dilatation-volvulus in dogs: 453 cases \(2004-2009\).](#)

Sartor AJ, Bentley AM, Brown DC.  
J Am Vet Med Assoc. 2013 May 15;242(10):1381-4.

Smart, L., Reese, S., Hosgood, G. (2017) Food engorgement in 35 dogs (2009–2013) compared with 36 dogs with gastric dilation and volvulus *Veterinary Record*

[Pyloric localisation in 57 dogs of breeds susceptible to gastric dilatation-volvulus in the UK using computed tomography.](#)

Tomlinson AW, Lillis SM, German AJ, Burrow RD.  
Vet Rec. 2016 Dec 17;179(24):626.

[Stomach gas analyses in canine acute gastric dilatation with volvulus.](#)

Van Kruiningen HJ, Gargamelli C, Havier J, Frueh S, Jin L, Suib S.  
J Vet Intern Med. 2013 Sep-Oct;27(5):1260-1.

[Association between outcome and changes in plasma lactate concentration during presurgical treatment in dogs with gastric dilatation-volvulus: 64 cases \(2002-2008\).](#)

Zacher LA, Berg J, Shaw SP, Kudej RK.  
J Am Vet Med Assoc. 2010 Apr 15;236(8):892-7