

Successful Intervention for Descending Necrotizing Mediastinitis : A Case Report

Akira Isaka,¹ Kiyohiro Oshima,¹ Hiroshi Hinohara,¹
Yoshiro Hayashi¹ and Fumio Kunimoto¹

Descending necrotizing mediastinitis (DNM) is a rare, however, highly fatal disease originating from odontogenic, pharyngeal, or cervical infectious sources that descend along facial planes into the mediastinum. We report a case who underwent surgical drainage using a mediastinoscope for the treatment of DNM and had successful postoperative course. Cervicothoracic CT should be performed immediately for diagnosis and for evaluating the extent of infection and necrosis, and effective drainage and debridement with suitable approach is required as soon as possible if DNM is suspected. (Kitakanto Med J 2006 ; 56 : 241~244)

Key Words : Descending necrotizing mediastinitis, Surgical management, Mediastinoscopy

Introduction

Descending necrotizing mediastinitis (DNM) is one of the most dangerous intrathoracic/mediastinal infections and is caused by odontogenic or cervicofacial infections or cervical trauma.^{1,2} In a case of DNM, an infection descends along the deep cervical facial space, causing cellulitis, necrosis, and abscess formation in the mediastinum ; often, the local/regional infection progresses to sepsis.² It has already been reported that the mortality rate of DNM is high, ranging from 20 to 50%.³⁻⁵ Early drainage and intensive care after drainage are important for survival. While successful surgical treatment of DNM has been increasingly reported, the strategy for treatment of DNM remains unclear and controversial.⁶ Herein, we report a patient who underwent surgical drainage using a mediastinoscope immediately after the diagnosis of DNM, followed by a successful postoperative course.

Case

A 70-year old female, who had diabetes mellitus with well controlled blood glucose (<200mg/dl) and HbA1c (about 6.0%), complained of pharyngodynia and dysphagia. She visited a hospital, where chest X-ray examination confirmed an expansion of the

mediastinum. The white blood cell (WBC) count and c-reactive protein (CRP) level increased to 15,200/mm³ and 23.1mg/dl, respectively. Cervicothoracic computed tomography (CT) performed in the hospital revealed a retropharyngeal abscess descending into the upper and the anterior mediastinum, above the tracheal bifurcation (Fig. 1). There was no finding of bilateral thoracic empyema. The patient was diagnosed with descending mediastinitis, and was immediately transferred to our hospital because an emergency operation and postoperative intensive care were necessary.

The emergent operation was performed by a team of thoracic surgeons and otolaryngologists. A U-shaped incision was made on her neck under general anesthesia. After the anterior cervical muscles were transversely incised, a large quantity of pus was discharged. Finger dissection around the thyroid cartilage, cricoid cartilage and trachea was performed, and a substantial amount of pus and necrotizing tissue were discharged. The posterior pharyngeal space was also drained. The connective tissue around the trachea was dissected toward the tracheal bifurcation, and then a video-assisted mediastinoscope was inserted to mediastinum. The capsule covering abscess was easily recognized and was ruptured under direct observation via the mediastinoscope. A large quantity of additional

¹ Intensive Care Unit, Gunma University Hospital, 3-39-15 Showa-machi, Maebashi, Gunma 371-8511, Japan

Received : March 20, 2006

Address : KIYOHIRO OSHIMA Intensive Care Unit, Gunma University Hospital 3-39-15 Showa-machi, Maebashi, Gunma 371-8511, Japan

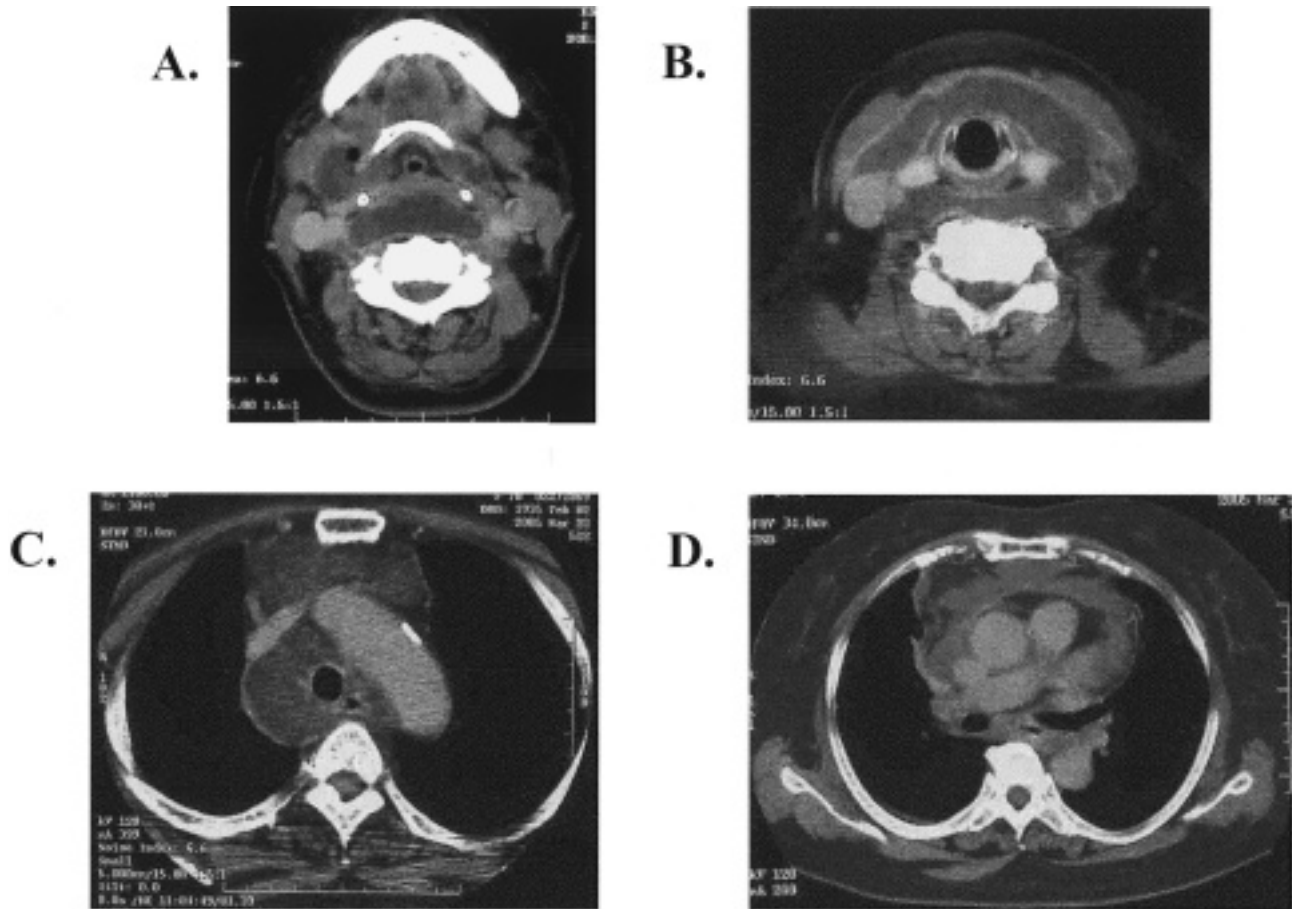


Fig. 1 CT scan from neck to chest before operation. Retropharyngeal abscess (A), deep neck abscess (B), and anterior mediastinum (C) were confirmed, however, abscess did not extend posterior mediastinum and below the tracheal bifurcation (D).

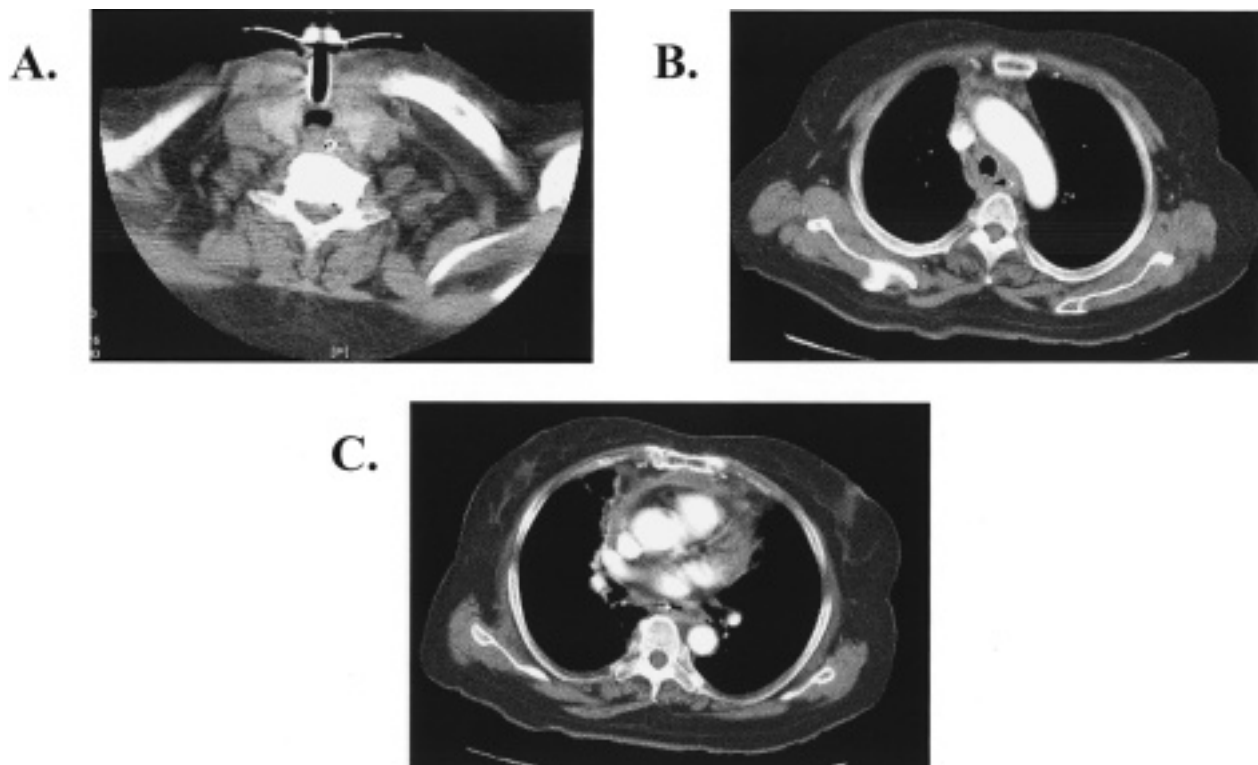


Fig. 2 CT from neck to chest at postoperative day 21. Abscess in neck and anterior mediastinum was almost disappeared.

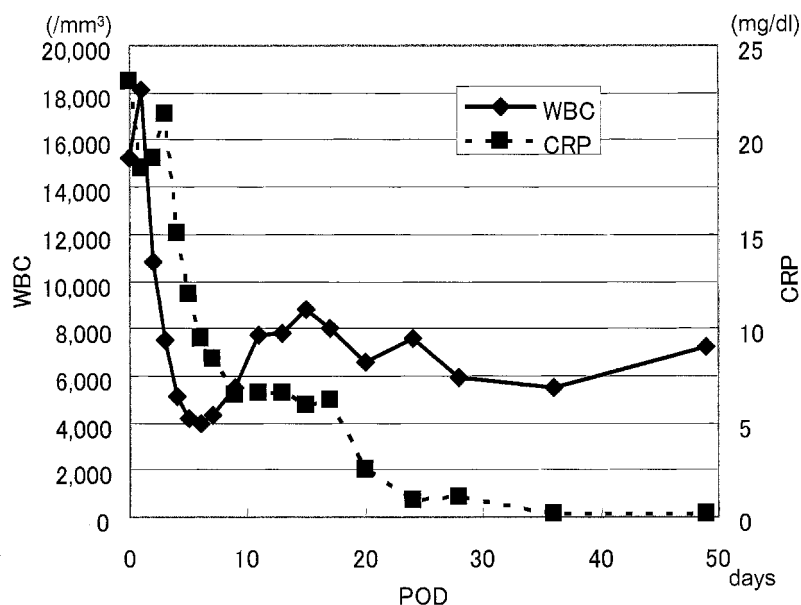


Fig. 3 The changes of WBC and CRP

pus was discharged. The capsule was removed and the remaining pus was drained. Following drainage, both the deep neck and mediastinum were irrigated with 1000 ml of a saline solution. Finally, two drains were installed around the trachea bilaterally, and two drains were installed bilaterally in the mediastinum. A thoracheostomy was also performed. The operative time and blood loss were 180 minutes and 303ml, respectively.

After the operation, the patient was transferred to intensive care unit (ICU). Daily irrigation with saline solution was performed via the mediastinal drainage tubes. The patient also received the adequate spectrum intravenous antibiotics on the basis of the culture results (*Bacteroides* was detected in intraoperative specimen). Respiratory support was required postoperatively. However, the patient's respiratory condition gradually improved, and the respirator was removed on post-operative day (POD) 5. Enteral nutrition was started on POD 4. The patient was discharged from the ICU to a normal ward on POD 7. On POD 11, a cervicothoracic CT scan revealed that the descending abscess was well drained and had almost disappeared (Fig. 2). The irrigation was finished and all drainage tubes in neck and mediastinum were removed on POD 17. The normal ingestion was initiated on POD 24. WBC count and CRP gradually decreased returning almost to the normal range by POD 30 (Fig. 3). The thoracheostomy was closed and the patient was discharged from our hospital on POD 51.

Discussion

The clinical aspects of a treatment strategy for DNM are sufficient debridement, adequate drainage, and effective irrigation.⁴ Endo and coworkers⁷ classified DNM into three groups on the basis of infection extension of DNM as diagnosed by CT, and suggested differential surgical management according to this classification: Type I, infection localized in the upper mediastinum above the tracheal bifurcation; Type IIA, infection extending to the lower anterior mediastinum; and type IIB, infection extending to the anterior and lower posterior mediastinum. They recommended transcervical drainage, or subxiphoid mediastinal drainage, or both as the treatment strategy for type I and IIA, and complete irrigation and debridement of the entire mediastinum as the treatment strategy for type IIB. According to this classification scheme, our case is classifying DNM type IIA, and the effective drainage and debridement could be accomplished by transcervical approach using a mediastinoscope because abscess had not extended to the lower posterior mediastinum. The postoperative evaluation of abscess with neck and chest CT should be required to detect residual abscess. If DNM extends to the posterior and lower mediastinum and/or empyema occurs, transcervical approach is not enough and complete mediastinal drainage should be necessary. In our case, a postoperative cervicothoracic CT scan revealed that the descending abscess was well drained and had almost disappeared.

Recently, the usefulness of thoracoscopic exploration for the surgical management of patients with

DNM has been reported.^{8,9} They insist that the thoracoscopic approach is minimally invasive and a feasible and effective method for the surgical management of patients with DNM, especially when applied early. However, the effectiveness of thoracoscopic exploration for DNM localized to the upper or anterior mediastinum or both (type I and IIA) is still unclear because thoracoscopic exploration can provide effective drainage for DNM, however, after the mediastinal pleura has been opened, cervical pus readily descends into the pleural cavity through the mediastinum and then residual empyema can occur.¹⁰ Endo and his coworkers¹¹ insisted that thoracoscopic irrigation should be the optimal treatment when DNM involves the posterior and lower mediastinum. In addition, Marty-Ane and colleagues reported that the transcervical approach may be adequate if infection involves the superior mediastinum above the level of the carina.¹⁰ Taking our case into consideration, we also thought that transcervical approach assisted with mediastinoscope is adequate method for the treatment of DNM if DNM is type I or IIA.

In conclusion, if DNM is suspected, cervicothoracic CT should be performed immediately for diagnosis and for evaluating the extent of infection and necrosis, and effective drainage and debridement with adequate approach is required as soon as possible.

References

1. Sancho LMM, Minomoto H, Fernandez A, et al. Descending necrotizing mediastinitis: A retrospective surgical experience. *Eur J Cardiothoracic Surg* 1999; 16: 200-205.
2. Stella F, Petrella F. Transsternal transpericardial approach for acute descending necrotizing mediastinitis. *J Thorac Cardiovasc Surg* 2005; 129: 212-214.
3. Karnath B, Siddiqi A. Acute mediastinal widening. *South Med J* 2002; 95: 1222-1225.
4. Iwata T, Sekine Y, Shibuya K, et al. Early open thoracotomy and mediastinopleural irrigation for severe descending necrotizing mediastinitis. *Eur J Cardiothorac Surg* 2005; 23 [Epub ahead of print].
5. Freeman RK, Vallieres E, Verrier ED, et al. Descending necrotizing mediastinitis: an analysis of the effects of serial surgical debridement on patient mortality. *J Thorac Cardiovasc Surg* 2000; 119: 260-267.
6. Hirai S, Hamanaka Y, Mitsui N, et al. Surgical treatment of virulent descending necrotizing mediastinitis. *Ann Thorac Cardiovasc Surg* 2004; 10: 34-38.
7. Endo S, Murayama F, Hasegawa T, et al. Guideline surgical management based on diffusion of descending necrotizing mediastinum. *Jpn J Thorac Cardiovasc Surg* 1999; 47: 14-19.
8. Min H-K, Choi YS, Shim YM, et al. Descending necrotizing mediastinitis: A minimally invasive approach using video-assisted thoracoscopic surgery. *Ann Thorac Surg* 2004; 77: 306-310.
9. Isowa N, Yamada T, Kijima T, et al. Successful thoracoscopic debridement of descending necrotizing mediastinitis. *Ann Thorac Surg* 2004; 77: 1834-1837.
10. Marty-Ane CH, Alauzen M, Alric P, et al. Descending necrotizing mediastinitis. Advantage of mediastinal drainage with thoracotomy. *J Thorac Cardiovasc Surg* 1994; 107: 55-61.
11. Endo S, Hasegawa T, Sato Y, et al. Is video-assisted thoracoscopic surgery an optimal approach for descending necrotizing mediastinitis? *Ann Thorac Surg* 2005; 79: 751.