

STUDY OF FEASIBILITY OF LAPAROSCOPIC INGUINAL HERNIA

SURGERY IN TAIPING HOSPITAL

BY

DR HASSLINDA BINTI ABU HASSAN

M.D (UNIMAS)

**DISSERTATION SUBMITTED IN PARTIAL FULFILLMENT OF THE
REQUIREMENT OF MASTERS OF MEDICINE (GENERAL SURGERY)**

UNIVERSITI SAINS MALAYSIA

2010

II . ACKNOWLEDGEMENTS

I wish to express my sincere thanks, gratitude and appreciation to the following individuals, without whom my dissertation would have not been possible:

School of Medical Sciences, University Sains Malaysia and Department of Surgery, Hospital Universiti Sains Malaysia (HUSM), Kubang Kerian for granting me the approval to proceed with the study.

Dr Syed Hassan Syed Aziz ,my supervisor for his guidance, beneficial advice and assistant to ensure successful completion of this dissertation.

Dr Zulkarnain Hasan, my co-supervisor for his patience, guidance and encouragement on helping me to complete this study.

Dr Zainal Mahamood, the previous Head of Department of Surgery, our current Head Dr Mohd Nor Gohar Rahman and all the lecturers in Department of Surgery, HUSM for their continuous support and encouragement.

Prof Dr Syed Hatim for his knowledge and guidance in statistics and analysis.

Dr. Vimal K.Vasudeavan and Dr Umasangar Ramasamy, my field supervisor and co-supervisor in Hospital Taiping whom has given undivided attention and support, supervision and assistant in the preparation of this study and throughout the duration of the program.

Not forgotten, my colleagues from Hospital Taiping, Dr Satkunan Mark and Dr Calvin Dinash for helping me with the data collection, patient recruitment and follow up of the case study.

My course mates, Dr Nik Marila, Dr Ismazizi, Dr Syauki and Dr Ainilhayat for their great assistance and encouragement upon completing these hard tasks.

My special thanks to my very understanding husband Encik Zainal Abidin for his sacrifice, continuous love, patience, courage and support.

My beloved mother, Puan Serbiah Saaid and family for their continuous care, reassurance, physical and spiritual support throughout the time I am away home.

Last but not least, the great motivator of my journey in this program, my late father Tuan Haji Abu Hassan bin Osman whom has given me his undivided love and care until his last breath. His spirit is in my every breath. May he will be peacefully stayed with Allah and blessed with our prayers.

Finally, all my other lecturers and collagues whom have indirectly contributed to the completion of this hard job.

DR HASSLINDA ABU HASSAN

TABLE OF CONTENTS

CONTENTS

I FRONTOSPIECE	i
II ACKNOWLEDGEMENTS	ii
III TABLE OF CONTENTS	iv
IV LIST OF FIGURES AND TABLES	viii
V LIST OF ABBREVIATIONS	xi
VI ABSTRAK	xii
VII ABSTRACT	xv
1.0 INTRODUCTION TO INGUINAL HERNIA	1
2.0 LITERATURE REVIEW	4
2.1 HISTORY OF INGUINAL HERNIA REPAIR	
2.1.1 EVOLUTION OF OPEN INGUINAL HERNIA REPAIR	4
2.1.2 EVOLUTION OF LAPAROSCOPIC INGUINAL HERNIA REPAIR	12
2.2 EMBRYOLOGY OF INGUINAL REGION	13
2.2.1 DEVELOPMENT OF INGUINAL CANAL	13
2.2.2 GONADAL GENESIS	14
2.3 ANATOMY OF INGUINAL CANAL	16
2.3.1 INGUINAL CANAL	17
2.3.2 INGUINAL HERNIA	20
2.3.2.1 INDIRECT INGUINAL HERNIA	26
2.3.2.2 DIRECT INGUINAL HERNIA	27

2.4	PHYSIOLOGY OF INGUINAL REGION	27
2.5	CLASSIFICATION OF INGUINAL HERNIA	28
2.6	APPROACH OF INGUINAL HERNIA REPAIR	33
2.7	ANAESTHESIA IN INGUINAL HERNIA REPAIR	40
2.8	COMPLICATIONS OF INGUINAL HERNIA SURGERY	44
2.8.1	INFECTION	44
2.8.2	SEROMA	44
2.8.3	HEMATOMA	45
2.8.4	POSTOPERATIVE NEURALGIA	45
2.9	LAPAROSCOPIC INGUINAL HERNIA SURGERY	49
2.9.1	INTRODUCTION	49
2.9.2	INDICATIONS OF LAPAROSCOPIC INGUINAL HERNIA REPAIR	50
2.9.3	CONTRAINDICATIONS OF LAPAROSCOPIC INGUINAL HERNIA REPAIR	52
2.9.4	ADVANTAGES OF LAPAROSCOPIC INGUINAL HERNIA REPAIR	52
2.9.5	TYPES OF OF LAPAROSCOPIC INGUINAL HERNIA REPAIR	53
2.9.6	PATIENTS SELECTION AND PREPARATION	54
2.9.7	PROCEDURE REQUIREMENT	55
2.9.7.1	OPERATING ROOM SETUP	55
2.9.7.2	INSTRUMENT REQUIREMENT	55
2.9.7.3	MESH	56
2.9.7.4	FIXATION DEVICES	58
2.9.8	LAPAROSCOPIC ANATOMY	59
2.9.9	TECHNIQUES OF TAPP	68
2.9.9.1	PNEUMOPERITONEUM	69
2.9.9.2	PORT PLACEMENT	71
2.9.9.3	PREPERITONEAL SPACE CREATION	71
2.9.9.4	MEDIAL AND LATERAL DISSECTION	72
2.9.9.5	SAC IDENTIFICATION AND DISSECTION	72
2.9.9.6	PLACEMENT OF MESH	73
2.9.9.7	CLOSURE OF PERITONEUM	74
2.9.10	REPAIR OF BILATERAL INGUINAL HERNIA	74
2.9.11	REPAIR OF RECURRENT INGUINAL HERNIA	75
2.9.12	ENDING OF OPERATION	75
2.9.13	COMPLICATIONS OF LAPAROSCOPIC INGUINAL HERNIA REPAIR	76

3.0 OBJECTIVES OF THE STUDY	80
3.1 GENERAL OBJECTIVE	80
3.2 SPECIFIC OBJECTIVE	80
4.0 DEFINITIONS	81
5.0 PERIOPERATIVE ASSESSMENT AND PATIENT PREPARATION	82
6.0 MATERIALS AND METHODOLOGY	83
6.1 STUDY DESIGN	83
6.2 PATIENTS SELECTION	83
6.3 OPERATIVE PROCEDURE	84
6.4 PERFORMA	85
6.5 FOLLOW UP	86
6.6 EVALUATION OF OUTCOME	86
7.0 VARIABLES	87
7.1 STATISTICAL ANALYSIS	87
8.0 RESULTS	
8.1 SOCIODEMOGRAPHIC PARAMETERS	88
8.2 HERNIA CHARACTERISTIC	88
8.3 INTRAOPERATIVE DATA	88
8.4 POSTOPERATIVE DATA	89
8.5 FOLLOW UP DATA	89
9.0 DISCUSSION	96
9.1 INTRODUCTION	96
9.2 SOCIODEMOGRAPHIC DATA	97
9.3 HERNIA CHARACTERISTIC	98
9.4 INTRAOPERATIVE REVIEW	99
9.5 POSTOPERATIVE REVIEW	101
9.6 FOLLOW UP REVIEW	102
10.0 STUDY LIMITATION	106
11.0 RECOMMENDATION	107
12.0 CONCLUSION	108

13.0 REFERENCES	109
APPENDIX 1	114
APPENDIX 2	123
APPENDIX 3	127
APPENDIX 4	132
APPENDIX 5	135

LIST OF FIGURES AND TABLES

FIGURES/TABLES	TITLES	PAGE
Table 1	Milestones in Hernia Repair: The Listerian Era	5
Table 2	Characteristics of an Ideal Prosthesis	8
Fig. 1	Lichtenstein onlay patch. Mesh is sutured from the transverses arch to the shelving edge of inguinal ligament creating a “tension-free” repair.	10
Fig. 2	Kugel Patch.”Race-track” oval shaped Polypropylene mesh graft with pocket for insertion and larger gauge polypropylene ring to hold graft`s flat shape.	11
Fig. 3	Anterior Abdominal Wall Anatomy	22
Fig. 4	Anatomy of Iinguinal Canal	23
Fig. 5	Hesselbach`s Triangle	24
Fig. 6	Route of indirect hernia	24
Fig. 7	Route of direct hernia	25
Fig. 8	Anatomy of the pelvis and inguinal trigone	25
Table 3	Physiology of inguinal region and mechanism Preventing hernia occurrence	29
Table 4	Nyhus classification of groin hernia	32
Fig. 9	Mc Vay open anterior repair	34

Fig. 10	Open mesh repair	36
Fig. 11	laparoscopic mesh repair, viewed from inside the pelvis toward the direct and indirect sites	39
Table 5	ASA classifications	43
Fig.12	Evacuation of hematoma with clots 4 hours after the operation	47
Table 6	Complications of Open and Laparoscopic Hernia Repair	48
Table 7	Indications for repair techniques (TAPP,TEP,Open)	51
Fig. 13	Placement of laparoscopic port in laparoscopic inguinal hernia repair	61
Fig.14	OT Setting and port placement	62
Fig. 15	Inguinal anatomy from the laparoscopic Viewpoint	63
Fig 16	Triangle of Pain	66
Fig. 17	Triangle of Doom	67
Fig.18	(a)Trocar and (b) Veress needle use in LIHR	70
Table 8	Intraoperative complications	79
Table 9	Postoperative complications	80
Table 10	Socio-demographic parameters	91
Table 11	Hernia characteristic	91

Fig.19	Percentage distribution of age group	92
Fig.20	Percentage distribution of duration Of symptoms prior to surgery	94
Fig.21	Duration of surgery	94
Fig.22	Percentage distribution for analgesia consumption	95

LIST OF ABBREVIATION

ASA	American Society of Anaesthesiology
CBD	Continous Bladder Drainage
COPD	Chronic Obstructive Pulmonary Disease
EOA	External Oblique Aponeurosis
GA	General Anaesthesia
HT	Hospital Taiping
HUSM	Hospital Universiti Sains Malaysia
IHR	Inguinal Hernia Repair
IPOM	Intra peritoneal Onlay Mesh
IV	Intravenous
LA	Local Anaesthesia
LIHR	Laparoscopic Inguinal Hernia Repair
LMA	Laryngeal Mask Airway
OHR	Open Hernia Repair
OT	Operation Theatre
PTFE	Polytetrafluoroethylene
RA	Regional Anaesthesia
TA	Transversus Abdominis
TAPP	Transabdominal Preperitoneal
TEP	Totally Extra Preperitoneal
TF	Transversalis Fascia
VAS	Visual Analogue Score

ABSTRAK

STUDY OF FEASIBILITY OF LAPAROSCOPIC INGUINAL HERNIA

SURGERY IN TAIPING HOSPITAL

Pengenalan

Sejarah pembedahan hernia inguinal telah melalui pelbagai fasa bermula dari zaman pra sejarah sehingga ke hari ini. Pembedahan hernia inguinal merupakan satu pembedahan yang sering dilakukan di seluruh dunia tanpa mengira latar belakang sosio-ekonomi sesebuah negara. Hari ini, seiring dengan perkembangan pesat pembedahan secara laparoscopi, ia menjadi satu kaedah pembedahan yang sangat menggalakkan untuk masalah hernia inguinal. Umum mengetahui komplikasi serta faedah dan keburukan pembedahan inguinal hernia secara laparoscopi. Namun, ia tetap diterima dan menjadi pilihan utama berbanding dengan pembedahan hernia inguinal secara kaedah terbuka.

Latar Belakang

Tujuan kajian ini dijalankan adalah untuk melihat kesesuaian pembedahan hernia inguinal kaedah laparoscopi secara 'Transabdominal Preperitoneal' (TAPP) di jalankan di Hospital Taiping. Ia turut menilai hasil akhir kaedah ini di samping melihat kepada masalah hernia berulang selepas pembedahan (recurrent).. Ia secara tidak langsung bertujuan mempertingkatkan kualiti perkhidmatan sedia ada di samping menghasilkan sebuah garis panduan untuk menjalankan rawatan ini secara 'day care' di masa akan datang.

Kaedah dan Keputusan

Jabatan Pembedahan Hospital Taiping, telah mula menawarkan pembedahan hernia inguinal secara laparoskopi sejak tahun 2004. Ia bermula dengan hanya seorang Pakar Bedah dan diikuti oleh beberapa Pakar Bedah yang berbeza latar belakang kemahiran dan penguasaan dalam bidang ini. Sejumlah 105 pesakit telah dikaji bermula dari bulan Januari 2009 hingga ke bulan Mac 2010. data yang berkaitan direkodkan dalam Performa dan dianalisa. Lelaki telah mendahului wanita dengan nisbah 16.5:1 dan bangsa Melayu adalah majoriti yang telah menjalani pembedahan ini iaitu seramai 71 orang. 59 pesakit mempunyai hernia 'indirect', 22 pesakit mempunyai hernia 'direct', 19 pesakit mempunyai kedua-dua hernia 'indirect' dan 'direct' dan 5 pesakit mempunyai hernia 'recurrent'. Terdapat 40 kes hernia sebelah kanan, 45 kes hernia sebelah kiri dan 20 kes hernia 'bilateral'. Kebanyakan pesakit mendapatkan rawatan selepas satu ke tiga tahun mengalami gejala-gejala hernia inguinal. Kesemua pesakit menjalani pembedahan ini secara bius penuh di mana 76 pesakit adalah dari kelas ASA(American Society of Anaesthesiology) II dan selebihnya dari ASA I. 79% pesakit telah dibedah dalam jangkamasa 1 ke 3 jam dan 74.3% tinggal di wad selama 2 ke 3 hari selepas pembedahan. 2 kes hernia 'recurrent' direkodkan di mana sebelum pembedahan kedua-duanya adalah hernia 'indirect'. 20 kes jangkitan luka pembedahan dikenalpasti pada peringkat awal rawatan susulan. Walaubagaimanapun, kesemuanya dirawat secara konservatif dan sembuh sepenuhnya pada rawatan susulan yang berikutnya. Daripada keseluruhan 53 pesakit yang bekerja, hanya 10 pesakit yang memerlukan lanjutan cuti sakit melebihi seminggu dan 52.4% mengambil analgesia selama kurang dari 48 jam.

KESIMPULAN

Kesimpulannya, komplikasi utama selepas pembedahan hernia inguinal secara laparoskopik dalam kajian ini adalah jangkitan luka dan hernia 'recurrent'. 'Recurrent' awal menggambarkan kemahiran dan kematangan Pakar Bedah. Namun, keperluan analgesia, tempoh tinggal di wad selepas pembedahan, lanjutan cuti sakit dan ketiadaan komplikasi-komplikasi lain selepas pembedahan selainn dari yang dinyatakan adalah signifikan (nilai $p < 0.05$). Ini menggambarkan bahawa pembedahan ini adalah sesuai dijalankan di Hospital Taiping

ABSTRACT

STUDY OF FEASIBILITY OF LAPAROSCOPIC INGUINAL HERNIA

SURGERY IN TAIPING HOSPITAL

INTRODUCTION

The history of inguinal hernia repair (IHR) has gone through many stages of development from the ancient era until today. Inguinal hernia repair is one of the commonest surgical procedure worldwide, irrespective of socioeconomic status or country. Today, with the advancement of laparoscopic surgeries, inguinal hernia has been listed as one of the preferred surgical condition repaired by laparoscopic approach. Nowadays, despite its known complications, advantages and disadvantages, Laparoscopic Inguinal Hernia Repair (LIHR) is widely accepted as the better option of treatment as compared to open approach of inguinal hernia repair (IHR).

Background

The purposes of this study is to look for the feasibility of Laparoscopy Inguinal Hernia Repair(LIHR) by Transabdominal preperitoneal (TAPP) done in Hospital Taiping. It is al to evaluate the outcome of the procedure and to look for recurrent. The aim is to improve the services available and to formulate a protocol looking into an opportunity of doing this surgery as a day care basis in future

Methods and Results

Surgical Department in Hospital Taiping has been offering Laparoscopic Inguinal Hernia Repair since 2004. It was started by a single surgeon, followed by other newcomers with different learning curve. A total of 105 patients have been studied from January 2009 to March 2010. Data related to this study is recorded in Performa and analyze upon completing the time phrame. The male leading the female with a ratio of 16.5:1 and Malays are the majority getting this procedure done with 71 candidates. 59 patients have indirect hernia, 22 patients have direct hernia, 19 patients have both direct and indirect hernia and 5 patients have recurrent hernia. There are 40 cases of right sided hernia, 45 cases of left sided hernia and 20 cases of bilateral inguinal hernia. Majority of the patients seek for treatment after 1 to 3 years of symptoms. All has undergone this elective procedure under general anesthesia. 76 patients are in ASAII with the remaining of ASA I. 79% of the patients were operated within one to two hours with 74.3% of postoperative ward stay of between two to three days. There were 2 cases of recurrent, which both were indirect type preoperatively. There were 20 cases of wound infection noted during the early review. However, all are managed conservatively and well on the subsequent review. Out of 53 patient documented as working, only 10 patients required medical certificate longer than one week and 52.4% of them took analgesia for less than 48 hours.

CONCLUSION

In summary, the commonest complication of LIHR were wound infection and recurrent. Early recurrent reflect the learning curve. However, analgesia requirement, length of ward stay ,prolongation of medical certificate and absence of other postoperative complications were significant (p value < 0.05) indicating that LIHR is feasible in Taiping Hospital.

ABSTRAK

STUDY OF FEASIBILITY OF LAPAROSCOPIC INGUINAL HERNIA SURGERY IN TAIPING HOSPITAL

PENGENALAN

Sejarah pembedahan hernia inguinal telah melalui pelbagai fasa bermula dari zaman pra sejarah sehingga ke hari ini. Pembedahan hernia inguinal merupakan satu pembedahan yang sering dilakukan di seluruh dunia tanpa mengira latar belakang sosio-ekonomi sesebuah negara. Hari ini, seiring dengan perkembangan pesat pembedahan secara laparoscopi, ia menjadi satu kaedah pembedahan yang sangat menggalakkan untuk masalah hernia inguinal. Umum mengetahui komplikasi serta faedah dan keburukan pembedahan inguinal hernia secara laparoscopi. Namun, ia tetap diterima dan menjadi pilihan utama berbanding dengan pembedahan hernia inguinal secara kaedah terbuka.

Latar Belakang

Tujuan kajian ini dijalankan adalah untuk melihat kesesuaian pembedahan hernia inguinal kaedah laparoscopi secara ‘Transabdominal Preperitoneal’ (TAPP) di jalankan di Hospital Taiping. Ia turut menilai hasil akhir kaedah ini di samping melihat kepada masalah hernia berulang selepas pembedahan (recurrent).. Ia secara

tidak langsung bertujuan mempertingkatkan kualiti perkhidmatan sedia ada di samping menghasilkan sebuah garis panduan untuk menjalankan rawatan ini secara 'day care' di masa akan datang.

Kaedah dan Keputusan

Jabatan Pembedahan Hospital Taiping, telah mula menawarkan pembedahan hernia inguinal secara laparoskopi sejak tahun 2004. Ia bermula dengan hanya seorang Pakar Bedah dan diikuti oleh beberapa Pakar Bedah yang berbeza latar belakang kemahiran dan penguasaan dalam bidang ini. Sejumlah 105 pesakit telah dikaji bermula dari bulan Januari 2009 hingga ke bulan Mac 2010. data yang berkaitan direkodkan dalam Performa dan dianalisa. Lelaki telah mendahului wanita dengan nisbah 16.5:1 dan bangsa Melayu adalah majoriti yang telah menjalani pembedahan ini iaitu seramai 71 orang. 59 pesakit mempunyai hernia 'indirect', 22 pesakit mempunyai hernia 'direct', 19 pesakit mempunyai kedua-dua hernia 'indirect' dan 'direct' dan 5 pesakit mempunyai hernia 'recurrent'. Terdapat 40 kes hernia sebelah kanan, 45 kes hernia sebelah kiri dan 20 kes hernia 'bilateral'. Kebanyakan pesakit mendapatkan rawatan selepas satu ke tiga tahun mengalami gejala-gejala hernia inguinal. Kesemua pesakit menjalani pembedahan ini secara bius penuh di mana 76 pesakit adalah dari kelas ASA(American Society of Anaesthesiology) II dan selebihnya dari ASA I. 79% pesakit telah dibedah dalam jangkamasa 1 ke 3 jam dan 74.3% tinggal di wad selama 2 ke 3 hari selepas pembedahan. 2 kes hernia 'recurrent' direkodkan di mana sebelum

pembedahan kedua-duanya adalah hernia 'indirect'. 20 kes jangkitan luka pembedahan dikenalpasti pada peringkat awal rawatan susulan. Walaubagaimanapun, kesemuanya dirawat secara konservatif dan sembuh sepenuhnya pada rawatan susulan yang berikutnya. Daripada keseluruhan 53 pesakit yang bekerja, hanya 10 pesakit yang memerlukan lanjutan cuti sakit melebihi seminggu dan 52.4% mengambil analgesia selama kurang dari 48 jam.

KESIMPULAN

Kesimpulannya, komplikasi utama selepas pembedahan hernia inguinal secara laparoskopik dalam kajian ini adalah jangkitan luka dan hernia 'recurrent'. 'Recurrent' awal menggambarkan kemahiran dan kematangan Pakar Bedah. Namun, keperluan analgesia, tempoh tinggal di wad selepas pembedahan, lanjutan cuti sakit dan ketiadaan komplikasi-komplikasi lain selepas pembedahan selainn dari yang dinyatakan adalah signifikan (nilai $p < 0.05$). Ini menggambarkan bahawa pembedahan ini adalah sesuai dijalankan di Hospital Taiping

ABSTRACT

STUDY OF FEASIBILITY OF LAPAROSCOPIC INGUINAL HERNIA SURGERY IN TAIPING HOSPITAL

INTRODUCTION

The history of inguinal hernia repair (IHR) has gone through many stages of development from the ancient era until today. Inguinal hernia repair is one of the commonest surgical procedure worldwide, irrespective of socioeconomic status or country. Today, with the advancement of laparoscopic surgeries, inguinal hernia has been listed as one of the preferred surgical condition repaired by laparoscopic approach. Nowadays, despite its known complications, advantages and disadvantages, Laparoscopic Inguinal Hernia Repair (LIHR) is widely accepted as the better option of treatment as compared to open approach of inguinal hernia repair (IHR).

Background

The purposes of this study is to look for the feasibility of Laparoscopy Inguinal Hernia Repair(LIHR) by Transabdominal preperitoneal (TAPP) done in Hospital Taiping. It is al to evaluate the outcome of the procedure and to look for recurrent. The aim is to improve the services available and to formulate a protocol looking into an opportunity of doing this surgery as a day care basis in future

Methods and Results

Surgical Department in Hospital Taiping has been offering Laparoscopic Inguinal Hernia Repair since 2004. It was started by a single surgeon, followed by other newcomers with different learning curve. A total of 105 patients have been studied from January 2009 to March 2010. Data related to this study is recorded in Performa and analyze upon completing the time phrame. The male leading the female with a ratio of 16.5:1 and Malays are the majority getting this procedure done with 71 candidates. 59 patients have indirect hernia, 22 patients have direct hernia, 19 patients have both direct and indirect hernia and 5 patients have recurrent hernia. There are 40 cases of right sided hernia, 45 cases of left sided hernia and 20 cases of bilateral inguinal hernia. Majority of the patients seek for treatment after 1 to 3 years of symptoms. All has undergone this elective procedure under general anesthesia. 76 patients are in ASAII with the remaining of ASA I. 79% of the patients were operated within one to two hours with 74.3% of postoperative ward stay of between two to three days. There were 2 cases of recurrent, which both were indirect type preoperatively. There were 20 cases of wound infection noted during the early review. However, all are managed conservatively and well on the subsequent review. Out of 53 patient documented as working, only 10 patients required medical certificate longer than one week and 52.4% of them took analgesia for less than 48 hours.

CONCLUSION

In summary, the commonest complication of LIHR were wound infection and recurrent. Early recurrent reflect the learning curve. However, analgesia requirement, length of ward stay ,prolongation of medical certificate and absence of other postoperative complications were significant (p value < 0.05) indicating that LIHR is feasible in Taiping Hospital.

1. INTRODUCTION

Hernia comes from the Greek word *hernios*, which means offshoot or bud.

A hernia is defined as protrusion of a viscus or part of it through an abnormal opening in the walls of its containing cavity. The protrusion consists of a sac, which may be empty or contain a loop of bowel.

Inguinal hernia is one of the commonest surgical pathologies needing a corrective surgery. A prevalence rate of 4.7% of inguinal hernia was found in men aged 25 years and older (Abramson JH et al, 1978). The lifetime prevalence rate reached 40 per 100 men between the ages of 65-74. The annual incidence of inguinal hernia was 13 per 10,000 population (Primates P, 1996). The estimated lifetime risk of inguinal hernia repair was 27% for men.

In the United States, approximately 96 percent of groin hernias are inguinal and 4 percent are femoral. Inguinal hernias are bilateral in as many as 20 percent of affected adults.

(Rutkof IM et al, 1993). The most common hernia in both sexes is the indirect inguinal hernia. The male-to-female ratio is 9:1 for inguinal hernias and 1:3 for femoral hernias. While inguinal hernias occur fairly equally across adult age groups, femoral hernias tend to occur more often in elderly women. The lifetime risk of inguinal herniation is approximately 10% (Rutkof IM et al, 1993).

Success of groin hernia repair is measured primarily by fewest complications, minimal costs, and earliest return to normal activities. This success depends largely on the understanding of the anatomy and physiology of the surgical area and choosing the most suitable techniques and materials.

A burning sensation in the groin occasionally precedes the development of a palpable hernia with later, a mass in the groin. Typically, the patient notes that the mass disappeared when he awakens in the morning, but it reappears upon standing upright. A dull sensation may be experienced as the day progresses and the patient has been upright for many hours. Patients may also have difficulty in movement, and some note a gas bubble in the groin.

An Ultrasound examination of the inguinal region with the patient in the supine and upright position and with the Valsalva maneuver has been reported to have a diagnostic sensitivity and specificity of greater than 90 percent (Schumpelick V et al, 1994). It may also be helpful in distinguishing an incarcerated hernia from a pathologic lymph node or other cause of a firm, palpable mass.

Risk factors associated with the development of groin hernias are obesity, pregnancy, and, aging, which studies suggest, contributes significantly to the breakdown of tissues resulting in the development of some groin hernias (Abramson JH et al, 1978).

Groin hernias can be categorized in a number of ways (Zollinger R.M. Jr, 1999). For practical purposes the main anatomical types are inguinal – indirect and direct – and femoral hernias. Clinically they may be asymptomatic, reducible, irreducible, incarcerated or painful, obstructed and strangulated.

The incidence of strangulation of groin hernias was reported in the literature to range from 1.3 to 5% (Gallegos NC et al, 1991). Mortality rate of strangulated inguinal hernia varied from 5% to 14%. Reported risk factors for strangulation of hernia included older age group, short duration of presentation, recurrent inguinal hernia, irreducibility of inguinal hernia

and coexisting medical illness (Gallegos NC et al, 1991 and McEntee GP et al, 1989). As 40% of patients did not seek medical treatment before strangulation of their hernias and 10% of strangulation occurred in patients with no prior history of hernia, increased public awareness of this condition is therefore required to ensure that patients seek and receive prompt surgical treatment.

A sudden increase in the mass size suggests incarceration or the development of a sliding component. Direct hernias are usually easily reducible and are less risk for incarceration or strangulation compared to indirect hernias. Sliding hernias more commonly are indirect, but when any part of the urinary bladder protrudes through a direct defect, it is too considered a sliding hernia .

Most inguinal hernia should be repaired electively, before they start to enlarge. Their enlargement is associated with higher surgical failure rates and adjusted lifestyle. This holds true for all indirect, femoral, recurrent, and most direct hernias. When a hernia does begin to enlarge or is no longer reducible, repair should be planned immediately.

The risks of delaying surgery can be considerable, with the most important concern being the chance of incarceration with strangulation. If this occurs, emergency surgery must be performed, regardless of the patient's medical status, comorbid medical conditions, or concomitant medications, including the use of anticoagulants. Although trusses have been used to defer or obviate surgery, they are often used incorrectly, adding to scar formation, which must be managed when the repair is eventually done.

2.0 LITERATURE REVIEW

2.1 HISTORY OF INGUINAL HERNIA REPAIR

2.1.2 EVOLUTION OF INGUINAL HERNIA REPAIR

Hernia repair has started since the ancient time to the present era. The chronological event leading to the hernia repair today are results of early surgeons contributions(Table 1). It was then further continued by the hernia surgeon Edoardo Bassini in the late 19th century

Among the most notable contemporary classic hernia repairs are the Bassini, Halsted, Shouldice and, McVay (Cooper Ligament) repairs.

Modified Bassini. Bassini's original repair yielded outstanding results for a pure tissue technique, but, problems occurred when surgeons failed to open the posterior wall. This operation became known as the "modified" or "North American" Bassini . By not opening the posterior wall, the wall tissue was damaged in its most medial portion by sutures placed under tension, and recurrences resulted, primarily in the pubic tubercle area. Thus, the failure of this operation in its first year was more likely due to an overlooked second hernia or to poor surgical technique, rather than a metabolic or tissue defect that might predispose to recurrent hernia.

The Halsted operation. Halsted, a contemporary of Bassini, published multiple generations of his operations for hernia repair, each one attempting to correct a flaw in the previous version. Like Bassini, Halsted opened the canal's posterior wall to do a high dissection and ligation of the peritoneal sac in the iliac fossa. He made a point to thin the cord as much as possible and then did a 4-layer repair of the canal's posterior wall.

Table 1. Milestones in Hernia Repair: The Listerian Era

Marcy (1871)	Publication of original paper on antiseptic herniorrhaphy ("A New Use of Carbolized Catgut Ligature")
Czerny (1876)	Described ligating and excising the indirect peritoneal sac through the external ring
Kocher	Twisted and suture-transfixed the peritoneal sac in the lateral muscles. through the external ring
MacEwen (1886)	Reefed the peritoneal sac into a plug to block the internal ring.
Lucas-Championniere	Opened the external oblique aponeurosis to expose the entire inguinal canal.

Cooper ligament repair. Cooper was the first to describe the superior pubic ligament, although he never used it to surgically repair a groin hernia. The first Cooper ligament repair was done in 1897 by the Austrian surgeon, Georg Lotheissen, who used the superior pubic ligament in 2 patients who had lost their inguinal ligaments in the course of prior unsuccessful hernia repairs.

Shouldice repair. Canadian surgeon E.E. Shouldice contributed substantially to hernia surgery in the second half of the 20th century. The Shouldice operation for hernia repair revitalizes Bassini's original technique (Welch DR et al, 1993). It applies the principle of an imbricated posterior wall closure with continuous monofilament suture. Local anesthesia is routinely used and bilateral hernias are usually repaired separately, 2 days apart. Patients resume their usual activities within a reasonable time after the operation.

The Shouldice repair has been considered the gold standard of hernia repairs for the last 4 decades, although its use has declined since the introduction of various tension-free prosthetic repairs. The Shouldice repair remains an excellent option, however, and has produced the best and most enduring results of any other pure tissue repair.

Use of Prosthetics in Hernia Repair

The need for a satisfactory prosthesis for hernia repair has been recognized for more than a century. Various materials, including autografts (the patient's own tissue), have been tried. The most successful of the autografts is fascia lata, which has been used as suture material, a pedicle graft, and as a free transplanted graft. However, in addition to requiring a second operation to harvest it, fascia lata weakens and fails over time and dissolves in the presence of infection.

Many authors have attempted to define characteristics of the ideal prosthetic material for hernia repairs (Table 2), although attempts to achieve this "ideal" have met with varying degrees of success. No currently available prosthesis is perfect or free of problems, and the choice of material thus requires compromised.

Table 2. Characteristics of an Ideal Prosthesis

<i>The ideal prosthetic mesh should:</i>
Not be physically modified by tissue fluids
Be chemically inert
Not excite inflammatory or foreign body reaction
Be noncarcinogenic
Not produce allergy or hypersensitivity
Be capable of resisting mechanical strain
Be capable of being fabricated in the form required, and constructed in a way such that sutures or cutting will not cause the mesh to unravel or fray
Be sterilizable
Be permeable and allow tissue ingrowth within it
Stimulate fibroblastic activity to allow incorporation into tissue rather than sequestration or encapsulation
Be sufficiently pliable so as not to cause stiffness or to be felt by the patient
Strong enough to resist bursting by the maximum forces that can be created by intra-abdominal pressure or from an outer force

Tension-Free Hernia Repair

The most important advance in hernia surgery has been the development of tension-free repairs. In 1958, Usher(Usher Fc, 1960) described a hernia repair using *Marlex* mesh. The benefit of that repair he described as being "tension-eliminating" or what we now call "tension-free" (Figure 2). Usher opened the posterior wall and sutured a swatch of *Marlex* mesh to the undersurface of the medial margin of the defect (which he described as the transversalis fascia and the conjoined tendon) and to the shelving edge of the inguinal ligament. He created tails from the mesh that encircled the spermatic cord and secured them to the inguinal ligament.

Every type of tension-free repair requires a mesh, whether it is done through an open anterior, open posterior, or laparoscopic route. The most common prosthetic open repairs done today are the Kugel patch repair, the Lichtenstein onlay patch repair, the *PerFix* plug and patch repair, and the *PROLENE Hernia System* bilayer patch repair (Figures 3).

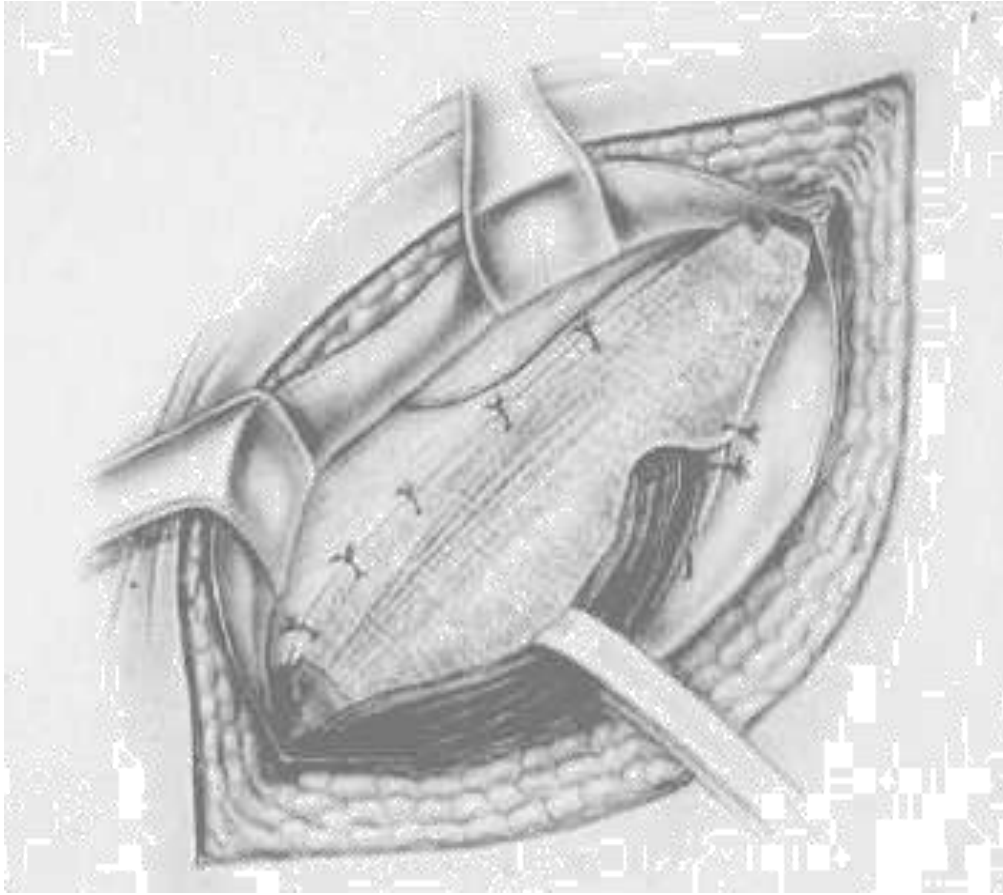


Figure 1:Lichtenstein onlay patch. Mesh is sutured from the transversus arch to the shelving edge of the inguinal ligament creating a "tension-free" repair.

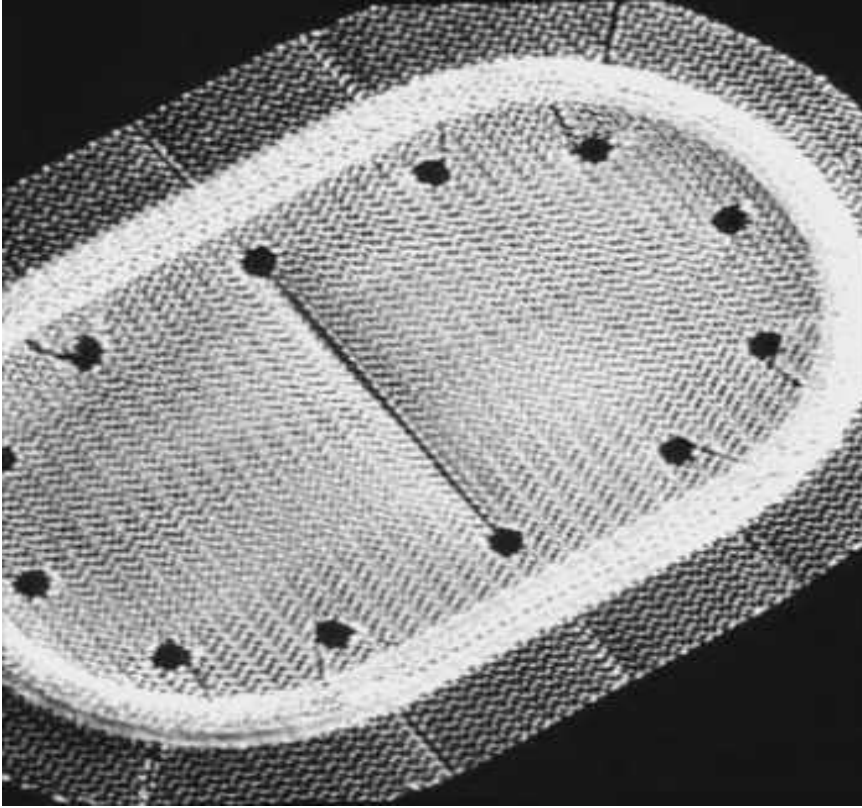


Figure 2-Kugel Patch. "Race-track" oval shaped polypropylene mesh graft with pocket for insertion and larger gauge polypropylene ring to hold graft's flat shape.

2.1.2 EVOLUTION OF LAPAROSCOPIC INGUINAL HERNIA REPAIR

Ger, was the first surgeon attempting minimal access groin hernia repair by closing the opening of an indirect inguinal hernial sac by Michel clips (Ger, 1982). The technique was then modified by intra-corporeal suture of the deep ring after plugging a Polypropylene mesh into the sac (Bogojavlensky, 1989). It was subsequently followed by a technique of intraperitoneal onlay mesh (IPOM) placement, where an intra-abdominal piece of polypropylene or e-PTFE was stapled over the myopectineal orifice without dissection of the peritoneum (Toy and Smoot,1992). The IPOM had some major drawbacks like possibility of bowel adhesions and migration of the mesh. These initial attempts of laparoscopic repair did not meet with encouraging results (Toy and Smoot 1992, Corbitt JD 1993). Since the early attempts by Ger, refinements of technique and innovations have subsequently changed the concept of hernia surgery. Despite the longer learning curve and being more challenging than laparoscopic cholecystectomy (Aeberhad P. et al, 1993 and Best GL. et al, 1999) it became an increasingly popular procedure though controversies abound (Velanovich B, 2000).

The techniques of laparoscopic hernia repair evolved from Stoppa's concept of pre-peritoneal reinforcement of fascia transversalis over the myopectineal orifice with its multiple openings by a prosthetic mesh.(Stoppa RE et al, 1993) .The trans-abdominal pre-peritoneal repair (TAPP) was introduced in the early 1990's (Arregui et al 1992 and Dion YM, 1992). In this technique, the abdominal cavity is first entered, peritoneum over the posterior wall of the inguinal canal is incised to enter into the avascular preperitoneal plane which is adequately dissected to place a large (15 x 10 cm) mesh over the hernial orifices. After fixation of the mesh, the peritoneum is carefully sutured or stapled.

Around the same time the totally extra-peritoneal (TEP) technique of endoscopic hernioplasty was introduced. In this technique, the peritoneal cavity is preserved and the entire dissection is performed bluntly in the extra-peritoneal space with a balloon device or the tip of the laparoscope. An advanced knowledge of the posterior anatomy of the inguinal region is essential. Once the dissection is complete, a 15 x 10 cm mesh is stapled in place over the myopectineal orifice. The TEP method minimizes the potential of the intra-abdominal organs injuries while eliminating the exposure of the bowel to the prosthetic biomaterial.

In both method, the mesh is in direct contact with the fascia of the transversalis muscle in the pre-peritoneal space, allows tissue ingrowths leading to the fixation of the mesh (as opposed to being in contact to the peritoneum as in IPOM repair where it is prone to migrate).

2.2 EMBRYOLOGY OF INGUINAL REGION

2.2.1 DEVELOPMENT OF INGUINAL CANAL

The inguinal canals form a route for descend of the testis from the abdomen through the anterior abdominal wall into the scrotum. Inguinal canals develop in both males and females. As the mesonephros degenerates, a ligament called the gubernaculum descends on each side of the abdomen from the inferior pole of the gonad. The gubernaculum passes obliquely through the developing anterior abdominal wall at the site of the future inguinal canal. It attaches to the internal surface of the labioscrotal swelling, that is the future half of the scrotum or labium majus (Moore and Persaud, 1993 and Skandalakis et al, 1993).

An evagination of processus vaginalis develops on each side of the ventral to the gubernaculum and herniates through the abdominal wall along the path formed by the gubernaculum. Each processus vaginalis carries before it extensions of the layers of the abdominal wall that forms the walls of the inguinal canal. In males, these layers also become the coverings of the spermatic cord and testis. The opening produced in the transversalis fascia by the processus vaginalis becomes the deep inguinal ring, and the opening formed in the external oblique aponeurosis eventually becomes the superficial inguinal ring (Moore, 1993). The embryologic entities between the skin and peritoneum allow the processus vaginalis to penetrate them and form the inguinal canal. The testicular descent into the scrotum is thus allowed. Descent of the ovary outside the peritoneal cavity, however, is forbidden. The processus vaginalis is also responsible in that it finally closes to obstruct ovarian exodus but leaves the formation of the inguinal canal in situ (Skandalakis et al, 1993).

2.2.2 GONADAL GENESIS AND DESCENT

The processus vaginalis is an outpouching of peritoneum attached to the testicle that trails behind as it descends retroperitoneally into the scrotum. When obliteration of the processus vaginalis fails to occur, inguinal hernia results.

Although the sex of the embryo is determined at fertilization, the gonads do not begin to differentiate until 7 weeks' gestation. Primordial germ cells migrate along the dorsal mesentery of the gut. They arrive at the primitive gonads early in the fifth week of development and, during the sixth week, invade the genital ridges, which lie on the medial

aspect of the mesonephros. The coelomic epithelium proliferates, and the underlying mesenchyme condenses, forming the primitive sex cords.

Under the influence of the Y chromosome, the cords in the male embryo proliferate to form the testes. Near the end of the second month, the testis and mesonephros are attached by the urogenital mesentery to the posterior abdominal wall. As the mesonephros degenerates, only the testis remains suspended. At its caudal end, the attachment is ligamentous and is known as the caudal genital ligament. The gubernaculum, a mesenchymal structure rich in extracellular matrices, also extends from the caudal pole of the testis. This structure attaches in the inguinal region between the differentiating internal and external oblique muscles prior to descent of the testes. As the testes begin to descend at about 28 weeks' gestation, an outgrowth of gubernaculum from the inguinal region grows toward the scrotal area, and as the testis passes through the inguinal canal, this portion of the gubernaculum comes in contact with the scrotal floor.

During this time, the peritoneum of the coelomic cavity is forming an evagination on each side of the midline into the ventral abdominal wall. This evagination, known as the processus vaginalis, follows the path of the gubernaculum testis into the scrotal swellings and forms, along with the muscle and fascia, the inguinal canal. The descent of the testes through the inguinal canal is thought to be regulated by both androgenic hormones produced by the fetal testis and mechanical factors resulting from increased abdominal pressure.

As each testis descends, the layers of the abdominal wall contribute to the layers of the spermatic cord. The internal spermatic fascia is a reflection of the transversalis fascia, the

internal oblique muscle helps form the cremaster muscle, and the external spermatic fascia results from the external oblique aponeurosis. In addition, a reflected fold of the processus vaginalis covers each testis and becomes known as the visceral and parietal layers of the tunica vaginalis.

In the female embryo, the ovaries descend into the pelvis but do not leave the abdominal cavity. The upper portion of the gubernaculum becomes the ovarian ligament, and the lower portion becomes the round ligament, which travels through the inguinal ring into the labium majus. If the processus vaginalis remains patent, it extends into the labium majus and is known as the canal of Nuck.

Before birth, the layers of the processus vaginalis normally fuse, closing off the entrance into the inguinal canal from the abdominal cavity. In some individuals, the processus vaginalis remains patent through infancy, into childhood, and possibly even into adulthood. The precise cause of the obliteration of the processus vaginalis is unknown, but some studies indicate that calcitonin gene-related peptide (CGRP), released from the genitofemoral nerve, may have a role in the fusion.

When luminal obliteration fails to occur, a ready-made sac is present where abdominal contents may herniate. Even when the processus vaginalis is patent, the entrance may be adequately covered by the internal oblique and transverse abdominal muscles, preventing escape of abdominal contents for many years. Failure of fusion can result not only in an inguinal hernia, but also in a communicating or noncommunicating hydrocele.

2.3 ANATOMY OF ANTERIOR ABDOMINAL WALL AND INGUINAL REGION

The anterior abdominal wall is a multilayered complex aponeurotic structure that covers the abdominal viscera. The superficial fascia above the umbilicus is a single layer that are divided into a superficial fatty layer (Camper's fascia) and a deeper membranous layer (Scarpa's fascia)below it. The superficial layer continuous with the outer layer of fascia covering the perineum, penis, the scrotum and the thigh. The deeper layer is loosely adherent to the fascia covering the aponeurosis of the external oblique superiorly and to the fascia lata of the thigh inferiorly.

2.3.1 INGUINAL CANAL

The inguinal canal is approximately 4 cm long and is directed obliquely inferomedially through the inferior part of the anterolateral abdominal wall. The canal lies parallel and 2-4 cm superior to the medial half of the inguinal ligament. This ligament extends from the anterior superior iliac spine to the pubic tubercle. It is the lower free edge of the external oblique aponeurosis. It contains the spermatic cord in males and the round ligament of the uterus in females. The canal also transmits the blood and lymphatic vessels and the ilioinguinal nerve (L1 collateral) from the lumbar plexus forming within psoas major muscle. It has openings at either end – the deep and superficial inguinal rings. The deep (internal) inguinal ring is the entrance to the inguinal canal. It is the site of an outpouching of the transversalis fascia. This is approximately 1.25 cm superior to the middle of the inguinal ligament and lateral to the inferior epigastric artery (from the external iliac artery). The deep inguinal ring is the beginning of an evagination in the transversalis fascia,

forming an opening like the entrance to a cave, through which the vas deferens (or round ligament of the uterus in the female), and gonadal vessels pass to enter the inguinal canal. The transversalis fascia continues into the canal, forming the innermost covering (internal fascia) of the structures traversing the inguinal canal. The superficial, or external inguinal ring is the exit from the inguinal canal. It is a slitlike opening between the diagonal fibres of the aponeurosis of the external oblique muscle, superolateral to the pubic tubercle, through which the spermatic cord or the round ligament of the uterus, emerge from the inguinal canal. The medial and lateral margins of the superficial ring formed by the split in the aponeurosis known as crura. The lateral crus is attached to the pubic tubercle and the medial crus is attached to the pubic crest. Fibres arising from the inguinal ligament lateral to the superficial ring arch superolaterally to the superficial ring. These are known as intercrural fibres and help to prevent the crura from spreading apart – ie preventing the split in the aponeurosis from expanding – increasing the likelihood of prolapse. The superficial ring is in the external oblique aponeurosis and is protected posteriorly by the conjoint tendon which is the amalgamation of the internal oblique and transverses abdominis. The deep ring is posterior to the aponeurotic fibres of external oblique and the muscular fibres of internal oblique. The final anatomical relations to describe of the inguinal canal is that of its anterior and posterior wall, and finally its floor and roof. The anterior wall of the canal is made up by the aponeurosis of the external oblique with the lateral part of the wall being reinforced by fibres of the internal oblique. The posterior wall is formed mainly by transversalis fascia with the medial part of the wall being reinforced by formation of the conjoint tendon also known as the inguinal falx, which is the merging of the pubic attachments of the internal oblique and transverse abdominal aponeurosis into a common tendon. The iliopubic tract is the thickened inferior margin of the transversalis fascia that

appears as a fibrous band running parallel and posterior to the inguinal ligament. The iliopubic tract contributes to the posterior wall of the inguinal canal as it bridges the external iliofemoral vessels from the iliopectineal arch to the superior pubic ramus.

The roof of the inguinal canal is formed by the arching fibres of the internal oblique and transverse abdominal muscles. The floor is formed by the superior surface of the incurving inguinal ligament, which forms a shallow trough. It is reinforced in its most medial part by the lacunar ligament, a reflected part or extension from the deep aspect of the inguinal ligament to the pectineal line of the superior pubic ramus. The deep and superficial inguinal rings in the adult do not overlap because of the oblique path of the inguinal canal. Consequently increases in intraabdominal pressure act on the inguinal canal, forcing the posterior wall of the canal against the anterior wall and strengthening this wall, thereby decreasing the likelihood of herniation until the pressures overcome the resistant effect of this mechanism. Furthermore, contraction of the external oblique approximates the anterior wall of the canal to the posterior wall. Contraction of the internal oblique and transverse abdominal muscles make the roof of the canal descend, constricting the canal. In the male it is the spermatic cord which is transmitted by the inguinal canal. It suspends the testis in the scrotum and contains the structures running to and from the testis. It begins at the deep inguinal ring lateral to the inferior epigastric artery, passes through the inguinal canal, exits the superficial inguinal ring and ends in the scrotum at the posterior border of the testis. The spermatic cord has three distinct layers of fascia surrounding it. There is the internal spermatic fascia derived from the transversalis fascia, the cremasteric fascia derived from the fascia of both the superficial and deep surfaces of the internal oblique muscle, and the external spermatic fascia derived from the external oblique aponeurosis. The inguinal canal transmits all of the contents of the spermatic cord, which includes the

vas deferens – a 45 cm long muscular tube responsible for conveying sperm from the epididymis to the ejaculatory duct, the testicular artery arising from the aorta and supplying the testis and epididymis, the sympathetic nerve fibres on arteries and both autonomic fibres on the vas deferens, the genital branch of the genitofemoral nerve (L1,2) from the lumbar plexus, supplying the cremaster muscle and the lymphatic vessels draining the testis, passing to the lumbar lymph nodes.

2.3.2 INGUINAL HERNIAS

A hernia is a protrusion of tissue (usually parietal peritoneum and viscera such as fat, gut or omentum) through or alongside an opening in the abdomen that is designed to allow a normal structure to enter or exit. In most patients there is no immediate obvious cause for the hernia but there may be a history of straining the groin . However, there are three likely underlying factors that contribute to many hernias. Incomplete adaptation to the upright posture in humans, damage to the ilioinguinal nerve at appendicectomy or other operation, or the persistence or reopening of the processus vaginalis that is seen in infants.

Approximately 90% of abdominal hernias are in the inguinal region. Inguinal hernias are broadly classified as indirect (75%) or direct (25%), which refer to the relation of the herniation to the inferior epigastric arteries on the abdominal wall and the Hasselbach's triangle. The anatomic region known as Hasselbach's triangle is defined laterally by the inferior epigastric artery, medially by the lateral border of the rectus muscle and inferiorly by the inguinal ligament (Figure5). An indirect hernia passes lateral to the inferior epigastric vessels and thus is outside of Hesselbach's triangle (Figure 6), while a direct

hernia is medial to the epigastric vessels and therefore within the confines of this space (Figure 7).

An indirect hernia is generally believed to have a congenital component. Thus, an indirect hernia is the result of two conditions: (1) the existence of a potential space due to nonobliteration of the processus vaginalis and (2) a weakening of the fascia of the transversalis muscle fibers surrounding the exit of the spermatic cord at the internal abdominal ring.

Direct inguinal hernias are not generally congenital. They are acquired by the development of tissue deficiencies of the transversus abdominis muscle, which makes up the floor of the inguinal canal. Thus, these hernias protrude directly through a defect in the inguinal canal floor, rather than indirectly following the potential space of the processus vaginalis and the path of the spermatic cord.

Nerve supply of the inguinal region is important as an injury to the nerves may cause significant problems. The nerves are the ilioinguinal, iliohypogastric and genitofemoral nerves. The ilioinguinal nerve traverses the inguinal canal near the external inguinal ring and provides unilateral sensory innervation to the pubic region and the upper portion of the scrotum or the labia majora. This is the nerve most commonly injured during open hernia repair. The iliohypogastric nerve passes superior to the internal inguinal ring and provides sensory innervation to the skin superior to the pubis. The genital branch of the genitofemoral nerve travels within the spermatic cord to provide sensation to the scrotum and the medial thigh. The femoral branch of this nerve supplies sensation to the skin of the anterior thigh (figure 8) (Condon RE).

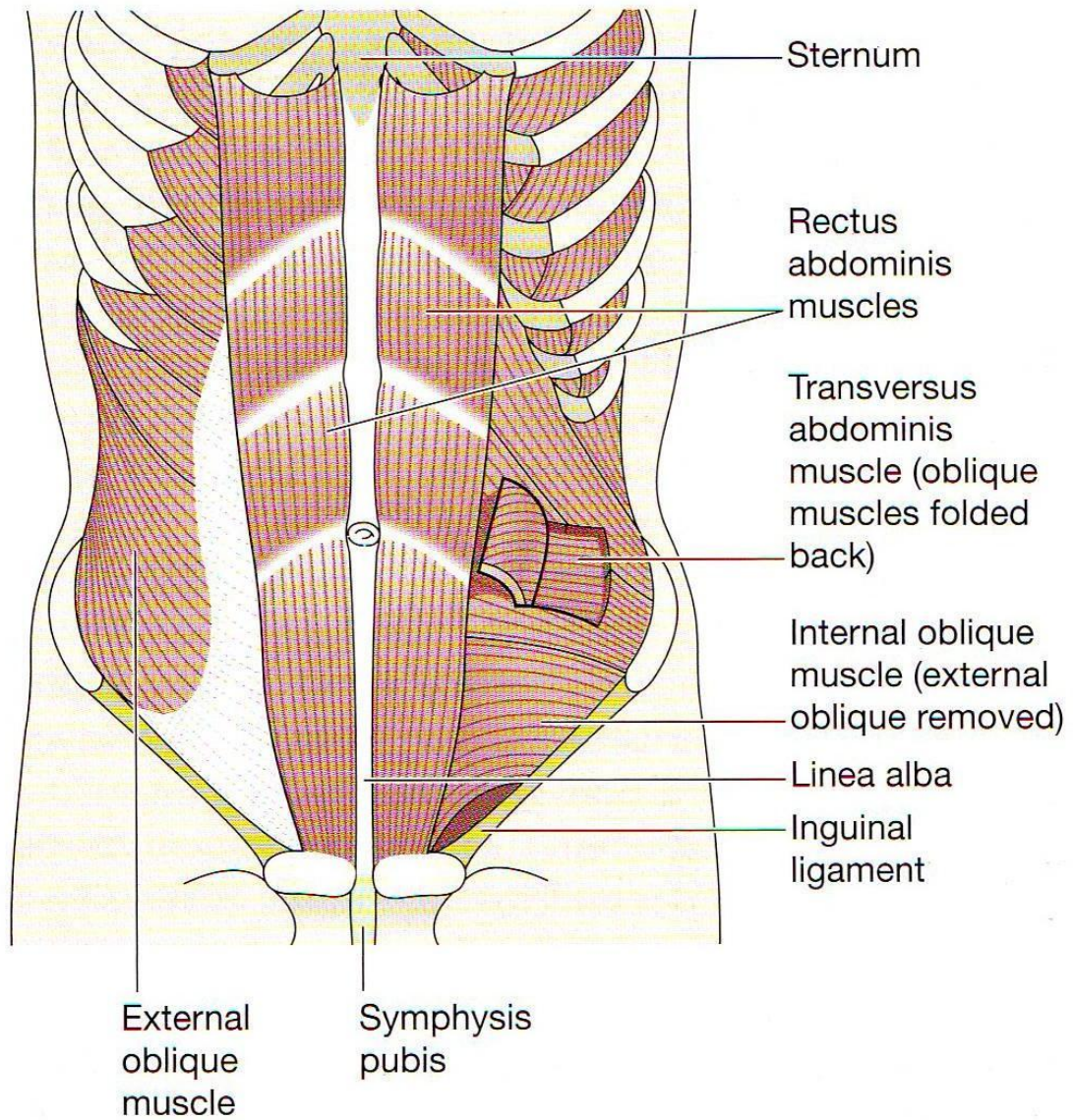


Figure 3-Anterior abdominal wall anatomy

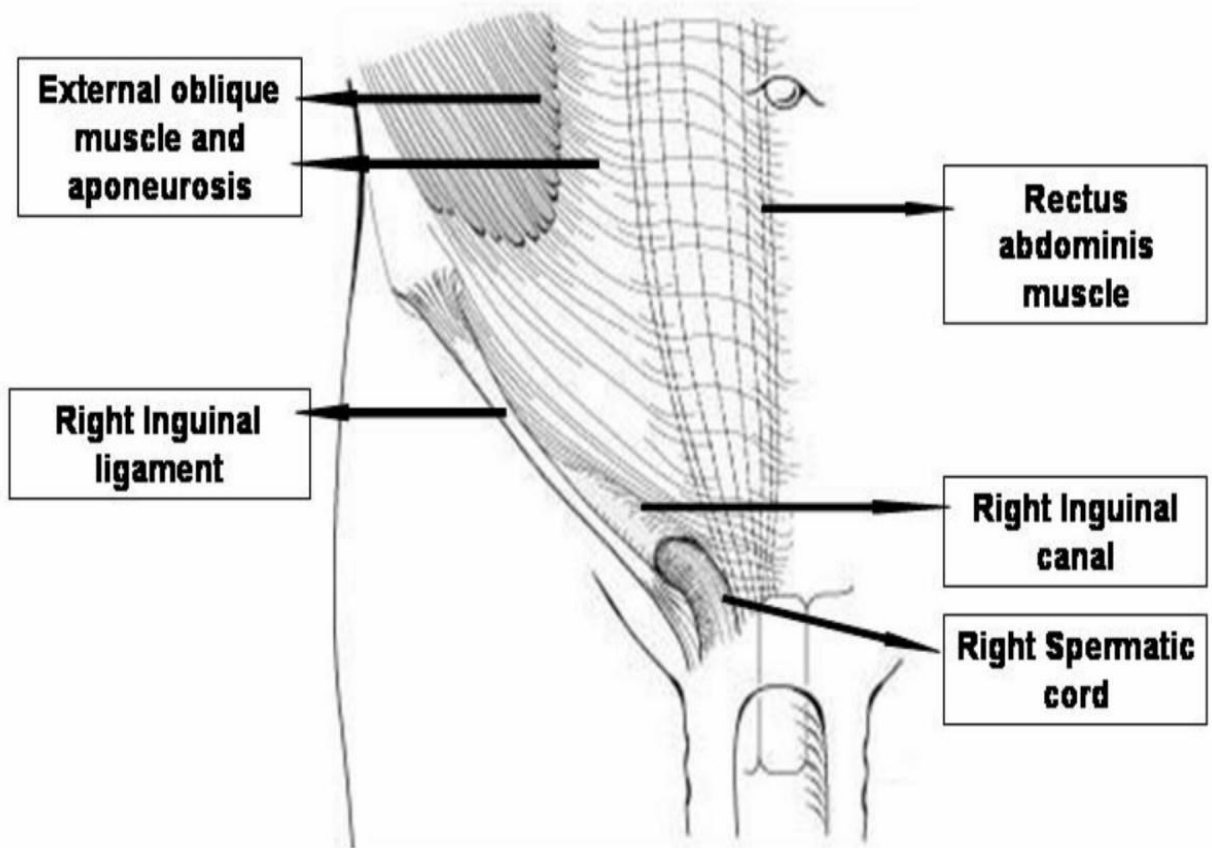


Figure 4 – Anatomy of the inguinal canal

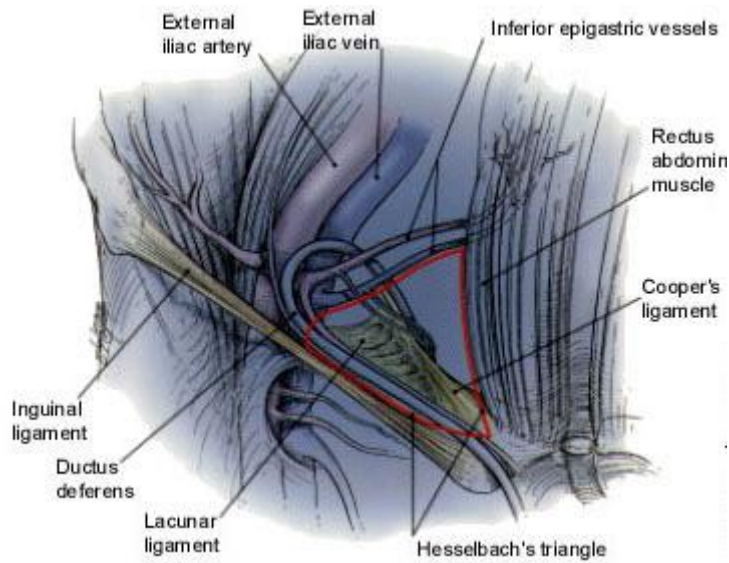


Figure 5-Hasselbach's triangle. This anatomic landmark is bounded by the rectus abdominis muscle medially, the inguinal ligament inferiorly and the inferior epigastric vessels laterally. The triangle is outlined in red

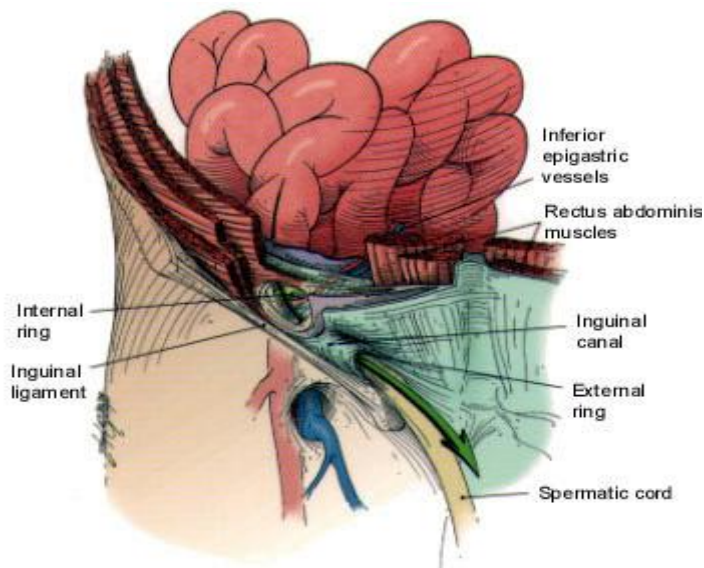


Figure 6-Route of an indirect hernia. Note that the hernia sac passes outside of the boundaries of Hasselbach's triangle and follows the course of the spermatic cord.