


Contents lists available at [ScienceDirect](http://ScienceDirect.com)

International Journal of Infectious Diseases

journal homepage: [www.elsevier.com/locate/ijid](http://www.elsevier.com/locate/ijid)

## Case Report

Extracorporeal membrane oxygenation (ECMO) as salvage treatment for pulmonary *Echinococcus granulosus* infection with acute cyst ruptureSören L. Becker<sup>a,b,c,\*</sup>, Sebastian Fährndrich<sup>d</sup>, Franziska C. Trudzinski<sup>d</sup>, Barbara Gärtner<sup>a</sup>, Frank Langer<sup>e</sup>, Torben K. Becker<sup>f</sup>, Robert Bals<sup>d</sup>, Philipp M. Lepper<sup>d</sup>, Christian Lensch<sup>d</sup><sup>a</sup> Institute of Medical Microbiology and Hygiene, Saarland University, Homburg/Saar, Germany<sup>b</sup> Swiss Tropical and Public Health Institute, Basel, Switzerland<sup>c</sup> University of Basel, Basel, Switzerland<sup>d</sup> Department of Medicine V – Pneumology, Allergy and Critical Care Medicine, ECLS Centre Saar, Saarland University, Homburg/Saar, Germany<sup>e</sup> Department of Thoracic and Cardiovascular Surgery, Saarland University, Homburg/Saar, Germany<sup>f</sup> Department of Emergency Medicine, University of Florida, Gainesville, FL, USA

## ARTICLE INFO

## Article history:

Received 11 June 2017

Accepted 4 September 2017

Corresponding Editor: Eskild Petersen, Aarhus, Denmark

## Keywords:

Extracorporeal membrane oxygenation

(ECMO)

Infection

Echinococcosis

*Echinococcus granulosus*

Hydatid disease

Infection

## ABSTRACT

Extracorporeal membrane oxygenation (ECMO) has been used successfully for the treatment of patients with respiratory failure due to severe infections. Although rare, parasites can also cause severe pulmonary disease. Tapeworms of the genus *Echinococcus* give rise to the development of cystic structures in the liver, lungs, and other organs. Acute cyst rupture leads to potentially life-threatening infection, and affected patients may deteriorate rapidly. The case of a young woman from Bulgaria who was admitted to hospital with severe dyspnoea, progressive chest pain, and haemoptysis is described. Computed tomography of the chest was pathognomonic for cystic echinococcosis with acute cyst rupture. Following deterioration on mechanical ventilation, she was cannulated for veno-venous ECMO. The patient's condition improved considerably, and she was weaned successfully from ECMO and mechanical ventilation. Following lobectomy of the affected left lower lobe, the patient was discharged home in good condition. This appears to be the first report of the successful use of ECMO as salvage treatment for a severe manifestation of a helminthic disease. Due to recent migration to Western Europe, the number of patients presenting with respiratory failure due to pulmonary echinococcosis with cyst rupture is likely to increase.

© 2017 The Author(s). Published by Elsevier Ltd on behalf of International Society for Infectious Diseases. This is an open access article under the CC BY-NC-ND license (<http://creativecommons.org/licenses/by-nc-nd/4.0/>).

## Introduction

Tapeworms of the genus *Echinococcus* can cause severe human infections with a potentially fatal course (Eckert and Deplazes, 2004). Cystic echinococcosis and alveolar echinococcosis represent the two main clinical entities and are caused by *Echinococcus granulosus* and *Echinococcus multilocularis*, respectively. The development of cystic structures in the liver, lungs, and other organs is the key feature of echinococcosis. While the main burden of this neglected tropical disease is concentrated in tropical and

subtropical countries, both forms of echinococcosis also occur across Europe, with *E. granulosus* being frequent in some Mediterranean countries and Southeast Europe (e.g. Bulgaria, Romania) and *E. multilocularis* being highly endemic in France, southern Germany, Austria, Switzerland, and Turkey (Eckert and Deplazes, 2004). Recently, a steady increase in cases has been reported from a number of European countries, but clinician awareness of the infection is usually low and treatment practices may vary considerably, even in specialised centres (Nabarro et al., 2015).

Extracorporeal membrane oxygenation (ECMO) is an extracorporeal technique that can provide temporary life support to patients with severe respiratory or cardiac failure (Makdisi and Wang, 2015). ECMO can be used for severe acute respiratory distress syndrome (ARDS) and any forms of potentially reversible respiratory insufficiency as 'bridge-to-recovery' or 'bridge-to-

\* Corresponding author at: Institute of Medical Microbiology and Hygiene, Saarland University, Homburg/Saar, Germany.

E-mail address: [soeren.becker@uks.eu](mailto:soeren.becker@uks.eu) (S.L. Becker).

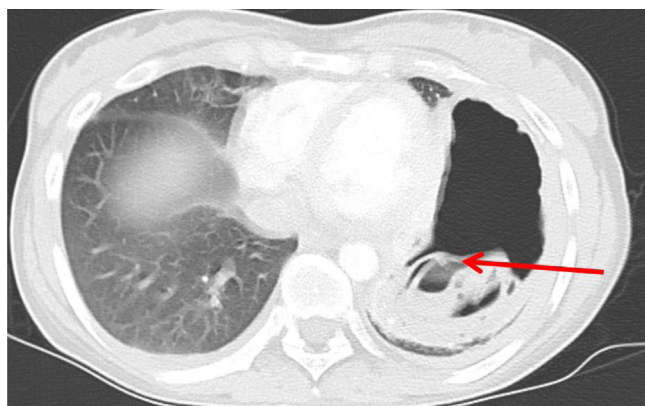
transplant' in patients who are eligible for lung transplantation. With regard to its use as salvage treatment for severe respiratory infections, a recently published systematic review and meta-analysis confirmed the role of ECMO as an adjunct for severe influenza A H1N1 pneumonia (Vaquer et al., 2017). However, it appears that no reports on the potential use of ECMO in the treatment of parasitic worm infections have been published to date.

### Case report

A 23-year-old female patient from Bulgaria was admitted to a local hospital in southwest Germany because of progressive dyspnoea and chest pain. The patient had lived in Germany for several years and her past medical history was unremarkable except for being a former smoker (cumulative dose of five pack-years). Upon admission, the patient reported having had mild chest pain during the four preceding weeks. She also reported one episode of haemoptysis on the day of presentation. On clinical examination, no fever was noted and the patient's peripheral oxygen saturation was 83%. Initial blood gas analysis revealed a  $pO_2$  of 44 mmHg and laboratory investigations showed considerably increased inflammatory markers with an elevated C-reactive protein (CRP) level of 56 mg/l (normal value <5 mg/l). On chest X-ray, a large cystic structure was seen in the left hemithorax.

The patient's condition deteriorated rapidly and she was admitted to the intensive care unit with a preliminary diagnosis of community-acquired pneumonia with a large abscess. Blood cultures and sputum samples were obtained for microbiological investigations, and empirical antibiotic treatment with piperacillin–tazobactam was started. A computed tomography (CT) scan of the thorax was performed, which showed one large, partially fluid-filled cystic structure (measuring  $11 \times 5.6 \times 9.2$  cm) in the left hemithorax that appeared to be septated and comprised several endocysts (Figure 1). Several freely floating membranes within the endocysts were seen (known as 'water-lily sign'), a finding highly suggestive of pulmonary echinococcosis.

The patient's condition continued to decline and she developed worsening hypoxia. Therefore, she was transferred to the Saarland University Medical Centre in Homburg, Germany. Upon arrival, the patient was in septic shock and respiratory failure, necessitating aggressive fluid resuscitation, vasopressor treatment, intubation and mechanical ventilation. The antibiotic regimen was changed to a carbapenem (meropenem 1 g three times a day) and vancomycin (1 g two times a day on the first day, then adjusted to serum levels).



**Figure 1.** Computed tomography scan of the patient with pulmonary echinococcosis, showing a large, partially fluid-filled cyst in the left lower lobe, in which freely floating membranes of smaller endocysts can be seen (red arrow; so-called 'water-lily sign').

Serology for anti-*Echinococcus* antibodies was positive and chest X-rays showed findings suggestive of acute rupture of the cystic structure in the left lower lobe. Albendazole (400 mg two times a day) was added to the anti-infective regimen. A new bronchial aspirate obtained on mechanical ventilation grew *Haemophilus influenzae*, which was sensitive to both meropenem and piperacillin–tazobactam.

The patient's condition worsened further and she developed progressive hypoxic and hypercapnic respiratory failure with respiratory acidosis ( $pO_2$  44 mmHg,  $pCO_2$  79 mmHg, pH 7.21,  $pO_2/FiO_2$  index 70). At this point, the patient was felt to have ARDS due to bacterial superinfection of a ruptured *Echinococcus* cyst in the left hemithorax. Given her progressive deterioration and ongoing clinical instability, the decision was made to initiate veno-venous ECMO support. Cannulation of the right femoral vein and the right internal jugular vein was performed and ECMO treatment was initiated.

After 7 days on ECMO support, the patient's condition improved considerably; she was weaned off vasopressors and her inflammatory markers normalised. The patient was then weaned off ECMO and she was extubated 3 days later. After further clinical improvement, the patient underwent a left lower lobectomy for surgical treatment of the residual cystic structure. Specific PCR assays on the resected tissue confirmed the presence of nucleic acids of *E. granulosus*. The postoperative course was uncomplicated and no signs of further organ involvement of the echinococcosis were found. The patient was discharged home in good condition, with plans to continue oral albendazole treatment for at least 2 years.

### Discussion

This case describes the use of ECMO as salvage treatment for severe respiratory insufficiency due to pulmonary *E. granulosus* infection with acute cyst rupture and bacterial superinfection, possibly for the first time. ECMO has been used widely as a treatment modality for severe respiratory failure and ARDS due to viral (e.g., influenza A) and bacterial diseases (e.g., pneumococcal pneumonia), as well as malaria (Alves et al., 2013). However, no previous reports on its use in respiratory failure due to helminthic diseases could be identified in the literature. With a steadily increasing number of echinococcosis cases in Europe and in view of a lack of awareness among clinicians, it is likely that many patients will only be diagnosed at an advanced stage of disease when they present with acute complications. Indeed, in 2015, 37.7% of all cases of echinococcosis in the European Union were reported from Bulgaria alone, thereby underscoring the significant endemicity of this parasitic infection in Southeast Europe (European Centre for Disease Prevention and Control, 2016). Thus, echinococcosis should always be included in the differential diagnosis of patients presenting with large, cyst-like lesions of the lung or liver.

In the case described herein, the pathognomonic 'water-lily' pattern was noted on the CT scan of the chest. Serology and PCR of the resected tissue confirmed the aetiology in this case, but it is important to note that no specific antibodies can be detected in approximately 30% of all pulmonary *Echinococcus* cases. Potential treatment modalities for echinococcosis include (1) surgical resection (indicated for larger cysts measuring >10 cm; complete resection may cure the disease); (2) a minimally invasive treatment option called PAIR, i.e. puncture–aspiration–injection–re-aspiration (which is particularly useful for treating univesicular hepatic cysts); and (3) medical treatment (chemotherapy with the benzimidazoles albendazole or mebendazole, both for inoperable cases and as an adjunct after surgery and PAIR) (Eckert and Deplazes, 2004). Choosing the most

appropriate, stage-specific treatment option for a patient with echinococcosis is not trivial, and recent surveys revealed significant heterogeneity among treating clinicians worldwide, who often did not follow the recommendations put forth by the World Health Organization Informal Working Group on Echinococcosis (Nabarro et al., 2015).

Similar to the management of echinococcosis, survival rates and outcomes of patients treated with ECMO are superior in specialised centres with intensivists who have long-standing experience with extracorporeal circuits and the management of complications such as bleeding and thromboembolic events. Close cooperation between intensivists and infectious disease experts is thus vital to ensure optimal patient outcomes.

In conclusion, this case demonstrates the feasibility and utility of ECMO therapy as a salvage ‘bridge-to-recovery’ treatment modality for severe respiratory failure due to a helminthic infection.

### Conflict of interest/funding

The authors of this manuscript have no conflicts of interest or funding to disclose.

### References

- Alves C, Chen JT, Patel N, Abrams D, Figueiredo P, Santos L, et al. Extracorporeal membrane oxygenation for refractory acute respiratory distress syndrome in severe malaria. *Malar J* 2013;12:306.
- Eckert J, Deplazes P. Biological, epidemiological, and clinical aspects of echinococcosis, a zoonosis of increasing concern. *Clin Microbiol Rev* 2004;17(1):107–35.
- European Centre for Disease Prevention and Control (ECDC). Annual epidemiological report 2015. Echinococcosis. 2016 Stockholm, Sweden.
- Makdisi G, Wang IW. Extracorporeal membrane oxygenation (ECMO): review of a lifesaving technology. *J Thorac Dis* 2015;7(7):E166–76.
- Nabarro LE, Amin Z, Chiodini PL. Current management of cystic echinococcosis: a survey of specialist practice. *Clin Infect Dis* 2015;60(5):721–8.
- Vaquer S, de Haro C, Peruga P, Oliva JC, Artigas A. Systematic review and meta-analysis of complications and mortality of veno-venous extracorporeal membrane oxygenation for refractory acute respiratory distress syndrome. *Ann Intensive Care* 2017;7(1):51.