

RVC OPEN ACCESS REPOSITORY – COPYRIGHT NOTICE

This author's accepted manuscript may be used for non-commercial purposes in accordance with [Wiley Terms and Conditions for Self-Archiving](#).

The full details of the published version of the article are as follows:

TITLE: Does the computed tomographic appearance of the lung differ between young and old dogs?

AUTHORS: Natasha L. Hornby, Christopher R. Lamb

JOURNAL: Vet Radiology & Ultrasound

PUBLISHER: Wiley

PUBLICATION DATE: November 2017

DOI: [10.1111/vru.12532](https://doi.org/10.1111/vru.12532)

1 **Does the computed tomographic appearance of the lung differ between young and old dogs?**

2 Natasha L. Hornby and Christopher R. Lamb

3 Department of Clinical Sciences and Services, The Royal Veterinary College, University of

4 London

5

6 Address correspondence to: C. R. Lamb, Department of Clinical Sciences and Services, The Royal

7 Veterinary College, Hawkshead Lane, North Mymms, Hertfordshire AL9 7TA, UK.

8 Tel: 01707-666234

9 Email: clamb@rvc.ac.uk

10 Key words: aging, atelectasis, computed tomography, dog, lung

11 Running head: CT of aged lung

12 Funding Sources: The authors received no financial support for the research, authorship or

13 publication of this article.

14 Abstract

15 In computed tomographic (CT) images of humans, decreased lung attenuation, bronchial
16 dilation and/or thickening, air trapping, cysts, and thickened interlobular septa have been
17 associated with increasing age. To determine if there are differences in the CT appearance of
18 the lungs of young and old dogs that could affect interpretation of diagnostic studies,
19 pulmonary CT images of dogs with conditions unrelated to the thorax were reviewed
20 retrospectively in a case-control study. CT studies of 42 young dogs (range 0.3-4.8 years) and 47
21 old dogs (range 9-15.1 years) were jumbled and reviewed by an observer blinded to dog age. CT
22 was performed under sedation in 62 (70%) dogs and under general anesthesia in 27 (30%).
23 Heterotopic bone was more prevalent (62% versus 14%) in old dogs. Lung collapse was
24 significantly associated with old age, greater body weight, and anesthesia. There were no
25 significant differences in median lung attenuation or occurrence of ground glass pattern, cysts,
26 bronchial thickening, bronchial dilation, or degree of tracheal calcification. No examples of
27 reticular pattern, emphysema, pleural thickening or septal thickening were observed in any
28 dog. Despite previous studies describing age-related changes in the radiographic appearance of
29 the lungs of old dogs, it appears that there are minimal observable differences in CT images.
30 Old dogs are more likely to have visible foci of heterotopic bone and may be more prone to
31 lung lobe collapse than young dogs, but neither of these differences should contribute to
32 misdiagnosis of pulmonary disease.

33 **Introduction**

34 Age-related changes in the morphology of the lung have been described in humans¹, dogs^{2,3},
35 and rats.⁴ A prominent age-related feature observed in dogs was accumulation of macrophages
36 containing dust and pigment in the respiratory bronchioles and alveolar openings.² It was
37 hypothesized that exposure to dust and reduction in function of the mucociliary escalator over
38 time resulted in accumulation of dust and pigment in the lungs,² but this was not confirmed.
39 There was also an increase in the relative volume ('volume density') of alveolar ducts,
40 progressive calcification of the bronchial cartilage, and increased size of the bronchial glands.²
41 Minimal emphysema was observed and fibrosis was sparse, mainly associated with foci of
42 pneumonitis.²

43 Correlations between morphologic changes in the lungs and the radiographic appearance of the
44 lung were described in 100 aged dogs that had no pathologic evidence of pulmonary or
45 cardiovascular disease.³ Emphysema and alveolar dilatation were reported, but more emphasis
46 was placed on findings of pleural fibrosis and interstitial fibrosis.³ Accumulation of peribronchial
47 collagen over time causing progressive pulmonary fibrosis has also been emphasized in studies
48 of aging rats.⁴ Together with fibrosis, thickening of the alveolar walls and calcification of
49 bronchial cartilage in dogs were associated with radiographic signs including pleural thickening,
50 increased linear markings, and increased opacity of the tracheal and bronchial walls.³ Foci of
51 heterotopic bone in the lungs of many older dogs produced small nodular opacities in
52 radiographs.³ Based on these findings, increased lung attenuation, pleural and septal thickening
53 and increased prevalence of heterotopic bone may be expected in computed tomographic (CT)

54 images of the lungs of aged dogs; however, there are no published studies of age-related
55 changes in pulmonary CT images of dogs.

56 Changes associated with normal aging in the lungs of humans have been studied extensively,
57 one aim being to avoid over-diagnosis of age-related changes as signs of clinically significant
58 disease. Age-related changes seen in pulmonary CT images of humans include decreased lung
59 attenuation as a result of dilatation of alveoli and/or emphysema, air-trapping, cysts, a sub-
60 pleural reticular pattern, bronchial dilation, bronchial thickening, and thickening of interlobular
61 septa without inflammation.⁵⁻⁹ CT signs usually associated with interstitial lung disease may also
62 be seen in healthy elderly humans, and radiologists have been cautioned not to over-interpret
63 such findings in asymptomatic patients.⁵

64 The aim of the present study was to determine if there are differences in the CT appearance of
65 the lungs of young and old dogs that could affect interpretation of diagnostic studies.

66

67 **Method and Materials**

68 Ethical approval was granted by the Clinical Research Ethical Review Board at the Royal
69 Veterinary College. For this retrospective case-control study, the medical records at the Queen
70 Mother Hospital for Animals (QMHA) in the period 2012-2016 were searched for cases that
71 satisfied the following inclusion criteria: dogs that had diagnosis of a non-malignant disease or
72 condition unrelated to the thorax; had non-contrast CT images of the lung acquired using a high
73 resolution (sharp or lung) algorithm; and were either less than 5 years old or more than 9 years
74 old. Dogs with a history of lower respiratory signs or diagnosis of cardiovascular, mediastinal,

75 pleural, bronchial, pulmonary disease, malignant neoplasia or systemic inflammatory disease
76 were not included.

77 For each dog, age at the time of CT, gender, body weight and diagnosis were recorded. On the
78 basis of body weight, dogs were divided in small (<10kg), medium (10-25kg), large (26-40kg),
79 and giant (>40kg) categories. Use of sedation or anesthesia for CT was also recorded. For all
80 sedated dogs, CT images were acquired during free breathing, whereas anaesthetised dogs had
81 brief manual hyperventilation with CT images acquired during the subsequent expiratory pause.

82 As part of the inclusion criteria, all CT images were acquired using the same multi-slice scanner
83 (MX8000 IDT, Phillips Best, The Netherlands). Studies lacking optimal settings for lung
84 examination were excluded. For the purposes of this study, optimal settings were helical
85 acquisition, slice thickness 2mm for small dogs and 3mm for other dogs, matrix 512x512, and
86 high frequency ('sharp' or 'lung enhanced') reconstruction algorithm. All CT images were
87 reviewed by a board-certified radiologist (CRL) without knowledge of the age, breed or history
88 of the subjects. Images were reviewed in a lung window (level -500HU, width 2000HU) using a
89 proprietary Digital Imaging in Communications and Medicine (DICOM) viewer (OsiriX 64-bit,
90 version 5.2.2, Pixmeo, Switzerland). For each dog, the lungs were also examined using
91 maximum- and minimum-intensity projections with slab thickness 5mm for small dogs and
92 8mm for other dogs. Dogs whose CT images were affected by motion blur were excluded.

93 CT images were evaluated for the following features: mean lung attenuation (Hounsfield units,
94 HU) based on the median of three measurements made using a circular region of interest of
95 minimum area 40mm² placed in different lung lobes and avoiding bronchi or large vessels;
96 ground glass opacity (absent/present); reticular pattern (absent/present); emphysema

97 (absent/present); pulmonary cysts (absent/present, diameter of largest cyst); visceral pleural
98 thickening (absent, affecting one lobe, affecting multiple lobes); interlobular septal thickening
99 (absent, affecting one lobe, affecting multiple lobes); bronchial thickening (none, slight,
100 marked); bronchial dilation (median of bronchus: pulmonary artery ratio measurements in the
101 right caudal lobe in three adjacent CT slices); degree of tracheal ring calcification (the median of
102 three HU measurements made by placing a point sample on a tracheal cartilage ring
103 immediately cranial to the origin of the lobar bronchi); foci of heterotopic bone (absent,
104 affecting one lobe, affecting multiple lobes); and pulmonary collapse (number of affected lobes
105 and distribution of collapse was recorded: lobe tip only, peripheral, bronchocentric, entire
106 lobe). The term tip is used here to indicate the pointed extremity of a lung lobe in transverse CT
107 images. Diagnosis of heterotopic bone was based on finding pulmonary hyperdense foci ranging
108 from sub-millimeter rounded foci to larger irregularly-shaped densely ossified foci. Diagnosis of
109 lung collapse was based on finding increased lung attenuation accompanied by reduced volume
110 of the affected lung. Terminology followed recommendations for thoracic imaging by the
111 Fleischner Society.¹⁰

112 Statistical analyses were done by a statistician (Yu-Mei Chang) using a commercial statistical
113 software package (SPSS 22, IBM) Significance of differences in median lung attenuation,
114 bronchus: pulmonary artery ratio and tracheal calcification between young and old dogs were
115 tested using the Mann-Whitney test. Differences in prevalence of ground glass opacity,
116 bronchial thickening and cysts were tested using Fisher's exact test. Differences in occurrence
117 of heterotopic bone and body weight of dogs were tested using Kendall's tau-c test.
118 Associations between the dependent variable lung collapse and independent variables age,

119 body weight, and anesthesia were tested using binary logistic regression and results
120 summarized as odds ratio (OR) and 95% confidence interval (CI). Differences with $p < 0.05$ were
121 considered significant.

122

123 **Results**

124 CT images of 42 young dogs (age range 0.3-4.8 years) and 47 old dogs (age range 9-15.1 years)
125 were reviewed. All dogs were scanned in sternal recumbency. Characteristics of young and old
126 dog groups are summarized in Table 1. CT features observed in young and old dogs are
127 summarized in Table 2. Heterotopic bone was more prevalent (62% versus 14%; $p < 0.001$) in old
128 dogs.

129 Signs of lung collapse were identified in 40 (46%) dogs. Based on regression analysis,
130 occurrence of lung collapse was significantly associated with age (OR 3.7, CI 1.4-9.5, $p = 0.007$),
131 body weight (OR 1.9, CI 1.1-3.3, $p = 0.02$), and anesthesia (OR 3.1, CI 1.1-8.8, $p = 0.03$). Lung
132 collapse affected the right middle lobe in 22 dogs, left cranial lobe in 21 dogs, right cranial lobe
133 in 18 dogs, left caudal lobe in 7 dogs, accessory lobe in 6 dogs, and right caudal lobe in 4 dogs.
134 Lung collapse affected a single lobe in 21 (24%) dogs and multiple lobes in 19 (22%) dogs. In
135 58/68 (85%) affected lobes collapse was limited to the tip of the lobe, in 7 (1%) lobes it was
136 bronchocentric, and in 3 (5%) lobes it was peripheral (figure 1).

137 There were no significant differences in median lung attenuation or occurrence of ground glass
138 pattern, cysts, bronchial thickening, bronchial dilation, or degree of tracheal calcification
139 between young and old dogs. Cysts were found in 6 (7%) dogs; these were solitary in 3 dogs and

140 multiple (2-9) in 3 dogs, and the largest ranged in size from 2-11mm diameter (figure 2). No
141 examples of reticular pattern, emphysema, pleural thickening or septal thickening were
142 observed in any dog.

143

144 **Discussion**

145 In this study there were minimal observable differences between the lungs of young and old
146 dogs. Heterotopic bone was more prevalent in old dogs, which agrees with previous
147 observations.³ Lung collapse was also observed more frequently in old dogs, although the
148 underlying reason for this difference cannot be determined by the present study. For
149 physiological reasons, the right middle lobe is most prone to collapse in the dog.¹¹ In the
150 present study, collapse of the right middle lobe and the right and left cranial lobes occurred
151 with similar frequencies. In the majority of dogs, lung collapse affected only the tip of the lobe.
152 Reduced collateral ventilation because of subclinical disease, such as chronic bronchitis with
153 excessive mucus production, is liable to exacerbate lung collapse.^{12,13} The increased tendency
154 for lung collapse in older dogs could reflect an increasing prevalence of subclinical lung disease
155 over their lifetime. The observation that lung collapse was more frequent in dogs that had CT
156 under general anesthesia than in dogs that were sedated could reflect the use of high inspired
157 pO₂ for anesthesia, which has also been associated with a higher prevalence of lung collapse
158 than when using moderate inspired pO₂ ('medical air').¹⁴ It is uncertain why lung collapse was
159 more frequent in larger dogs. It is known that intermittent positive pressure ventilation to
160 minimize lung collapse is required more frequently in large dogs than small dogs or cats¹⁵, and

161 this may reflect the larger gravitational gradient that occurs within the lung of larger patients,
162 as observed in anesthetized horses.¹⁶

163 There were no significant differences in median lung attenuation or occurrence of ground glass
164 pattern, cysts, bronchial thickening, bronchial dilation, or degree of tracheal calcification
165 between young and old dogs. These results are in contrast with those of a previous study in
166 which the lungs of old dogs had radiographic signs including pleural thickening, increased linear
167 markings, and increased opacity of the tracheal and bronchial walls.³ Although the results of CT
168 in one group of dogs cannot be compared directly with results of radiography in a different
169 group of dogs, it seems likely that CT would have detected signs of pleural thickening, increased
170 linear markings and increased opacity of the tracheal and bronchial walls had they been
171 present. In fact, based on ability to directly measure lung attenuation using CT and other canine
172 studies that found increased sensitivity of CT for lung lesions^{17,18}, CT might be expected to
173 reveal more age-related changes than radiography. Therefore, the relative lack of CT signs in
174 the present study could reflect a true difference in the condition of the lungs of the dogs used
175 in these respective studies, possibly reflecting different genetic or environmental factors. If so,
176 this could limit the generalizability of our results, which may not be applicable in other
177 locations.

178 Attenuation measurements of tracheal rings were used in the present study as an indirect
179 indicator of bronchial wall calcification. Tracheal rings were measured instead of bronchial walls
180 because they are normally thicker than bronchial walls, hence any attenuation measurements
181 will be less affected by partial volume artifact.

182 The process of aging occurs over a shorter period of time in dogs than in humans¹, and It is
183 generally accepted that dogs of large and giant breeds age more rapidly than dogs of small or
184 medium breeds. The smaller number of giant breed dogs in the aged group in the present study
185 reflects this phenomenon. Non-contiguous age ranges were used in this study to ensure
186 separation of young and aged dogs, which could intermingle if a heterogeneous sample of dogs
187 were classified using a single calendar age threshold alone.

188 In this study, examination of the CT images included quantitative measurements and search for
189 multiple possible lesions based on previous studies of CT signs in aged humans⁵⁻⁹; however, few
190 examples were found of ground glass pattern, bronchial thickening or bronchial dilation, and no
191 signs of reticular pattern, emphysema, pleural thickening or septal thickening were identified in
192 any dog. Hence, finding any of these features in CT images of a dog with respiratory signs
193 suggests the presence of non-age-related lung pathology that is clinically relevant.

194 Cysts were found in 6 (7%) dogs in this study. There is some overlap in use of the terms cyst and
195 bulla, although in humans bulla is used for lesions greater than 1cm, and usually several cm in
196 diameter.¹⁰ Lung cysts (and bullae), which can be subclinical, should be distinguished from both
197 congenital lobar emphysema^{19,20} and superficial bullous emphysema, which is associated with
198 non-traumatic ('spontaneous') pneumothorax.^{21,22}

199 The main limitation of the present study was the lack of pathologic examination of lungs, which
200 prevents histologic proof of the nature of lesions identified by CT, and allows the possibility that
201 there were age-related lung changes that were undetected by CT. All CT studies reviewed in
202 this study were obtained using settings suitable for clinical assessment of the lung of dogs, but
203 more detailed assessment is possible using thinner (1mm) CT slices²³ or micro-CT²⁴ with

204 histologic examination of precisely orientated lung sections. Further studies are indicated to
205 better examine imaging-pathologic correlations in the aging canine lung. The number of dogs
206 available for study was limited by the need to avoid including dogs likely to have had pathologic
207 lung lesions. Use of a single observer to review the CT is also a limitation, but this is not
208 considered to be a major problem because of the relatively homogenous nature of the study
209 sample and use of comprehensive, pre-considered assessment criteria based on previous
210 studies of humans.⁵⁻⁹

211 In conclusion, despite previous studies describing age-related changes in the radiographic
212 appearance of the lungs of old dogs, it appears that there are minimal observable differences in
213 CT images. Old dogs are more likely to have visible foci of heterotopic bone and may be more
214 prone to lung lobe collapse than young dogs, but neither of these differences should contribute
215 to misdiagnosis of pulmonary disease.

216

217 **List of Author Contributions**

218 Category 1

219 (a) Conception and Design

220 Author name (s) Natasha L. Hornby and Christopher R. Lamb

221 (b) Acquisition of Data

222 Author name (s) Natasha L. Hornby and Christopher R. Lamb

- 223 (c) Analysis and Interpretation of Data Author name (s) Natasha L. Hornby and Christopher R.
224 Lamb
225 Category 2
226 (a) Drafting the Article
227 Author name (s) Natasha L. Hornby and Christopher R. Lamb
228 (b) Revising Article for Intellectual Content Author name (s) Natasha L. Hornby and Christopher
229 R. Lamb
230 Category 3
231 (a) Final Approval of the Completed Article Author name(s) Natasha L. Hornby and Christopher
232 R. Lamb
233
234 **Acknowledgement**
235 We thank Yu-Mei Chang for performing the statistical analyses.

236 **References**

- 237 1. Pinkerton KE, Green FHY. Normal aging of the lung. In: Harding RD, Pinkerton KE and
238 Plopper CG (Eds). The lung: development, ageing and the environment. London: Elsevier
239 Academic Press, 2004, pp213-233.
- 240 2. Robinson NE and Gillespie JR. Morphologic features of lungs of aging beagle dogs. Am Rev
241 Respir Dis 1973; 108: 1192-1199.
- 242 3. Reif JS and Rhodes WH. The lungs of aged dogs. A radiographic-morphologic correlation. J
243 Am Vet Radiol Soc 1966; 7:5-11.
- 244 4. Calabresi C, Arosio B, Galimberti L, et al. Natural aging, expression of fibrosis-related genes
245 and collagen deposition in rat lung. Experimental Gerontology 2007; 42:1003-1011.
- 246 5. Copley SJ, Wells AM, Hawtin KH, et al. Lung morphology in the elderly: comparative CT
247 study of subjects over 75 years old versus those under 55 years old. Radiology 2009;
248 251:566-573.
- 249 6. Copley SJ. Morphology of the ageing lung on computed tomography. J Thorac Imaging 2016;
250 31:140-150.
- 251 7. Leelakanok N and Piyavisetpat N. CT features of normal lung change in asymptomatic
252 elderly patients. Asian Biomed 2015; 9:613-623.
- 253 8. Lowery EM, Brubaker AL, Kuhlmann E and Kovacs EJ. The aging lung. J Clin Interv Aging
254 2013; 8: 1489-1496.
- 255 9. Verbeken EK, Clement JM and Van De Woestijne KP. The senile lung – comparison with
256 normal and emphysematous lungs. 2. Functional-Aspects. Chest 1992; 101:800-809.

- 257 10. Hansell DM, Bankier AA, MacMahon H, McLoud TC, Muller NL, Remy J. Fleischner Society:
258 glossary of terms for thoracic imaging. *Radiology* 2008; 246: 697-722.
- 259 11. Robinson NE. Lobar variations in the mechanics of collateral ventilation in intact dog lungs.
260 *Am Rev Respir Dis* 1981; 124:68-71.
- 261 12. Robinson NE. Some functional consequences of species-differences in lung anatomy. *Adv*
262 *Vet Sci Comp Med* 1982; 26:1-33.
- 263 13. Lord PF, Gomez JA. Lung lobe collapse. Pathophysiology and radiologic significance. *Vet*
264 *Radiol* 1985;26:187-195.
- 265 14. Staffieri F, Franchini D, Carella GL, et al. Computed tomographic analysis of the effects of
266 two inspired oxygen concentrations on pulmonary aeration in anesthetized and
267 mechanically ventilated dogs. *Am J Vet Res* 2007; 68:925-931.
- 268 15. Grimm KA, Lamont LA, Tranquilli WJ, Greene SA, Robertson SA (Eds). *Veterinary Anesthesia*
269 *and Analgesia, The 5th Edition of Lumb and Jones*. Oxford: Wiley-Blackwell, 2015, p543.
- 270 16. Moens Y, Schramel JP, Tusman G, Ambrisko TD, Solà J, Brunner JX, et al. Variety of non-
271 invasive continuous monitoring methodologies including electrical impedance tomography
272 provides novel insights into the physiology of lung collapse and recruitment – case report of
273 an anaesthetized horse. *Vet Anaesth Analg* 2014;41: 196–204.
- 274 17. Nemanic S, London CA, Wisner ER. Comparison of thoracic radiographs and single breath-
275 hold helical CT for detection of pulmonary nodules in dogs with metastatic neoplasia. *J Vet*
276 *Internal Med* 2006; 20:508-515.

- 277 18. Eberle N, Fork M, Von Babo V, Nolte I and Simon D. Comparison of examination of thoracic
278 radiographs and thoracic computed tomography in dogs with appendicular osteosarcoma.
279 Vet Comp Oncol 2010; 9: 131-140.
- 280 19. Mitchell C, Nykamp S. Congenital lobar emphysema in an old English sheepdog puppy. Vet
281 Radiol Ultrasound 2006; 47:465-467.
- 282 20. Matsumoto H, Kakehata T, Hyodo T, et al. Surgical correction of congenital lobar
283 emphysema in a dog. J Vet Med Sci 2004; 66: 217-219.
- 284 21. Brissot HN, Dupre GP, Bouvy BM, et al. Thoracoscopic treatment of bullous emphysema in 3
285 dogs. Vet Surg 2003; 32: 524-529.
- 286 22. Puerto DA, Brockman DJ, Lindquist C, et al. Surgical and nonsurgical management of and
287 selected risk factors for spontaneous pneumothorax in dogs: 64 cases (1986-1999). J Am Vet
288 Med Assoc 2002; 220: 1670-1674.
- 289 23. Heikkilä HP, Lappalainen AK, Day MJ, Clercx C and Rajamäki MM. Clinical, bronchoscopic,
290 histopathologic, diagnostic imaging, and arterial oxygenation findings in West Highland
291 white terriers with idiopathic pulmonary fibrosis. J Vet Internal Med 2011;25: 433-439.
- 292 24. Mai C, Verleden SE, McDonough JE, et al. Thin-section CT features of idiopathic pulmonary
293 fibrosis correlated with micro-CT and histologic analysis. Radiology 2017;283: 264-272.

294 Table 1. Characteristics of young and old dog groups

| | Young dogs (n=42) | Old dogs (n=47) |
|------------------------|--------------------|--------------------|
| Median (range) age (y) | 3 (0.3-4.8) | 11 (9.0-15.1) |
| Males/ females | 28 (67%)/ 14 (33%) | 31 (66%)/ 16 (34%) |
| Body weight range | | |
| Small (<10kg) | 10 (24%) | 12 (25%) |
| Medium (10-25kg) | 15 (36%) | 20 (43%) |
| Large (26-40kg) | 12 (28%) | 13 (28%) |
| Giant (>40kg) | 5 (12%) | 2 (4%) |
| Diagnostic category | | |
| Upper respiratory | 19 (45%) | 12 (25%) |
| Immune-mediated | 11 (26%) | 1 (2%) |
| Alimentary | 4 (10%) | 3 (6%) |
| Neurologic | 4 (10%) | 3 (6%) |
| Orthopedic | 2 (5%) | 0 |
| Urinary | 2 (5%) | 2 (4%) |
| Benign neoplasm | 0 | 17 (36%) |
| Oral conditions | 0 | 6 (13%) |
| Endocrinopathy | 0 | 3 (6%) |
| CT under anesthesia | 12 (29%) | 15 (32%) |

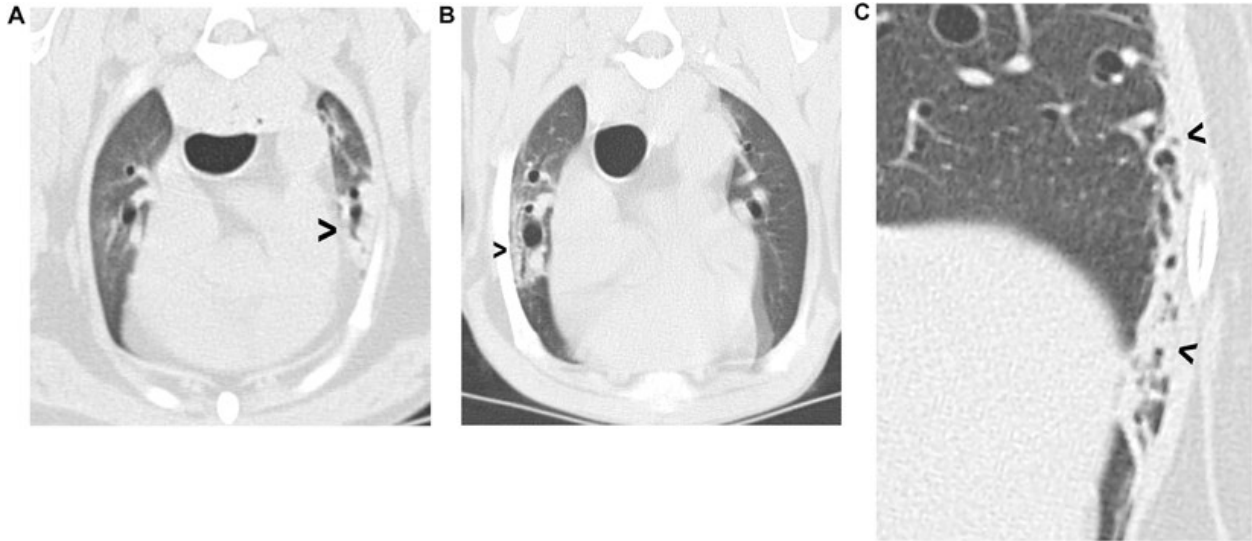
296 Table 2. CT features of the lungs of young and old dogs

| | Young dogs (n=42) | Old dogs (n=47) |
|---|---------------------|---------------------|
| Median (range) lung attenuation (HU) | -788 (-605 to -878) | -793 (-679 to -900) |
| Ground glass opacity | 7 (17%) | 8 (17%) |
| Cysts | 1 (2%) | 5 (10%) |
| Bronchial thickening | 5 (12%) | 5 (11%) |
| Median (range) bronchus: pulmonary artery ratio | 0.66 (0.41-1.06) | 0.63 (0.40-1.46) |
| Median (range) tracheal calcification (HU) | 224 (65-577) | 236 (107-512) |
| Heterotopic bone | | |
| In one lobe | 3 (7%) | 6 (13%) |
| In multiple lobes | 3 (7%) | 23 (49%) |
| Pulmonary collapse | | |
| None | 29 (69%) | 20 (43%) |
| One lung lobe affected | 9 (21%) | 12 (26%) |
| Multiple lobes affected | 4 (10%) | 15 (32%) |

297

298 **Legend**

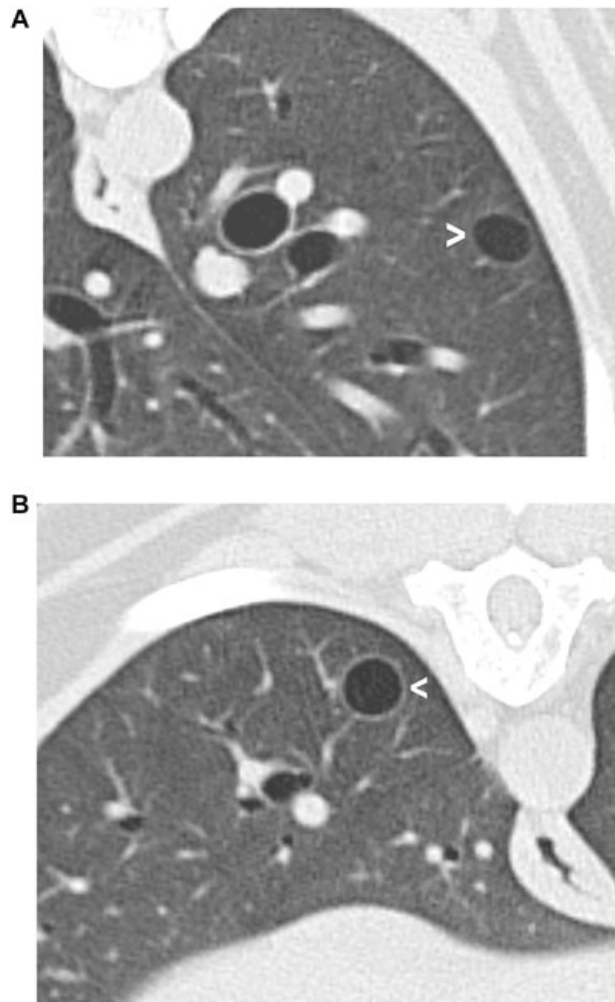
299 Figure 1. Examples of pulmonary collapse. A) Collapse of the ventral tip of the left cranial lobe
300 (arrowhead); B) bronchocentric collapse (arrowhead) affecting the right cranial lobe; C)
301 peripheral pulmonary collapse (arrowheads) affecting the lateral aspect of the left caudal lobe.



302

303

304 Figure 2. Examples of lung cysts. A) 10mm diameter cyst (arrowhead) in the left caudal lobe of a
305 1-year-old golden retriever that had CT as part of the work-up for nasal panniculitis. This was
306 one of 3 pulmonary cysts in this dog; B) 8mm diameter cyst (arrowhead) in the right caudal lobe
307 of a 14-year-old English springer spaniel that had CT as part of the work-up for
308 hyperadrenocorticism.



309