

## Estimation and Perturbation of the Mid-Sagittal Plane and its Effects on Corpus Callosum Morphometry

K. V. Skoglund<sup>1</sup>, M. B. Stegmann<sup>1</sup>, C. Ryberg<sup>2</sup>, H. Ólafsdóttir<sup>1</sup>, E. Rostrup<sup>2</sup>

<sup>1</sup>Informatics and Mathematical Modelling, Technical University of Denmark, Kongens Lyngby, Denmark, <sup>2</sup>Danish Research Centre for Magnetic Resonance, Copenhagen University Hospital, Hvidovre, Copenhagen, Denmark

### Introduction

Brain morphometry is an important tool for detecting and monitoring brain pathologies such as epilepsy, dementia [1,2] and multiple sclerosis [3]. A common method is to delineate some well-defined area of the brain to yield a shape for inter- or intra-subject studies. One such structure is the *corpus callosum* (CC), the white-matter nervous tissue bridging the left and right cerebral hemisphere. A multitude of papers (e.g. [2]) report on measurements performed on the two-dimensional cross-section of the CC defined by the *mid-sagittal plane* (MSP) which separates the left hemisphere from the right. Differences in shape due to pathologies are often slight (e.g. [1]). This makes it imperative to define the MSP in an accurate and consistent manner. This work investigates the importance of proper MSP estimation by measuring relative area changes of the CC as a function of plane perturbation angle from an estimated optimal MSP.

### Methods

A proper MSP is found by optimizing a plane parameterized by azimuth and elevation angles along with the orthogonal distance to the origin [4]. The objective function is based on local measures of symmetry along profiles normal to the plane. A Nelder-Mead simplex optimizer is used to find the optimal parameters. For the cases where the mid-sagittal surface is curved, it is possible to fit a thin-plate spline [4]. However, this study focuses on the CC, and since curvature is typically seen near the frontal and occipital lobe, MSPs are used exclusively.

It has been shown that the CC can be automatically localized [5] by means of Active Appearance Models (AAMs) [6]. This is carried out by building statistical models of variations in shape and image texture learned from an annotated training set, and subsequently fitting these models to unseen examples in an optimization process. AAMs based on annotated corpora callosa in two-dimensional MSP images can thus be employed to localize the CC in off-angle approximations to the MSP. Due to the coherence between subsequent rotations, the AAM is propagated from image to image (in this case from smaller to larger rotation) to increase accuracy and efficiency.

Although AAMs provide a dense correspondence between examples, it is well-known that ambiguities remain on virtually feature-less objects such as the CC. Recently, a proposed minimum description length (MDL) approach [7] has been widely popularized as a tool to redeem this problem. This study employs a freely available MDL implementation [8] to ensure well-defined correspondences along the CC outline prior to AAM building. This facilitates measurements of five reference areas (rostrum, genu, truncus, isthmus and splenium) on any example by choosing a set of associated landmarks on a single representative example (in this case the estimated mean shape).

To investigate the influence of the estimated MSP on CC morphometry, the optimal MSP is perturbed around the first and second principal axis of the CC as shown in Fig. 1. Total CC area and the five reference areas are measured and normalized using the corresponding area without MSP perturbation.

### Results

Volumetric magnetic resonance brain images were acquired from 56 subjects (sequence: MPRAGE; matrix: 256x256x150 pixels; voxel size: 0.977x0.977x1.0 mm). All subjects originated from a subset of the LADIS study [9]. MSPs were estimated automatically and the CC was manually annotated in these 56 planar images, which comprised the data set used to build a 2D CC AAM based on MDL correspondences. This model automatically localized the CC in two sets of 1120 MSP perturbation images (+/-10 degrees). Mean areas and error bars (one standard error) are given in Fig. 2 for rotation around the second principal axis. The genu and splenium showed the largest areas change at +/-10 degrees (25-35%). Due to the posterior-anterior elongation of the CC, area changes for perturbations around the first principal axis were less pronounced (approximately 10% at +/-10 degrees).

### Discussion

The results emphasize that consistent corpus callosum morphometry is highly dependent on a well-defined frame of reference, in this case a properly positioned mid-sagittal plane. The magnitude of change in the CC area suggests that any measurement on the corpus callosum should be preceded by careful MSP estimation. Such MSP estimation could thus remove potentially substantial random effects stemming from poor MSP determination (e.g. by plain in-scanner subject alignment) and thereby increasing the sensitivity of subsequent morphometric analyses. This would in turn allow for a reduction of the number of subjects in a given population study. Finally, it has also been demonstrated that robust and fully automatic corpus callosum localization using MDL-based AAMs, as well as MSP optimization is feasible.

### References

- [1] SJ Teipel, W Bayer, GE Alexander, Y Zebuhr, D Teichberg, L Kulic, MB Schapiro, HJ Moller, SI Rapoport, H Hampel, *Arch.Neurol. Dev.* 59, 243-248, 2002.
- [2] H Hampel, SJ Teipel, GE Alexander, B Horwitz, D Teichberg, MB Schapiro, SI Rapoport, *Arch.Neurol. Dev.* 55, pp. 193-198, 1998.
- [3] J Pelletier, L Suchet, T Witjas, M Habib, CR Guttman, G Salamon, O Lyon-Caen, AA Cherif, *Arch.Neurol. Dev.* 58, 105-111, 2001.
- [4] MB Stegmann, K Skoglund, C Ryberg, International Symposium on Medical Imaging 2005, San Diego, CA, Proc. of SPIE vol. 5747 (to appear), SPIE, 2005.
- [5] MB Stegmann, RH Davies, C Ryberg, International Symposium on Medical Imaging 2004, San Diego, CA, Proc. of SPIE vol. 5370, pp. 612-619, SPIE, 2004.
- [6] TF Cootes, GJ Edwards and CJ Taylor, *IEEE Trans. on Pattern Analysis and Machine Intelligence*, 23(6):681-685, 2001.
- [7] RH Davies, CJ Twining, et al. *IEEE Trans. on Medical Imaging*, 21(5):525-537, 2002.
- [8] HH Thodberg, Proceedings of Information Processing in Medical Imaging, pp. 51-62, Springer, 2003.
- [9] L Pantonia, AM Basile, G Pracuccia, K Asplund, J Bogousslavsky, H Chabriat, T Erkinjuntti, F Fazekas, JM Ferro et al. *Neuroepidemiology* 24:51-62, 2005.

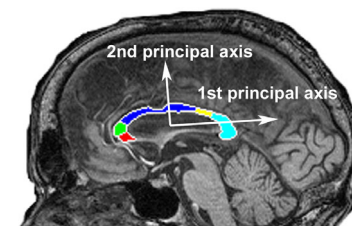


Fig. 1. Principal axes and reference areas of the corpus callosum.

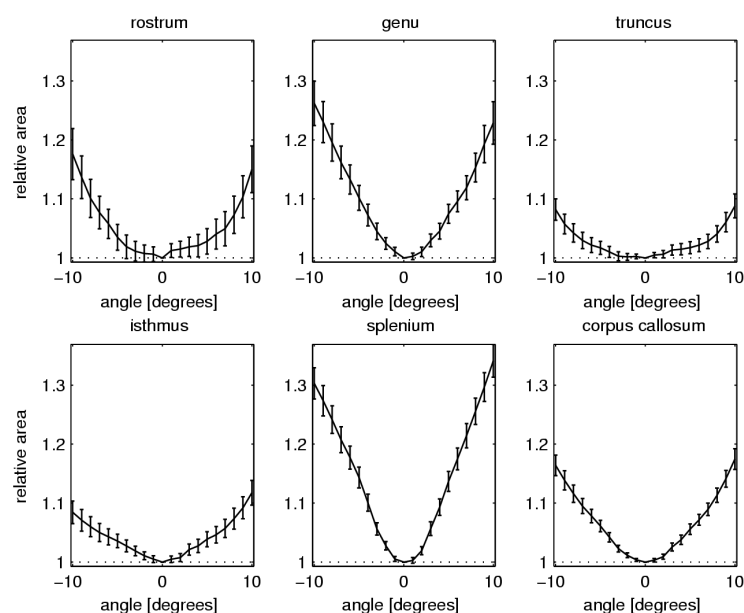


Fig. 2. Mean corpus callosum area changes for varying mid-sagittal planes.