

LONG-TERM INTRAOCULAR PRESSURE AFTER UNCOMPLICATED PARS PLANA VITRECTOMY FOR IDIOPATHIC EPIRETINAL MEMBRANE

DANIELE TOGNETTO, MD,* MARCO R. PASTORE, MD,* GABRIELLA CIRIGLIANO, MD,*
ROSSELLA D'ALOISIO, MD,* MASSIMO BORELLI, PhD,† CHIARA DE GIACINTO, MD*

Purpose: To investigate long-term intraocular pressure trends after uncomplicated pars plana vitrectomy for idiopathic epiretinal membrane.

Methods: Three hundred and sixty-eight eyes of 368 consecutive patients were enrolled. Changes in intraocular pressure 1, 3, 6, and 12 months after surgery and during the final follow-up visit were evaluated in vitrectomized eyes and nonvitrectomized fellow eyes.

Results: The median follow-up period was 36 months (range 12–92 months). Longitudinal data analysis evidenced a 2.5-mmHg (2.2 mmHg; 2.7 mmHg, 95% confidence interval) statistically significant difference in intraocular pressure 30 days after surgery between treated and fellow untreated eyes, gradually recovering to a not significant 0.2-mmHg (–0.1 mmHg; 0.4 mmHg, 95% confidence interval) difference within 26 months. The incidence of late-onset ocular hypertension was 5.7% (21 over 347, 2%; 12%, 95% confidence interval) without difference between the treated eyes and the group control. No significant difference in the incidence of late-onset ocular hypertension and sex, lens status, or gauge of vitrectomy instruments was detected. Only patient's age was significantly higher (mean difference 4.2 years; 0.1–8.0 years, Monte Carlo, 95% confidence interval) in those who developed late-onset ocular hypertension in the vitrectomized eye.

Conclusion: Uncomplicated pars plana vitrectomy for idiopathic epiretinal membrane seems not to increase the risk of late-onset ocular hypertension or open-angle glaucoma development.

RETINA 0:1–9, 2017

Pars plana vitrectomy is used in the treatment of many different posterior segment diseases including macular hole (MH), epiretinal membrane (ERM), vitreous hemorrhage, and retinal detachment. With expanding indications for vitrectomy, it becomes increasingly important to evaluate the long-term complications of this procedure. An uncommon early postoperative complication after vitrectomy was a transitory increased intraocular

pressure (IOP), because of inflammation, use of viscoelastics, silicone oil tamponade, or expanding gas filling.^{1–3} Several recent studies have reported the late development of open-angle glaucoma (OAG) after pars plana vitrectomy (PPV).^{4–7} The early postoperative increased IOP after PPV is usually transient and treated by medications. If the ocular hypertension (OHT) occurs later, its detection might be missed because of the lack of long-term follow-up. Chang firstly estimated that up to 20% of eyes undergoing uncomplicated PPV might be at risk of developing OAG in the long term. He proposed that oxidative stress played a major role in the development of OAG.⁸ By contrast, other studies did not find an association between OAG or IOP increasing and uncomplicated PPV.^{9–11} Given this controversy, the primary purpose of this retrospective study was to analyze the incidence of late-onset OHT after

From the *Eye Clinic, Department of Medical Surgical Sciences and Health, University of Trieste, Ospedale Maggiore, Trieste, Italy; and †Department of Mathematics and Computer Science, University of Trieste, Trieste, Italy.

Presented in part at 16th EURETINA Congress, Copenhagen, Denmark, November 11, 2016.

None of the authors has any financial/conflicting interests to disclose.

Reprint requests: Marco R. Pastore, MD, University Eye Clinic of Trieste, Ospedale Maggiore, Piazza Ospitale 1, 34129 Trieste, Italy; e-mail: marco.pastore@hotmail.it

uncomplicated PPV in eyes with idiopathic ERM. The secondary purpose was to evaluate the rate of IOP changes in relation to sex, lens status, biometric parameters, and gauge of vitrectomy instruments.

Material and Methods

The study was performed in accordance with the ethical standards of the Declaration of Helsinki, and an approval was obtained from the institutional review board of AOUST Ospedali Riuniti di Trieste and Trieste University Hospital. We conducted a retrospective analysis of 783 medical records of consecutive patients who underwent an uncomplicated PPV and membrane peeling for an idiopathic ERM between January 2008 and August 2015 at Eye Clinic University of Trieste, Department of Medical Surgical Sciences and Health.

A PPV using a 23-, 25-, or 27-gauge system after retrobulbar anesthesia was performed using the CONSTELLATION Vision System (Alcon, Fort Worth, TX). The surgical procedure consisted of a standard complete vitrectomy and removal of macular ERM and internal limiting membrane. The 25-gauge and 27-gauge vitrectomy were sutureless, whereas 23-gauge procedures were sutured.

Variations in surgical technique according to the surgeon's preference included staining of the macular ERM with either trypan blue or brilliant blue. All the eyes remained fluid filled at the end of surgery. Three hundred and twelve eyes underwent PPV alone because these eyes were already pseudophakic at the time of surgery. Four hundred and seventy-one eyes underwent combined phacovitrectomy. After the surgery, to confirm an open anterior chamber angle, a gonioscopic examination was performed. Postoperatively, patients were treated with a topical corticosteroid (dexamethasone 0.1%) 4 times a day for 2 weeks.

The inclusion criteria were a treatment-naïve ERM and at least a 12-month follow-up period including examinations at 1, 3, 6, and 12 months after vitrectomy. Furthermore, the fellow eye was requested to be unoperated. The exclusion criteria were diagnosis of glaucoma (neovascular, traumatic, congenital, open angle, or narrow angle), glaucoma suspect, OHT, chronic systemic or topical corticosteroid treatment, and previous intravitreal or periocular steroids injections. In addition, patients with history of anterior segment inflammation, previous penetrating ocular trauma and PPV, diabetic retinopathy, and proliferative vitreoretinopathy were excluded from the study. These criteria also applied to the fellow eyes. The fellow nonvitrectomized eyes served as the group

control and were not allowed to have any other previous eye procedures besides cataract surgery.

Postoperative examinations included best-corrected visual acuity using Early Treatment Diabetic Retinopathy Study acuity charts, IOP measurements at slit-lamp biomicroscopy, and fundus examinations. Patient age, sex, lens status, family history of glaucoma, and surgical indication were recorded.

Preoperatively, biometry parameters of axial length, anterior chamber depth, and keratometry were taken at baseline using intraocular lens master (version 5.0; Carl Zeiss Meditec Ltd, Jena, Germany). Scheimpflug camera combined with Placido-disk corneal topography (software version 2.0; Sirius) was used for the measurements of corneal pachimetry.

Intraocular pressure was measured with a Goldmann applanation tonometer (Haag-Streit, Koeniz, Switzerland). Ocular hypertension was defined as an IOP ≥ 22 mmHg found in at least 2 postoperative visits or the increase in the IOP > 4 mmHg than the preoperative IOP. A cutoff of 4 mmHg was used to define increased IOP because it exceeds the mean diurnal variation (3.7 mmHg) in IOP of normal eyes without glaucoma.^{12,13} Late-onset OHT was defined as an IOP > 22 mmHg developed more than 6 months postoperatively in at least 2 postoperative visits. We had defined glaucoma suspect as normal open angle on gonioscopy with one of the following findings in at least one eye that required further evaluation: an optic nerve or nerve fiber layer defect suggestive of glaucoma (enlarged cup-disk ratio ≥ 0.7 but ≤ 0.9 , asymmetric cup-disk ratio, notching or narrowing of the neuroretinal rim, a disk hemorrhage, or suspicious alteration and defect in the nerve fiber layer); a visual field abnormality consistent with glaucoma, or a visual field not reliable or available; an elevated IOP greater than 22 mmHg.

Open-angle glaucoma was identified as an IOP ≥ 22 mmHg with documented optic disk changes and/or visual field defects consistent with glaucoma. The optic disk changes were analyzed by a glaucoma subspecialist and included large cup-to-disk ratio (≥ 0.9) with thin neuroretinal rim, progressive optic disk cupping, asymmetric cup-disk ratio (≥ 0.3 difference), optic disk hemorrhage, or notching. Data were analyzed with the Statistical Package for the Social Sciences version 20.0 for Mac (IBM, Chicago, IL). Quantitative variables were described by mean with SD or in percentage. Longitudinal data analysis by mixed-effects models and Monte Carlo tests were used to compare categorical values.¹⁴⁻¹⁷ The Monte Carlo simulation performs risk analysis by building models of possible results by substituting a range of values, a probability distribution, for any factor that has inherent uncertainty, producing distributions of possible outcome values.

Results

A total of 368 patients met the inclusion criteria. Baseline demographic characteristics of the study cohort are summarized in Table 1. One hundred and sixty-nine patients were men and 199 were women. The mean age was 72 years (interquartile range [IQR], 67–77, range 63–89 years). This cohort had an average follow-up period of 36 months (IQR 23–56 months, range 12–92 months). At baseline, 32% (117/368) of the study eyes were already pseudophakic, and 68% (251/368) of the study eyes underwent combined phacovitrectomy. In our cohort, 57% (210/368) of the study eyes were treated with 23-gauge PPV, 29% (107/368) with 25 gauge, and 14% (51/368) underwent 27-gauge system (Table 2).

The distribution of IOP change from baseline is demonstrated in Figure 1. Mean IOP values of treated eyes and fellow nonvitrectomized eyes from baseline to the last follow-up visit are summarized in Figure 2. The longitudinal data analysis by mixed-effects models on preoperative IOP values demonstrated that there were no differences between treated (15.43 mmHg) and untreated fellow eyes (15.44 mmHg with 95% confidence interval [CI], -0.2 to 0.2 mmHg). At the 30-day follow-up control, a statistically significant 2.5-mmHg decrease of mean IOP values from baseline was evidenced in operated eyes in comparison with IOP mean values in both preoperative and fellow eyes (95% CI, 2.2–2.7 mmHg). This gap diminished, reverting to a not significant 0.2-mmHg (95% CI, -0.1 to 0.4 mmHg) difference within 26 months (t -value 4.5). At the end of the follow-up period, mean IOP increased 0.1 mmHg and 0.3 mmHg in operated and fellow eyes, respectively ($P = 0.43$; Figure 2). The duration of the follow-up period after vitrectomy is shown in Figure 3, with 284 patients (77%) of the 368 followed more than 36 months.

At the final visit, the incidence of IOP ≥ 22 mmHg or increased >4 mmHg from baseline was 5.7% (21 of 347, 95% CI, 2–12%) of vitrectomized eyes and 5.7%

Table 1. Baseline Demographic and Clinical Characteristics of the Study Cohort

Characteristics	
Study cohort	368
Sex (man:woman)	169:199
Mean age (IQR)	72 (67–77)
BCVA (treated fellow eye)	20/63–20/32
Mean IOP (treated fellow eye)	15.4–15.4
Pseudophakic (treated fellow eye)	32–41%
Phakic (treated fellow eye)	68–59%
Diabetes	18% (66/368)

BCVA, best-corrected visual acuity.

Table 2. Analysis of the Study Cohort and Eyes that Developed Late-Onset OHT According to the Gauge of Vitrectomy and the Follow-up Period

	Treated Eyes	Eyes With OHT
Gauge of vitrectomy		
23-G	57% (210/368)	62% (13/21)
25-G	29% (107/368)	29% (6/21)
27-G	14% (51/368)	9% (2/21)
Follow-up subgroup (m)		
12–24	7% (27/368)	(0/21)
24–36	16% (57/368)	9% (2/21)
36–48	17% (63/368)	24% (5/21)
48–60	16% (58/368)	20% (4/21)
60–72	19% (71/368)	24% (5/21)
72–84	16% (60/368)	14% (3/21)
84–92	9% (32/368)	9% (2/21)

m, months.

of unoperated fellow eyes. During the follow-up period, no elevation of IOP was found in unilateral treated eye.

Among the patients who developed late-onset OHT after PPV, 13 were men and 8 were women, ($P = 0.08$) with a mean age of 83 years (IQR 80–86, range 78–89 years). Six of these 21 patients (29%) were already pseudophakic, and 71% (15/21) underwent combined phacovitrectomy (Table 3). A 23-gauge vitrectomy was performed in 13 patients (62%), whereas 6 patients (29%) were treated using the 25-gauge system and 2 (9%) using the 27-gauge vitrectomy (Table 2). No P value for the gauge vitrectomy system was calculated because of the small number of events.

Seventeen of 21 study eyes that developed OHT required glaucoma medications and the remaining 4 eyes were followed without any treatment, with regression of increased IOP within the first year of scheduled visits. In the follow-up period, in five eyes, (1.4%, 5/368) OAG was newly diagnosed after vitrectomy, but only two study eyes had a progression of a glaucomatous visual defect despite topical medications and underwent surgical glaucoma treatment.

Finally, biometry parameters, including corneal pachymetry, axial length, anterior chamber depth, and keratometry, at the baseline were not statistically significant difference between the group of patients with normal IOP at final visit and the group that developed late-onset OHT (Table 4).

The Monte Carlo analysis revealed no significant difference in sex, lens status at the time of PPV, or gauge of vitrectomy instruments between the group with normal IOP and the group developing a late-onset OHT. Only age of patients was significantly higher (mean difference 4.2 years; 0.1–8.0 years, Monte Carlo, 95% CI) in those who developed late-onset OHT.

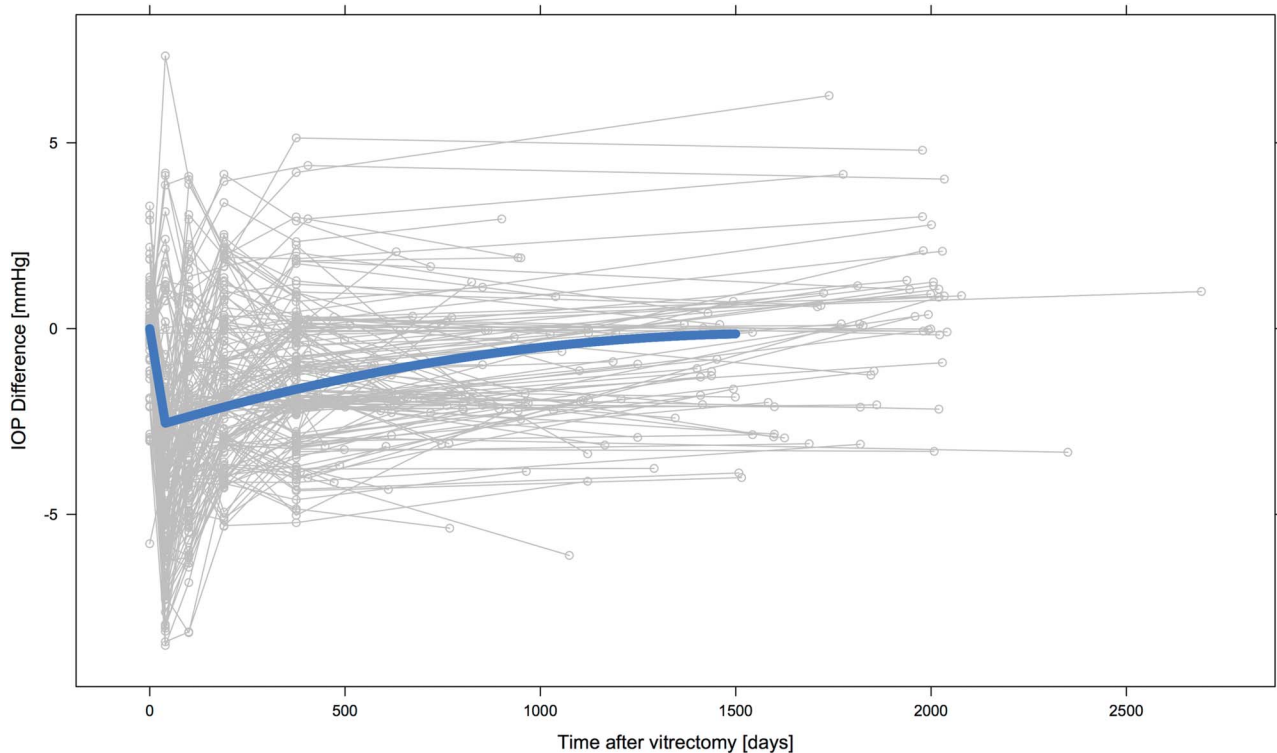


Fig. 1. Longitudinal data by mixed-effects model analysis reveals IOP change distribution in vitrectomized eyes for idiopathic ERM compared with fellow eyes as group control. The axis of ordinate shows the mean IOP difference between the treated eyes and the group control in function of the time after vitrectomy reported in the axis of abscissas. An early statistically significant 2.5-mmHg decrease of mean IOP values in operated eyes was found compared with the mean IOP values in both preoperative and fellow eyes at the 30-day follow-up control. This difference recovers to a not significant value within 26 months.

According to generalized linear model, we found no significant difference in the incidence of OHT between sex, gauge of vitrectomy instruments, and lens status at the time of PPV, between the vitrectomized eyes and treated eyes which developed late-onset OHT.

Discussion

In our study, uncomplicated PPV for idiopathic ERM seems not to increase the risk of late-onset OHT or OAG development.

Glaucoma represents the second largest cause of blindness worldwide, and the most common of glaucoma type in industrialized countries is primary OAG (POAG).¹⁸ According to the etiology, multifactorial conditions have been hypothesized. The most important risk factor is the increased IOP, and the risk of OAG is directly related with the IOP level.¹³

The exact mechanism that causes the late-onset OHT after vitrectomy has not been determined yet and many factors have been involved. The pathologic mechanisms leading to an increase of IOP are multiple and complex, in general, related to an increased outflow resistance.

Under normal physiological conditions, the intra-vitreous concentration of oxygen is not uniform. An oxygen concentration gradient exists with higher oxygen concentrations near the retinal surface as compared to the middle and anterior vitreous cavity.¹⁹ Normally, oxygen diffuses from the retinal arteries into the adjacent avascular vitreous. The gelatinous structure of the vitreous prevents wide diffusion of oxygen. Diffusion is inversely related to the viscosity of the medium. The vitreous is much more viscous than saline.²⁰ Before the oxygen gets a chance to diffuse widely, it is consumed by ascorbate, an antioxidant molecule in the vitreous cavity. This mechanism protects the crystalline lens from oxidative damage. Vitrectomy significantly increases the intravitreal oxygen concentration and eliminates the intravitreal oxygen gradient normally found in nonvitrectomized eyes.^{21,22} The removal of the vitreous gel removes ascorbate and decreases its viscosity, allowing mixing and uniform distribution of oxygen in the vitreous cavity fluid.²³

Chang was the first to raise the association of late development of OAG after uncomplicated PPV at LXII Edward Jackson Memorial Lecture and hypothesized the mechanism of increased oxidative damage

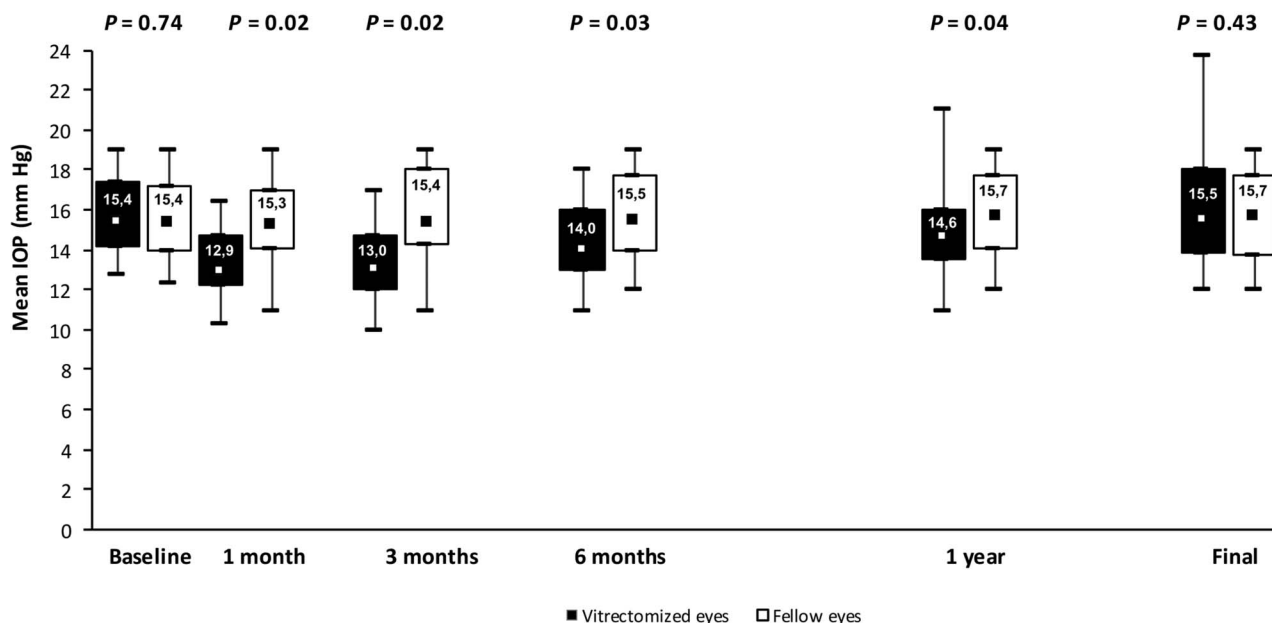


Fig. 2. Box and whisker summary distributions of treated (black box) and fellow nonvitrectomized eyes (white box) at each time point of the follow-up. The final follow-up corresponds to the median follow-up period of 36 months. At baseline, no significant IOP difference was found. After the statistically significant decrease of mean IOP value between the treated and fellow control eyes at the 30-day follow-up control, the values recover to a not significant value within 26 months. At the final visit, no significant IOP difference was detected.

to the trabecular meshwork.⁸ After vitrectomy in phakic eyes, the increased oxygen concentration contributes to the pathogenesis of nuclear sclerosis. Siegfried et al²⁴ reported that there is no oxygen consumption by the vitreous or the lens in vitrectomized pseudophakic or aphakic eyes. So, the increased oxygen concentration flows into the anterior chamber and finds its way to the trabecular meshwork, where it can cause oxidative damage. Chang estimated that up to 20% of eyes may be at risk of development of OAG

after vitrectomy. However, the Chang's analysis did not completely account for all IOP changes and a large percentage of the eyes included in his series had previous vitrectomy, previous or concomitant scleral buckling, or gas tamponade. In addition, vitrectomies for retinal detachment, retained lens fragment, and dislocated intraocular lens were included. These surgeries may predispose toward OAG because of longer operating times and higher complications rate, which may increase tissue trauma and inflammation.¹⁰ Several

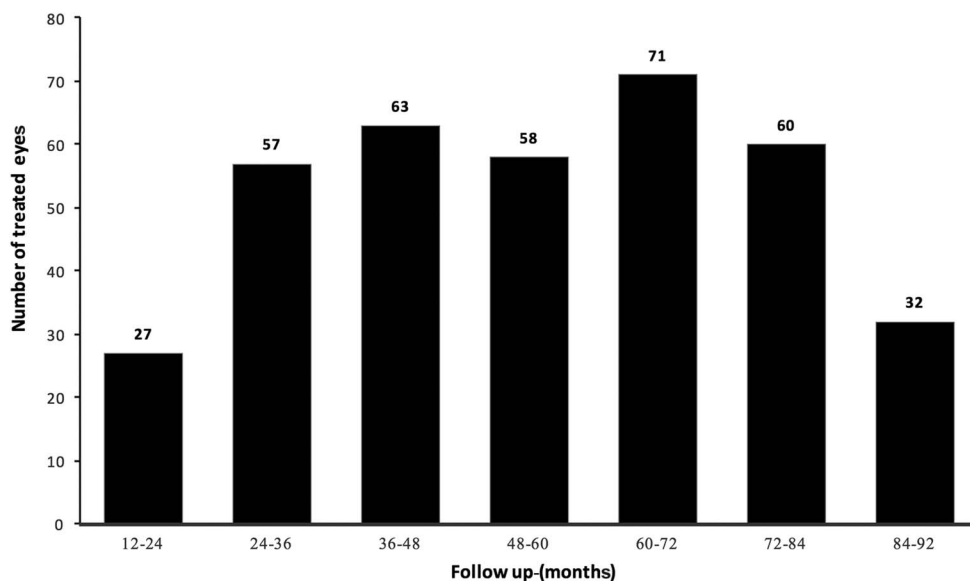


Fig. 3. Histogram showing the number of eyes that underwent uncomplicated PPV for idiopathic ERM as a function of the duration of the follow-up period.

Table 3. Characteristics of the Eyes that Developed Late-Onset OHT

Characteristic	
Sex (male:female)	13:8
Mean age (y)	83 (IQR 80–86)
Underwent phacovitrectomy	71% (15/21)
Underwent vitrectomy	29% (6/21)
Glaucoma medications required	81% (17/21)
Observed without treatment	19% (4/21)
OAG diagnosed	24% (5/21)

recent analyses have reported late development of OAG after PPV.^{4–7} Koreen et al⁴ analyzed a larger study population of 285 eyes, in which vitrectomy was performed for a variety of indications including vitreous hemorrhage (18.2%), retinal detachment (16.5%), crystalline lens dislocation (6.1%), and intraocular lens dislocation (3%). In their study, an overall 11.6% incidence of OAG development in vitrectomized eyes was reported. The studies by Chang et al⁸ and Koreen et al,⁴ which reported the highest incidence of postvitrectomy glaucoma development, had the broadest inclusion criteria including eyes that had undergone previous vitrectomy and scleral buckling. Toyokawa et al⁵ included various vitreoretinal diseases. Of the 767 eyes examined, 32 eyes (4.2%) developed late-onset hypertension with no significant differences in the incidence of OHT between the different subgroups. However, the authors reported a higher incidence of 4.2% in their series compared with the prevalence of OHT in the Tajimi study of Japanese population (0.8%).²⁵ Fujikawa et al⁶ studied a more homogenous patient population including 108 consecutive eyes that received vitrectomy for MH or ERM. The last visit demonstrated an increased IOP in 4 (7.0%) treated and fellow eyes in ERM group, and 10 (8.2%) operated eyes and 7 (4.9%) fellow eyes in the MH group. This series reported a significant difference between the operated eyes and fellow eyes only in the MH group ($P < 0.01$), whereas no differences in the ERM group were detected. They suggested that face-down postoperative position and a clogging of the trabecular meshwork with intraoperative sludge after fluid–gas exchange could have a role

for developing an increased postoperative IOP in MH surgery.

In a multicenter study, including 198 patients who received vitrectomy for idiopathic ERM, Wu et al⁷ considered their fellow unoperated eyes as the control. Patients with any type of postoperative tamponade or an IOP spike during first postoperative month were excluded. Thirty-eight (19.2%) of the vitrectomized eyes developed an IOP increase compared with nine (4.5%) fellow unoperated eyes. This study did not examine the incidence of glaucoma development. They concluded that uncomplicated vitrectomy may increase IOP, especially in pseudophakic patients or with a family history of OAG.

By contrast, other reports did not find any association between OAG or increase in IOP and uncomplicated PPV.^{9–11} Yu et al⁹ analyzed a large series of 441 eyes that underwent PPV for various indications including retinal detachment (29%), ERM (28%), MH (25%), choroidal neovascularization (12%), synchysis scintillans (4%), and vitreomacular traction syndrome (2%). No statistically significant difference in the incidence of OAG or OHT between vitrectomized and fellow control eyes, or between phakic and pseudophakic vitrectomized groups, was found. In addition, the authors reported no correlation between OHT or OAG and the lens status, even if the number of phakic vitrectomized eyes ($n = 61$) were lower than the number of pseudophakic vitrectomized eyes ($n = 177$). Lalezary et al¹⁰ evaluated a smaller population with greater heterogeneity than those of the studies by Yu et al,⁹ including eyes with complications related to diabetic retinopathy. The 101 eyes in their study underwent vitrectomy for nonclearing vitreous hemorrhage (37%), chronic macular edema (11%), and tractional retinal detachment (3%), in addition to an ERM (36%) and MH (14%). Patients with previous or concomitant scleral buckle and previous vitrectomy were excluded. The authors reported a much lower incidence of OAG development compared with those reported by Chang et al.⁸ None of the eyes developed OAG or required glaucoma treatment, and only four eyes were newly diagnosed with OHT. In this report, the inclusion of diabetic eyes (62% of study population) may be

Table 4. Comparisons of Biometric Parameters Between the Eyes With Normal IOP at Final Visit and the Group That Developed Late-Onset OHT

	Eyes With Normal IOP	Eyes With Ocular Hypertension	P^*
Pachymetry (μm)	576.12 \pm 46.89	565.12 \pm 42.05	0.084
Axial length (mm)	23.83 \pm 1.56	23.86 \pm 1.60	0.893
Anterior chamber depth (mm)	3.44 \pm 0.37	3.52 \pm 0.41	0.106
Keratometry (D)	44.34 \pm 1.54	44.22 \pm 1.38	0.472

*Paired sample t -test.

a confounding factor. Subgroup analysis of 66 fellow eyes that had not undergone previous vitrectomy did not find any significant difference in rates of increased IOP > 4 mmHg between vitrectomized and fellow eyes. Lens status and diabetes did not alter mean IOP change comparing vitrectomized and fellow eyes.¹⁰ Last, Mi et al¹¹ analyzed a large series of 234 eyes of 234 patients, 100 MHs (42.7%) and 134 idiopathic ERMs (57.3%), who underwent a 20-, 23-, or 25-gauge PPV. The fellow eyes were used as group control. Mean IOP values in vitrectomized were significantly lower at baseline, 3-month, and 6-month control and lower but not significantly at 1-year, 2-year, and final follow-up visits after surgery when compared with fellow eyes. The incidence of OAG found in this study was 2.6% in vitrectomized eyes and 1.7% in fellow control eyes and is comparable with that reported by studies evaluating the overall incidence of OAG.²⁶ These percentages are much lower than the incidence of glaucoma development after vitrectomy reported by Chang⁸ (15–20%), Koreen et al⁴ (11.6%), Fujikawa et al⁶ (7–8.2%), and Wu et al⁷ (19.2%). All the studies' references had similar OHT or OAG definitions. The review of these conflicting studies raises the question of why some studies found a link between vitrectomy and increased IOP or glaucoma, whereas others with a similar study size and follow-up duration did not. One possible source of different findings could be that the risk of OAG development after vitrectomy is higher just for some surgical diseases.

Our study has been conducted only on patients who underwent PPV for an idiopathic ERM. We observed a statistically significant 2.5-mmHg decrease of mean IOP values in operated eyes in comparison with the mean IOP values in both preoperative and fellow eyes at the 30-day follow-up control. This difference in mean IOP values recovers to a not significant 0.2 mmHg within 26 months. At the end of the follow-up period, mean IOP increased 0.1 mmHg and 0.2 mmHg in operated and fellow eyes, respectively. In our series, 5.7% of 368 patients developed bilateral IOP \geq 22 mmHg or increased >4 mmHg from baseline. No unilateral treated eye IOP elevation was found, as further proof of the fact that uncomplicated PPV for idiopathic ERM seems not to increase the OAG development. We found no variable to have a significant association with late-onset OHT, including gauge of vitrectomy instrument, despite the different surgical approach at the end of surgery. Indeed, the 23-gauge vitrectomy was performed with suture of sclerotomy, whereas the 25-gauge and 27-gauge vitrectomy were sutureless completed. We also did not observe a relationship between lens status at the time of PPV and incidence of increased IOP. Only the age seems to be significantly higher in those who

developed late-onset OHT with a mean age of 83 years (IQR 80–86, range), as well reported in literature.^{25–28}

The prevalence of OHT related to racial variations in nonvitrectomized eyes has been shown in different studies.^{25–27} The Ponza Eye Study,²⁸ conducted on an Italian population, reported a 3.8% overall incidence of POAG, rising to 6.2% and 6.7% in age-related subgroups, 60 to 70, and >70 years, respectively. The 1.4% POAG incidence observed in our analysis is in agreement with the results of the Ponza Eye Study, in the same race and age subgroups. In the Ocular Hypertension Treatment Study²⁹, the authors found a cumulative probability of developing POAG of 9.5% in patients with OHT. In our report, we newly diagnosed OAG in 5 of 21 eyes with late-onset OHT. This higher rate (23.4%) could be related to the different mean age of the patients enrolled in the series, as previously reported by Gordon et al¹³ who confirmed that baseline age was a good predictive factor for the development of POAG in the individuals with OHT. In the analysis by Kass et al,²⁹ only 7.2% of the study population had a range of age comparable with our cohort (mean age 72 years). In our series, in a large percentage of treated eyes 30 days after surgery, IOP was significantly lower than baseline also when compared with fellow unoperated eyes. This IOP difference subsequently recovers to the baseline value within 26 months of the follow-up period with no significant differences between 2 groups (*t*-value 4.5). The lower IOP within the 26-month follow-up period may result from decreased production or increased outflow. Vitrectomy may alter scleral rigidity and thereby affect episcleral venous pressure, which has a direct relationship with IOP.¹¹ Increased oxygen tension after vitrectomy may cause arterial constriction, which may reduce blood flow to the ciliary body and limit production of aqueous humor.³⁰ Conventional anterior pathways of aqueous flow may be altered without the vitreous body and result in more posterior flow into an empty cavity, readjusting the fluid-IOP dynamic. To minimize confounding factors, we enrolled only patients with same indication for PPV, idiopathic ERM, in which no use of tamponade at the end of surgery was required. Furthermore, none of the eyes had exposure to indocyanine green dye during surgery, which is a potential cause of concentric and nasal visual field defects.³¹

Despite the homogeneity of patients examined, our study has some limitations. The follow-up duration was not the same for all patients. The minimum period of follow-up was 12 months and it is reasonable to assume that this period is insufficient to evaluate the onset of OHT or POAG. Nevertheless, this limitation affects only a limited part of the study population

because 284 patients (77%) of 368 were followed more than 36 months (Figure 3). In addition, previous study has suggested that the lens sparing may protect the anterior segment from oxidative stress and may retard the development of OAG.⁸ We cannot exclude this condition because our study was performed only on previous pseudophakic eyes or pseudophakic at the time of combined phacovitrectomy.

Finally, an essential point to consider is the circumstance that OHT was already developing in the eye regardless of the vitrectomy. Before vitrectomy, the patients could have been at the early stage of undiagnosed POAG. According to the slowly natural course of glaucoma, we cannot completely exclude this occurrence. However, to minimize this confounding factor in our series, we analyzed the contralateral untreated fellow eye as control, and no unilateral late-onset OHT was found.

In conclusion, in our study, uncomplicated PPV for idiopathic ERM seems not to increase the risk of late-onset OHT or OAG development. No unilateral-treated eye IOP elevation and no statistically significant association between late-onset OAG or OHT and sex, biometric parameters, lens status, or gauge of vitrectomy instruments were detected, as further proofs of the fact that uncomplicated PPV for idiopathic ERM seems not be influenced incidence of OAG development. The most important issue is to continue long-term follow-up examinations after PPV. Nevertheless, a prospective controlled clinical trial analyzing changes in retinal nerve fiber thickness and IOP after vitrectomy would provide important insight into this topic, which may strengthen these results.

Key words: 23-, 25-, or 27-gauge vitrectomy, idiopathic epiretinal membrane, intraocular pressure, late-onset ocular hypertension, open-angle glaucoma, pars plana vitrectomy.

References

- Han DP, Lewis H, Lambrou FH Jr, et al. Mechanisms of intraocular pressure elevation after pars plana vitrectomy. *Ophthalmology* 1989;96:1357–1362.
- Chen CJ. Glaucoma after macular hole surgery. *Ophthalmology* 1998;105:94–99.
- Costarides AP, Alabata P, Bergstrom C. Elevated intraocular pressure following vitreoretinal surgery. *Ophthalmol Clin North Am* 2004;17:507–512.
- Koreen L, Yoshida N, Escario P, et al. Incidence of, risk factors for, and combined mechanism of late-onset open-angle glaucoma after vitrectomy. *Retina* 2012;32:160–167.
- Toyokawa N, Kimura H, Matsumura M, et al. Incidence of late-onset ocular hypertension following uncomplicated pars plana vitrectomy in pseudophakic eyes. *Am J Ophthalmol* 2015;159:727–732.
- Fujikawa M, Sawada O, Kakinoki M, et al. Long-term intraocular pressure changes after vitrectomy for epiretinal membrane and macular hole. *Graefes Arch Clin Exp Ophthalmol* 2014;52:389–393.
- Wu L, Berrocal MH, Rodriguez FJ, et al. Intraocular pressure elevation after uncomplicated pars plana vitrectomy: results of the Pan American Collaborative Retina Study Group. *Retina* 2014;34:1985–1989.
- Chang S. LXII Edward Jackson lecture: open angle glaucoma after vitrectomy. *Am J Ophthalmol* 2006;141:1033–1043.
- Yu AL, Brummeisl W, Schaumberger M, et al. Vitrectomy does not increase the risk of open-angle glaucoma or ocular hypertension—a 5-year follow-up. *Graefes Arch Clin Exp Ophthalmol* 2010;248:1407–1414.
- Lalezary M, Kim SJ, Jiramongkolchai K, et al. Long-term trends in intraocular pressure after pars plana vitrectomy. *Retina* 2011;31:679–685.
- Mi CW, Thompson JT. Long-term follow-up of intraocular pressure after vitrectomy in eyes without preexisting glaucoma. *Retina* 2015;35:2543–2551.
- Drance SM. The significance of the diurnal tension variations in normal and glaucomatous eyes. *Arch Ophthalmol* 1960;64:494–501.
- Gordon MO, Beiser JA, Brandt JD, et al. The Ocular Hypertension Treatment Study: baseline factors that predict the onset of primary open-angle glaucoma. *Arch Ophthalmol* 2002;120:714–720.
- Faraway JJ. *Extending the Linear Model With R: Generalized Linear, Mixed Effects and Nonparametric Regression Models*. Boca Raton, FL: CRC Press; 2005.
- Pesarin F, Salmaso L. *Permutation Tests for Complex Data: Theory, Applications and Software*. Chichester, UK: John Wiley & Sons; 2010.
- Core Team R. *R: A Language and Environment for Statistical Computing*. Vienna: R Foundation for Statistical Computing; 2014.
- Verbeke G, Molenberghs G. *Linear Mixed Models for Longitudinal Data*. New York: Springer Science & Business Media; 2000.
- Renard JP, Rouland JF, Bron A, et al. Nutritional, lifestyle and environmental factors in ocular hypertension and primary open-angle glaucoma: an exploratory case-control study. *Acta Ophthalmol* 2013;91:505–513.
- Sakaue H, Negi A, Honda Y. Comparative study of vitreous oxygen tension in human and rabbit eyes. *Invest Ophthalmol Vis Sci* 1989;30:1933–1937.
- Gisladdottir S, Loftsson T, Stefansson E. Diffusion characteristics of vitreous humour and saline solution follow the Stokes Einstein equation. *Graefes Arch Clin Exp Ophthalmol* 2009;247:1677–1684.
- Barbazetto IA, Liang J, Chang S, et al. Oxygen tension in the rabbit lens and vitreous before and after vitrectomy. *Exp Eye Res* 2004;78:917–924.
- Holekamp NM, Shui YB, Beebe DC. Vitrectomy surgery increases oxygen exposure to the lens: a possible mechanism for nuclear cataract formation. *Am J Ophthalmol* 2005;139:302–310.
- Stefansson E. Physiology of vitreous surgery. *Graefes Arch Clin Exp Ophthalmol* 2009;247:147–163.
- Siegfried CJ, Shui YB, Holekamp NM, et al. Oxygen distribution in the human eye: relevance to the etiology of open-angle glaucoma after vitrectomy. *Invest Ophthalmol Vis Sci* 2010;51:5731–5738.
- Iwase A, Suzuki Y, Araie M, et al; The Tajimi Study Group, Japan Glaucoma Society. The prevalence of primary open-angle glaucoma in Japanese: the Tajimi Study. *Ophthalmology* 2004;111:1641–1648.

26. Friedman DS, Wolfs RC, O'Colmain BJ, et al; Eye Diseases Prevalence Research Group. Prevalence of open-angle glaucoma among adults in the United States. *Arch Ophthalmol* 2004;122:532–538.
27. Varma R, Ying-Lai M, Francis BA, et al; Los Angeles Latino Eye Study Group. Prevalence of open-angle glaucoma and ocular hypertension in latinos: the Los Angeles Latino Eye Study. *Ophthalmology* 2004;111:1439–1448.
28. Cedrone C, Mancino R, Ricci F, et al. The 12-year incidence of glaucoma and glaucoma-related visual field loss in Italy: the Ponza eye study. *J Glaucoma* 2012;21:1–6.
29. Kass MA, Heuer DK, Higginbotham EJ, et al. The Ocular Hypertension Treatment Study: a randomized trial determines that topical ocular hypotensive medication delays or prevents the onset of primary open-angle glaucoma. *Arch Ophthalmol* 2002;120:701–713.
30. Dallinger S, Dorner GT, Wenzel R, et al. Endothelin-1 contributes to hyperoxia-induced vasoconstriction in the human retina. *Invest Ophthalmol Vis Sci* 2000;41:864–869.
31. Yamashita T, Uemura A, Kita H, et al. Long-term outcomes of visual field defects after indocyanine green-assisted macular hole surgery. *Retina* 2008;28:1228–1233.