

See discussions, stats, and author profiles for this publication at: <https://www.researchgate.net/publication/286459832>

Spinas E., Aresu M., Canargiu F., Giannetti L.. Preventive treatment of post-traumatic dental infraocclusion: study on...

Article · December 2015

CITATIONS

0

READS

84

3 authors, including:



E. Spinas

Università degli studi di Cagliari

42 PUBLICATIONS 167 CITATIONS

SEE PROFILE

Some of the authors of this publication are also working on these related projects:



cone beam and mouth guard [View project](#)



Sport and Dental Traumatology [View project](#)

E. Spinas*, M. Aresu**, F. Canargiu**,
L. Giannetti***

*University of Cagliari, Department of Surgical Sciences,
Dental Prosthetic Division

**University of Cagliari, Department of Surgical Sciences,
Periodontology division

***University of Modena-Reggio, Department of Surgical
Sciences, Pedodontics division

e-mail: enricospinas@tiscali.it

Preventive treatment of post-traumatic dental infraocclusion: study on the knowledge of dental decoronation in a sample of Italian dental students and dentists

ABSTRACT

Aim The aim of the present work is to investigate whether dental decoronation is a procedure known by a sample of dental students and Italian dentists. Dental decoronation technique is performed in order to mitigate the outcomes which may occur after a delayed tooth replantation.

Materials and methods A cognitive survey about the knowledge of the dental decoronation technique was carried on two groups: a sample of 120 dental students (5th year of dental school), from University of Cagliari, Sassari and of Chieti-Pescara (60 males and 60 females), and a group which involved 200 Italian dentists (200 subjects, of age comprised between 25 and 45, 130 females and 70 males) enrolled at pedodontics and orthodontics Masters and CE courses (University of Roma Sapienza, Chieti-Pescara, Cagliari). The latter group's main field of work was paediatric dentistry and orthodontics, two dental specialties often involved in treating Traumatic dental injuries.

Results Only 20 dentists out of the 200 interviewed

answered that they knew this technique and only 5 of them proved to know it and were able to describe it correctly. No students interviewed knew this technique.

Conclusion It is apparent from the results of this survey that there is very little information about the dental decoronation technique both during the Degree Course in Dentistry and Post Graduate specialty programmes (Continuing Education Courses and Masters).

Keywords Avulsed tooth; Decoronation; Tooth Replantation.

Introduction

Dental ankylosis is often seen in adolescents who received a delayed post-traumatic tooth replantation [Andersson et al., 2012]. In addition to being characterised by gradual root resorption with bone remodeling (Fig. 1), ankylosis also exhibits an apparent dental infraocclusion of the tooth involved [Andersson et al., 1989]. Delayed dental replantations are those performed more than an hour after the traumatic avulsion or when the avulsed tooth was in conditions of poor (dry) conservation [Andreasen et al., 1995]. Moreover, the younger the patient at the time of trauma, the more severe the degree of dental infraocclusion at the end of the dentoskeletal growth [Hammarstrom et al., 1989], and subsequently, the more difficult the dental implant rehabilitation of the traumatised lost tooth will be [Sapir S. et al., 2009].

In cases where dental infraocclusion is diagnosed, there may also be extensive root resorption accompanied by an arrest of growth of the local alveolar bone. In such cases, decoronation of the infraoccluded tooth may be the most suitable preservation method to avoid future crestal bone loss, which often requires extensive regenerative procedures in order to rebuild bone necessary for optimal aesthetic restoration [Cohenca and Stabholz, 2007]. When an ankylosed tooth is left in place, infraocclusion will tend to worsen

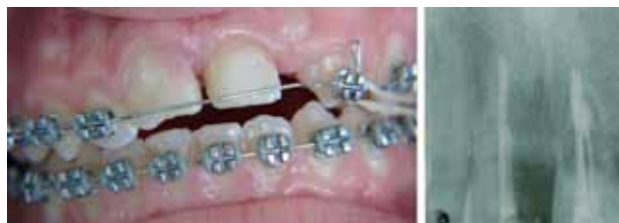

FIG. 1 Clinical image and radiograph of an infraoccluded upper central incisors showing ankylosis and advanced root resorption.

In most cases temporary mutilation of a crown should be performed on patients aged between 12 and 14, i.e. the period when the puberal bone growth usually occurs, something which, in fact, discourages parents of young patients from giving consent to this procedure [Sapir and Shapira., 2008].

The aim of the present work is to investigate to what extent Italian dental school students and dentists are familiar with the dental decoronation procedure. Therefore, a cognitive survey was carried out on a sample of fifth-year dental students and on a second sample of dental professionals, whose main fields of work were paediatric dentistry and orthodontics, namely the two areas of dentistry mainly involved in the treatment of traumatic dental injuries.

Materials and methods

In the academic year 2013-2014, 120 fifth-year dental school students (60 males, and 60 females) from the University of Cagliari (40 students), Sassari (40 students), and Chieti-Pescara (40 students) were interviewed in order to assess their knowledge of the dental decoronation technique. All subjects interviewed had completed their course of study and exams and were about to graduate.

Students was given 20 minutes to fill a brief anonymous questionnaire (Table 2), divided into two parts: the first was designed to collect demographic information, the second consisted of the following 3 basic questions (Table 1):

- 1) Do you know what the dental decoronation technique is?
- 2) Can you describe it?
- 3) Please specify the course in which this procedure was taught.

All the 120 questionnaires were answered.

Student Questionnaire

Personal Details:

- Gender:
- Birthplace:
- Degree course:
- University:
- Academic year:

Questions about Decoronation:

- Do you know the dental decoronation technique?
- Can you describe it?
- Please specify the course in which this procedure was taught

TABLE 1 Student Questionnaire.

During the same academic year a similar survey was carried out on a sample of Italian dentists attending Masters and CE courses (University of Roma Sapienza, Chieti-Pescara, and Cagliari) in paediatric dentistry and orthodontics.

A total of 200 practicing dentists aged between 25 and 45 (130 females and 70 males) were given a brief anonymous questionnaire (Table 2), divided into two parts: the first was designed to collect demographic information, the second consisted of the following 4 questions on the dental decoronation technique:

- 1) Do you know what the dental decoronation technique is?
- 2) Can you briefly describe the various stages involved?
- 3) Did you ever performed it?
- 4) What results did you obtain and how many cases did you treat?

Dentists were given 30 minutes were allowed to complete the questionnaire. All of them were completed.

Statistical analysis

We tested for any statistical correlation between the degree of knowledge/no-knowledge of the decoronation technique and applied relevant variables such as gender, geographical place of training (north, central, south of Italy), years of experience (10 years of activity, more than 10 years, over 20 years), and the type of specialisation (general dentist, paediatric dentist and paedodontics-orthodontics dentist).

Results

The personal data of the group of 200 dentists showed that academic training was equally distributed geographically, i.e. 70 were from Northern Italy (40 F and 30 M), 68 from Central Italy (50 F and 18 M), and

Dentist Questionnaire

- Personal Details

- Gender:
- Birthplace:
- Degree course:
- University:
- Specialization:
- Years of professional activity:

Questions about Decoronation:

- Do you know the dental Decoronation technique?
- Can you briefly describe the various realization stages?
- Did you ever used this technique?
- Which results did you get? how many cases did you treat?

TABLE 2 Dentist Questionnaire.

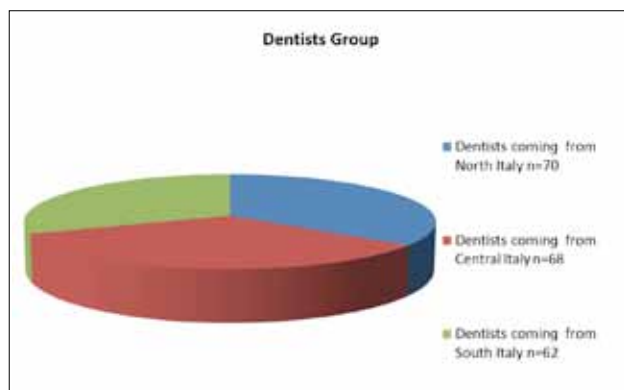


TABLE 3 Analysis of the dentists: area of origin.

62 (40 F and 22 M) from Southern Italy and islands (Table 3).

Regarding the years of experience, 104 participants had less than 10 years of professional activity, 86 had more than 10 years, and 10 stated they had been working for more than 20 years (Table 4).

With regard to the professional areas of specialisation, 90 (60 F and 30 M) participants stated they worked mainly as paedodontists and orthodontists, 50 (40 F and 10 M) worked exclusively in paediatric dentistry, while 60 (30 F and 30 M) dentists reported to work in general dentistry along with occasional work in paediatric dentistry.

As for the second part of the questionnaire, relating to the knowledge of dental decoronation [Malmgren, 2013; Sigurdsson, 2009] we found that 180 out of the 200 interviewed stated they were not familiar with this technique and its field of application (Table 5). Only 20 subjects (12 females and 8 males) knew the procedure and therefore were able to answer the following 3 items of the questionnaire.

As regards answers to question 2, 10 participants (6 females and 4 males) were not able to describe the technical phases; 5 interviewees (3 females and 2 males) described methods not pertinent to this procedure; only 5 participants (3 females and 2 males) proved to be familiar with this procedure, describing it correctly in all its main features [Malmgren B., 2000] (Table 6).

Finally, the results for questions 3 and 4 were as follows: only 2 of those interviewed (both females) asserted they had performed this technique in a few cases (5 in total) with good results (small alveolar bone loss).

Of the 5 participants (out of 200) who answered the questionnaire correctly, 2 were from Northern Italy, 1 from Central Italy and 2 were from Southern Italy.

Regarding their years of working activity, 2 of these reported less than 10 years of activity, 2 more than 10 years and 1 more than 20 years.

Table 7 shows the level of knowledge and required skills for this technique existing among the 'dentists'

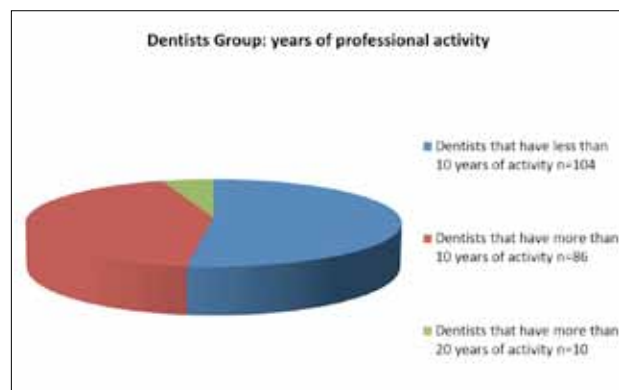


TABLE 4 Analysis of the dentists: years of professional activity.

group. The results of an analysis of questionnaires from the student group were very clear indeed, in that none of the students interviewed claimed to know or even to have heard of this procedure during their classes in dental school.

Statistical results

Data were analysed using STATA-13 package (Stata

The Decoronation Technique:	
-	A mucoperiosteal flap is raised and the crown is removed with a diamond bur under continuous saline irrigation.
-	The root filling is removed with an endodontic file and the coronal part of the root surface is reduced to 2 mm below the marginal bone.
-	The empty root canal is thoroughly rinsed with saline and thereafter allowed to fill with blood, this is very important, as the blood clot is organized from the surrounding tissues.
-	The mucoperiosteal flap is drawn over the alveolus and sutured with single sutures. A blood clot forms in the gap between the labial and palatal mucosa.

TABLE 5 Descriptive stage of the dental decoronation technique [from: Malmgren, 2000].

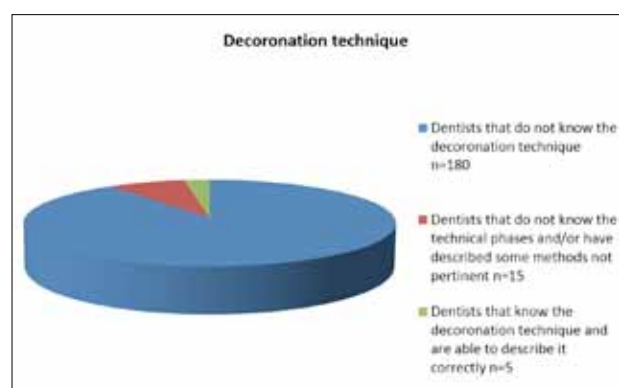


TABLE 6 Survey of the dentists: answers related to the knowledge of the dental decoronation technique.

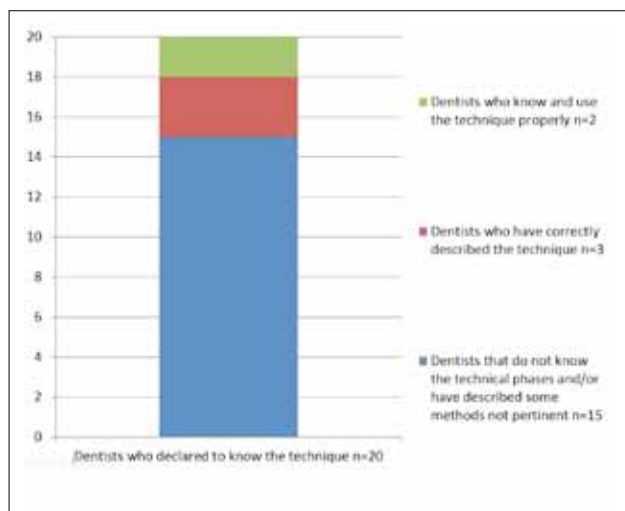


TABLE 7 The graph shows significant differences among the 20 dentists who declared to know the dental Decoronation technique.

Corp LP4905 Lakeway Drive College Station, Texas - USA).

Due to the sparsity of the contingency tables that cross tabulate the joint distribution of the binary variable 'KNOW/NOT KNOW' of the decoronation technique with the explanatory variables (i.e. Sex, Geography, Experience, Specialisation), we opted to use the Fisher's "Exact Test". The p-values obtained are given in Tables 8 and 9. Table 8 represents the p-value for the variable KNOW/NOT KNOW with respect to the variable of the different categories.

Table also represents the p-values of the Fisher's "Exact Test" calculated for the cross tabulation of the variable KNOW/NOT KNOW with the explanatory variables, considering only those respondents who demonstrated a real knowledge of the technique (5 subjects).

As shown, with an α level set at 0.05, there is sufficient statistical evidence to reject the null hypothesis that there is no association between the response variable and the different explanatory variables considered.

Discussion

It is apparent from the results of this survey that there is very little information imparted on the dental decoronation technique, either during Dentistry Degree Courses or in Post Graduate Specialisation programmes.

This result does not seem surprising in the light of previous surveys [De Vasconcellos et al., 2009] and a recent survey on topics related to the treatment and handling of dental traumas carried out on a sample of 500 Italian dentists [Re et Al., 2014].

These reviews reveal lack of knowledge regarding

Test	p-value
KNOW vs Sex	0.628
KNOW vs Geography	0.463
KNOW vs Experience	0.326
KNOW vs Specialisation	0.494

TABLE 8 Results obtained by applying the Fisher's exact test to the initial study group of Dentists (200 interviewed).

Test	p-value
KNOW2 vs Sex	1.000
KNOW2 vs Geography	0.865
KNOW2 vs Experience	0.278
KNOW2 vs Specialisation	0.721

TABLE 9 Results obtained by applying the Fisher's exact test to the Dentist group who have demonstrated knowledge of the technique (5 subjects).

the handling and treatment of traumatic avulsions and the subsequent need to perform tooth replantation (only 23% of the sample answered the questions on this subject correctly). As stated earlier, the dental decoronation technique is performed in order to mitigate the effects of undesired outcomes which can occur after a delayed tooth replantation.

It seems understandable therefore that only 20 dentists out of 200 interviewed in our survey stated that they knew this technique but only 5 proved to have a full knowledge of it and were thus able to describe it correctly. This finding is particularly surprising given that 140 out of 200 respondents said that they mainly worked in orthodontics and/or paedodontics.

Further confirmation of this data emerged in our survey of the 120 dental school students interviewed. None of them were able to answer questions correctly and most had no knowledge of this technique whatsoever.

Even though the sample was fairly restricted, our survey also revealed that there was no significant difference regarding the geographical location of the participants' academic training and the knowledge of the topic. In fact, the 200 dentist participants were evenly distributed in terms of geographical area of origin and there was no statistical evidence of association between the response variable and the explanatory variables considered. Furthermore, of the 5 interviewees who correctly answered the second part of the questionnaire, 2 were from Northern Italy, 1 from Central Italy and 2 were from Southern Italy. The data concerning the dental school students interviewed provided further confirmation of our results, in spite of the relatively low number of the sample and the limited distribution of their home

universities throughout the Italian national territory. Even the data relating to the number of working years showed no positive correlation between years of activity and accurate knowledge of the dental decoronation technique. Indeed, of the 5 dentists who proved to know this technique, 2 of them had less than 10 years of work experience, 2 more than 10 years and 1 more than 20 years of experience; this data actually corroborated those inferred from a recent survey done by Re et al. (2014).

Finally, only 2 interviewees (both females, one from the North and one from Southern Italy) stated they had performed this technique in a few cases and that they had obtained good predictable results (5 cases total).

Conclusion

It seems apparent from the literature data that there is a significant lack of knowledge of traumatology and tooth replantations, which in turn results in lack of knowledge and use of the advantages offered by the dental decoronation technique.

Our study samples showed a clear lack of knowledge in this specific area of dental traumatology both in the dental student group and in the dentists group.

Such a void needs to be filled with the creation of proper courses during the degree course in dentistry as well as with the establishment of new specialty post graduate programs (continuing professional education courses and masters).

The data presented here have to be further confirmed with surveys involving a larger number of dental students, professional dentists and with a greater number of Universities, in order to implement the specific areas of training.

It is our firm belief that more clinical studies ought to be performed in order to confirm the positive results obtained with the use of the dental decoronation technique in the field of traumatic tooth avulsions in

adolescent age, along with a better training concerning the results obtained from using this technique.

References

- › Andersson L, Andreasen JO, Day P, Heithersay G, Trope M, Diangelis AJ, Kenny DJ, Sigurdsson A, Bourguignon C, Flores MT, Hicks ML, Lenzi AR, Malmgren B, Moule AJ, Tsukiboshi M. International Association of Dental Traumatology guidelines for the management of traumatic dental injuries: 2. Avulsion of permanent teeth. *Dent Traumatol*. 2012 Apr;28(2):88-961.
- › Andersson L, Bodin I, Sörensen S, Progression of root resorption following replantation of human teeth after extended extra-oral storage. *Endod Dent Traumatol* 5(1):38-47, 1989.
- › Andreasen JO, Borum MK, et al, Replantation of 400 avulsed permanent incisors, 4. Factors related to periodontal ligament healing. *Endod Dent Traumatol* 11(2):76-89, 1995.
- › Cohenca N, Stabholz A. Decoronation - A conservative method to treat ankylosed teeth for preservation of alveolar ridge prior to permanent prosthetic reconstruction: literature review and case presentation. *Dent Traumatol* 2007 Apr;23(2):87-94.
- › Cohenca N, Forrest JL, Rotstein I. Knowledge of oral health professionals of treatment of avulsed teeth. *Dent Traumatol* 2006 Dec;22(6):296-301.
- › De Vasconcellos LG, Brentel AS, Vanderlei AD, de Vasconcellos LM, Valera MC, de Araújo MA. Knowledge of general dentists in the current guidelines for emergency treatment of avulsed teeth and dental trauma prevention. *Dent Traumatol* 2009 Dec;25(6):578-83.
- › Ebeleseder KA, Friehs S, et al, A study of replanted permanent teeth in different age groups. *Endod Dent Traumatol* 14(6):274-8, 1998.
- › Hammarström L, Blomlof L, Lindskog S, Dynamics of dentoalveolar ankylosis and associated root resorption. *Endod Dent Traumatol* 5(4):163-75, 1989.
- › Lin S, Schwarz-Arad D, Ashkenazi M. Alveolar bone width preservation after decoronation of ankylosed anterior incisors. *J Endod* 2013 Dec;39(12):1542-4.
- › Malmgren B. Ridge preservation/decoronation. *J Endod* 2013 Mar;39(3 Suppl):S67-72.
- › Malmgren B. Decoronation: how, why, and when? *J Calif Dent Assoc* 2000 Nov; 28(11):846-54.
- › Malmgren O, Malmgren B, Goldson L. Orthodontic management of the traumatized dentition. In, Andreasen JO, Andreasen FM, eds, *Textbook and Color Atlas of Traumatic Injuries to the Teeth*. Munksgaard, Copenhagen, 1994, 587-633.
- › Re D, Augusti D, Paglia G, Augusti G, Cotti E. Treatment of traumatic dental injuries: evaluation of knowledge among Italian dentists. *Eur J Paed Dent* 2014; 1 (15): 23-28.
- › Sapir S, Kalter A, Sapir MR. Decoronation of an ankylosed permanent incisor: alveolar ridge preservation and rehabilitation by an implant supported porcelain crown. *Dent Traumatol* 2009 Jun; 25(3): 346-9.
- › Sapir S, Shapira J. Decoronation for the management of an ankylosed young permanent tooth. *Dent Traumatol* 2008 Feb;24(1):131-5.
- › Sigurdsson A. Decoronation as an approach to treat ankylosis in growing children. *Pediatr Dent* 2009 Mar-Apr;31(2):123-8.