

CASE REPORT

Complete resolution of non-necrotizing lung granuloma and pyoderma gangrenosum after restorative proctocolectomy in a woman with severe ulcerative colitis and cytomegalovirus infection

Alessandro Sartini, Marcello Bianchini, Filippo Schepis, Luca Marzi, Nicola De Maria & Erica Villa

Gastroenterology Unit, Policlinico di Modena, Via Del Pozzo 71, 41124 Modena, Italy

Correspondence

Alessandro Sartini, Gastroenterology Unit, Policlinico di Modena, Via Del Pozzo 71 41124, Modena, Italy. Tel: +39 0594224358; Fax: +39 059 422 4419; E-mail: ale.sartini@gmail.com

Funding Information

No sources of funding were declared for this study.

Received: 9 June 2015; Revised: 30 October 2015; Accepted: 3 November 2015

Clinical Case Reports 2016; 4(2): 195–202

doi: 10.1002/ccr3.464

Key Clinical Message

Here, we report the unusual case of an ulcerative colitis female patient presenting together with cytomegalovirus infection, pyoderma gangrenosum and a noncasing lung granuloma, both resistant to immunomodulatory drugs which dramatically obtained a clinical stable remission after restorative proctocolectomy.

Keywords

Crohn's disease, inflammatory bowel disease, lung granuloma, pyoderma gangrenosum, ulcerative colitis.

Report

A 30-year-old woman with severe active left sided Ulcerative Colitis (UC) (Montreal classification E2, Mayo endoscopic subscore 3 at the last colonoscopy), who had already failed multiple courses of steroids and 5ASA, was referred to our third level Gastroenterology Unit because of rapid worsening of rectal bleeding and dyspnea of 4 days duration. Chest X-rays showed a round lesion in inferior right lung lobe (Fig. 1). In the internal side of the left popliteal region the patient had a purple skin lesion (diameter 5 cm), compatible with Pyoderama Gangrenosum (PG) (Fig. 2). Blood tests showed: WBC count 17.160/mm³, Hb 9.9 gr/dL, C Reactive Protein – CRP – 6.37 mg/dL, AST/ALT 54/158 U/L. Stool cultures were negative, such as screening for hepatotropic viruses (HAV, HBV, HCV, EBV) and for autoimmune diseases (ANA, AMA, SMA, LKM). We started antibiotic therapy with ciprofloxacin 200 mg bid and metronidazole 500 mg qd iv (prolonged for 14 days), and topical tacrolimus bid for the treatment of PG. Before starting steroid therapy we performed a High-Resolution CT, confirming a nonhomogeneous 2.5 cm diameter lesion, close to the

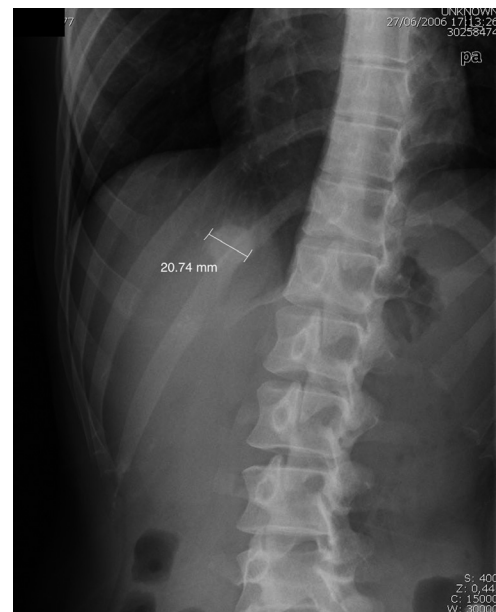


Figure 1. Chest/abdominal X-rays showing a 2 cm diameter ground lesion in inferior right lung lobe.

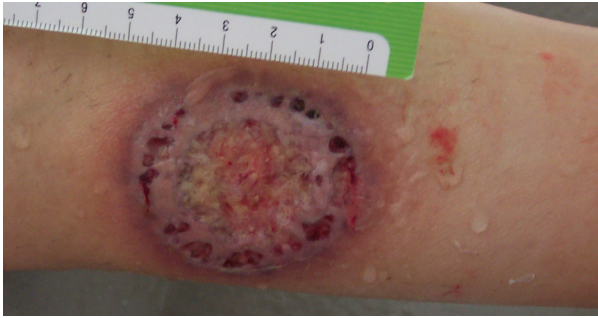

Figure 2. Pyoderma Gangrenosum located in left popliteal region, internal side, diameter 5 cm.

pleura, with irregular borders compatible with a benign lesion (Fig. 3). Blood cultures and fungal antigens screening were negative; serum IgM for CMV and plasma

CMV-DNA were positive. We suspected hence a CMV-related pneumonia, causing at the same time the hepatitis and the UC recrudescence. Ganciclovir was administered for 21 days obtaining negative viremia; we finally started steroid therapy with prednisone 50 mg per os once daily, with nevertheless a poor improvement of intestinal symptoms. A CT chest scan performed 2 months later showed a dimensional growth of the lung lesion (until 3 cm diameter) and patient underwent a bronchoscopy with broncho-alveolar lavage (BAL), which confirmed chronic inflammatory cells infiltrate; acid-fast stain, culture, and PCR for tuberculosis were negative, as well as molecular test for CMV. A CT-guided biopsy was therefore performed and histology showed lymphocytes, granulocyte, and activated mesothelium, whereas immunochemistry for Anti-keratin antibodies (AKA) was negative: these findings were consistent with pulmonary non-necrotizing granuloma (Fig. 4). Even if the patient had not renal or

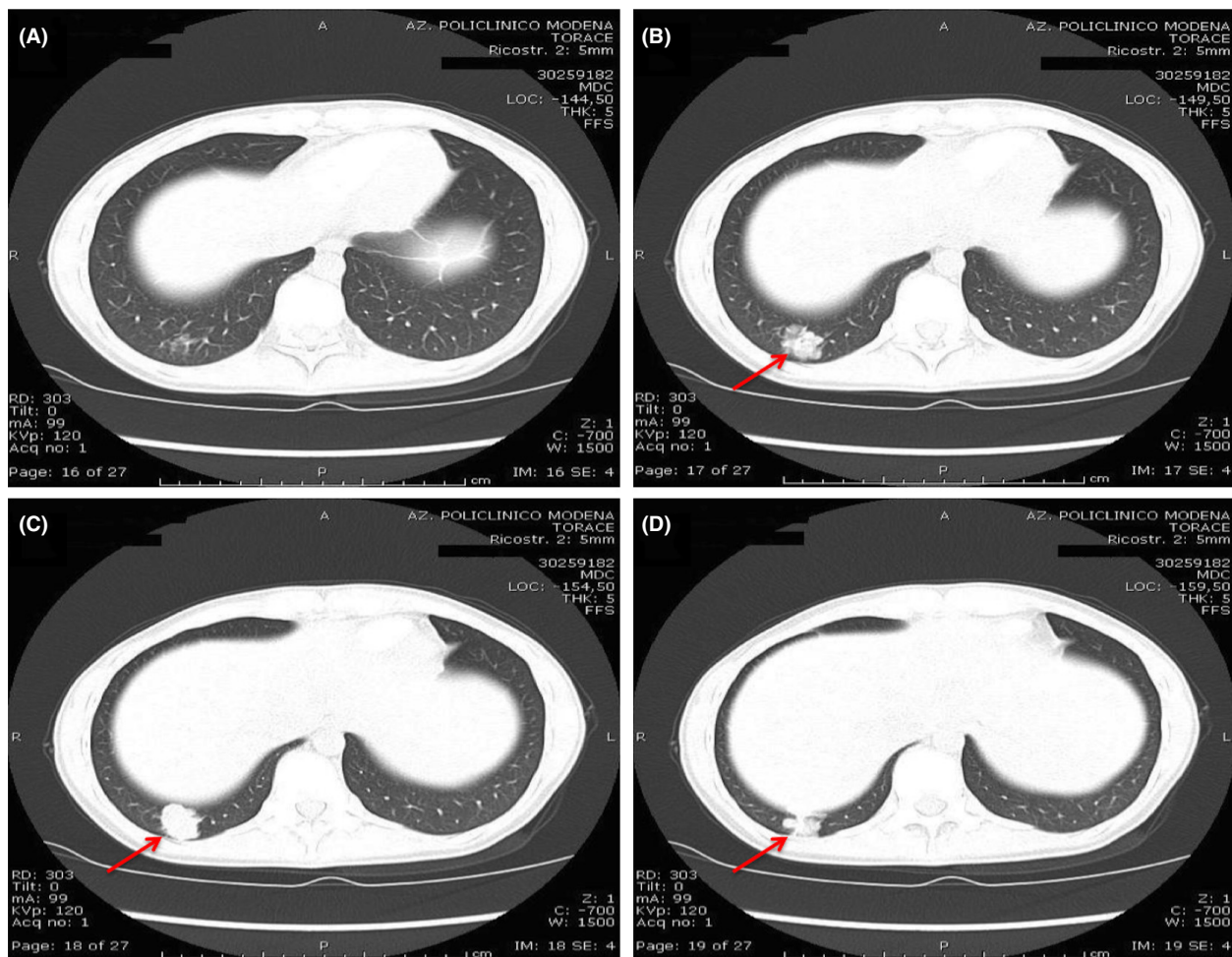


Figure 3. (A–D) High-resolution CT scan showing 2.5 cm diameter lesion with irregular borders in keeping with benign lesion.

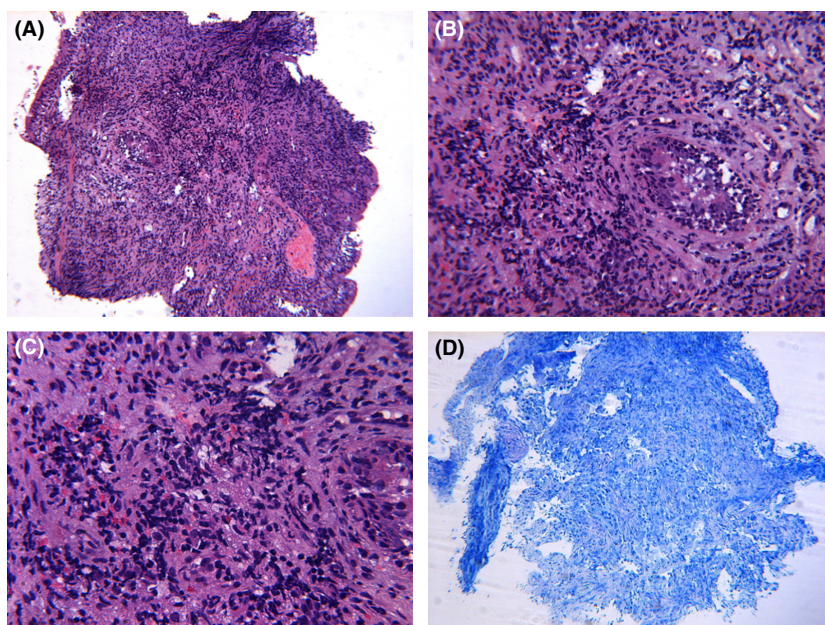


Figure 4. (A) Pulmonary parenchyma completely occupied by a chronic inflammatory reaction in the absence of necrosis; hematoxylin/eosin (HE), (10 \times): (B, C) Epithelioid noncaseating lung granuloma with a monocytic infiltrate consisting primarily of lymphocytes, plasma cells, neutrophils, and some eosinophils; hematoxylin/eosin (HE), (20 \times): (D) Ziehl–Neelsen immunostaining (10 \times) negative for acid and alcohol-fast bacilli.

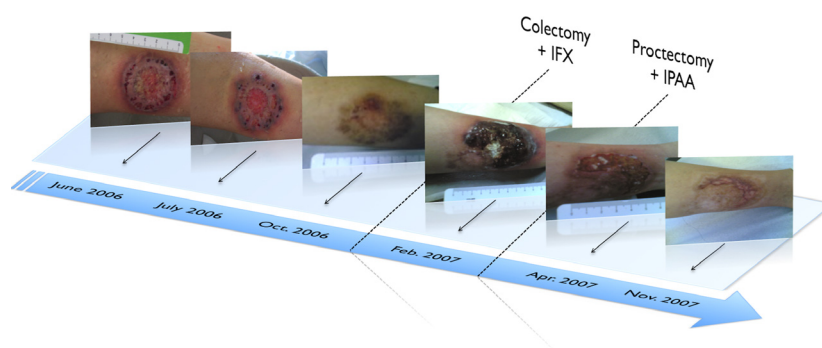


Figure 5. Timeline of lower limb pyoderma evolution.

nasopharyngeal involvement, we performed a cANCA screening (negative), excluding a Wegener's Granulomatosis. Because of a further worsening in clinical condition, we started a "rescue therapy" with cyclosporine 4 mg/kg iv combined with azathioprine (AZA) 2.5 mg/kg/day for maintenance. After a great improvement in the first 72 h, the patient reported rapid onset of nausea and vomiting and a moderate recurrence of UC (3–5 bloody stools emissions, abdominal pain). AZA was therefore discontinued for intolerance. Giving the presence of the refractory UC, the decision to perform a restorative total colectomy with temporary protective ileostomy and delayed proctectomy was taken. A rectoscopy after few

weeks showed the persistence of severe inflammation in the rectal stump. We attempted a treatment with infliximab (IFX), 5 mg/kg at week 0, week 2, and week 6, observing only a partial improvement in intestinal disease; the patient, moreover, manifested a severe allergic reaction, accompanied by a progressive worsening of PG, and IFX was then discontinued. Proctectomy with ileal pouch-anal anastomosis (IPAA) was then performed. Postoperative course was regular, PG achieved the remission in few weeks after the complete removal of the rectum (Fig. 5) and subsequent chest CT scan showed the concomitant resolution of the pulmonary lesion (Fig. 6).

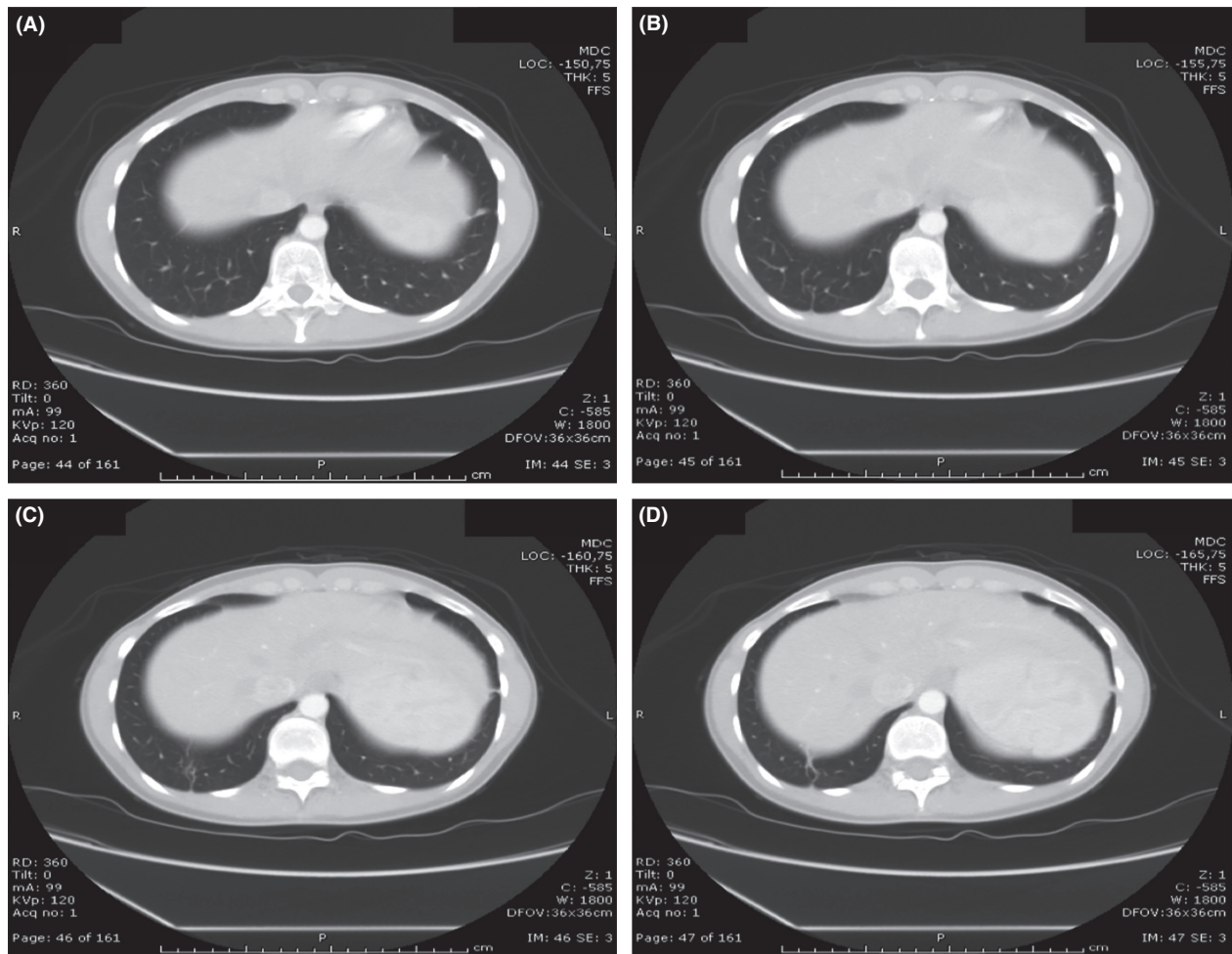


Figure 6. HRCT scan made 12 months later with complete resolution of the pulmonary lesion.

Discussion

Inflammatory bowel diseases (IBD) may be associated with extraintestinal manifestations (EIMs). Approximately, 10% to 35% of UC patient develop one or more EIMs, mostly involving the skin (pyoderma gangrenosum and erythema nodosum) or the hepato-biliary system (Primary sclerosing cholangitis and autoimmune hepatitis) [1–5]. PG, an immune-mediated skin inflammation, commonly occurs in 1–2% of IBD patients, whereas up to 50% of PG patients have active IBD [6,7]. Its pathogenesis is not completely clear, but $\text{TNF}\alpha$ seems to play a role in mediating skin damage, since anti- $\text{TNF}\alpha$ antibodies have been successfully used for its treatment [8]. Even less is known about pulmonary lesions (PLs) in IBD setting, as they are very uncommon [9,10]. We described an unusual clinical presentation of UC and to our knowledge the first case of contemporary noncaseating granulo-

matous lesion and PG resistant to immunosuppressive therapy with complete resolution after restorative proctocolectomy. Most of the IBD-associated lung lesions described in literature are drug-related or granulomatous conditions [11–14]. Necrobiotic parenchymal lung nodules composed by sterile aggregates of neutrophils with or without areas of necrosis are the most frequent report in both UC and CD [15–19]. A possible explanation for this association is the common embryological derivation of respiratory and gastrointestinal epithelia from primitive foregut, the so called gut-lung axis [20]. Nevertheless, IBD-associated pulmonary lesions remain an exclusion diagnosis: it is essential to rule out malignancies, infections (mycobacteria and CMV), associated disorders (sarcoidosis, Wegener's granulomatosis), and parenchymal disease such as bronchiolitis obliterans with organizing pneumonia – known as cryptogenic organizing pneumonia [21]. Our patient was supposed at first to have a

Table 1. Characteristics of contemporary PG and pulmonary lesion in IBD patients (See author references in Table S1).

Reference (Table S1)	Age	Sex	IBD type	Respiratory symptoms	Strumental appearance	Histologic features	Diagnosis	Treatment	Previous/ineffective treatments	Outcome of pulmonary lesions
McCulloch et al. [1]	53	F	Active UC	Pleuritic chest pain, cough, purulent sputum, fever	Consolidation in the apical segment of the right lower lobe	Chronic nonspecific organizing pneumonia, no evidence of vasculitis, no granulomas	UC-associated lung involvement	CCS	Erythromycin, ampicillin, gentamicin, metronidazole, sulfasalazine	Complete resolution and recrudescence
Bhat et al. [37]	37	F	Active CD	Nonproductive cough, wheezing dyspnea	Collapse of the left upper lobe of the lung	Mild to moderate chronic nonspecific inflammation	Tracheobronchitis	IV and oral prednisone	SSP	Complete resolution
Field et al. [48]	52	F	Inactive Ulcerative proctitis ¹	Fever, cough hemoptysis	Homogenous shadowing in the right upper lobe (RUL) of the lung	Multifocal neutrophilic microabscesses with granulomatous inflammation, multinucleated giant cells.	PG-associated pulmonary involvement	Surgery	–	No recrudescence
Basseri B et al. [56]	37	F	UC	None	Emphysematous and bronchiectatic changes, nodular interstitial infiltrate, cavitary lesion	Patchy areas of organizing pneumonia with prominent bronchiolitis obliterans	COP	Prednisone	5ASA, 6MP	Complete resolution
Deregnacourt D et al. [74]	17	M	Active UC	Fever	Bilateral excavated nodules	Biopsy not performed	PG pulmonary locations	IFX	CCS, 5ASA, AZA, MTX, CsA	Complete resolution
This case	30	F	Active UC	Dyspnea, fever	Nodular, noncavitating, nonhomogeneous lesion	Non-necrotizing granuloma	UC-associated lung involvement	IFX	CCS, CsA, AZA	Complete resolution after restorative proctocolectomy

¹IBD diagnosis was made 1 year later PG and pulmonary lesion.

M, male; F, female; PG, pyoderma gangrenosum; CCS, Corticosteroids; IFX, Infliximab; ADA, Adalimumab; CsA, Cyclosporine; AZA, Azathioprine; 6MP, 6-mercaptopurine; SSP, Salazosulfapyridine; 5ASA, Mesalazine.

pneumonia related to CMV infection, which could ultimately explain both the hepatitis and the recrudescence of the intestinal disease. CMV reactivation in immunocompromised patient is suspected to be a risk factor for the development of steroid-refractory UC, with a significant greater colectomy rate in CMV+ patients [22,23]. CMV treatment with ganciclovir was therefore decided, more for the signs of systemic infection than to treat pulmonary lesion (which, moreover, did not improve). The subsequent lung biopsy showed a noninfectious granulomatous inflammation, which could represent, in IBD setting, a consistent lung manifestation of the intestinal disease. Our patient featured, moreover, a contemporary PG, a neutrophilic dermatosis affecting up to 20% of UC patients, and usually characterized by ulcer with purple and undermined borders (sometimes nodular), pustular, bullous, or vegetating lesions of lower extremities [6]. We performed an up-to-date literature review in PubMed using the terms “pyoderma gangrenosum”, “IBD”, “Crohn’s Disease”, “Ulcerative colitis”, “infliximab”, “adalimumab”, “antiTNFalpha”, “pulmonary/lung lesions/involvement”, considering case reports, case series, RCTs, and retrospective papers published in English. Papers without basic demographic information such as sex, age, IBD type, and treatment were excluded. Almost 300 IBD cases with associated PG are so far available (Table S1). In five cases a contemporary PG and pulmonary involvement in IBD patients was reported, but none of them was associated with noncaseating lung granuloma (Table 1). Four of five cases were UC patients, mostly female (4/5) and young adults (mean age 39 years, range 17–53). Most of the patients were symptomatic, although a wide range of presenting respiratory signs was present. All the cases responded to the treatment adopted: three recovered with steroids, one with surgery, and one with IFX alone. Our case have a peculiar clinical course: both gut, skin, and lung lesion were resistant to immunosuppression and completely resolved after restorative proctocolectomy, supporting the idea that the presence of a severe UC and impaired intestinal immune system had led to a consequent dysregulation of the overall immune system. PG, lung granulomas such as of sarcoidosis, and UC are chronic inflammatory diseases, in which regulatory T cells (Treg) impairment plays a central role [24]. In normal gut, intestinal epithelial cells (IECs) act as a functional barrier and nonprofessional antigen-presenting cells (APCs), balancing the immune oral tolerance. In IBD, immune oral tolerance is lost because of a global defect in the mucosal immune system: the balance between the barrier function (with impairment in IECs integrity) and the innate and adaptive response is lost. Such defects affect the epithelial-lymphocyte crosstalk and

alter the imbalance between Treg and effectors (activated CD4+ lymphocytes), leading to a chronic inflammatory state [25,26]. Indeed, Treg-depleted mice develop a broad range of autoimmune diseases, confirming the role of such lymphocyte subset in the control of T-cell-mediated autoimmunity [27]. Eastaff-Leung et al. described a decrease in Treg and an increase in Th17 cells in peripheral blood from IBD patients, with a lower Treg/Th17 ratio, which is similarly perturbed in other chronic inflammatory conditions (Juvenile Arthritis, Primary Biliary Cirrhosis, etc.) [28]. Moreover, it has been recently demonstrated a reduction in Treg/Th17 ratio in PG as well [29]. Our case is an example of how a local altered environment such as of a severe UC may afflict the overall immune system. Actually, it was demonstrated that in UC patients colectomy cause the Treg cells improvement with a peak around 7 days after colectomy [30]; this increase is probably determined by the removal of target antigens which may prevent Treg growth, such as described above. We can therefore speculate that the increase in Treg cells caused a restoration in the systemic T-cell-mediated global autoimmunity control. In conclusion, our case is the first report of contemporary UC, pulmonary noncaseating granuloma, and PG, which nevertheless resolved only after a restorative proctocolectomy. Gut is indeed the interface between the immune system and the epithelial barrier and behaves hence as the “keystone” on which the overall immune system rests. Further studies in IBD patients with multiple EIMs are needed to help us in better understanding such a complex crosstalk.

Acknowledgments

Alessandro Sartini and Marcello Bianchini conceived the manuscript, collected data, revised the literature, and wrote the manuscript; Luca Marzi collected data and revised the literature; Nicola De Maria, Filippo Schepis, and Erica Villa contributed to concept the manuscript. We thank Maria Marino for the clinical support and Livia Maccio for the histology revision.

Conflict of interest

None to declare.

References

1. Danese, S., and C. Fiocchi. 2011. Ulcerative colitis. *N. Engl. J. Med.* 365:1713–1725.
2. Trikudanathan, G., P. G. K. Venkatesh, and U. Navaneethan. 2012. Diagnosis and therapeutic

- management of extra-intestinal manifestations of inflammatory bowel disease. *Drugs* 72:2333–2349.
3. Ozdil, S., F. Akyüz, B. Pinarbasi, K. Demir, C. Karaca, G. Boztas, et al. 2004. Ulcerative colitis: analyses of 116 cases (do extraintestinal manifestations effect the time to catch remission?). *Hepatogastroenterology* 51:768–770.
 4. Huang, B., L. Y. Kwan, and D. Q. Shih. 2011. Extraintestinal manifestations of ulcerative colitis. In: O'Connor M. *Ulcerative Colitis - Epidemiology, Pathogenesis and Complications*. ISBN: 978-953-307-880-9.
 5. Van Assche, G., A. Dignass, B. Bokemeyer, S. Danese, P. Gionchetti, G. Moser, et al. 2013. Second European evidence-based consensus on the diagnosis and management of ulcerative colitis Part 3: special situations. *J. Crohn's Colitis*, 7:1–33.
 6. Callen, J. P., and J. M. Jackson. 2007. Pyoderma gangrenosum: an update. *Rheum. Dis. Clin. North Am.* 33:787–802, vi.
 7. Miller, J., B. A. Yentzer, A. Clark, J. L. Jorizzo, and S. R. Feldman. 2010. Pyoderma gangrenosum: a review and update on new therapies. *J. Am. Acad. Dermatol.* 62:646–654.
 8. Andrisani, G., L. Guidi, A. Papa, A. E. Potenza, D. Cervelli, and A. Armuzzi. 2013. A case of pyoderma gangrenosum with ulcerative colitis treated with combined approach: infliximab and surgery. *J. Crohns. Colitis* 7:421–426.
 9. Camus, P., and T. V. Colby. 2000. The lung in inflammatory bowel disease. *Eur. Respir. J.* 15:5–10.
 10. Ji, X. Q., L. X. Wang, and D. G. Lu. 2014. Pulmonary manifestations of inflammatory bowel disease. *World J. Gastroenterol.* 20:13501–13511.
 11. Casella, G., V. Villanacci, C. Di Bella, E. Antonelli, V. Baldini, and G. Bassotti. 2010. Pulmonary diseases associated with inflammatory bowel diseases. *J. Crohns. Colitis* 4:384–389. Review.
 12. Freeman, H. J. 2000. Granulomatous bronchiolitis with necrobiotic pulmonary nodules in Crohn's Disease. *Eur. Respir. J.* 15:41–48.
 13. Mahadeva, R. 2000. Clinical and radiological characteristics of lung disease in inflammatory Bowel disease. *Eur. Respir. J.* 15:41–48.
 14. Casey, M. B. 2003. Noninfectious lung pathology in patients with Crohn's disease. *Am. J. Surg. Path.* 27:213–219.
 15. Golpe, R. 2003. Multiple pulmonary nodules in a patient with Crohn's disease. *Respiration* 70:306–309.
 16. Songür, N., Y. Songür, M. Tüzün, I. Doğan, D. Tüzün, A. Ensari, et al. 2003. Pulmonary function tests and high-resolution CT in the detection of pulmonary involvement in inflammatory bowel disease. *J. Clin. Gastroenterol.* 37:292–298.
 17. Cordier, J. F. 2006. Cryptogenic organizing pneumonia. *Eur. Respir. J.* 28:422–446.
 18. Warwick, G. 2009. Pulmonary necrobiotic nodules: a rare extraintestinal manifestation of Crohn's disease. *Eur. Respir. Rev.* 18:47–50.
 19. Desai, D. 2011. Pulmonary manifestations in inflammatory bowel disease: a prospective study. *Indian J. Gastroenterol.* 000:225–228.
 20. Carrascosa, M. F., J. R. Salcines-Caviedes, M. V. Millán, M. C. Martín, M. Z. Murguiondo, P. G. Gutiérrez, et al. 2011. Pulmonary nodules as respiratory manifestation of inflammatory bowel disease: case report and review. *Inflamm. Bowel Dis.* 17:E99–E101.
 21. Basseri, B., P. Enayati, A. Marchevsky, and K. A. Papadakis. 2010. Pulmonary manifestations of inflammatory bowel disease: case presentations and review. *J. Crohns. Colitis* 4:390–397.
 22. Pillet, S., B. Pozzetto, C. Jarlot, S. Paul, and X. Roblin. 2012. Management of cytomegalovirus infection in inflammatory bowel diseases. *Dig. Liver Dis.* 44:541–548. doi: 10.1016/j.dld.2012.03.018. Epub 2012 Apr 25. Review.
 23. Cascio, A., C. Iaria, P. Ruggeri, and W. Fries. 2012. Cytomegalovirus pneumonia in patients with inflammatory bowel disease: a systematic review. *Int. J. Infect. Dis.* 16:e474–e479. doi:10.1016/j.ijid.2012.03.008 Epub 2012 May 22.
 24. Rapp, G., S. Pabst, D. Riemann, A. Schmidt, C. Wickenhauser, W. Schütte, et al. 2011. Regulatory T cells with reduced repressor capacities are extensively amplified in pulmonary sarcoid lesions and sustain granuloma formation. *Clin. Immunol.* 140:71–83.
 25. Sakaguchi, S., N. Sakaguchi, and M. Asano. 1995. Immunologic self-tolerance maintained by activated T cells expressing IL-2 receptor alpha-chains (CD25). Breakdown of a single mechanism of self-tolerance causes various autoimmune diseases. *J. Immunol.* 155:1151–1164.
 26. Roda, G., A. Sartini, E. Zambon, A. Calafiore, M. Marocchi, A. Caponi, et al. 2010. Intestinal epithelial cells in inflammatory bowel diseases. *World J. Gastroenterol.* 16:4264–4271.
 27. Sakaguchi, S., N. Sakaguchi, J. Shimizu, S. Yamazaki, T. Sakihama, M. Itoh, et al. 2001. Immunologic tolerance maintained by CD25+ CD4+ regulatory T cells: their common role in controlling autoimmunity, tumor immunity, and transplantation tolerance. *Immunol. Rev.* 182:18–32.
 28. Eastaff-Leung, N., N. Mabarrack, A. Barbour, A. Cummins, and S. Barry. 2010. Foxp3+ regulatory T cells, Th17 effector cells, and cytokine environment in inflammatory bowel disease. *J. Clin. Immunol.* 30:80–89.
 29. Caproni, M., E. Antiga, W. Volpi, A. Verdelli, L. Venegoni, P. Quaglino, et al. 2015. The Treg/Th17 cell

ratio is reduced in the skin lesions of patients with pyoderma gangrenosum. *Br. J. Dermatol.* 173:275–278.

30. Furihata, M., T. Sawada, and T. Okada. 2006. Total colectomy improves altered distribution of regulatory T cells in patients with ulcerative colitis. *World J. Surg.* 30:590–597.

Supporting Information

Additional Supporting Information may be found in the online version of this article:

Table S1. Literature review of IBD-associated PG, with/without PLs.