

# A rare case of pulmonary alveolar microlithiasis

Rachelle Ascik,<sup>1</sup> Richard Pullicino,<sup>2</sup> Adrian Mizzi,<sup>2</sup> Stephen Montefort<sup>1</sup>

<sup>1</sup>Department of Respiratory Medicine, Mater Dei Hospital, Msida, Malta

<sup>2</sup>Department of Radiology, Mater Dei Hospital, Msida, Malta

## Correspondence to

Dr Rachelle Ascik,  
[rachasciak@gmail.com](mailto:rachasciak@gmail.com)

Accepted 16 November 2015

## DESCRIPTION

A 47-year-old asymptomatic man with no significant family history was referred to our faculty because of an abnormal chest X-ray (CXR).

The CXR, similar to his CXR 10 years previously, showed bilaterally increased interstitial markings suggestive of pulmonary fibrosis.

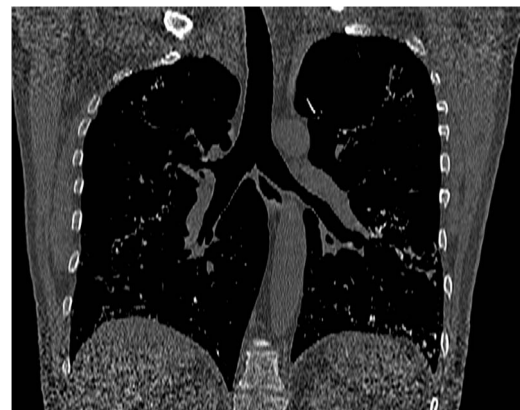High-resolution CT (HRCT) showed multiple bilateral branching calcifications, mostly in the lung bases (figures 1 and 2), with ground-glass opacities in the lingula, and no enlarged mediastinal lymph nodes. Spirometry was normal (forced expiratory volume in 1 s 102%, forced vital capacity 118%), as were total lung capacity, 117%, and diffusion capacity of the lung for carbon monoxide, 87%. Blood tests including serum calcium and phosphate concentrations were normal.

A repeat HRCT after 4 months remained similar. After discussion at a multidisciplinary team meeting, a diagnosis of pulmonary alveolar microlithiasis (PAM) was reached.

The patient remains asymptomatic on follow-up 1 year after diagnosis.

PAM is a rare condition, with an autosomal recessive pattern, and is more common in families with a high rate of consanguineous marriages (none known in this case). The responsible gene is SLC34A2, which encodes a sodium-dependent phosphate transporter. SLC34A2 mutations lead to widespread intra-alveolar deposition of phosphates, and this likely leads to the spherical sand-like calcipherites in PAM.<sup>1</sup>

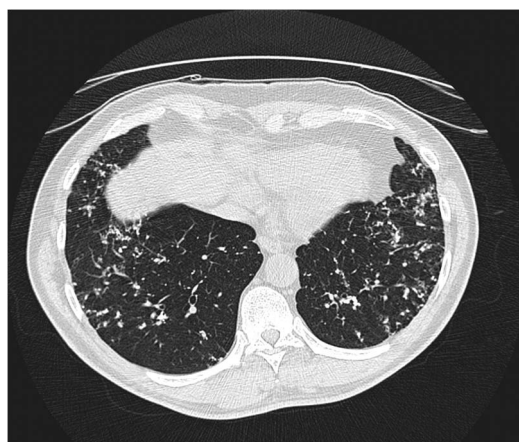
Calcium and phosphate metabolism is usually normal, and extrapulmonary calcifications are rare, although there are reported cases of associated cardiac valve calcification, cholelithiasis and nephrocalcinosis.<sup>2</sup>



**Figure 2** Coronal reconstruction of high-resolution CT thorax image as viewed in the bone window setting, highlighting the intra-alveolar calcifications and their distribution, mainly in the lung bases.

Most known PAM cases are European,<sup>3</sup> and usually an incidental finding, as in this case, because of a striking lack of symptoms despite extensive characteristic radiographic changes, which are almost pathognomonic. Some differential diagnoses of pulmonary calcifications include healed varicella pneumonia, hyperparathyroidism, pulmonary amyloidosis, hypervitaminosis D, Paget disease and occupational lung disease such as silicosis.

Lung function tests may be normal or may show a restrictive defect. Identification of microliths on bronchoalveolar lavage supports the diagnosis of PAM, thereby avoiding lung biopsy. Histology of the lung tissue shows calcified spherules filling the alveolar space. Genetic testing for SLC34A2 mutations help confirm the diagnosis. PAM usually progresses slowly with eventual respiratory insufficiency and cor pulmonale.<sup>3</sup> There is no known effective treatment.



**Figure 1** Axial high-resolution CT thorax image as viewed in the lung window setting, showing widespread bilateral intra-alveolar deposition of sand-like calcifications throughout the lungs but predominantly in the lung bases.

## Learning points

- ▶ Pulmonary alveolar microlithiasis is a rare disease but with potentially serious consequences of respiratory failure and cor pulmonale.
- ▶ CT scan images are almost pathognomonic.
- ▶ Identification of microliths on bronchoalveolar lavage supports the diagnosis of pulmonary alveolar microlithiasis, thereby avoiding lung biopsy.

**Competing interests** None declared.

**Patient consent** Obtained.

**Provenance and peer review** Not commissioned; externally peer reviewed.



**To cite:** Ascik R, Pullicino R, Mizzi A, *et al.* *BMJ Case Rep* Published online: [please include Day Month Year] doi:10.1136/bcr-2015-212804

REFERENCES

- 1 Tachibana T, Hagiwara K, Johkoh T. Pulmonary alveolar microlithiasis: review and management. *Curr Opin Pulm Med* 2009;15:486–90.
- 2 Giallauria F, Giallauria G. Pulmonary alveolar microlithiasis. *Thorax* 2011;66:840.
- 3 Mariotta S, Ricci A, Papale M, et al. Pulmonary alveolar microlithiasis: report on 576 cases published in the literature. *Sarcoidosis Vasc Diffuse Lung Dis* 2004;21:173–81.

Copyright 2015 BMJ Publishing Group. All rights reserved. For permission to reuse any of this content visit <http://group.bmj.com/group/rights-licensing/permissions>.

BMJ Case Report Fellows may re-use this article for personal use and teaching without any further permission.

Become a Fellow of BMJ Case Reports today and you can:

- ▶ Submit as many cases as you like
- ▶ Enjoy fast sympathetic peer review and rapid publication of accepted articles
- ▶ Access all the published articles
- ▶ Re-use any of the published material for personal use and teaching without further permission

For information on Institutional Fellowships contact [consortiasales@bmjgroup.com](mailto:consortiasales@bmjgroup.com)

Visit [casereports.bmj.com](http://casereports.bmj.com) for more articles like this and to become a Fellow