

Polymorphous low-grade adenocarcinoma of the parotid gland. Case report and review of the literature

L Ruiz-Godoy¹, L Suárez¹, A Mosqueda², A Meneses¹

(1) Instituto Nacional de Cancerología, México.

(2) Universidad Autónoma Metropolitana, México.

Correspondence:

Dr. Abelardo Meneses García

Dirección Médica

Instituto Nacional de Cancerología

Av. San Fernando No.22, Tlalpan, México D.F.

C.P. 14080.

E-mail: aameness@hotmail.com

Received: 5-05-2006

Accepted: 11-11-2006

Indexed in:

-Index Medicus / MEDLINE / PubMed
-EMBASE, Excerpta Medica
-SCOPUS
-Índice Médico Español
-IBECs

Ruiz-Godoy L, L Suárez L, Mosqueda A, Meneses A. Polymorphous low-grade adenocarcinoma of the parotid gland. Case report and review of the literature. Med Oral Patol Oral Cir Bucal 2007;12:E30-3.
© Medicina Oral S. L. C.I.F. B 96689336 - ISSN 1698-6946

ABSTRACT

Polymorphous low-grade adenocarcinoma (PLGA) is difficult to diagnose both clinically and histologically due to its indolent presentation, and because of its morphological diversity that includes several microscopic patterns. The aggressive biologic behavior seen in minor salivary glands as compared to major glands is apparently associated histologically to a predominance of the papillary pattern in the former. Biologic behavior of PLGA in the major salivary glands is uncertain, as some cases have developed recurrences and metastases independently of the presence of a papillary pattern. A case of PLGA originated de novo in parotid gland is presented a 60 year-old male, treatment was surgically excised through superficial parotidectomy and to postoperative radiotherapy (46 Gy). Forty-eight months later the patient is alive with no signs of recurrence, as well as a review of the literature, with particular emphasis in its differential diagnosis and biological behavior.

Key words: Polymorphous low-grade, salivary glands, parotid, adenocarcinoma.

INTRODUCTION

Polymorphous low-grade adenocarcinoma (PLGA) was first described simultaneously in 1983 by two groups of researchers under different names. Batsakis et al denominated it as terminal duct carcinoma and Freedman et al named it as lobular carcinoma. At present, this neoplasm is well recognized and known as PLGA (1-3).

PLGA is the second most frequently diagnosed malignant neoplasm of the minor salivary glands, with approximately 60% of the cases located in the palate. Age at diagnosis ranges from 16 to 94 years, with a mean of 59 years and a 2:1 female predilection (4). Evolution varies from some months to several years and the lesion is usually asymptomatic (5). Surgery is the treatment of choice and survival is in most cases long, as recurrences have been reported between 9% and 17% and regional metastases have been found between 9% and 15% of the cases (4). Most deaths associated to this neoplasm are related to invasion to vital structures (6). Although PLGA occurs predominantly in the minor salivary

glands, there are reports in the world literature which shows that at least 32 cases have occurred in the parotid gland, either arising de novo or as neoplasms developing in a pre-existent pleomorphic adenoma (carcinoma ex pleomorphic adenoma) (3,5,6-13). In this article we report a case of PLGA that developed de novo in the parotid gland and was surgically treated with facial nerve preservation.

CASE REPORT

A 60 year-old male had an asymptomatic right pre-auricular painless mass, which had gradually increased in size over a period of seven years. Axial CT showed a 5 x 5 cm multicystic tumoral mass that did not involve the parapharyngeal space (Figure 1). Aspiration biopsy rendered a diagnosis of pleomorphic adenoma (PA) and the lesion was surgically excised through superficial parotidectomy with facial nerve preservation.

Macroscopically the lesion was well circumscribed, partly encapsulated and measured 5 x 4 x 4 cm and comprised

around 90% of the specimen. The cut surface had yellow-brown solid areas intermingled with cystic spaces.

Microscopically the lesion was composed by round to oval isomorphic cells with bland, minimally hyperchromatic oval nuclei, occasional nucleoli and scant mitotic figures. These cells formed diverse patterns, including lobular, papillary and follicular, with predominance of the first two types. The neoplasm infiltrated the adjacent adipose and subcutaneous tissues. The cystic spaces were lined by squamous epithelium with focal production of keratin. In other areas there were scant and isolated cells were scattered in hyalinized material that resembled basal lamina. Neither perineural invasion nor vascular permeation were seen in the studied sections (Figures 2,3).

Immunohistochemical analysis revealed an intensely positive reaction to cytokeratin. Actin and S-100 protein were focally positive, while glial fibrillary acidic protein was negative in all neoplastic cells.

Histopathologic diagnosis was PLGA and the patient was submitted to postoperative radiotherapy (46 Gy). Forty-eight months later the patient is alive with no signs of recurrence.

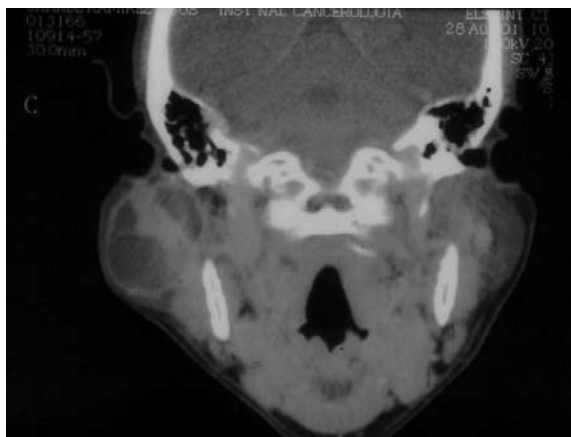


Fig. 1. CT Scan. This image shows a multicystic tumoral mass that do not involve the parapharyngeal space.

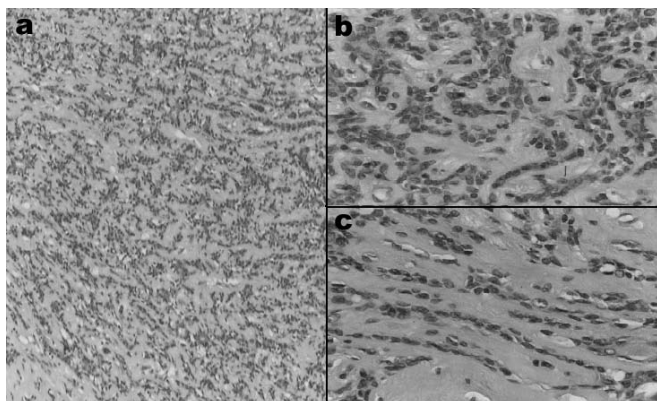


Fig. 2. a) PLGA solid pattern areas with tubular focus H&E lower power, b) solid pattern areas with tubular focus, H&E high power, c) showing individual cell infiltration Indian file, high power H&E.

DISCUSSION

PLGA develops from the intercalated (terminal) duct cells, and it is characterized by its cytologic uniformity with histomorphologic diversity, infiltrative growth and low metastatic potential (3-18).

This tumor shows a marked predominance for minor salivary glands, although some cases have been identified in the parotid gland, where most cases have been diagnosed as part of a carcinoma ex pleomorphic adenoma, such as those in the series reported by Kemp et al, who found that only two out of twenty cases arose de novo, and the rest showed remnants of pleomorphic adenoma (3-12).

It is interesting to note that possible differences with respect to the biologic behavior among those cases that arise de novo and those that develop from a pleomorphic adenoma have not been mentioned in the literature. This may be due to the relatively few cases of this neoplasm and the lack of a long follow-up of the affected patients.

Treatment in all cases, independently of its location consists of complete surgical excision, and neck dissection should be added only in those cases with cervical lymphadenopathy. Two points to take into consideration to decide giving post-operative radio or chemotherapy are the presence of perineural invasion and vascular permeation of tumoral cells (6).

Only 9% to 17% of all PLGA that develop from the minor salivary glands show local recurrence and regional metastases have revealed regional metastases. Distant metastases have seldom been reported (4). Recurrence has been estimated in 33% for parotid tumors, while lymph node metastases have been found in 6.6%, with no cases reported to date with distant metastases (5,16).

At present, several studies suggest that minor salivary gland PLGAs with a predominant papillary and papillary-cystic configuration are more aggressive, as these show a higher incidence of cervical lymph node metastases (7).

However, although the papillary pattern have been found in most of the reported cases of PLGA located in the parotid (Table 1), there has been only one case with lymph node metastasis (13). As PLGAs of major salivary glands are very infrequently diagnosed, it is difficult to determine the particular biologic behavior of this neoplasm in the parotid gland.

On the other hand, Mark et al mentioned that some differences do exist in PLGA located in the minor salivary glands with respect to those cases located in the parotid gland (7-8). These chromosomic differences do not imply differences in biologic behavior due to its anatomical location, but they support the possible origin of PLGA of the parotid gland in a PA (7-8).

This entity is difficult to diagnose because of the multiple histomorphologic patterns it may present and its cytologic uniformity. These features are similar to those seen in PA and in adenoid cystic carcinoma. Immunohistochemical studies that compares PA and PLGA have shown that glial fibrillary acidic protein (GFAP) is negative in PLGA and positive in PA (5,16).

Table 1. Reported cases of PLGA of the parotid gland.

Case	Age/sex	Size	Metastases	Recurrences	Follow-up	Papillary-cystic pattern	References
1	54 /F	2.7 cm.	No	1	48 months	Yes	Merchant, <i>et al</i> ⁹
2	65/M	6 cm.	No	No	-	No	Katoh, <i>et al</i> ³
3	69/M	2 cm.	No	No	-	No	Mark, <i>et al</i> ⁶
4	70/F	2.5 cm.	No	No	9 months	Yes	Mark, <i>et al</i> ⁷
5	85/ F	6 cm.	No	1	72 months	No	Ritland, <i>et al</i> ⁸
6-27*	37-83 (58.8)/ 1:7M/F	0.8-10 cm	1/15 (6.6%)	5/15 (33.3%)	1.5-12 m. (5.2 years)	Yes	Kemp, <i>et al</i> ¹¹
28	69/F	4cm	No	No	24 months	Yes	Puxeddu, <i>et al</i> ⁴
29	-	-	-	-	-	-	Miliauskas ¹⁰
30-31	79/M 65/M	- -	No No	No Yes	14 months 4 months	No Yes	Nagao, <i>et al</i> ¹²
32	60 / M	5 cm.	No	No	36 months	Yes	Ruiz-Godoy, <i>et al.</i>

* Series of 22 cases; 15 of which had follow-up.

In the present case GFAP was negative in all histomorphologic patterns, which supports the diagnosis of PLGA. The morphologic pattern, immunohistochemical findings and clinical evolution suggest that this is a PLGA that arose de novo in the parotid gland.

It is necessary to consider that PLGA may occur in the major salivary glands de novo or as a part of a PA that does not shows clinical evidence of malignancy, as the clinical course of the PLGA is usually indolent and may mimic a benign neoplasm, therefore making necessary to examine carefully the entire surgical specimen. In case a PLGA is recognized, it is important to inform the predominant histologic pattern, the occurrence of perineural invasion and vascular permeation, in order to determine if these criteria may be of assistance to identify its biological behavior.

REFERENCES

- Batsakis JG, Pinkston GR, Luna MA, Byers RM, Sciuba JJ, Tillery GW. Adenocarcinomas of the oral cavity: a clinico-pathologic study of terminal duct carcinomas. *J Laryngol Otol* 1983;97:825-35.
- Freedman PD, Lumerman H. Lobular carcinoma of intraoral minor salivary gland origin. Report of twelve cases. *Oral Surg Oral Med Oral Pathol* 1983;56:57-66.
- Katoh T, Yoshihara T, Naitoh J, Kaneko T, Nagao K, Matsuzaki O, et al. A case of polymorphous adenocarcinoma in the right parotid gland. *Gan No Rinsho* 1985;31:861-4.
- Luna MA, Wenig BM. Polymorphous low-grade adenocarcinoma. In: Barnes L, Eveson JW, Reichart P, Sidransky D, Eds. *Pathology*

and Genetics Head and Neck Tumours. World Health Organization Classification of Tumours. Lyon: IARC Press; 2005. p. 223-4.

- Puxeddu R, Puxeddu P, Parodo G, Faa G. Polymorphous low-grade adenocarcinoma of the parotid gland. *Eur J Morphol* 1998;36:262-6.
- Simpson RHW, Reis-Filho JS, Pereira EM, Ribeiro AC, Abdulkadir A. Polymorphous low-grade adenocarcinoma of the salivary glands with transformation to high-grade carcinoma. *Histopathology* 2002;41:250-9.
- Mark J, Wedell B, Dahlenfors R, Stenman G. Karyotypic variability and evolutionary characteristics of a polymorphous low grade adenocarcinoma in the parotid gland. *Cancer Genet Cytogenet* 1991;55:19-29.
- Mark J, Dahlenfors R, Stenman G, Bende M, Melen I. Cytogenetical observations in two cases of polymorphous low-grade adenocarcinoma of the salivary glands. *Anticancer Res* 1992;12:1195-8.
- Ritland F, Lubensky I, LiVolsy VA. Polymorphous low-grade adenocarcinoma of the parotid salivary gland. *Arch Pathol Lab Med* 1993; 117:1261-3.
- Merchant WJ, Cook MG, Eveson JW. Polymorphous low-grade adenocarcinoma of the parotid gland. *Br J Oral Maxillofac Surg* 1996;34: 328-30.
- Miliauskas JR. Polymorphous low-grade (terminal duct) adenocarcinoma of the parotid gland. *Histopathology* 1991;19:555-7.
- Kemp BL, Batsakis JG, El-Naggar AK, et al. Terminal duct adenocarcinomas of the parotid gland. *J Laryngol Otol* 1995;109:466-8.
- Nagao T, Gaffey TA, Minato H, Serizawa H, Lewis JE. Polymorphous low-grade adenocarcinoma of the major salivary glands: report of three cases in an unusual location. *Histopathology* 2004;44:164-71.
- Pelkey JT, Mills ES. Histologic transformation of polymorphous low-grade adenocarcinoma of salivary gland. *Am J Clin Pathol* 1999;111:785-91.
- Tortoledo ME, Luna MA, Batsakis JG. Carcinoma ex pleomorphic adenoma and malignant mixed tumors. *Arch Otol* 1984;100:172-6.
- Gnepp RD, El-Mofty S. Polymorphous low-grade adenocarcinoma.

Glial fibrillary acidic protein staining in the differential diagnosis with cellular mixed tumors. *Oral Surg Oral Med Oral Pathol Oral Radiol Endod* 1997;83:691-5.

17. Evans HL, Luna MA. Polymorphous low-grade adenocarcinomas. A study of 40 cases with long-term follow up and an evaluation of important of papillary areas. *Am J Surg Pathol* 2000;24:1319-28

18. Perez OB, Linkov I, Huvos AG. Polymorphous low-grade adenocarcinomas of minor salivary glands :study of 17 cases with emphasis on cell differentiation. *Histopathology* 1998;32:521-9.

Acknowledgements:

We wish to acknowledge Dr. Hiro Kumagai for his help in the translation of the article published in Japanese, entitled "A case of polymorphous adenocarcinoma in the right parotid gland "(3).