

Polymorphous low grade adenocarcinoma: Review and case report

María Fernanda Pintor ¹, Liberto Figueroa ², Benjamín Martínez ³

(1) Becado en formación académica Servicio de Cirugía Máxilo-Facial, Clínica Alemana de Santiago

(2) Residente Servicio de Cirugía Máxilo-Facial Clínica Alemana de Santiago

(3) Patología Oral, Facultad de Odontología, Universidad Mayor. Chile

Correspondence:

Dra. María Fernanda Pintor
Servicio de Cirugía Máxilo Facial
Clínica Alemana
Av Vitacura 5951
Vitacura, Santiago - Chile
E-mail: fernandapintor@gmail.com

Received: 15-03-2007

Accepted: 23-10-2007

Pintor MF, Figueroa L, Martínez B. Polymorphous low grade adenocarcinoma: Review and case report. Med Oral Patol Oral Cir Bucal. 2007 Dec 1;12(8):E549-51.

© Medicina Oral S. L. C.I.F. B 96689336 - ISSN 1698-6946

Indexed in:

-Index Medicus / MEDLINE / PubMed
-EMBASE, Excerpta Medica
-SCOPUS
-Índice Médico Español
-IBECs

ABSTRACT

Polymorphous Low-Grade Adenocarcinoma is a rare, malignant salivary gland tumor, which is found almost exclusively in minor salivary glands. It is more frequent in the age range from 30 to 70, with a clear female predilection in a 2:1 ratio. It is usually located in the hard or soft palate, although it may be found in the rest of the oral cavity too. It is rare in major salivary glands. In general it has good prognosis, with recurrence rates in the range of 17% - 24%. Although rare, metastasis to regional lymph nodes may occur in 9% of the cases.

This report describes the case of a patient that consulted at the Military Odontological Center (Central Odontológica del Ejército) due to an esthetic alteration of her dental prosthesis, which had been made 8 years before. The patient was sent to the Maxillofacial Surgery Service, where the intraoral examination showed a big mass compromising the hard palate and the alveolar ridge. During examination, a dent in her prosthesis was found to correspond to the tumor mass; it was therefore concluded that the tumor had at least an eight-year-old evolution. An incisional biopsy was carried out, and once the polymorphous low-grade adenocarcinoma diagnosis had been stated, the patient was sent to the Head and Neck Surgery Service of the Military Hospital, where the lesion was treated by wide surgical excision followed by radiation therapy.

Key words: Polymorphous low grade adenocarcinoma, salivary gland tumors.

INTRODUCTION

Minor salivary gland malignant neoplasms account for 2 - 4% of head and neck malignant neoplasms, 10% of all oral cavity malignant neoplasms and 15 - 23% of all salivary gland malignant neoplasms (1). Among the latter, the polymorphous low-grade adenocarcinoma (PLGA) is found, which was first described in 1983 simultaneously by Batsakis et al and Freedman and Lumerman who named it as Terminal Duct Carcinoma and Lobular Carcinoma (2). Before being described as an entirely different entity, this tumor was diagnosed as Pleomorphic Adenoma or Unspecific Carcinoma or even sometimes as Adenoid Cystic Carcinoma (3). It is a malignant neoplasm of salivary glands, more

frequently detected in minor salivary glands (4). It is a rare pathology that affects people in the age range from 30 to 70, with a female predilection in a 2:1 ratio (5). Polymorphous low grade adenocarcinoma is found almost exclusively in minor salivary glands (3), and is rare in extraoral locations, including major salivary glands. Sixty percent of the cases occur on the hard or soft palate, followed by 13% of the cases occurring in the buccal mucosa, 10% in the upper lip, 6% in the retromolar area, and 9% in the rest of the oral cavity (5). The lesion is normally described as a painless, slow-growing mass, covered by non-ulcerated mucosa. In some cases it may be adhered to deep planes and it can reach sizes between 1 and 4 cm (3, 5). Diagnosis is late and can take

weeks or even years because of its slow growth. This lesion can erode or infiltrate bone tissue (3). Histology shows a non-encapsulated lesion with infiltrative margins. It is named as polymorphous due to its different growth patterns: tubular, solid, papillary, microcystic, cribriform, fascicular, and cords. It can infiltrate bone tissue and even present perivascular and perineural invasion. The best treatment is surgical excision including the subjacent bone, if necessary (3,5). This surgery is frequently followed by radiotherapy. The prognosis is good and recurrence rate ranges between 17% and 24%. Metastasis is unusual (9%) but in case it occurs, it mainly affects regional lymph nodes (6).

CASE REPORT

A 65 year-old female patient consults due to an esthetic alteration of her removable prosthesis. The problem was that it was progressively exposing the teeth of one side (Figure 1). The patient was immediately sent to the maxillofacial surgery service where the intraoral examination showed a big mass located in the hard palate and part of the right alveolar ridge, which caused an evident maladjustment of the prosthesis. The patient said she had noticed this mass one year ago and that, during this period, it had showed a very slow growth. Clinically, the lesion was a big soft mass of 5 cm diameter, with gummy consistency, painless, not adhered to deep planes and covered with normal mucosa (Figure 2). During the exam, a dent corresponding to the lesion was observed in the patient's prosthesis. The prosthesis had been made 8 years ago, which determined that the lesion was there before the prosthesis was made (Figure 3), and that it had had a very slow growth, thus producing an actual maladjustment in the last year. An orthopantomography revealed a more radiopaque lesion located in the palatal region, but did not indicate if it was infiltrating bone tissue or not. Watters radiography revealed no compromise of ipsilateral maxillary sinus. Incisional biopsy was planned and sent to histopathological analysis which confirmed polymorphous low grade adenocarcinoma diagnosis (Figure 4). Because of its malignant condition, the patient was sent to the Head a Neck Surgery Service of the Military Hospital where surgical excision with security margins was performed. The lesion reached the excision margins and it presented positive bone and perineural infiltration so the patient was subsequently submitted to radiotherapy.

DISCUSSION

Polymorphous low grade adenocarcinoma is a rare lesion. In a research study carried out by González Lagunas (1), a sample of 59 malignant salivary gland tumors was assessed, and no PLGA was found. This lesion is located almost exclusively in minor salivary glands within the oral cavity, mostly hard palate, being its extraoral presentation extremely rare. Nasal fossa and nasopharynx locations have been described in less than 0.5 – 1% of the cases (7). There is a clear female predilection, particularly affecting women in their forties and fifties. This characteristic is also found in other salivary gland neoplasms (5,8) that

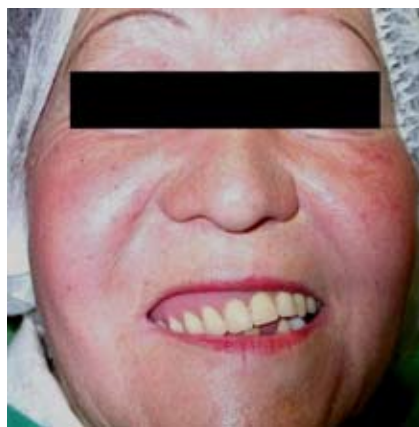

Fig. 1. Clinical image that shows the right side descent of the prosthesis.

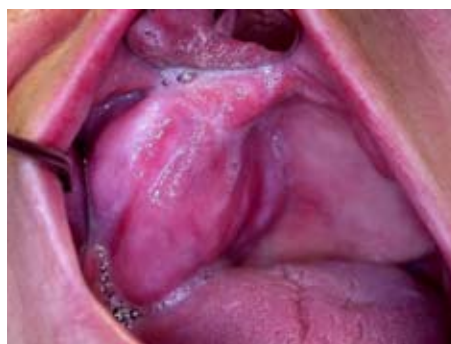


Fig. 2. Clinical image that shows the palatal and alveolar bone mass.

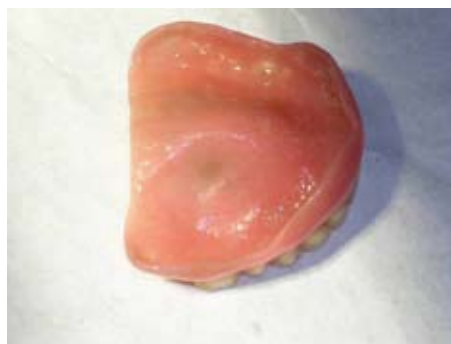

Fig. 3. Clinical image that shows the prosthesis's lesion impression.

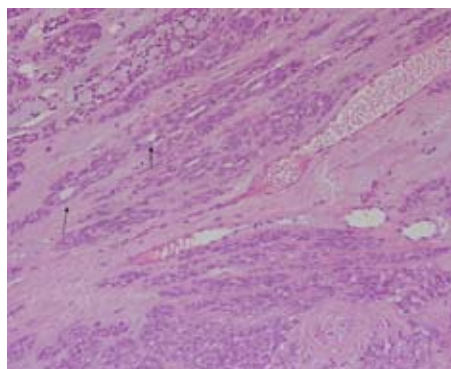


Fig. 4. Histological image that shows ductal or tubular like structures with a central lumina formed by one layer of cubic cells.

may appear as multiple benign or malign salivary gland tumors, and this is the reason why it was wrongly diagnosed during a long time. Differential diagnosis is important in the case of benign tumors such as pleomorphic adenoma. This tumor often shows a very similar clinic behaviour, which sometimes generates a dilemma in the histological analysis. This especially occurs within lesions with a large number of cells and few matrix, with no fibrous capsule, which is common in minor salivary gland tumors but not in major salivary gland tumors (2). This is the reason why immunohistochemistry is an important tool when dealing with salivary gland neoplasms (9). Pleomorphic adenoma shows immunoreactivity for GFAP (glial fibrillary acid protein) which is normally present in nervous system cells, specifically in glial cells. However, the presence of this antibody has also been described in other tumors of non-glial origin. PLGA has minimum or none reactivity to GFAP which is a difference with pleomorphic adenoma (2). Other immunohistochemical studies have shown that polymorphous low grade adenocarcinoma expresses big amounts of vimentin, which is absent in canalicular adenoma. These two tumors share similar hystological characteristics, being vimentin a useful marker for the differential diagnosis of both lesions (9).

Among the malignant lesions we may mention the adenoid cystic carcinoma, that despite of being a malignant neoplasm as PLGA, shows a different clinical behaviour. Adenoid cystic carcinoma is much more aggressive, has a faster growth and a high metastasis rate (10).

This case evidences the low grade of malignancy and slow growth of PLGA which is demonstrated with the fact that the tumor was there before the prosthesis was made 8 years ago. During all this time, no symptoms were noticed by the patient except for the presence of a mass in her palate. It is important to underline that physical examination before any dental treatment must be accurate, and all perceptible swellings must be evaluated by means of appropriate radiographs or other complementary exams.

Polymorphous low grade adenocarcinoma described in this report corresponds to the experience described in other countries, with high incidence in palate and slow growth. Hystological findings are also similar to those described above: lobular growth, cord-like infiltration, and pale, ovoid nuclei.

CONCLUSION

Polymorphous low grade adenocarcinoma is a rare malignant neoplasm, with a clinical behavior similar to that of a benign neoplasm, with low symptomatology, which may determine a late diagnosis like it was in the case presented in this report.

REFERENCES

1. González Lagunas J, Rodado C, Raspall G, Bermejo B, Huguet P, Giralt J. Malignant tumors of the minor salivary glands. Retrospective study on 59 cases. *Med Oral*. 2001 Mar-Apr;6(2):142-7.
2. Curran AE, White DK, Damm DD, Murrah VA. Polymorphous low-grade adenocarcinoma versus pleomorphic adenoma of minor salivary

glands: resolution of a diagnostic dilemma by immunohistochemical analysis with glial fibrillary acidic protein. *Oral Surg Oral Med Oral Pathol Oral Radiol Endod*. 2001 Feb;91(2):194-9.

3. Neville BW, Damm DD, Allen CM, Bouquot JE. *Oral and Maxillofacial Pathology*. 2nd edition. Philadelphia: W.B. Saunders; 2002.

4. Vincent SD, Hammond HL, Finkelstein MW. Clinical and therapeutic features of polymorphous low-grade adenocarcinoma. *Oral Surg Oral Med Oral Pathol*. 1994 Jan;77(1):41-7.

5. Clayton JR, Pogrel MA, Regezi JA. Simultaneous multifocal polymorphous low-grade adenocarcinoma. Report of two cases. *Oral Surg Oral Med Oral Pathol Oral Radiol Endod*. 1995 Jul;80(1):71-7.

6. Kelsch RD, Bhuiya T, Fuchs A, Gentile P, Kahn MA, Fantasia JE. Polymorphous low-grade adenocarcinoma: flow cytometric, p53, and PCNA analysis. *Oral Surg Oral Med Oral Pathol Oral Radiol Endod*. 1997 Oct;84(4):391-9.

7. González-Lagunas J, Alasa-Caparros C, Vendrell-Escofet G, Huguet-Redecilla P, Raspall-Martin G. Polymorphous low-grade adenocarcinoma of the nasal fossa. *Med Oral Patol Oral Cir Bucal*. 2005 Aug-Oct;10(4):367-70.

8. Ledesma-Montes C, Garces-Ortiz M. Salivary gland tumours in a Mexican sample. A retrospective study. *Med Oral*. 2002 Nov-Dec;7(5):324-30.

9. Furuse C, Tucci R, Machado de Sousa SO, Rodarte Carvalho Y, Cavalcanti de Araújo V. Comparative immunoprofile of polymorphous low-grade adenocarcinoma and canalicular adenoma. *Ann Diagn Pathol*. 2003 Oct;7(5):278-80.

10. Edwards PC, Bhuiya T, Kelsch RD. Assessment of p63 expression in the salivary gland neoplasms adenoid cystic carcinoma, polymorphous low-grade adenocarcinoma, and basal cell and canalicular adenomas. *Oral Surg Oral Med Oral Pathol Oral Radiol Endod*. 2004 May;97(5):613-9.