

Department of Veterinary Biosciences  
Faculty of Veterinary Medicine  
University of Helsinki, Finland

**FUR ANIMAL EPIDEMIC NECROTIC PYODERMA  
PATHOLOGY, ETIOLOGY, AND EPIDEMIOLOGY**

**Heli Nordgren**

ACADEMIC DISSERTATION

To be presented, with the permission of the Faculty of Veterinary Medicine of the  
University of Helsinki, for public examination in the Walter Auditorium,

Agnes Sjöberginkatu 2, Helsinki on 29.11.2017, at 12 noon.

Helsinki 2017

**Supervisors**

Professor Antti Sukura, DVM, PhD  
Department of Veterinary Biosciences  
Faculty of Veterinary Medicine  
University of Helsinki  
Helsinki, Finland

Professor Olli Vapalahti, MD, PhD  
Departments of Virology and Veterinary Biosciences  
Faculties of Medical and Veterinary Medicine University  
of Helsinki  
Helsinki, Finland

Associate Professor Anna-Maija Virtala, DVM, PhD  
Department of Veterinary Biosciences  
Faculty of Veterinary Medicine  
University of Helsinki  
Helsinki, Finland

**Reviewers**

Professor Stina Ekman, DVM, PhD, diplomate of ECVP  
Swedish University of Agricultural Sciences  
Uppsala, Sweden

Dr. Mariann Chriél, Senior Executive Officer, DVM,  
PhD  
National Veterinary Institute  
Technical University of Denmark  
Lyngby, Denmark

**Opponent**

Associate Professor Anne Sofie Vedsted Hammer,  
DVM, PhD  
Institute for Veterinary Disease Biology  
University of Copenhagen  
Fredriksberg, Denmark

ISBN 978-951-51-3807-1 (pbk.)

ISBN 978-951-51-3808-8 (PDF)

Unigrafia, Helsinki 2017

# ABSTRACT

In 2007, Finnish farmers detected signs of a new disease in fur animals. Mink had severe necropurulent dermatitis in the feet and head region and foxes had aggressive keratoconjunctivitis that spread to the eyelid and also to facial dermatitis. Even Finnraccoons (a raccoon dog bred for the fur industry), which are generally resistant to many diseases, suffered from painful furuncles between the toes.

The symptoms were severe, even fatal, and the disease seemed to spread aggressively between and within the farms. Similar symptoms (designated as "pododermatitis") in mink had previously been detected in the early 1970s in USA and in 1996 in Canada. North American farmers, and later researchers, linked the onset of the new symptoms to the start of feeding mink with feed containing seal byproducts. Today, the fur industries have detected similar signs of this disease in many countries including Denmark, the Netherlands, Iceland, Poland, Spain, Greece, Norway, and Sweden.

The disease severely compromises animal welfare and causes financial losses to the farmers and the fur industry. The University of Helsinki (UH), the Finnish Fur Breeders' Association (FFBA), and the Finnish Food Safety Authority—Evira initiated a collaborative project in 2009 to describe the pathology of the disease, identify the causative organism(s), and describe the epidemiology of the disease in Finland including identification of possible sources and risk factors of the disease. Hence, we conducted pathological, microbiological, epidemiologic, and experimental studies.

Ninety-nine fur animals underwent necropsies with complete microbiological examinations, including: mink, foxes, and Finnraccoons. The groups comprised diseased animals (61), their healthy controls from non-affected farms (34), and clinically healthy animals from affected farms (4). Due to the common gross and histologic lesions, particularly the severe necrotizing pyoderma observed in diseased animals of all fur animal species the disease was named *Fur animal epidemic necrotic pyoderma* (FENP).

No specific viral pathogens have yet been identified via microbiological examination, however, a suspected causative agent was seen in bacteriological studies. The bacterium *Arcanobacterium phocae* was isolated and confirmed by PCR from the affected tissues from all diseased animals (61/61), but not from healthy controls (1/23\*) derived from non-affected farms. The association to *A. phocae* infection is particularly interesting, because this bacterium causes purulent skin inflammations and abscesses in marine mammals such as seals, and a temporal connection between the onset of the epidemic in mink and the use of seals as a feed source for mink had previously been found in North America.

\* The farm selected for healthy control farm for Finnraccoons proved to be affected during the study, hence healthy Finnraccoon controls (11) are excluded. One healthy mink from non-affected farm had low numbers of *A. phocae* in the PCR study.

This report is the first to discover *A. phocae* in the samples obtained from fur animals. In addition, a novel *Streptococcus* species also with a likely marine origin and closely related to *Streptococcus halicoeri*, was detected in the tissues of animals with FENP, especially in mink and Finnraccoons. Further investigation is required into the role of the novel *Streptococcus* sp., as well as other possible viral or bacterial pathogens, in the pathogenesis of FENP.

Infection of mink with *A. phocae* alone was shown here to cause FENP-like symptoms. Signs were evident when *A. phocae* was delivered as the only infectious isolate (23/34), and also when delivered in combination with the novel *Streptococcus* sp. (7/8 tested). The inoculates were successfully delivered intradermally/subcutaneously or via artificially wounded skin. No signs were detected in animals that had been inoculated perorally (0/24). Similarly, inoculating mink with tissue extract of an FENP-diseased animal intradermally/subcutaneously or via artificially wounded skin caused typical signs (4/10) of the disease, whereas no signs were detected using the peroral inoculation route (0/4). The experimental infection also showed that the bacterium was able to spontaneously spread within in the experimental facility, as low levels of *A. phocae* were detected in non-inoculated mink towards the end of the study, but not from samples taken from the control animals from the beginning of the study. The experimental infection study further indicated that weather conditions may influence the outcome of FENP, as severe signs developed more rapidly when the ambient temperatures were very low (below - 20 °C).

Our epidemiological study conducted as a mail survey among Finnish fur farmers showed that the disease had spread to all areas where fur farming is practiced in Finland during the study years 2009-2011. Signs of FENP were reported in all farmed species, and the number of affected farms increased each year: 40% of responding farms (92/239) reported signs of FENP during the study period. The study also clarified the specific clinical signs of FENP observed by the farmers in different fur animal species. The presence of FENP on a given farm in the study was associated with importation of fur animals from Denmark and/or Poland, and the spread of the disease between Finnish farms was connected with fur animal purchases from domestic sources. Some predisposing risk factors were identified, such as the farm type: FENP was detected most on mixed farms (farming more than one species of fur animals) and on larger farms (as defined by the number of the breeding fur animals). The study also showed an association between the occurrence of FENP on the farm and the access of birds and other wildlife to the farm and animal housing. The use of the escape-proof shelter buildings, which block the access of birds and other wildlife to the shelter buildings and thus prevent

close contacts between the wildlife and fur animals, significantly diminished the risk of FENP. The study indicated that FENP can be associated with other diseases on the farm as a positive association to sticky kits and a negative association to plasmacytosis was observed. The disease was also found to be associated with the color type of the mink, nipple drinking water dispensers, and the type of the bedding material used in mink nests.

This thesis describes the clinical signs and gross and histopathological lesions of FENP in fur animals. It implicates *A. phocae* as a likely causative pathogen for FENP and indicates a possible additional role of a novel *Streptococcus* sp. as a potential cofactor or co-pathogen. The data provide a basis for the development of the diagnostics, treatment, or vaccines for FENP. The data also describe the epidemiologic aspects of FENP in Finland showing that FENP is a highly detrimental disease among Finnish fur animals. Some potential risk factors that may be involved in contributing to the spread of the disease are revealed and thus provide targets for control and mitigation of FENP.

# ACKNOWLEDGEMENTS

These studies were carried out in the Doctoral Programme in Clinical Veterinary Medicine (CVM) at the Department of Veterinary Biosciences, Faculty of Veterinary Medicine, University of Helsinki, Finland in cooperation with FinFurlab, FFBA and Evira. The Helve foundation, the Reino Rinne foundation, the University of Helsinki, Evira and FFBA kindly provided funding and enabled the studies.

I wish to warmly thank the supervisors of this study, Professors Antti Sukura and Olli Vapalahti and adjunct Professor Anna-Majja Virtala; Thank you for your valuable scientific advice and guidance as well as for your great patience with me and my sometimes a bit straightforward way to jump in to the conclusions. "You can take a boy out of the jungle, but you can't take the jungle out of the boy". But I think you made a big effort and an excellent job!

I also express my warm thanks to both pre-examiners Professor Stina Ekman and Dr. Mariann Chriél for their effort and good and constructive comments; you really made me sweat, but helped me to improve this thesis a lot. I want to thank adjunct Professor Anne Sofie Hammer for her kind acceptance to be my opponent; it will be a pleasure to discuss with you about this topic that we share an interest on.

All the farmers participating in the studies, my co-authors and all the other people who helped me in various ways during this long process; I thank you from the bottom of my heart, you made this possible!

Tarja Sironen, Kirsi Aaltonen, Anna-Maria Moisande-Jylhä, Katariina Vapalahti, Mirja Raunio- Saarnisto, Pirjo Aronen, you were my scientific life savers in many, many situations, but I am proud to think that I got also your dear friendship for the rest of my life. Special thanks to all my other dear coworkers at Evira Seinäjoki, FinFurlab, FFBA and my great former and current fellow workers at pathology and parasitology unit. Especially thanks to Henna, with whom I share the room, interesting cases and a kind of post mortal humor. Thanks also for all technical support and for always knowing where my keys are, and of course, for the therapeutic delicious cakes you bake!

Mira, Virpi, Hannu, my top friends and a support group, thank you for all the help concerning my studies and special thanks for dragging me every now and then out of my scientific cave and showing me that there is life outside veterinary medicine. Thank you also for my super cool ice hockey team mates in Kiekko- Nikkarit Ladies; Ice hockey players have fire in their hearts and ice in their veins (I will probably need that at the defense)!

Then finally, warm thank you to my mother Sirkka for her endless support. My children Eppu, Santtu and Vensku; heartfelt thanks to you for providing everyday joy and sometimes a bit different kind of challenge in my life, you still are my best achievements.

Let the sun shine in your heart,  
Riihimäki, October 2017

# CONTENTS

|   |    |
|---|----|
| ABSTRACT.....   | 3  |
| ACKNOWLEDGEMENTS .....  | 6  |
| CONTENTS.....   | 8  |
| LIST OF ORIGINAL PUBLICATIONS.....                                | 14 |
| ABBREVIATIONS.....  | 15 |
| 1 INTRODUCTION .....  | 16 |
| 2 REVIEW OF THE LITERATURE.....                                   | 18 |
| 2.1 FUR FARMING.....  | 18 |
| 2.1.1 GENERAL OUTLINE.....  | 18 |
| 2.1.2 SPECIES FARMED FOR THEIR FUR.....                           | 18 |
| 2.1.2.1 Mink ( <i>Neovison vison</i> ) .....                      | 18 |
| 2.1.2.2 Blue fox ( <i>Vulpes lagopus</i> ) .....                  | 19 |
| 2.1.2.3 Silver fox ( <i>Vulpes vulpes</i> ) .....                 | 19 |
| 2.1.2.4 Finnraccoon ( <i>Nyctereutes procyonoides</i> ) .....     | 20 |
| 2.1.3 HOUSING SYSTEM AND PRODUCTION CYCLE OF<br>FUR ANIMALS ..... | 21 |
| 2.1.4 FUR FARMING IN FINLAND.....                                 | 22 |
| 2.2 SKIN .....  | 23 |
| 2.2.1 STRUCTURE OF THE SKIN .....                                 | 23 |
| 2.2.2 FUNCTIONS OF THE SKIN.....                                  | 25 |
| 2.2.3 NORMAL FLORA OF THE SKIN .....                              | 25 |
| 2.2.4 NORMAL FLORA OF THE SKIN OF FUR ANIMALS ...                 | 26 |
| 2.3 SKIN DISEASES IN FUR ANIMALS.....                             | 26 |
| 2.3.1 INFECTIOUS SKIN DISEASES .....                              | 26 |
| 2.3.1.1 Viral diseases with a dermal manifestation .....          | 26 |



|         |   |    |
|---------|---|----|
| 2.3.1.2 | Bacterial diseases with a skin manifestation .....                        | 28 |
| 2.3.1.3 | Fungal diseases with a skin manifestation.....                            | 29 |
| 2.3.1.4 | Parasitic diseases with a dermal manifestation.....                       | 29 |
| 2.3.2   | PHYSICAL AND CHEMICAL INJURY TO THE SKIN ..                               | 30 |
| 2.3.2.1 | Traumatic skin diseases .....   | 30 |
| 2.3.2.2 | Callus .....  | 31 |
| 2.3.2.3 | Temperature and sunlight .....  | 31 |
| 2.3.3   | IMBALANCES THAT MANIFEST IN ALTERED SKIN<br>CONDITION AND APPEARANCE..... | 31 |
| 2.3.4   | CONGENITAL AND HEREDITARY DISEASES OF<br>THE SKIN .....                   | 32 |
| 2.3.4.1 | Tyrosinaemia .....  | 32 |
| 2.3.4.2 | The Ehlers-Danlos syndrome .....  | 33 |
| 2.3.4.3 | Keke-syndrome of silver foxes .....                                       | 33 |
| 2.3.5   | ENDOCRINE DISEASES OF THE SKIN.....                                       | 33 |
| 2.3.6   | OCULAR DISEASES OF BLUE FOXES.....  | 34 |
| 2.4     | FUR ANIMAL EPIDEMIC NECROTIC PYODERMA, FENP .....                         | 34 |
| 2.4.1   | PREVIOUS OUTBREAKS OF A SIMILAR<br>SYNDROME .....                         | 34 |
| 2.4.2   | EPIDEMIOLOGIC CHARACTERISTICS .....                                       | 35 |
| 2.4.3   | TENTATIVE ETIOLOGY .....  | 36 |
| 2.5     | CHARACTERISTICS OF <i>ARCANOBACTERIUM PHOCAE</i> .....                    | 36 |
| 2.5.1   | TAXONOMY .....  | 36 |
| 2.5.2   | MORPHOLOGY AND GROWTH CONDITIONS .....                                    | 37 |
| 2.5.3   | DIAGNOSTICS .....   | 37 |
| 2.5.3.1 | Detection by culturing .....  | 37 |
| 2.5.3.2 | Molecular detection .....   | 37 |
| 2.5.3.3 | MALDI-TOF mass spectrometry.....  | 37 |
| 2.5.4   | VIRULENCE FACTORS .....   | 38 |

|         |   |    |
|---------|---|----|
| 2.5.5   | DISEASES CAUSED BY ARCANOBACTERIA.....  | 38 |
| 3       | AIMS OF THE STUDY .....   | 40 |
| 4       | MATERIALS AND METHODS .....   | 41 |
| 4.1     | SAMPLING ANIMALS FOR DESCRIPTION OF CLINICAL<br>SIGNS AND FOR PATHOLOGICAL AND MICROBIOLOGICAL<br>STUDIES (I) ..... | 41 |
| 4.2     | EXPERIMENTAL INFECTION STUDY (II) .....   | 42 |
| 4.2.1   | EXPERIMENTAL ANIMALS .....  | 42 |
| 4.2.2   | THE FACILITIES USED IN STUDY II .....   | 42 |
| 4.2.3   | THE BACTERIA AND TISSUE SUSPENSION USED<br>IN EXPERIMENTAL INFECTION (II) .....                                     | 43 |
| 4.2.3.1 | Bacterial Inocula .....   | 43 |
| 4.2.3.2 | FENP tissue inocula .....   | 43 |
| 4.2.4   | EXPERIMENTAL INFECTIONS.....  | 44 |
| 4.2.4.1 | Pilot study 1 (II) .....  | 45 |
| 4.2.4.2 | Pilot study 2 (II).....   | 46 |
| 4.2.4.3 | The main experimental study (II) .....  | 46 |
| 4.3     | PATHOLOGICAL AND MICROBIOLOGICAL STUDIES.....   | 48 |
| 4.3.1   | GROSS PATHOLOGY AND HISTOPATHOLOGY IN<br>STUDIES I AND II.....  | 48 |
| 4.3.2   | BACTERIOLOGICAL STUDIES IN STUDIES I AND<br>II.....   | 48 |
| 4.3.2.1 | PCR detection of <i>Arcanobacterium phocae</i> and the<br>novel <i>Streptococcus</i> sp. ....                       | 49 |
| 4.3.2.2 | Antibiotic susceptibility .....   | 49 |
| 4.3.3   | VIROLOGICAL STUDIES.....  | 49 |
| 4.3.3.1 | Virus detection by (RT)-PCR-studies .....   | 49 |
| 4.3.3.2 | Antibody detection .....  | 50 |
| 4.3.3.3 | Virus isolation trials.....   | 50 |
| 4.4     | MAIL SURVEY OF FINNISH FUR FARMERS (III) .....  | 51 |
| 4.4.1   | STUDY DESIGN.....   | 51 |

|         |  |    |
|---------|--|----|
| 4.4.2   | DEFINITIONS OF THE VARIABLES USED IN THE STUDY .....   | 51 |
| 4.4.3   | STATISTICAL ANALYSIS .....   | 52 |
| 4.5     | ETHICAL STATEMENTS AND LEGISLATION REGARDING STUDIES I, II, AND III.....   | 53 |
| 5       | RESULTS .....  | 55 |
| 5.1     | CLINICAL SIGNS, PATHOLOGICAL CHARACTERIZATION, AND MICROBIOLOGICAL FINDINGS OF FUR ANIMAL EPIDEMIC NECROTIC PYODERMA, FENP ..... | 55 |
| 5.1.1   | CLINICAL SIGNS.....  | 55 |
| 5.1.1.1 | Clinical signs in mink (I).....  | 55 |
| 5.1.1.2 | Clinical signs in foxes (I).....   | 56 |
| 5.1.1.3 | Clinical signs in Finnraccoons (I) .....   | 57 |
| 5.1.2   | GROSS PATHOLOGY FINDINGS .....   | 58 |
| 5.1.2.1 | Gross pathology in mink (I).....   | 58 |
| 5.1.2.2 | Gross pathology findings in foxes (I).....   | 61 |
| 5.1.2.3 | Gross pathology in Finnraccoons (I).....   | 62 |
| 5.1.2.4 | Clinical signs and gross pathology in the experimental infection (II).....   | 63 |
| 5.1.3   | HISTOPATHOLOGICAL FINDINGS .....   | 66 |
| 5.1.3.1 | Histopathological findings in mink (I).....  | 66 |
| 5.1.3.2 | Histopathological findings in foxes (I) .....  | 68 |
| 5.1.3.3 | Histopathological findings in Finnraccoons (I).....  | 69 |
| 5.1.4   | HISTOPATHOLOGICAL FINDINGS IN THE INFECTION STUDY (II).....  | 69 |
| 5.1.5   | BACTERIOLOGICAL RESULTS (I) .....  | 72 |
| 5.1.6   | BACTERIOLOGICAL RESULTS (II) .....   | 74 |
| 5.1.7   | VIROLOGICAL RESULTS (I).....   | 74 |
| 5.2     | EPIDEMIOLOGIC STUDIES OF FENP (III).....   | 75 |
| 5.2.1   | COVERAGE OF THE RESPONDENT FARMS.....  | 75 |
| 5.2.2   | OCCURRENCE OF FENP IN THE STUDY FARMS.....   | 76 |

|         |  |    |
|---------|--|----|
| 5.2.3   | RISK FACTORS FOR FENP IN THE STUDY FARMS...                                  | 78 |
| 5.2.4   | GENERAL INFORMATION OBTAINED FROM THE SURVEY STUDY OF FINNISH FUR FARMS..... | 81 |
| 6       | DISCUSSION .....   | 82 |
| 6.1     | FUR ANIMAL EPIDEMIC PYODERMA .....   | 82 |
| 6.1.1   | CHARACTERISTICS OF FENP .....  | 82 |
| 6.1.1.1 | Predilection site .....  | 83 |
| 6.1.1.2 | Fur animal species specific presentation .....                               | 84 |
| 6.1.1.3 | Systemic signs .....   | 84 |
| 6.1.1.4 | Potential infection route.....   | 85 |
| 6.1.1.5 | Demography of FENP .....   | 86 |
| 6.1.1.6 | Treatment trials .....   | 86 |
| 6.1.2   | ETIOLOGY OF FENP.....  | 87 |
| 6.1.2.1 | Subclinical infections .....   | 88 |
| 6.1.2.2 | Synergetic pathogens .....   | 88 |
| 6.1.2.3 | Searching for a virus .....  | 89 |
| 6.1.3   | EXPERIMENTAL INFECTION OF <i>A. PHOCAE</i> IN MINK .....                     | 89 |
| 6.1.3.1 | Spontaneous spread of <i>A. phocae</i> in the experimental unit .....        | 90 |
| 6.1.3.2 | Immunity .....   | 91 |
| 6.1.4   | EPIDEMICAL STUDIES ON FENP .....   | 91 |
| 6.1.4.1 | Importance .....   | 92 |
| 6.1.4.2 | Risk factors .....   | 92 |
| 6.1.4.3 | Biosecurity of fur animals .....   | 93 |
| 6.1.4.4 | Animal and environmental risk factors .....                                  | 94 |
| 6.1.4.5 | Other suspected sources .....  | 95 |
| 7       | CONCLUSION AND FUTURE PROSPECTS .....  | 96 |
|         | REFERENCES .....   | 98 |

ORIGINAL PUBLICATIONS..... 108

# LIST OF ORIGINAL PUBLICATIONS

This thesis is based on the following publications:

- I Heli Nordgren, Kirsi Aaltonen, Tarja Sironen, Paula M. Kinnunen, Ilkka Kivistö, Mirja Raunio-Saarnisto, Anna-Maria Moisander-Jylhä, Johanna Korpela, Ulla-Maija Kokkonen, Udo Hetzel, Antti Sukura, Olli Vapalahti: **Characterization of a New Epidemic Necrotic Pyoderma in Fur Animals and its Association with *Arcanobacterium phocae* Infection.**  
PloS one 9.10 (2014): e110210.
- II Heli Nordgren, Kirsi Aaltonen, Mirja Raunio-Saarnisto, Antti Sukura, Olli Vapalahti, Tarja Sironen: **Experimental infection of mink enforces the role of *Arcanobacterium phocae* as causative agent of Fur Animal Epidemic Necrotic Pyoderma (FENP).**  
PloS one 11.12 (2016): e0168129.
- III Heli Nordgren, Katariina Vapalahti, Olli Vapalahti, Antti Sukura, Anna-Maija Virtala: **Questionnaire survey of detrimental fur animal epidemic necrotic pyoderma in Finland.**  
Acta Veterinaria Scandinavica (2017): 59(1), 54.

The publications are referred to in the text by their Roman numerals (I-III). The original articles are reprinted with the kind permission of their copyright holders.

# ABBREVIATIONS

|              |  |
|--------------|--|
| AMDV         | Aleutian Mink Disease virus  |
| CDV          | Canine Distemper Virus   |
| c.f.u        | Culture forming unit   |
| CI           | Confidence interval  |
| CPE          | Cytopathic effect  |
| ELISA        | Enzyme-linked immunosorbent assay  |
| EM           | Electron microscope  |
| et al.       | And others   |
| Evira        | Finnish Food Safety Authority  |
| FENP         | Fur Animal Epidemic Pyoderma   |
| FFBA         | Finnish Fur Breeders Association   |
| FMD          | Foot and mouth disease   |
| GMS          | The Modified Gomori Methenamine-Silver Nitrate                               |
| HE           | Hematoxylin and eosin stain  |
| i.d.         | intra dermal   |
| i.m.         | intra muscular   |
| MALDI-TOF MS | Matrix Assisted Laser Desorption Ionization Time of Flight Mass Spectrometry |
| MEV          | Mink Enteritis parvovirus  |
| n            | Number   |
| nt           | Nucleotide   |
| OR           | Odds ratio   |
| p            | probability  |
| p.o.         | per os (by mouth)  |
| PCR          | polymerase chain reaction  |
| PFT          | Pore Forming Toxin   |
| PLD          | Phospholipase D  |
| PLO          | Pyolysin   |
| s.c.         | sub cutaneous  |
| UH           | University of Helsinki   |
| WQ           | Welfare quality  |
| WS           | The Warthin–Starry stain   |
| ZN           | The Ziehl–Neelsen stain  |

# 1 INTRODUCTION

Fur animals are bred for fur and any injury reducing the quality of the pelt has a notable negative impact on fur farming. Issues such as wounds, mechanical injuries, vaccination granulomas, ectoparasites, fungal skin diseases, fur biting, nutritional deficiencies, or genetic disorders can cause lesions in the skin and fur. These lesions cause discomfort to the animals which compromises the animal's welfare and affect the quality of the pelt with considerable financial losses to the farmers.

An apparently new severe necropurulent dermatitis was detected in Finnish fur animals in 2007. It differed in nature from previously known skin diseases, as the new disease spread between farms and from an infected site to uninfected sites within farms like a contagious disease. The disease affected all fur animal species farmed in Finland: mink (*Neovison vison*), foxes (*Vulpes lagopus*), and Finnraccoons (*Nyctereutes procyonoides*, a raccoon dog bred for the fur industry). The location of the lesions and symptoms varied between different species, but a common feature was a severe necrotizing pyoderma, which led to the suggested name of the disease: fur animal epidemic necrotic pyoderma (FENP). The symptoms developed rapidly and no treatment was clearly effective. High doses of antibiotics s.c./i.m. seemed to help some animals when the treatment was started at an early stage of the disease. However, the treated animals with no clinical symptoms had relapses or were able to spread the disease. In general, skin inflammations have poor prognosis in fur animals and often need long term treatment. In the case of semi-wild animals that are not individually handled every day, the initial symptoms are not easy to detect, and treatment of large numbers of animals individually for long periods is cumbersome. Veterinarians recommend that Finnish farmers euthanize fur animals as soon as the first clinical signs of FENP are detected to avoid pain and distress of the diseased animals and to disinfect the cages to reduce the spread of the disease within a farm.

Similar symptoms, diagnosed as pododermatitis, were documented earlier in farmed mink in Canada in 1996 and USA in the 1970's. The onset of the disease was simultaneous with the beginning of the use of seal byproducts in the mink feed (Bröjer, 2000). A Canadian study suggested that the cause of the diseases was an unidentified infectious agent with secondary bacteriologic pyoderma. To our knowledge, there is no published research done previously about this disease in foxes and Finnraccoons. Presently, other countries have observed similar lesions in farmed fur animals, but the pathogenesis and contributing factors remained hitherto unidentified.

In 1997, a newly discovered bacterium, *Araconobacterium phocae*, was isolated from the diseased tissues taken from gray seals (*Halichoerus grypus*) and common seals (*Phoca vitulina*) in the UK (Ramos et al., 1997). Johnson et al. (2003) reported 141 *A. phocae* isolates from marine mammals sampled in the USA from 1994-2000. The isolates originated from skin lesions, such as abscesses and wounds after traumatic skin injury (bites, bullet wounds, fishing hooks). However, in some cases *A. phocae* have also been isolated from systemic inflammations but often in mixed inflammations in marine mammals (Johnson et al., 2003). *A. phocae* belongs to the genus *Araconobacterium* first described by Collins et al. in 1982. The genus *Araconobacterium* comprises the species *A. haemolyticum*, *A. hippocoleae*, *A. pluranimalium*, *A. phocae*, and



recently *A. canis*, *A. phocisimile*, and *A. pinnipediorum* sp. nov. have also been included. Bacteria belonging to the genus *Arcanobacterium* are recovered from various organs such as the respiratory, digestive, and reproductive tracts, abscesses and systemic inflammations in different species (MacKenzie et al., 1995).

In 2010, a collaborative project to isolate the etiological agents of the disease and to describe the clinical signs, gross and histological lesions, and to identify risk factors was initiated by the Finnish Fur Breeders association (FFBA), Finnish Food Safety Authority Evira, and the University of Helsinki (UH).

This dissertation reports the clinical, pathological, and microbiological characteristics (study I); an experimentally induced infection (study II); and epidemiologic studies (III) of FENP and provides evidence that *A. phocae* and the novel *Streptococcus* sp. have a role in the pathogenesis of FENP.

The following literature review describes the main characteristics of fur production and farmed fur animals. Furthermore, the structure and function of the normal skin as well as known diseases that affect the skin of fur animals provide the background to the discourse on FENP, a new skin disease of fur animals.

## 2 REVIEW OF THE LITERATURE

### 2.1 FUR FARMING

#### 2.1.1 GENERAL OUTLINE

Fur animals are defined as production animals bred exclusively for their pelt. Fox, mink, and Finn raccoon pelts are produced in Finland. Finland is the biggest producer of Finn raccoon pelts and the second biggest producer after China of fox pelts in the world. Denmark is a leading country in mink pelt production. Other pelt-producing countries include Poland, the Netherlands, Canada, the U.S.A., Spain, Greece, the Baltic countries, Russia and Sweden. China became the biggest mink producer at the beginning of 2000, but Chinese production volumes have recently diminished. The most important sales channel of pelts is auctions through which the furs are sold to the fashion industry and clothing businesses. Saga Furs Oyj sells the majority of the Finnish pelts. The export revenues earned by Finnish pelt varies between years: in 2015 it was 611 million euros but in 2016 it was approximately half of the income of year 2015.

#### 2.1.2 SPECIES FARMED FOR THEIR FUR

##### 2.1.2.1 *Mink (Neovison vison)*

Mink (The American mink *Neovison vison*) originates from North America. It is a carnivorous mammal. According to the latest taxonomic research it belongs to the genus *Neovison* in the subfamily *Mustelinae* (Abramov, 2000) and thus is not a member of the subgenus *Mustelidae* as is the European mink (*Mustela lutreola*). Domestication of mink started in North America in the late 1880s. In Finland, mink farming began in the 1930s. There are various color variants of mink, from white and light grey to brown, maroon, and black (Nes et al., 1998, Lohi et al., 2015). Females weigh 1–3 kg and males 2–5 kg. Mink mate in March in the Northern hemisphere, and give birth in April–May. The average litter size in Finland is 4.5 mink kits per breeding female.



**Figure 1.** Mink (*Neovison vison*), brown color type. The picture was obtained from the FFBA.

### **2.1.2.2 Blue fox (*Vulpes lagopus*)**

Farmed blue foxes originate from Alaska’s and Greenland’s arctic foxes. Both blue and winter-white colors are found among the wild foxes. The arctic fox was previously counted as its own genus “Alopex,” but according to the latest changes in the taxonomic system it has been moved to the genus “Vulpes” (Roskov et al., 2015). The Blue fox is the most common fur animal farmed in Finland—its breeding began in Finland in the 1920s. The blue fox coat color varies from a very light tone in the winter to a dark tone in the summer. There are also partly or entirely white color mutants of farmed blue foxes, such as white or pale shadow foxes (Nes et al., 1998, Lohi et al., 2015). Breeding females weigh 7–8 kg and males 10–20 kg. Blue foxes are almost exclusively bred using artificial insemination in March–April. The cubs are born in May–July and the average litter size is 4.8 cubs per breeding female.



**Figure 2.** Blue fox (*Vulpes lagopus*). The picture was obtained from the FFBA.

### **2.1.2.3 Silver fox (*Vulpes vulpes*)**

Silver fox is a melanistic form of red fox (*Vulpes vulpes*). Breeding of silver foxes began in Finland in the 1910s. Selective breeding has resulted in a strongly silver-toned variant from the original black color. In-between types of red and silver fox, as well as several brown and grey color mutants, are known (Nes et al., 1998, Lohi et al., 2015). Silver foxes are smaller

than blue foxes; females weigh 4.5–6 kg and males 6–7 kg. Silver foxes are mostly artificially inseminated in February–March and give birth in April–May, the average litter size is 3.6 cubs per breeding female.



**Figure 3.** Silver fox (*Vulpes vulpes*). The picture was obtained from the FFBA.

#### **2.1.2.4 Finnracon (Nyctereutes procyonoides)**

Raccoon dogs originate from East Asia (Mäkinen, 1978) and were translocated to the Ural Mountains and migrated to neighboring countries including Finland. Farming of Finnracons began in Finland in the 1970s. The name Finnracon is used to differentiate farmed raccoon dogs from those that are wild. Finnracons unlike the wild raccoon dogs do not hibernate because in farm conditions nutrition is available all year round. The color of the Finnracon fur goes from white and light brown to maroon and almost black (Nes et al., 1998), some color variants are also known (Lohi et al., 2015). The weight of a Finnracon varies from 6–8 kg in the summer to over 10 kg in the winter. Finnracons are inseminated or mated in February–March. On average, they give birth to 6 cubs per breeding female in April–May.



**Figure 4.** Finnracon (*Nyctereutes procyonoides*). The picture was obtained from FFBA.

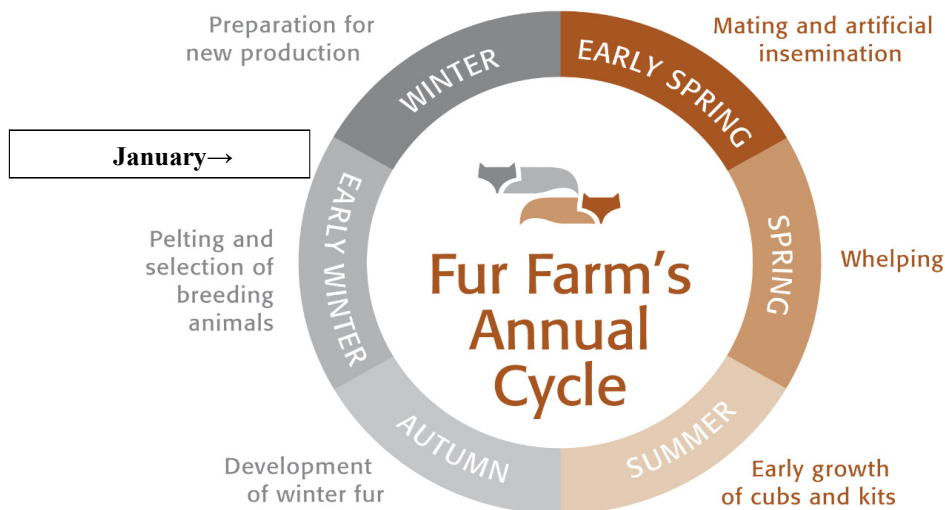
### 2.1.3 HOUSING SYSTEM AND PRODUCTION CYCLE OF FUR ANIMALS

The fur animals are mainly housed outside in shelter buildings but mink may also be housed indoors in halls. In Finland, animals are kept under their natural climatic conditions, and they can cope in the farm conditions well all year round. The Finnish climate especially favors breeding of the long-haired fur animals (Finnraccoons and foxes).

The breeder animals are caged individually, and the cubs and kittens are housed in groups of 2–4 mink, or 2–5 foxes and Finnraccoons, depending of the cage size. The feed for fur animals mainly consists of byproducts of the fish and meat industries. The requirements for housing and management of fur animals are regulated under Finnish legislation (Vna 1084/2011).

The annual cycle of a fur farm can be divided into six periods. The breeding season is in early spring when animals are mated or inseminated. Whelping takes place in spring to early summer depending on the species. In summer, kits and cubs grow with littermates and their mother. Mink kits are vaccinated with a trivalent vaccine against parvoviral enteritis, botulism, and hemorrhagic lung inflammation caused by *Pseudomonas aeruginosa*. Most Finnracon farmers vaccinate cubs against parvoviral enteritis. The cubs and kittens are weaned at the age of approximately 8 weeks. In autumn, winter pelts start to develop and pelting takes a place in November–December.

Fur animals are culled on the farms. Foxes and Finnraccoons are culled using electricity and mink using gas, carbon monoxide (CO) or carbon dioxide (CO<sub>2</sub>). The methods, the competency, and training requirements for the persons in charge of the equipment and handling of the animals are outlined in legislation concerning culling of the animals (EUN: o 1099/2009). The breeding mink for the following breeding season are selected in November and blue fox vixens and Finnracon females in August–September. Some farmers vaccinate blue fox breeding animals in December–January in order to avoid infertility problems caused by parvovirus. Plasmacytosis (Aleutian disease) testing on mink farms is performed at three distinct times. If all animals are tested on a farm, this will be carried out in September–October. The breeders are tested during winter, and barren females in July–August.



**Figure 5.** Fur farm's annual cycle. FFBA's website; [http://www.turkistieto.fi/Basic\\_Information](http://www.turkistieto.fi/Basic_Information).

## 2.1.4 FUR FARMING IN FINLAND

Fur farming has a long tradition in Finland, starting in 1910 with silver fox farming. In 2016, there were 923 fur farms operating in Finland. Altogether 97% of Finnish fur farms are in Western Finland in the Ostrobothnia region. A total of 1.9 million mink, 2.4 million foxes, and 148,000 Finnraccoons were farmed in Finland in 2016. The majority of farms are family businesses and they operate independently without any state subsidies. Most Finnish fur farmers are members of the Finnish Fur Breeders' Association (FFBA) (Profur).

The FFBA created its own certification system of Finnish fur farms in 2004 in order to focus on animal welfare and environmental protection on the farms. The certification criteria were developed with assistance of authorities and specialists in fur farming. In 2016, the certification system covered 93% of all fur farms in Finland.

The WelFur welfare system is based on Welfare quality (WQ)-principles and it is used as a tool to measure animal welfare on fur farms. It is developed by fur animal behavior and welfare scientists, and at the time of writing this thesis there are separate protocols for mink and fox, while the protocol for Finnraccoons is currently under development.

A healthcare system for Finnish fur animals, FUREVA, was established in 2015. FUREVA consists of regular healthcare visits of veterinarians to the farms in order to prevent health problems, improve animal welfare, and implement adequate and rapid treatment in a case of a disease outbreak. FUREVA is administered by FFBA and information, such as the health status of the animals (diseases detected and treated on the farm, mortality rate and cause of the deaths), is recorded in the database. In the future, using the data collected to the FUREVA it is also possible to monitor the health status and disease situation among Finnish fur animals.

## 2.2 SKIN

### 2.2.1 STRUCTURE OF THE SKIN

The skin is the largest organ of the body, consisting of several layers and forming appendages in animals: nails, hooves, and claws. Although most diseases affecting the skin originate in its layers, many internal diseases also affect the skin. Skin lesions may be induced by internal diseases such as; endocrinopathies and metabolic disturbances, such as hypothyroidism (Scott-Moncrieff 2007), Cushing disease (Zur et al., 2011), and hepatocutaneous syndrome in dog due to a vacuolar hepatopathy (Miller et al., 1990). The layers of the skin and the adnexa will be reviewed here in turn, including the epidermis, dermis, hair follicles, sebaceous and sweat glands, and the underlying subcutis (Fig. 6).

The epidermis is the outermost layer of the skin, consisting of distinct layers (Fig. 6): the stratum corneum, the stratum lucidum, the stratum granulosum, the stratum spinosum, and the stratum basale. It is thinner in the haired areas and thicker in non-haired areas, such as the nose and footpads. The stratum corneum is the most superficial layer and it comprises many sheets of flat anucleated eosinophilic keratinized cells (terminally differentiated keratinocytes). Keratin is responsible for the mechanical resistance of the skin and the stratum corneum is at its thickest in the high-pressure areas, such as the footpads. The dead cells shed from the stratum corneum and the epidermis renews when new keratinocytes from the stratum basale migrate to the stratum corneum. The stratum basale is the deepest germinate layer and produces new keratinocytes, which are mitotically active nucleated cells. The stratum granulosum and the stratum spinosum are situated between the stratum basale and the stratum corneum. The stratum granulosum comprises cells with basophilic keratohyaline granules. The stratum lucidum is a thin, pale eosinophilic layer, and only seen in regions where epidermis is very thick (Bacha and Bacha 2006).

The cells of the epidermis include keratinocytes (85-90% of the cells of epidermis, described above), melanocytes, Langerhans cells, and Merkel cells (Mauldin and Peters-Kennedy, 2015). Melanocytes produce melanin pigment, which imparts color to the skin and hair, as well as protecting against ultraviolet (UV) light. Exposure to UV light increases melanin production. In addition, local inflammation enhances skin pigmentation because melanocytes respond to inflammatory mediators. Langerhans cells are related to monocyte/macrophage cells and they act as antigen presenting cells providing immunosurveillance. Merkel's cells are believed to act as mechanoreceptors and regulate epidermal and adnexal structures (Mauldin and Peters-Kennedy, 2015).

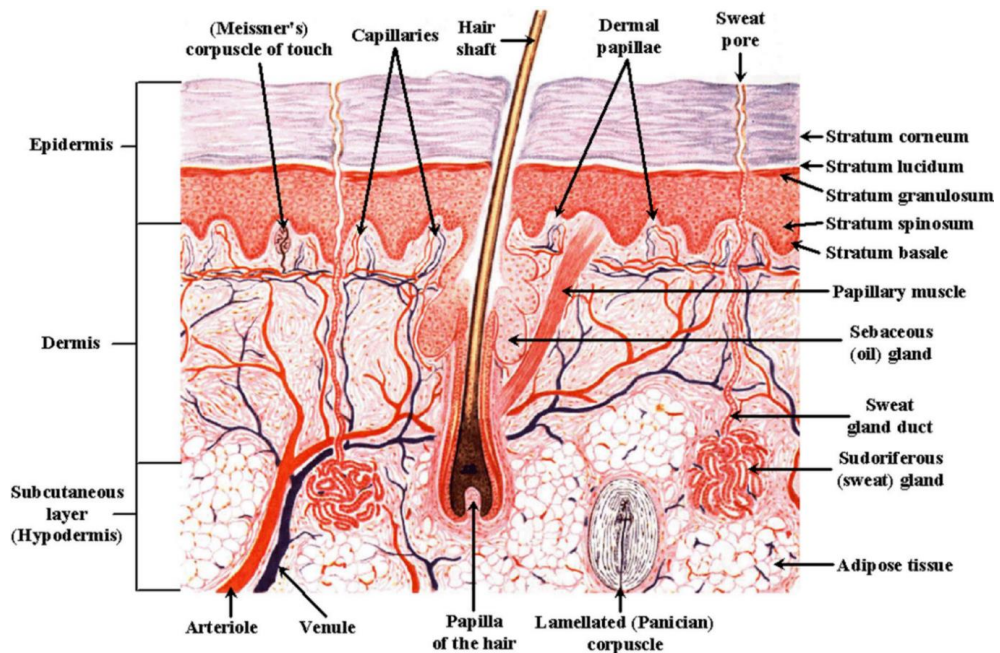
The junction between epidermis and dermis is defined by the basement membrane of stratum basale. The dermis is responsible for the maintenance and repair of the skin. It makes the skin elastic and gives it high tensile strength. The dermis consists of fibroblasts producing different collagen fibres (in the skin primarily types I and III) and elastic fibres, blood and lymphatic vessels, nerves, melanocytes, dermal T lymphocytes, and mast cells. Adnexal structures of the skin are located in the dermis, including: hair follicles, different glands, and arrector pili muscles. Skeletal muscles can also be found in the muzzle, forehead, eyelids, and perianal regions (Mauldin and Peters-Kennedy, 2015).

The major functions of hair in animals are protection, thermal insulation, social communication, and sensory perception. Hair follicles, which give rise to the hairs, are divided into primary or

secondary, and simple or compound. Primary hairs, with a large diameter, originate from deep dermis/sub cutis, associated with arrector pili muscles, sebaceous and sweat glands. A simple hair follicle gives rise to one hair and compound follicles to multiple hairs. In animals, growth of the hair is seasonal. The development of hair is divided into different phases: the anagen phase (growth phase), the catagen phase (involution phase), and the telogen phase (resting phase). Sinus hairs (tactile hairs) respond to stimuli and static displacement of the hair (Mauldin and Peters- Kennedy, 2015).

The sebaceous glands comprise holocrine glands and produce sebum, which is needed for maintaining skin and hair. Sebum creates a physical barrier to retain moisture, and acts as chemical barrier against pathogens. Ducts open to the hair follicles or in mucocutaneous junctions directly on the surface of the skin. Sweat glands are both apocrine (epitrichial) glands which are distributed throughout haired skin and eccrine (atrichial) sweat glands which are situated for instance in the footpads. The sweat glands in fur animals probably have a role in scent signaling.

The subcutis (hypodermis, panniculus) is the deepest layer of the skin. It consists of adipose tissue and collagen and elastic fibres, which provide flexibility. It attaches skin to the underlying muscles or bones (Mauldin and Peters-Kennedy, 2015). The structure of the skin is presented in Figure 6.



**Figure 6.** Structure of the skin. <http://healthfavo.com/wp-content/uploads/2013/09/labeled-skin-diagrams.gif>



## 2.2.2 FUNCTIONS OF THE SKIN

Skin protects the body from the external environment. It is also a barrier against potential physical, microbial and chemical damage and it protects against fluid and electrolyte loss. Defense mechanisms of the skin include hair coat, pigment, stratum corneum, chemical barriers and microbial flora. The skin immune system (SIS) provides active protection against pathogens and consists of skin-specific immune-response-associated cells and of humoral factors (Table 1). The immunologic defense mechanisms of the skin contain elements of the innate and adaptive immune systems.

**Table 1.** Cells associated in skin-specific immune response

---

|                                       |  |
|---------------------------------------|--|
| Keratinocytes                         | Non-specific proinflammatory and up-regulating effect: production of cytokines, adhesion molecules, chemotactic factors. |
| Langerhans cells<br>(dendritic cells) | Traps antigens in the epidermis, migrate to regional lymph nodes, present antigen to T cells.                            |
| Dermal perivascular unit cells        | Mast cells, macrophages, tissue dendritic cells, T cells   |
| Skin- homing T memory cells           | Cellular bases to immunologic memory   |

---

Predisposing factors for skin infections include factors that disturb the defence mechanism of the skin e.g. friction, trauma, foreign bodies, ectoparasites, dirt, freezing, burning. The skin also has an important role in temperature regulation and it is a major sensory organ. The skin produces vitamin D<sub>3</sub> and stores water, vitamins, fat, protein, and other nutrients (Mauldin and Peters- Kennedy, 2015).

## 2.2.3 NORMAL FLORA OF THE SKIN

Cutaneous infections develop when the skin's defense mechanisms fail to resist infectious pathogens. The normal microflora of the skin (skin microbiota) consists of mixed populations of symbiotic bacteria, which live and reproduce on the skin. The normal flora prevents pathogenic organisms from colonizing the skin surface, by either competing for nutrients, secreting substances against them, or stimulating the skin's immune response. Some bacteria of the skin may also be opportunistic, thus they can potentially cause disease when the skin is damaged, when the immune system of the animal is compromised, or when a sudden imbalance in the composition of the normal flora develops (Mauldin and Peters-Kennedy, 2015).

## 2.2.4 NORMAL FLORA OF THE SKIN OF FUR ANIMALS

The normal bacterial flora of fur-animal skin is poorly understood in mink and nearly unknown in foxes and Finnraccoons. This raises difficulties in interpreting the bacteriological results obtained from skin inflammations. The *Staphylococcus intermedius* SI-group consists of three closely related coagulase-positive bacterial species including *S. intermedius*, *S. pseudointermedius*, and *S. delphini*. Guardabassi et al. (2012) investigated natural hosts for the SI-group and they found that the Mustelidae are natural hosts for *S. delphini* group A, and foxes (Canidae) for *S. pseudointermedius*. Larsen et al. (2014) investigated the microbiology of healthy skin and wound lesions in mink using MALDI-TOF-MS and PCR. The study revealed that the majority of isolated bacteria (182/254) belonged to the *S. intermedius* group. The *S. delphini* group A, was detected only in 12 samples of 254, and more on healthy skin than in wounds. In contrast, *S. schleiferi*, a Staphylococcal species isolated from recurrent pyodermas of dogs (Frank et al., 2003), was observed significantly more in samples from wounds than from healthy mink skin. The study showed no indications of MRSA (methicillin-resistant *Staphylococcus aureus*) in mink in Denmark (Larsen, 2014). However, Danish researchers later detected that LA-MRSA (live-stock associated MRSA) is highly present in Danish mink. The results showed that MRSA could be isolated from both diagnostic submissions (34%) and from healthy mink at pelting (40%). MRSA was most prevalent in the swabs from the paws and from the pharynx (Larsen et al., 2016). The bacterium was also found in feed, indicating a feed-born introduction (Hansen et al., 2017).

## 2.3 SKIN DISEASES IN FUR ANIMALS

### 2.3.1 INFECTIOUS SKIN DISEASES

#### 2.3.1.1 *Viral diseases with a dermal manifestation*

**Canine distemper** is a worldwide contagious viral disease that causes cutaneous lesions and conjunctivitis in Canidae, Mustelidae and Procynodidae (Pearson and Gorham, 1987). It is caused by Canine Distemper Virus (CDV), a pantropic morbillivirus within the *Paramyxoviridae* family, and the virus particularly infects the epithelial cells and lymphocytes. Distemper is one of the most severe diseases that affects fur animals and causes high morbidity and mortality in naïve populations. The transmission is direct or indirect contact of airborne saliva or nasal exudate. The incubation period is usually 9-14 days but may be longer. The virus replicates in the respiratory tract, proliferates in all lymphoid tissues and becomes viremic, which infects nearly all tissues (Pearsom and Gorham, 1987)

The disease is often subacute in young cubs and kits, and morbidity can affect up to 90% of neonates. In older breeding animals, the morbidity and mortality depend on the virulence of the virus strain (Pearson and Gorham, 1987). It causes immunosuppression by infecting the cells of the immune system. Infected animals presented with squinty swollen eyes and serous oculonasal

discharge, which then turns to thick purulent brown granular exudate that adheres to the skin and covers the eyes and the nostrils. There may be papules or ulcers in the lips (Budd, 1981). Later the mink's feet may become swollen to two or three times their normal size. There have been reports of swollen heads in mink as well (Person and Gorham, 1987). Severe inflammation is detected on the surface of the footpads. Weeks later, if the animal survives, the hyperkeratinisation of the footpads ("hard pad") is seen. Fever, anorexia, vomiting, and diarrhea may occur, diarrhea being more common in infected foxes and Finnraccoons than in mink. If the animal recovers from the first catarrhal phase, it may still be later affected by a nervous form of distemper. The nervous form may also occur without the catarrhal phase. Vocalization and convulsions (screaming fits) and end stage coma are caused by encephalitis (Person and Gorham, 1987).

Gross pathology lesions in the catarrhal phase include serous to mucopurulent discharge around the eyes, nose, and on the footpads. The lungs are congested and mottled and secondary bacterial pneumonia may be detected (Hammer et al., 2012). The spleen is enlarged, the thymus may be atrophied and foul smelling greenish diarrhea may persist. The neurologic form of distemper causes no detectable gross pathological lesions. Microscopically, intracytoplasmic, and/or intranuclear eosinophilic inclusion bodies in the epithelial cells of the bronchi, lungs, and urinary bladder, can be detected. Marked hyperkeratosis and secondary bacterial infections are typical found in the skin. The lung lesions vary from interstitial pneumonia to more suppurative secondary pneumonia, occasionally cyncytial cells are also seen. In intestines, necrotizing gastroenteritis is detected, whilst in the neurologic form, nonsuppurative-demyelinating encephalitis is seen (Dietz et al., 2013).

Farmed fur animals are infected mostly by introduction of diseased fur animals to the farm or by diseased farm dogs (Pearson and Gorham, 1987). Infected wild animals that enter the premises of the fur farm are also a possible source of the distemper infection, as in the most recent epidemic in Denmark (Trebbien et al., 2014). In Finland, a distemper outbreak in fur animals in 1985-1987 was caused by imported animals (personal communication from veterinarians treating fur animals 1985-1987). In 2012, distemper was detected on one Finnish mink farm. The source of infection remained unclear, but the farm had a history of recent importations of mink from North America.

The diagnosis of distemper is performed by classical signs, typical histological lesions and by virus detection using RT-PCR. After the acute disease, antibodies against the virus develop and are detectable in serum. There is no therapy for the disease, but vaccinations and good-practice in biosecurity aids to prevent possible infections.

**Aujeszky's disease** (pseudorabies) is a viral disease, which causes cutaneous lesions, mainly in foxes. Aujeszky's disease is caused by porcine herpesvirus 1 and fur animals are infected by feed when offal from diseased swine is used as a raw material. The virus invades and enters blood circulation by the oral route and spreads to the brains causing a destruction of the nerve cells. Mink and foxes (blue foxes and silver foxes) are susceptible. The characteristic symptoms are anorexia, depression alternating with excitability, superficial respiration, a foamy discharge from the mouth, biting of the tongue, tonic and clonic convulsions, and death (Dietz et al., 2013, Christodoulou et al., 1970, Kimman et al., 1986, Quiroga et al., 1995). Foxes suffer from pruritus ("mad itch") and scratching leads to lesions of the skin that are mainly located in the head region (Lyubashenko et al., 1958). The pruritus and self-mutilation are however not common in mink. Diagnosis is based on virus isolation from brain tissue samples or by serology. There are no data about farmed raccoon dogs and Aujeszky disease, and there has been no detection of antibodies against porcine herpes virus 1 reported in wild raccoon dogs (Neagari et al., 1998, Yang et al., 2014)

**Plasmacytosis** (Aleutian disease) is one of the most important viral diseases found in mink. It is a persistent infection caused by Aleutian mink disease virus (AMDV). The AMDV virus is a member of the Amdovirus genus in the family *Parvoviridae*. AMDV infection decreases immunity and predisposes animals to other diseases. There is no effective vaccination against it, but the disease is controlled with continual testing of animals. The disease spreads easily between animals and farms, causing lung lesions in neonatal kits. In adults, it causes immune-complex glomerulonephritis and heavy infiltration with plasma cells in many organs (Bloom et al., 1994). Aleutian disease does not cause direct lesions in the skin but may cause poorer pelt quality, so called “sprinklers” in chronic forms of the disease (Hammer et al., 2012). Aleutian disease is diagnosed by detecting high levels of specific antibodies in Enzyme-linked immunosorbent assay (ELISA) or by virus detection in polymerized chain reaction (PCR) (Knuuttila et al., 2009).

Young mink kits from birth to weaning may have a syndrome known by many names: sticky kits, **greasy kits, wet kits or dermal adenitis, and pre-weaning diarrhea** (Clausen and Dietz, 2004). It causes outbreaks and, in most severe cases, high morbidity and mortality. The signs include greasy exudate on the skin surface of especially the neck, claws, and tail. Mink kits have cervical apocrine glands in the neck region that seem to disappear after the kits are four weeks old. These glands secrete pheromones, which initiate and enhance maternal instincts and behavior in females (Affolter and Gorham 2001). In addition, red swollen perianal region and yellowish diarrhea are often seen, the latter of which leads to dehydration. The disease is probably multifactorial and the etiology is still unclear. The common opinion is that there may be a combination of different predisposing factors, including management (feed and feeding of females), environmental (hygiene), and infectious agents. An astrovirus has been detected in diseased kits and may have an association with the disease (Englund et al., 2002). Caliciviruses (Guo et al., 2001), coronaviruses, and rotaviruses (Jørgensen et al., 1995) have been detected in diseased kittens as well. Bacterial pathogens, *Staphylococcus sp.* and *Escherichia coli*, are commonly found (Clausen and Dietz, 2004).

There is no published data about other viral diseases among fur animals with skin manifestation. However, there are probably more viruses, which may infect the skin structures or cause changes in the skin.

### **2.3.1.2 Bacterial diseases with a skin manifestation**

Bacterial skin inflammations of animals are mostly suppurative pyodermas. Predisposing factors, such as ectoparasites or trauma, usually proceed and cause superficial pyoderma (Mauldin and Peters-Kennedy, 2015). Bacterial skin inflammations mostly occur in individuals, are seldom contagious, and usually do not cause problems for the entire farm population. Primary bacterial skin inflammations are rare in fur animals. They are more manifested as secondary bacterial infections as consequences of traumas such as biting wounds.

**Malignant edema** is a bacterial infection caused by *Clostridia* species and is referred to as "gas gangrene". These infections usually result from a skin wound that was covered with dirt and exudate, which creates an anaerobic environment that is beneficial to *Clostridia* growth. The growth of *Clostridia* bacteria leads to tissue destruction in the skin, connective tissue, and muscle. Toxins produced by the bacteria are absorbed into the blood and can cause death. Local lesions are often dark brown or black (Affolter and Gorham, 2001).

**Pododermatitis** is an important problem in mink in North America. It appears as acute, severe ulcerative dermatitis of the footpads or as a more chronic form with hyperkeratosis and purulent dermatitis. It seems to be endemic in some farms. The etiology is somewhat unclear, although mechanical pressure associated with increasing weight of breeder animals can be one of the predisposing factors. The recent results of Canadian studies of *A. phocae* as causative agent in pododermatitis are presented in the discussion.

### **2.3.1.3 Fungal diseases with a skin manifestation**

Relatively high body temperature resists fungal infections of the skin (Mauldin and Peters- Kennedy, 2015). Some fungi are pathogens but most are opportunistic and cause infection in immunocompromised animals (Mauldin and Peters-Kennedy, 2015). Fungal infections typically cause round lesions with patches of hair loss and dry, scaly skin that occasionally is red or crusty. All fur animals are susceptible to **ringworm** and is mostly caused by *Trichophyton* or *Microsporum* species. It is a rare disease among fur animals in the Nordic countries but may be more common in countries with warm and moist atmospheres. Fungal diseases may have economic impact when they affect animals close to pelting time and therefore all animals need to be treated. Usually the infection is spread to the farm by infected cats, especially when they are able to get into contact with the bedding materials. The diagnosis is made by direct microscopy or skin biopsy, and special stains (GMS, PAS) may be used. *Microsporum canis* usually causes the ringworm in mink (Affolter and Gorham, 2001). However, *Trichophyton equinum* was detected in two mink farms in Canada with outbreaks of dermatophytosis (Overy et al., 2015). In 2015, Danish researchers described cutaneous candidiasis for the first time in farmed mink. The diseased mink had local or general alopecia, erythema, erosions, and ulcers in the skin. Some cases had crust formation around the nose and on the paws (Hammer et al., 2015).

### **2.3.1.4 Parasitic diseases with a dermal manifestation**

Parasitic pathogens of the skin are called ectoparasites and include mites, ticks, lice, fleas, and flies. Ectoparasites may damage the skin and fur and predispose skin to secondary bacterial infections (Mauldin and Peters-Kennedy, 2015). Mites cause **sarcoptic mange** (*Sarcoptes scabiei*) in foxes, but it is very rarely seen in mink. There is no published report of farmed Finnraccoons and *S. scabiei* infection, but in the author's experience it has been isolated in samples taken from Finnraccoons with typical clinical signs and it has also been detected in wild raccoon dogs (Takahashi et al., 2001). The mites are transmitted by direct contact or indirectly by contaminated clothing or tools used to handle the animals. The disease spreads very easily when the animals are separated or are mated because handling of the animals during these times is intensive. It causes severe pruritus and discomfort to the animals. Lesions of moist crusty inflammation and alopecia are detected especially in the head and extremities. The diagnosis is established by anamnestic information and by skin scrapings or skin biopsy.

**Otodectic mange** is caused by *Otodectis cyanotis* and it is seen in foxes (Hanson, 1932). *O. cyanotis* inhabits the external ear and causes pruritus, head shaking and scratching, and aural haematoma. The exudate is brown and becomes crusty. If secondary bacterial inflammation is

present, there may be pus formation and the inflammation may spread to the skin of the head. Otodectic mange is easily diagnosed by detecting the mites microscopically in smear samples taken from the ear. Diseased feral or domestic cats or wildlife entering the farm often causes both *S. scabiei* and *O. cyanotis* infestation in farms (Dietz et al., 2013).

Lice are mostly blood-sucking, host-specific parasites and cause pediculosis in many species. Lice are seen mostly in mink kits and they cause blood loss rather than detectable skin lesions.

Some helminths (endoparasites) are known to cause cutaneous lesions due to migration of helminth larvae. Ancylostoma or Uncinaria larvae cause hookworm dermatitis in dogs. They cause lesions in footpads that became soft and a keratinized portion may even separate and lead to secondary bacterial inflammation. These larvae have also been detected in wild foxes (Petavy and Deblock, 1979) and wild raccoon dog (Shimalov and Shimalov, 2002). However, contact with the feces is uncommon in farmed fur animals because they are housed in wire cages.

The protozoan *Leishmania* can cause cutaneous lesions. However, in the high latitudes of Finland, sand flies that are required vector for *Leishmania* are not found.

### **2.3.2 PHYSICAL AND CHEMICAL INJURY TO THE SKIN**

Skin is directly exposed to the environment and vulnerable to possible physical and chemical injuries. Physical factors include trauma, friction, pressure, vibration, electricity, temperature extremes, moisture, and sunlight. Chemical compounds can cause skin lesions by irritation (irritation contact dermatitis) or by poisoning (Mauldin and Peters-Kennedy, 2015).

#### **2.3.2.1 Traumatic skin diseases**

*Staphylococcus spp.* and *Streptococcus spp.* are normally present on the skin of the fur animals. However, when the skin or mucosa is weakened these bacteria can cause inflammation. Sharp objects in the cage structures such as sharp wires may cause puncture wounds. Moreover, the sharp stalks of hay or straw as a bedding material for mink can cause lesions in the mouth and in the head region. In addition, unhygienic vaccine routines have caused abscesses in vaccination sites. These should not, however, be confused with vaccination granulomas, which are granulomatous nodules in the panniculus due to the irritation caused by the adjuvant of the vaccine. Recently, *A. phocae* has been isolated from postvaccinational wounds in mink on FENP affected farms (Molenaar et al., 2016).

Bite wounds are mostly seen in young individuals that are housed in groups as a part of their hierarchy development. Bite wounds may cause up to 10% mortality among mink kits (Hansen et al., 2007). Breeder animals are caged individually and bite marks are rare, except in mink in the mating period, when bite marks can be seen in both females and males. In females, the bite marks are usually situated on the neck.

According to a Danish study (Jespersen et al., 2016) wounds are located in young kits (age of 1-2 months) in the front parts of the body and in the head, and later in the autumn in older kits (5-6 months) and breeder animals in the posterior parts of the body and the tail. The same study also reported that females are more prone to having wounds than males, whereas males are more prone to having ear wounds. Furthermore, a difference was observed in occurrence of ear and tail base wounds between the different color types, with black mink having more ear wounds than other color types.

Some individuals can in stressful situations also react by self-mutilation, i.e. by biting their own fur and/or skin (psychogenic injury) (Affolter and Gorham, 2001).

### **2.3.2.2 Callus**

Prolonged repeated or constant pressure or friction may cause lesions in the skin. Callus occurs when pressure or friction is applied to a localized area of the skin. Response of the skin to repeated friction is epidermal proliferation and hyperkeratosis (Mauldin and Peters-Kennedy, 2015). This is often seen in heavy breeder male mink in the plantar surface of the hind feet or in the hocks. Callus may split and become secondarily infected. Jespersen et al. (2015) detected hyperkeratosis, crusting and alopecia mostly in plantar metatarsal skin when they examined lesions in mink feet in Denmark. Histologically, the lesions presented orthokeratosis and hyperkeratosis in addition to granulomatous to pyogranulomatous dermatitis with trichogranulomas. These kinds of findings are characteristic of pressure induced lesions such as callosities (Mauldin and Peters-Kennedy, 2015). *Staphylococcus spp.* was the most frequently isolated microorganism from these lesions. The study also showed that the foot lesions were detected more often in males, and lighter color phases were affected more than dark color types (Jespersen et al., 2015).

### **2.3.2.3 Temperature and sunlight**

Extreme temperatures can cause lesions on the skin, e.g. from frostbite and burns (Mauldin and Peters-Kennedy, 2015). However, fur animals are well adapted to cold climate and cope well in frost. Unsuitable bottom mesh wires can in some circumstances cause freezing of the footpads. Fur animals are also protected from direct sunlight and heat in the shelter buildings.

## **2.3.3 NUTRITIONAL IMBALANCES THAT MANIFEST IN ALTERED SKIN CONDITION AND APPEARANCE**

Skin conditions often respond to most deficiencies of essential nutrients or in some metabolic disturbances. The cause of deficiencies can be due to the dietary lack, malabsorption, antimetabolites or body's failure to absorb or utilize nutrients. Most of the Finnish fur animals are fed a commercial feed that is formulated and mixed in feed centres, only a few farmers produce feed by themselves. The composition of the feed is based on research results and recommendations given by FFBA.

Vitamin imbalances cause cutaneous lesions, as vitamins A, E and the B complex are essential for the health of the skin. Vitamin A has a role in the maintenance of differentiated epithelia (Juokslahti, 1989). Excess of vitamin A has been reported to cause cutaneous lesions in foxes (Helgebostad, 1955). A deficiency of vitamin B2 (riboflavin) can cause dermatitis in foxes (especially blue foxes), abnormal shedding of hair, opaque eye lenses and lacrimation (Juokslahti, 1989). A deficiency of vitamin B6 (pyridoxine) deficiency in mink kits has been shown to cause a brown exudate around the nose, excessive lacrimation and difficulty in opening the eyes, swelling and puffiness around the nose and the face region (Bowman et al., 1968). A vitamin B12 (cyanocobalamin) deficiency manifests as a rough fur coat and dermatitis (Juokslahti,

1989). Deficiency in biotin (B7), occurs when fur animals are fed purified diets without biotin supplement or when high levels of uncooked avian egg-white and oviduct tissue, are used as raw ingredients, since they are rich in avidin. This deficiency produces changes in the skin and fur (grey underfur), an exudate around the eyes (“spectacle eye”), nose and mouth and the encrustation of the paws (Juokslahti, 1989, Rouvinen-Watt and Clausen, 1991). Vitamin E deficiency leads to steatitis, “yellowfat disease,” which involves subcutaneous fat and may clinically manifest in the skin. Vitamin E functions together with selenium as an antioxidant and protects the cell membrane phospholipids from oxidative damage. Yellow fat disease is seen in healthy rapidly growing mink kits if diet has high amount polysaturated fatty acids and/or rancid fatty quality. The first signs are paralysis of hind limbs and high mortality. Necropsy reveals subcutaneous oedema and brownish yellow discoloration of the fat. Myopathy may be seen in skeletal and hearth muscle (Rouvinen-Watt and Clausen, 1991).

Trace mineral deficiencies of iron, iodine, cobalt, copper and zinc may influence the condition of the skin. Zinc deficiency can cause lesions in the integument in many species, most typical lesions being hyperkeratosis and parakeratosis. Iron deficiency in mink cause a rough pelage and failure of color pigment development in the underfur; “cotton fur” (achromotricia) (Rouvinen-Watt and Clausen, 1991).

### **2.3.4 CONGENITAL AND HEREDITARY DISEASES OF THE SKIN**

Congenital diseases are present at birth. They are either hereditary or acquired during gestation. Environmental factors such as infections, nutritional imbalances and toxins can cause abnormalities of the skin and the hair.

#### **2.3.4.1 Tyrosinaemia**

Tyrosinaemia is an enzyme disorder where the body cannot effectively break down the amino acid tyrosine. Tyrosinaemia occurs only in black standard type mink as an autosomal recessive hereditary disease. This enzyme defect increases serum tyrosine levels gradually after birth, and the peak is seen when the kits start to eat solid feed. The body tries to excrete tyrosine through tears, urine and sweat, but renal and liver tissues cannot entirely eliminate the excess tyrosine (Christensen 1979).

The signs resemble the signs that occur in distemper and hence tyrosemia is also referred to as “false distemper”. The first signs appear at the age of six weeks; watery eyes and eyelids firmly stuck together. Crusts develop around the eyes and the nose and sometimes around the lips. A greyish exudate is seen dorsally on the toes. Especially in male mink the ventral part is wet due to the urine leakage. Kits usually die in few days. There are reports of two other types of this disease, an intermediate type in which the signs are seen in kits at the age of 3 months and a milder late type, in which the kits are affected at about 6 months of age (Christensen et al., 1986).

Histopathology shows acantholysis and epidermal necrosis with secondary neutrophilia, micropustules often associated with crystal granules of tyrosine and erosion and ulceration of the skin. In kidneys and liver, epithelial necrosis is seen. Nowadays the disease is very rare due the selective breeding (Christensen et al., 1986).



#### **2.3.4.2 The Ehlers-Danlos syndrome**

The connective tissue consists of collagen, elastic fibres, and ground substance composed of glycoproteins and proteoglycans. Defects in these skin molecules result in structural and functional disorders in the connective tissues. Hereditary collagen dysplasia, Ehlers-Danlos syndrome (dermatosparaxis, cutaneous asthenia, cutis hyperplastica) have been reported in humans, cattle, sheep, horses, dogs, cats, rabbits and mink. The skin of affected individuals is fragile, hyperextensible and loose. The skin is easily damaged due to the fragility and wounds are found especially in young mink, which are housed together. The hyperextensibility is most clearly seen in the skin of the head, legs and neck. In mink the disease is genetically transmitted as an autosomal dominant trait (Hegreberg et al. 1977, Counts et al. 1997).

#### **2.3.4.3 Keke-syndrome of silver foxes**

Keke-syndrome has been reported in silver foxes and genetic background of the disease is suspected. It causes dry, short, dull, curly fur and a shortening of the under wool. Normal hair color is disturbed as is the structure of the hair follicles. The defect impairs the development of hair follicles and the thickness of the skin. The skin is thinner and the connective tissue consists of shortened collagen fibres. Diseased animals may also have mild hepatic lipidosis and fibrosis and accumulation of copper in the liver. Eosinophilic enteritis is detected in the intestines (Ingo, et al., 1988). The affected silver foxes were detected first time at 1980s. The syndrome was named as “Keke” after a curly haired famous Finnish formula-1 driver Keijo “Keke” Rosberg at that time. In the other hand, the furs of Keke-foxes look like a formula had driven all over them.

### **2.3.5 ENDOCRINE DISEASES OF THE SKIN**

Lesions caused by endocrine disorders can occur in any species but they are most common in dogs (Mauldin and Peters-Kennedy, 2015). They are mostly seen sporadically in individual animals and very seldom as a herd problem. Clinical signs often include dry, coarse, brittle, dull, easily epilated hair coat that fails to regrow after clipping, hypotrichosis and hyperpigmentation and often bilaterally manifested alopecia. Secondary pyoderma or seborrhea may be seen. Histopathological lesions include orthokeratotic hyperkeratosis, follicular keratosis, dilatation of follicles, increased number of telogen follicles, variably increased thricolemmal keratinization of follicles, hair follicle atrophy, absence of hair shafts, and also epidermal hyperpigmentation is seen. These lesions are typically detected in endocrine dermatoses but are not pathognomonic for a specific endocrinopathy. Common endocrinopathies in dogs include hypothyroidism, hyperadenocorticism (Cushing disease), hyposomatotropinism and hyperestrogenism (Mauldin and Peters- Kennedy, 2015). There are few research studies that have targeted endocrinopathies of fur animals.

### **2.3.6 OCULAR DISEASES OF BLUE FOXES**

Eye infections in the blue fox are clearly a seasonal health problem and seem to be associated with cold weather. The experience of fur farmers and veterinarians and the results of the WelFur visits on the farms indicate that incidence of an eye infection is highest during pelting time, i.e. November–December, and during the breeding season in January–February (Ahola et al., 2014). In clinical and post mortem examinations signs of deformations of the eye lids are detected. Entropion, where the eye lids are inverted inside, may be the most common finding, but a reverse situation, ectropion, and ectopic cilia have also been detected. All these malformations cause irritation to the conjunctiva and cornea which may lead to the erosions and proceed to secondary viral and bacterial inflammations. It has been speculated that extremely loose skin, skin folds, excessive subcutaneous fat around eyes and massive, thick hair coat of blue foxes may aggravate an initial entropion. In addition, sudden weight loss could also predispose to an eye infection. There also seems to be a clear hereditary predisposing factor to eye infections and eye health. Genetic selection has had a positive effect in eye health in Finnish blue foxes (Kempe and Stranden, 2015).

## **2.4 FUR ANIMAL EPIDEMIC NECROTIC PYODERMA, FENP**

Fur Animal Epidemic Necrotic pyoderma FENP is described in the results of this thesis. Here is a description of previous outbreaks of similar signs and research results of previous studies.

### **2.4.1 PREVIOUS OUTBREAKS OF A SIMILAR SYNDROME**

Canadian fur farmers reported 1996 a new kind of skin disease in mink. The investigations made concerning the disease are reported in a thesis by Caroline Bröjer (2000). Lesions were mainly detected in feet, and only occasionally in the facial skin, hence the disease was called pododermatitis (“skin inflammation of the feet”). The farmers linked the onset of the signs with the start of the use of the seal offal as a raw ingredient in mink feed formulations. There is also evidence that in Utah, in the USA, similar lesions in mink fed with seal meat as an ingredient had occurred as early as in the beginning of 1970`s. According to the the Canadian study, the lesions seen in mink feet varied from alopecia and swollen footpads with mild hyperkeratosis and thick skin folds around the toes to more acute lesions with ulceration and crust formation. Lesions were also detected in junctions of furred skin and footpads, and sometimes around nailbeds. The author(s) also reported that lesions were also detected in the mucocutaneous junctions of the head around the nose pad or the corner of the eye. In internal organs of diseased mink splenomegaly and occasionally local lymphadenopathies were detected. The lungs were mottled and congested in some cases. Histologically, the findings were orthoceratotic hyperkeratosis and follicular and dermal inflammation. Cases with partial or complete ulceration contained neutrophilic inflammation with gram positive cocci and microabscesses in intact areas of skin. Mural folliculitis or perifolliculitis with perifollicular lymphocytosis and occasionally furunculosis were also detected. Lesions in internal organs were generally non-specific. In microbiological studies

*S. intermedius* (today bacteria belonging to *S. intermedius* group) was the most common bacterium in samples of affected skin. In addition, non-haemolytic and  $\beta$ -haemolytic *Streptococcus* and *Staphylococcus epidermidis* were isolated. No viral pathogens were detected in these studies.

Epidemiologic studies revealed that pododermatitis was an emerging contagious disease among Canadian mink (Bröjer 2000). They showed a clear association between the feeding seal meat and the presence of pododermatitis on the farms. One affected farm in the survey had not used seal meat in the feed, but the farmer reported that signs were detected after he had introduced animals from an affected farm to his own farm. The signs were further detected in offspring born on affected farms after the use of the seal meat had been discontinued. Beside seal meat no difference between occurrence of pododermatitis and other management procedures such as the prophylactic use of antibiotics, vaccination routines, or bedding material used in nests were detected. Neither had the color phase of mink nor other diseases on the farm an association with pododermatitis. However, pododermatitis was seen more in males than females and mostly in the hind feet. The researchers speculated that friction caused by heavier bodyweight could have acted as a predisposing factor (Bröjer, 2000).

The conclusion of the Canadian research on pododermatitis in mink was that the disease is caused by an infectious agent with secondary bacteriologic pyoderma. The primary infectious agent, however, remained unidentified. A possible association of onset of disease and use of seal meat as feed was seen. However, juveniles that had not been fed with seal meat on affected farms developed signs, so it was concluded that even the seal meat may have been an initial contributing factor, it was no longer necessary for the propagation of the agent causing the disease (Bröjer, 2000).

Several mink had been submitted for necropsy in Spain during 2006-2008 period due to ulcers with scabs and debris in the footpads. In contrast to the Canadian mink, the lesions were more often found in females than in males, and the mean age of diseased mink was more than two years old. The lesions consisted of hyperkeratosis, necrosis, crusting and abscesses and they were detected on the palmar and plantar surfaces of metacarpal and metatarsal surfaces. Occasionally lesions were also detected in face, mainly around the nose and eyes. Hyperkeratosis and folliculitis were microscopically determined and ulcers with suppurative inflammatory response were detected. Bacteriological studies revealed the presence of *Staphylococcus intermedius*. No viral components were detected (Fernández-Antonio et al., 2008).

Personal communications with veterinarians of other fur farming countries confirm that similar lesions have been found in Denmark, the Netherlands, Iceland, Poland, Greece and some individual cases in Norway and Sweden.

#### **2.4.2 EPIDEMIOLOGIC CHARACTERISTICS**

The study by Bröjer revealed a correlation between feeding seal meat and the occurrence of signs of the syndrome in Canada (Bröjer, 2000). However, the disease seemed to continue to spread after the utilization of seal meat was finished. The disease was also detected on farms that had not used seal meat but had a history of purchasing animals from an affected farm, which had used seal offal. In addition, the detection of signs in countries which do not use seal meat as a raw feed material also indicates that the seal meat is not an obligatory prerequisite to an outbreak and subsequent spread of the disease.

No connection between different bedding materials, color phases, use of vaccination or medication, or other diseases and the onset of symptoms was reported in the Canadian survey. The only difference was in the sex of the animals; the symptoms were more predominant in males than in females and mostly in the hind feet. It was speculated that it could be due to the fact that males are heavier than females and there is more weight on the footpads that come into contact with the flooring of the cages and this could act as a predisposing factor. Interestingly the lesions reported in Spain were predominantly found in females and both in front and hind limbs. The lesions in Spain and Canada were occasionally detected in the head of the mink, too (Bröjer, 2000, Fernández-Antonio et al., 2008).

### 2.4.3 TENTATIVE ETIOLOGY

The link seen between onset of symptoms and feeding mink with by-products of seal in Canada in 1996 and in the USA in the 1970s indicated that the source of initial contributing factor of disease may have been in seal meat. The disease, however, continued spreading between farms and animals after the use of seal meat had discontinued and outbreaks have even occurred in countries where seal meat has not been used as a raw feed material, which indicates that the causative agent is presently spreading between fur animals and not via an agent in their diet.

## 2.5 CHARACTERISTICS OF *ARCANOBACTERIUM PHOCAE*

### 2.5.1 TAXONOMY

*Arcanobacterium phocae* belongs to the genus *Arcanobacterium* in the *Actinomycetaceae* family and was first described by Collins et al. in 1982. This genus is currently under taxonomic revision. The Genus *Arcanobacterium* comprises the species *A. haemolyticum*, *A. hippocoleae*, *A. pluranimalium*, *A. phocae* (Yassin et al., 2011) and *A. canis* (Hijazin et al., 2012) and *A. phocisimile* (Hijazin et al., 2013). A new member of the genus was introduced in 2015 (Sammra et al., 2015): *A. pinnipediorum* sp. nov. Five previous members of the genus *Arcanobacterium* have been proposed to form a new genus, *Trueperella*: *T. bernardiae*, *T. pyogenes*, *T. bialowiezense*, *T. bonasi*, and *T. abortisuis* (Yassin et al., 2011).

The knowledge about the natural habitat of *Arcanobacterium* spp. remains scant. It has been assumed that these organisms are present as a part of the normal flora and are potentially opportunistic pathogens on the mucous membranes of terrestrial and marine mammals. They have been recovered from abscesses and systemic inflammations of various organs such as the respiratory, digestive, and reproductive tracts (Ramos et al., 1997). *A. phocae* was isolated from the tissues from gray seals (*Halichoerus grypus*) and common seals (*Phoca vitulina*) on the Scottish coast in 1997 (Ramos et al., 1997). Johnson et al. (2003) reported *A. phocae* in samples gathered between 1994 and 2000; *A. phocae* isolates were recovered from tissue sites with abnormal discharge or evidence of inflammation of 141 marine mammals stranded along the Californian coast. It was cultured from 66 California sea lions (*Zalophus californianus*), 50 Pacific harbor seals (*Phoca vitulina richardii*), 19 northern elephant seals (*Mirounga*

*angustirostris*), 5 southern sea otters (*Enhydra lutris nereis*), and one common dolphin (*Delphinus delphis*).

## **2.5.2 MORPHOLOGY AND GROWTH CONDITIONS**

Bacteria from the genus *Arcanobacterium* are gram positive, 0.3-0.8 x 1-5 µm in size, non-spore-forming, non-motile pleomorphic, short rods or coccobacilli, which occasionally morph to V or T shapes (Ülbeği 2010). They are facultative anaerobic bacteria and at 37° C have an incubation period that ranges between 24-48h in the standard microaerobic conditions that are used in culturing. Their growth is enhanced with a CO<sub>2</sub>-enriched atmosphere and on agar containing blood or serum. Bacteria of the genus *Arcanobacterium* are inactivated by treating for 15 min at 60 °C (Collins et al., 1982). *A. phocae* has been found to be susceptible to all tested antibiotics including aminoglycosides, β-lactams, bacteriostatic and bactericidal antibiotics, fluoroquinolones, macrolides, rifamycins, and polyketides (Johnson et al., 2003).

## **2.5.3 DIAGNOSTICS**

### **2.5.3.1 Detection by culturing**

*A. phocae* grows relatively slowly on blood agar and it forms translucent small pinpoint-like colonies with a strong beta-haemolytic zone around them. *A. phocae* is gram positive, catalase-positive, and oxidase-negative. A positive CAMP reaction (synergistic hemolysis) to *Rhodococcus equi*, *Psychrobacter phenylpyruvicus*, and *Streptococcus agalactiae* is typical and hemolysis is also seen in the reverse CAMP reaction with *Staphylococcus aureus* (Hijazin, 2012).

### **2.5.3.2 Molecular detection**

Slow growth with very translucent and small colonies of *A. phocae* mostly in mixed cultures suggests that *A. phocae* may be overgrown by other bacteria and may be overlooked in cultured samples. Thus, a PCR-method is used enhancing the detection of *A. phocae* from affected tissue samples. The characterization of bacteria by using 16S rRNA gene amplification and sequencing is a standard method for identification of bacteria species, genera and families. The PCR targets the 16S-23S RNA intergenic region in the bacterial genome. This region is known to be well- suited to differentiate bacterial species.

### **2.5.3.3 MALDI-TOF mass spectrometry**

Matrix-assisted laser desorption ionization–time of flight mass spectrometry (MALDI-TOF MS) has become more popular in recent years in medical microbial diagnostics for its rapid, accurate and moderately inexpensive bacterial identification modality. It is used mostly at the genus or species level. MALDI-TOF spectra are used for the identification of microorganisms such as bacteria or fungi. A colony of the microbe is smeared directly on the

sample target and overlaid with a matrix. The mass spectra generated are analysed by software and compared with known standard profiles. Hijazin (2012) evaluated MALDI-TOF MS for species identification of genus *Arcanobacterium* and the results showed discriminating power comparable with tests at the DNA level. It has also been used in Evira (the Finnish Food Safety Authority) to detect *A. phocae* in cultures of fur animal samples submitted from clinical cases.

#### 2.5.4 VIRULENCE FACTORS

Üllbegi (2010) presented the phocaelysin encoding gene *phl*, a gene encoding a pore forming toxin in *A. phocae*. However, this toxin has not yet been described. The *Phl* gene is comparable to the pyolysin encoding gene of *T. pyogenes*. The pathogenesis of *T. pyogenes* is known to be based on the production of the hemolytic exotoxin, pyolysin (PLO). PLO is a member of the cholesterol-binding, pore-forming family of toxins (PFT) and it has cytolytic effects. It has also been demonstrated to induce dermonecrotic and lethal effects in laboratory animals (Billington et al., 2001). Pore-forming toxins produced by bacteria cause disruption of epithelial barrier function and evasion of host immune response, both of which contribute to bacterial growth and spreading. Many bacteria are presumed to have PFT as a virulence factor based on their sequence data or actual properties (Los et al., 2013). *Arcanobacterium haemolyticum*, closely related to *A. phocae*, expresses phospholipase D (PLD), which promotes bacterial pathogenesis through the action on host cell membranes, and it enhances bacterial adhesion and promotes host cell necrosis following invasion (Lucas et al., 2010).

Dobinsky et al. (1999) hypothesized that *A. haemolyticum* might have a synergistic pathologic effect with other bacteria. *A. phocae* is predominantly found as a part of mixed bacterial infections, usually together with bacteria of the *Streptococcus spp.* and *Staphylococcus spp.* groups. It is theoretically possible that *A. phocae* may also have synergy with other microorganisms.

#### 2.5.5 DISEASES CAUSED BY ARCANOBACTERIA

*A. phocae* is usually isolated in specimens taken from marine mammals, from infected skin lesions such as superficial abscesses and wounds, which often occur as a result of bites, bullet wounds, or fishing hooks and other traumatic skin injuries. A break in skin tissue seems to be a predisposing factor to the inflammation. However, in some cases with deep-seated and systematic inflammations, osteomyelitis and brain abscesses have also been documented.

*A. phocae* is often found in a mixed inflammation, with  $\beta$ -hemolytic *Streptococcus sp.* and *E. coli*, *Enterococcus spp.*, *Proteus spp.*, *Staphylococcus aureus*, *Streptococcus viridans*, *Pseudomonas spp.*, *Corynebacterium spp.*, and *Klebsiella spp.* The *A. phocae* bacterium is also detected from nasal, fecal, and vaginal swabs taken from wild-caught healthy harbor seals. This occurrence could indicate that *A. phocae* is probably an opportunistic pathogen that causes infection in animals with wounds or other pre-existing disease. The role and pathogenesis of *A. phocae* in marine mammals is still under investigation (Johnson et al., 2003).

The most well-known bacterium that belongs to the genus *Arcanobacterium* is *A. haemolyticum*. It was first described in 1946 as a pathogenic agent that causes pharyngitis and cutaneous infections in humans (Almuzara et al., 1995). *A. haemolyticum* is usually detected in patients with pharyngitis, but it has been occasionally isolated in samples taken from patients

with sepsis, osteomyelitis, septic arthritis, cellulitis, wound infections, venous ulcers, skin abscesses, peritonsillar abscesses, cavitary pneumonia, pyothorax, paronychia, omphalitis, otitis media, endocarditis, sinusitis, orbital cellulitis, canaliculitis, meningitis, brain abscesses, diabetic soft tissue infections, and spontaneous bacterial peritonitis. *A. haemolyticum* infection has rarely been reported in animals, and its pathogenicity in animals has not been well documented. Humans are believed to be its main environmental reservoir (Almuzara et al., 1995).

*Arcanobacterium hippocoleae* was isolated from the vagina of a horse (Hoyles et al., 2002) and from a placentitis of a mare (Bemis et al., 2008). *Arcanobacterium pluranimalium* was first isolated from a harbor porpoise and a fallow deer (Lawson et al., 2001), but in the U.K. it has been isolated in various ovine specimens, mostly abortion tissues, and also in semen, abscesses, viscera, navel and peritonitis. It has also been isolated from the milk of a cow in a mastitis case (Foster et al., 2011). *A. canis* is one of the youngest members of genus *Arcanobacterium* and it has been found in the otitis externa of the dog (Hijazin et al., 2011). *A. phocisimile* has been isolated from fecal and vaginal samples of harbor seals (Hijazin et al., 2013). *A. pinnipediorum* sp. nov. is isolated from harbour seals (Sammra et al., 2015).

### 3 AIMS OF THE STUDY

The aims of this dissertation were as follows:

1. To describe the clinical signs, gross and histopathological lesions and characterize possible causative pathogens of fur animal epidemic necrotic pyoderma FENP in mink, foxes, and Finnraccoons (I).
2. Confirm the role of *A. phocae* and the novel *Streptococcus sp.* isolated in study I as a cause of FENP.
3. To characterize the occurrence and geographical distribution of FENP in Finland (III).
4. To identify risk factors for the disease (III).



## 4 MATERIALS AND METHODS

### 4.1 SAMPLING ANIMALS FOR DESCRIPTION OF CLINICAL SIGNS AND FOR PATHOLOGICAL AND MICROBIOLOGICAL STUDIES (I)

Sampling of the animals for the study was performed during the pelting time between November 2010 and January 2011. Fur animals were submitted for a complete necropsy (gross pathology and histopathology) and microbiological examinations. The animals (61) were sampled from 10 farms with a history of typical signs of FENP (case farms) and 34 animals from three farms with no previous signs of FENP (control farms). Additionally, four clinically healthy minks from two affected farms (control animal from affected farm (4)) were sampled. The animals were submitted without pelting because the lesions were in the skin, which diminished the number of healthy control animals. The sampled animals are presented in table 2. In a covering note, the farmers and veterinarians were asked to describe the signs and symptoms of the disease detected on the farm to obtain a clinical description of the disease.

**Table 2.** Number (n) and gender of the animals necropsied in study I.

| <b>Farms (n)</b>    | <b>Animals (n)</b> | <b>Gender<br/>female (n)/male (n)</b> |
|---------------------|--------------------|---------------------------------------|
| <b>MINK</b>         |                    |                                       |
| Case farm (2)       | 21                 | 9/12                                  |
| Control farm (1)    | 11                 | 0/11                                  |
| <b>FOXES</b>        |                    |                                       |
| Case farm (3)       | 19                 | 16/3                                  |
| Control farm (1)    | 12                 | 0/12                                  |
| <b>FINNRACCOONS</b> |                    |                                       |
| Case farm (5)       | 21                 | 13/8                                  |
| Control farm (1)    | 11                 | 7/4                                   |

Case farm is a farm affected with FENP, Control farm is a farm with no previous signs of FENP. In addition to animals listed in table 2, two case farms sent 4 clinically healthy minks for necropsy.

## 4.2 EXPERIMENTAL INFECTION STUDY (II)

### 4.2.1 EXPERIMENTAL ANIMALS

An experimental infection was performed in 2013 on one-hundred black, Aleutian disease seronegative, one-year old female mink (*Neovison vison*). The mink originated from a Finnish production farm with no previous history of the signs of FENP. The two studies (I and III) showed that the black color-type was a risk for developing FENP with equal risk for males and females. The mink were transported to the experimental farm, where they were housed and infected, after an adaption period. The animals were blood sampled during the study and finally submitted for necropsy. The procedures carried out at experimental infection are described in detail in the following chapter (4.2.4). The experiment lasted for 11 weeks. The mink were handled and monitored by an experienced mink farmer and fed with commercial mink feed and a nipple-drinking system was in use. The animals were euthanized by using carbon monoxide.



**Figure 7.** Mink were individually marked and caged in the experimental infection study II. Photo Kirsi Aaltonen.

### 4.2.2 THE FACILITIES USED IN STUDY II

The experimental study II was performed on an empty mink farm. The shed had been empty for 14 months and was mechanically cleaned before the trial. The farm had no history of the signs of FENP.



**Figure 8.** The shed used in housing of the experimental animals resembles housing conditions on commercial fur farms. Photo Kirsi Aaltonen.

## **4.2.3 THE BACTERIA AND TISSUE SUSPENSION USED IN EXPERIMENTAL INFECTION (II)**

### **4.2.3.1 Bacterial Inocula**

The inocula used in the experimental infection (study II) were prepared from cultures of *A. phocae* and the novel *Streptococcus* sp. isolates from clinical cases of FENP and identified by 16S gene sequencing (publication I). Bacteria were cultivated on agar plates overnight and suspended in isotonic saline solution (0.9% NaCl). Concentration was determined by spectroscopy and the concentrations adjusted based on the viability experiment.

Viability and infectivity was tested by incubation of bacteria in saline suspension at +4°C for 6 hours at known concentrations of *A. phocae* and novel *Streptococcus* sp., determined as colony forming units (cfus) based on experiments correlating absorbance (OD 600) values with cfu. Both pre- and post-incubation samples were tested overnight at +37 °C and the colonies counted the following day. The +4°C temperature was used as the study II was performed in winter conditions (January-March). The inocula were prepared in the laboratory and the transport to the experimental farm lasted approximately 3-5 h.

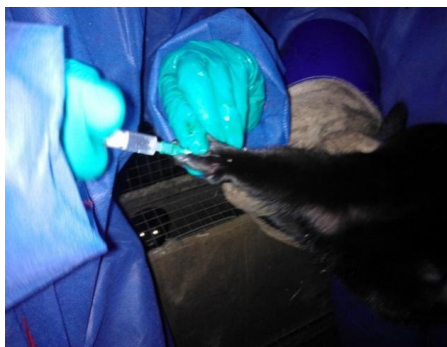
### **4.2.3.2 FENP tissue inocula**

A suspension taken from foot lesions from four mink from a FENP-affected farm was used for inoculation. The presence of *A. phocae* and novel *Streptococcus* sp. was tested using PCR.

#### 4.2.4 EXPERIMENTAL INFECTIONS

Clinical cases of FENP are usually observed during the periods of colder weather in Finland, thus we performed study II from January to March 2013, when the ambient temperature mainly varied between 0°C and +4°C but -20°C was recorded during the study period. The animals had two weeks of adjustment time after transport before the experimental infection and they were monitored for signs at least twice a day during the study.

We conducted two pilot studies in order to determine the optimal doses and infection routes for the main study. In total, 40 mink were used in the pilot studies: 30 mink were used for the 1st and 10 for the 2nd. The mink were infected per orally (p.o.) and subcutaneously (s.c.)/intradermally (i.d.). For the p.o. inoculation, the inoculum (1 ml) was mixed in 150g of mink feed and fed once a day. The mink were fed a 20% smaller portion the day before and the day of the inoculation to ensure that all the feed was eaten. The s.c./i.d. route was performed in pilot studies by injecting the inoculum (0.5 ml) via a 20 G needle to the dermis and subcutis in the plantar area of the right hind foot. No anesthetic was used during the procedure.



**Figure 9.** Subcutaneous (s.c.) /intradermal (i.d.) route was performed by injecting the inocula (0.5 ml) to the dermis and subcutis in the plantar area of right hind foot. **Photo Kirsi Aaltonen.**

#### 4.2.4.1 Pilot study 1 (II)

The first pilot study lasted four weeks: infection doses and routes are presented in Table 3.

**Table 3.** Infection doses (c.f.u.), routes and volumes used in pilot study 1.

| Group                   | Route         | Dose                              | Volume              | Mink (n) |
|-------------------------|---------------|-----------------------------------|---------------------|----------|
| Controls                | p.o.          | 9 mg/ml NaCl                      | 1 ml                | 2        |
| Controls                | s.c./i.d.     | 9 mg/ml NaCl                      | 0.5 ml              | 2        |
| Controls                | No procedures | -                                 | -                   | 2        |
| <i>A. phocae</i>        | p.o.          | 200 c.f.u.                        | 1 ml, mixed in feed | 4        |
| <i>A. phocae</i>        | p.o.          | 9 x 10 <sup>6</sup> c.f.u.        | 1 ml, mixed in feed | 4        |
| <i>A. phocae</i>        | p.o.          | 10 000 c.f.u.                     | 1 ml, mixed in feed | 4        |
| <i>A. phocae</i>        | p.o.          | 2 x 10 <sup>6</sup> c.f.u. (each) | 1 ml, mixed in feed | 4        |
| <i>A. phocae</i>        | s.c./i.d.     | 50 c.f.u.                         | 0.5 ml              | 4        |
| <i>A. phocae</i>        | s.c./i.d.     | 2500 c.f.u.                       | 0.5 ml              | 4        |
| FENP homogenized tissue | p.o.          |                                   | 1 ml, mixed in feed |          |
| FENP homogenized tissue | s.c./i.d.     |                                   | 0.5 ml              |          |
|                         |               |                                   |                     | 30       |

#### 4.2.4.2 Pilot study 2 (II)

The design of the second pilot study was based on the results and experience obtained from the first. The used inocula, infection routes, and doses are listed in table 4.

**Table 4.** Infection doses (c.f.u.), routes and volume used in pilot study 2.

| Group  | Route         | Dose                              | Volume              | Mink (n) |
|--|---------------|-----------------------------------|---------------------|----------|
| Controls   | no procedures | -                                 | -                   | 2        |
| <i>A. phocae</i>   | p.o.          | 9 x 10 <sup>6</sup> c.f.u.        | 1 ml, mixed in feed | 2        |
| <i>A. phocae</i>   | s.c./i.d.     | 4 x 10 <sup>6</sup> c.f.u.        | 0.5 ml              | 2        |
| Mixture of <i>A. phocae</i> and Novel <i>Streptococcus</i> sp. | p.o.          | 2 x 10 <sup>6</sup> c.f.u. (each) | 1 ml, mixed in feed | 2        |
| Mixture of <i>A. phocae</i> and Novel <i>Streptococcus</i> sp. | s.c./i.d.     | 2 x 10 <sup>6</sup> c.f.u. (each) | 0.5 ml              | 2        |
|  |               |                                   |                     | 10       |

#### 4.2.4.3 The main experimental study (II)

The main experimental study design was modified based on the results obtained from the two pilot studies, including: a changed inoculation route for per oral inoculation and the addition of a new inoculation route. The peroral route was changed to application of the inoculum with the syringe directly in the mouth and around the facial area of the mink, because the low temperatures proved to be difficult for mixing the inoculum in the feed. This route also mimicked the intranasal infection route. A new inoculation route was also included: application of the inoculum to an artificially created skin trauma (using the blade of the scalpel to scrape the superficial skin layers of the plantar area (0.5 cm x 0.5 cm) in the right hind feet). All mink were tested prior to the experiment for the presence of *A. Phocae* and the novel *Streptococcus* sp. in the blood. The inocula, doses, and routes used in the main study are presented in Table 5.

**Table 5.** Infection doses (c.f.u.), routes, and volumes used in the main study (II)

| <b>Group</b>  | <b>Route</b>   | <b>Dose</b>                       | <b>Volume</b>                             | <b>Mink (n)</b> |
|---|--|-----------------------------------|---|-----------------|
| <b>Controls</b>   | no procedures  | -                                 | -   | 1               |
| <b>Controls</b>   | Artificial skin trauma   | -                                 | -   | 6               |
| <b>Controls</b>   | Transferred to the cages of animals that died in the pilot study 2 | -                                 | -   | 4               |
| <b>A. phocae</b>  | p.o.   | 5 x 10 <sup>6</sup> c.f.u.        | Applied to the mouth and facial area 1 ml | 6               |
| <b>Mixture of A. phocae and Novel Streptococcus sp.</b> | p.o.   | 5 x 10 <sup>6</sup> c.f.u. (each) | Applied to the mouth and facial area 1 ml | 6               |
| <b>A. phocae</b>  | s.c.   | 3 x 10 <sup>5</sup> c.f.u.        | 0.5 ml                                    | 6               |
| <b>A. phocae</b>  | s.c./i.d.  | 3 x 10 <sup>6</sup> c.f.u.        | 0.5 ml                                    | 6               |
| <b>A. phocae</b>  | Artificial skin trauma   | 3x 10 <sup>5</sup> c.f.u.         | 0.5 ml                                    | 6               |
| <b>A. phocae</b>  | Artificial skin trauma   | 3 x 10 <sup>6</sup> c.f.u.        | 0.5 ml                                    | 6               |
| <b>Mixture of A. phocae and Novel Streptococcus sp</b>  | Artificial skin trauma   | 5 x 10 <sup>5</sup> c.f.u. (each) | 0.5 ml                                    | 6               |
| <b>FENP tissue</b>                                      | s.c.   | -                                 | 0.5 ml                                    | 6               |
|   |  |                                   |   | 59              |

## 4.3 PATHOLOGICAL AND MICROBIOLOGICAL STUDIES

### 4.3.1 GROSS PATHOLOGY AND HISTOPATHOLOGY IN STUDIES I AND II

The gross lesions were described by the location of the lesion, width, and severity of the inflammation, and classified by duration of the inflammation as an acute or chronic process. Possible lesions in the internal organs were recorded. The classification of severity of gross pathological lesions was divided into three categories: mild, moderate, or severe. Lesions with alopecia, slight hyperemia, and oedema were classified as mild inflammation; lesions with exudate formation, obvious edema and hyperemia were classified as moderate inflammation; and lesions with necrosis and marked pus formation as severe inflammation. A lesion with hyperemia, pus, and fibrin formation was considered as acute, and a lesion with predominant features including marked crusting and fibrous scarring was considered as chronic.

Samples of brain, heart, lung, trachea, spleen, liver, kidney, bladder, duodenum, jejunum, ileum, colon, local lymph nodes, skin (mink, Finn raccoon, fox), and eyes (fox) were taken at the necropsy. Tissues were immersed in 10% phosphate buffered formalin, embedded in paraffin, cut into 4µm sections and stained with hematoxylin and eosin (H&E). In study I, special stains were used in some samples Gomori Methenamine Silver (GMS), Ziehl-Neelsen (ZN), and Warthin Starry silver stain (WS). The severity of the inflammation in histopathological samples was classified based on the number of inflammatory cells (mild: few; moderate: constantly; severe: abundantly), the severity of tissue damage (mild: absent or minimal damage; moderate: obvious damage; severe: marked damage), and on vascular events (mild: some oedema and congestion; moderate: clear oedema and some hemorrhages; severe: extensive hemorrhages) detected on the lesions. The duration of the inflammation was concluded by the predominant inflammatory cell type (acute: neutrophilic granulocytes; chronic: lympho-plasmacytic). Occurrence of fibrin and hemorrhages were indicative for acute inflammation as fibrosis, granulomatous inflammation, neovascularization, and regeneration for chronic inflammation. Chronic-acute inflammation had characteristics of chronicity with features of acute inflammation.

### 4.3.2 BACTERIOLOGICAL STUDIES IN STUDIES I AND II

Samples of brain, heart, lung, spleen, liver, kidney, duodenum, jejunum, ileum, colon, local lymph nodes, skin (mink, Finn raccoon) and eyes (fox) were cultured on blood agar plates containing 5% defibrinated bovine blood were used. The seeded cultures were incubated at 37°C for between 24-28 hours in an aerobic and anaerobic (skin and eyes) atmosphere. The culturing was performed in E-vira. In earlier investigations, we had tested for yeast, fungi, *Salmonella*, *Campylobacter spp.*, other anaerobic pathogens, and mycoplasma in the diseased animals with negative results, so these tests were not included in studies I and II. Confirmation of bacterial species was made by biochemical methods or 16S RNA PCR and sequencing.



#### 4.3.2.1 PCR detection of *Arcanobacterium phocae* and the novel *Streptococcus* sp.

In study I, a PCR-method was developed for the detection of *A. phocae*. Samples from tissues (diseased and non-diseased) were tested for the presence of *A. phocae*. The same PCR- method was used in study II. Tissues of infected and selected control animals and infected animals with no clinical symptoms, blood samples, and feed used in experimental infection were subjected to PCR probing for the presence of both *A. phocae* and the novel *Streptococcus* sp. The PCR primers for *A. phocae* were designed to amplify a 182-nt product and primers. Forw-5'-TGGCATGCTGTTGGGGTGT-3'Rev-5'-TCGGCTCCGTATGCCAAGGC-3'were used. The PCR was set up on a real-time PCR platform with SYBR Green chemistry. The developed PCR methods are described more in detail in publication I. PCR studies were performed in the UH.

#### 4.3.2.2 Antibiotic susceptibility

VetMIC-panels for Gram positive bacteria (VetMIC GP mo) and for small animals (VetMIC små djur) (The National Veterinary Institute, SVA, Sweden) were used in Evira to test the antibiotic susceptibility.

### 4.3.3 VIROLOGICAL STUDIES

#### 4.3.3.1 Virus detection by (RT)-PCR-studies

Tissue samples were sent to the Evira laboratory for routine virological studies of Canine Distemper virus (CDV) and Mink enteritis parvovirus (MEV). Samples of the affected skin and eyes were sent to the UH for studies of herpesvirus DNA. Tests, sample materials, and methods are presented in table 6.

**Table 6.** Virus detection studies performed in study I.

| Virus       | Test   | Sample and site        | Reference                |
|-------------|--|------------------------|--------------------------|
| CDV         | RT- PCR primers based on phosphoprotein(P) gene  | Lung, trachea, bladder | Barret et al., 1993      |
| MEV         | PCR primers based on the sequence of the VP2 gene  | Rectum                 | Uwatoko et al., 1995     |
| Herpesvirus | A consensus primer PCR method. Amplifies a region of herpesviral DNA directed DNA polymerase and which degenerate primers in a nested format | Affected skin/eyes     | VanDevanter et al., 1996 |

#### 4.3.3.2 Antibody detection

Antibodies against CDV and MEV were measured from the serum of necropsied animals in Evira by methods used in routine diagnostics in fur animals. All mink were tested against plasmacytosis (Aleutian Mink Disease virus) in Fin Furlab in Vaasa. Tests, sample materials, and methods are presented in table 7.

**Table 7.** Antibody testing concluded in study I.

| Virus                            | Test                             | Sample | Reference                 |
|----------------------------------|----------------------------------|--------|---------------------------|
| CDV                              | Serum neutralization test        | Serum  | Ek- Kommonen et al., 1997 |
| MEV                              | Hemagglutination inhibition test | Serum  | Carmichael et al., 1980   |
| AMDV Aleutian mink disease virus | ELISA                            | Blood  | Knuutila et al., 2009     |

#### 4.3.3.3 Virus isolation trials

PCR techniques, cell culturing, and transmission electron microscopy (TEM) were used in study I to determine the presence of viral antigens in the samples of affected tissues from skin, eye, and swabs of the eye area. Small pieces of the skin and eye lesions were frozen in Universal Transport Medium (UTM) -tubes (Copan, USA) at  $-70^{\circ}\text{C}$  and sent to UH for further investigations. These samples were homogenized by grinding over dry ice. For homogenizing, Dulbecco's modified phosphate buffered saline solution with 0.2% bovine serum albumin, 10 U/ml penicillin, 0.1 mg/ml streptomycin, and 1.25 mg/ml amphotericin B (Fungizone, Invitrogen) was used with 700 ml of D-PBS added to 10–50 mg of tissue. Swabs were vortexed and 100 ml of the medium was diluted with 400 ml of D-PBS.

Electron microscopy was carried out on skin and eye sample homogenates and samples of eye swabs, transport media, as well as on cell culture media from cultures showing CPE or delayed propagation. Cell culturing was performed on canine kidney epithelial cells (MDCK, ATCC CCL-34) and Mink Lung epithelial cells (Mv1Lu, ATCC CCL-64). When symptoms of cytopathic effect (CPE) were detected, samples of medium and cells were collected.

The skin and eye samples, especially those representing the earlier stages of the infection, and cell culture derived samples were tested by several PCR assays. A pan-picornavirus RT-PCR was used to screen for members of the *Picornaviridae*. The *Poxviridae* were covered by two assays designed specifically for orthopoxviruses and parapoxviruses, respectively. Vesicular stomatitis virus was tested with a specific PCR test and the genus *Vesivirus* belonging to *Caliciviridae* was probed with a pan-vesivirus assay.

## **4.4 MAIL SURVEY OF FINNISH FUR FARMERS (III)**

### **4.4.1 STUDY DESIGN**

Study III was an epidemiologic study using a questionnaire mail survey regarding FENP in Finnish commercial fur farms and members of FFBA (n=958) in 2011. The study period which the questionnaire covered was for the years 2009, 2010, and first 6 months of 2011. There were multiple choice questions, yes/no questions, and questions requiring numerical or written information. The questionnaire covered the following issues: symptoms of FENP on the farm in different fur animal species, the symptoms and signs of the diseased animals, the farm and farmer characteristics, introduction of new fur animals (by import from other countries and/or by purchases from Finnish farms), details of other diseases than FENP on the farm, prophylactic and therapeutic practices on the farm, different management, and biosecurity measures. However, diarrhea was missing from the diseases list for foxes.

The farms were divided based on their responses to farms with clinical signs of FENP (case farms) and farms without clinical signs of FENP (control farms). The study design, the sample size calculations, content of the questionnaire, and the implementation of the study are described more in detail in publication III.

### **4.4.2 DEFINITIONS OF THE VARIABLES USED IN THE STUDY**

Logistic regression was used in analyzing the data. The occurrence of FENP was defined as response variable and the respondent farms were divided into case or control farms for which risk factors were retrieved from the questionnaire. The variables are listed in the tables and additional files of publication III.

- Case farm = farm with clinical signs of FENP detected in at least one fur animal species during the study period
- Control farm = farm with no clinical signs of FENP in any of the species during the study period

Four different farm types were used:

- 1) Mink farms
- 2) Fox farms
- 3) Finnraccoon farms
- 4) Mixed farms with at least two species

The size of the farm was determined according to the number of the breeder animals. The size classification and limits were based on the number of breeding animals on the respondent farms, reported by the farmer in the questionnaire. The aim was to create two different size groups approximately equal number of farms. The limits do not necessarily describe the sizes of Finnish farms in general:

- Mink  $\geq 750$  vs.  $< 750$
- Fox  $\geq 320$  vs.  $< 320$
- Finnraccoon  $\geq 125$  vs.  $< 125$
- The size was determined in mixed farms according to the most numerous species

In cases of species-specific variables (such as species-specific vaccinations and diseases, bedding materials in mink nests etc.) it was necessary to study these variables for all farms farming mink, foxes, or Finnraccoons regardless of whether there was only one species on the farm or if it was a mixed farm. In these cases, the farms were referred to as "farms with mink", "farms with foxes," and "farms with Finnraccoons". These variables are listed in table 4 in publication III and in the additional file 2.

- Farms with mink
- Farms with foxes
- Farms with Finnraccoons

The information was collected at an annual level, however for some events it was sufficient to know if an event had occurred at all during the study period. Therefore, new combined variables were created that summarised the annual data:

- Other diseases than FENP
- Medication given
- Vaccinations administered
- Purchases of animals – domestic or import

Both annual and combined variables were analyzed, if necessary. When annual data is used, it is mentioned in the text and in the tables in publication III.

#### **4.4.3 STATISTICAL ANALYSIS**

SAS version 9.3, SAS Institute, Cary, NC, USA was used for all statistical analyses in study III.

The following SAS procedures and tests were used:

- Proc Freq statement with Chisq and Fisher options in testing differences and association in binary data. Fisher was used in small samples in which chi square test was not valid.
- Proc Npar1way statement with Wilcoxon option producing Kruskal–Wallis test in data with more than two categories.
- Proc Logistic statement in logistic regression analysis in defining the most important factors in the spreading of FENP to the farm and its further spread.

Frequencies of all variables in the study were calculated for cases and controls. For all independent variables, the crude odds ratios (OR) and their 95% confidence intervals (CI) were estimated with logistic regression models.

The multivariable logistic regression analysis was performed in four subgroups:

- 1) All farms (model 1)
- 2) Mixed farms (model 2)
- 3) Farms with mink (model 3)
- 4) Farms with foxes (model 4)

For these groups, the variables with a significant crude OR at 95% confidence level were included. The effect of missing values was tested by running models that included missing values for variables recoded as “no”. Multicollinearity was tested by using the phi-coefficient for binary variables and by considering wideness of confidence intervals for more than two category variables. Second-order interactions were tested between all the variables. Pearson’s goodness of fit statistic (Pearson GOF) and McFadden’s and Cox and Snell  $R^2$  statistics were used for finding the best model.

The representativeness of the study farms was established by comparing the study farms and farmers with all Finnish fur farms and farmers with statistical tests. The information of Finnish fur farms was obtained from results of the study performed by FFBA in 2010.

#### **4.5 ETHICAL STATEMENTS AND LEGISLATION REGARDING STUDIES I, II, AND III**

No ethical permission was required for study I as culling was performed as a normal procedure at pelting. However, the carcasses were not pelted as the lesions situated in the skin in the head and/or feet or paws. The carcasses were obtained as donations from fur animal farms. The mink were euthanized on the farm using carbon monoxide or carbon dioxide (CO or CO<sub>2</sub>) gas, and foxes and Finnraccoons by using electricity. The culling was performed by methods described in the legislation concerning culling of the animals (EU N: o 1099/2009). Experimental study II was performed in accordance with the Finnish Act on Animal Experimentation 62/2006 and with the European convention for the protection of vertebrate animals used for experimental and other scientific purposes (Directive 86/609/EEC). All the experimental procedures of the study were approved by the Animal Experiment Board in Oulu (Permit Number: ESAVI/6780/04.10.03/2012). The housing of the experimental mink was in full compliance with the Finnish requirements given to the housing and management of mink (VN a1084/2011). The mink were monitored regularly and euthanized when symptoms of severe disease (such as high fever, anorexia or apathy) or signs of marked inflammation in the skin were detected to avoid unnecessary prolonged pain or distress and suffering. The animals were euthanized by the regulations in legislation concerning culling of the animals ((EU) N: o 1099/2009). Study III was an epidemiologic mail survey and did not encompass any living animals or any materials obtained from living animals. The questionnaires were handled and presented anonymously and the confidentiality of respondents was secured by handling the

data without any information for identification. Furthermore, the data obtained from the questionnaires was protected from unauthorized access during processing and storing.

## 5 RESULTS

### 5.1 CLINICAL SIGNS, PATHOLOGICAL CHARACTERIZATION, AND MICROBIOLOGICAL FINDINGS OF FUR ANIMAL EPIDEMIC NECROTIC PYODERMA, FENP

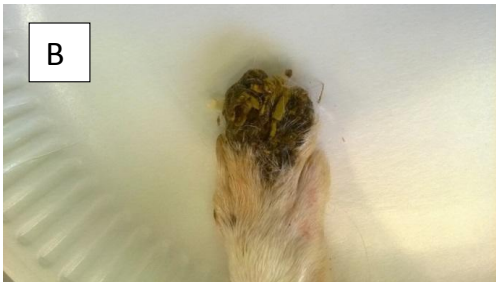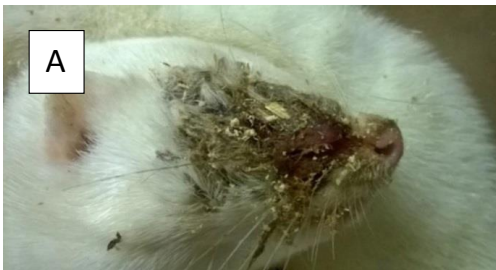#### 5.1.1 CLINICAL SIGNS

##### 5.1.1.1 *Clinical signs in mink (I)*

The signs of FENP in mink were seen mainly in the skin of the face or foot. Sensitivity to light was first noted (Fig 10). Then lesions characterized by edema and serous discharge developed in the head region especially in the mucocutaneous junctions around the mouth, eye, nose pad, or ear before the typical purulent discharge and facial necrotizing dermatitis was detected (Fig 11A). The lesions that occurred in the feet were located around the nailbeds, occasionally spreading to the footpads and the dorsal skin of the feet (Fig 11B). Inflammation had occasionally spread to the bone structures and caused nails to drop out. When the lesions developed in the feet, mink may have avoided the use of the affected feet and the swelling of the paw gave an appearance of toes being splayed. In some cases, the lesions in the feet had been detected after nail clipping for blood testing. Systemic signs of lethargy and anorexia in addition to increased mortality were detected on the affected farms. The disease seemed to spread effectively throughout the farm. Despite this, some animals that shared the same cage as an affected animal showed no signs of the disease. Farmers have also reported that before visible symptoms occur on the farm, the litter size diminishes. The experiences of Finnish farmers and veterinarians indicate that the symptoms and signs are at their most severe when the farm is first affected, but over a few years there is a decrease in the number of affected animals and signs become milder. The farm may become symptomless but relapses may occur.



**Figure 10.** The first signs of FENP in mink may include puffiness around the eye, sensitivity to light, and a yellowish serous discharge around the eye (see black arrow). Photo Heli Nordgren.

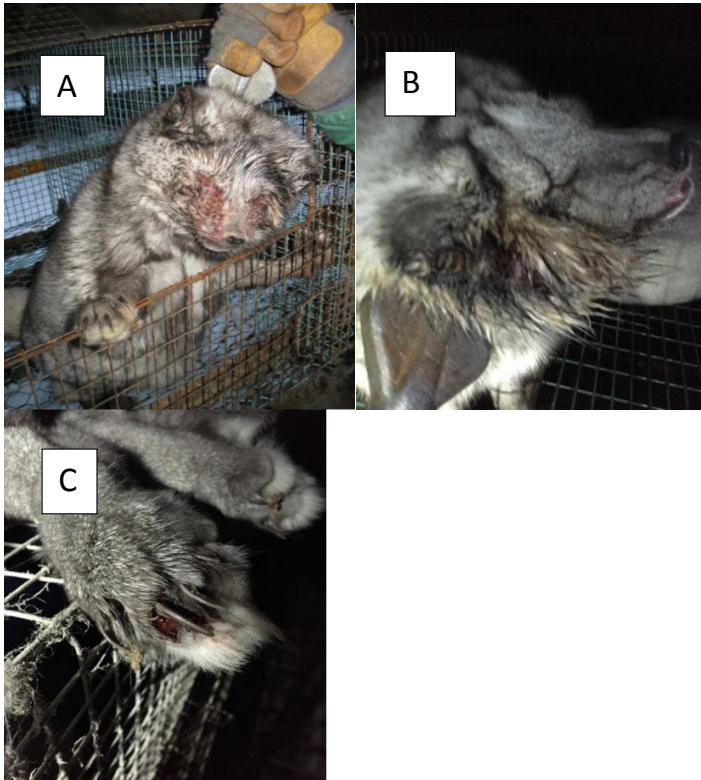


**Figure 11.** Dermatitis typically starts in the mucocutaneous junctions, such as around the eye or in the nail bed from where it spreads to periorbital facial skin (A) or to toes (B) of the mink. Photos Heli Nordgren.

#### **5.1.1.2 Clinical signs in foxes (I)**

The signs of FENP in foxes manifested in the eyes, eyelids, and in the facial skin. The first manifestation of the disease was a serous discharge from the eyes and the third eyelid that was hyperemic and edematous. The discharge soon turned into a purulent exudate and the inflammation commonly spread to the eyelids and facial skin (Fig 12 A). In acute outbreak, signs progressed very rapidly and a high mortality could be detected. In some cases, inflammation evolved around the ear (Fig 12 B) or around the nailbeds (Fig 12 C) in foxes. Farmers have also reported poor appetite or anorexia.

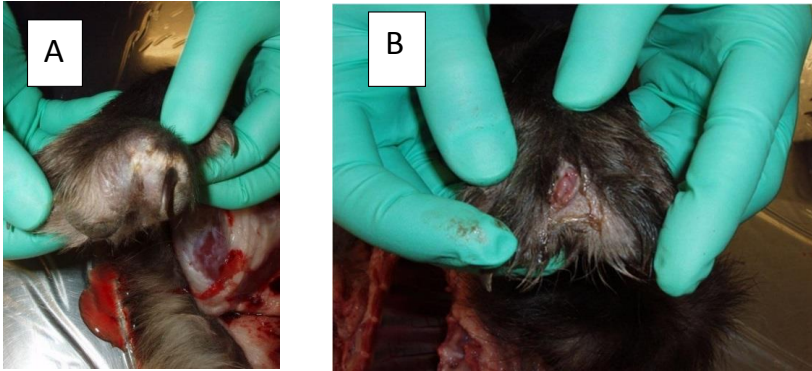




**Figure 12.** In foxes, FENP is seen in the eyes, the eyelids and in the periorbital facial skin (A). In some cases, lesions around the ear (B) or around the nailbeds (C) occur. Photo A Hannu Kärjä, photos B and C Sami Pesonen.

### **5.1.1.3 Clinical signs in Finnracons (I)**

Finnracons are generally resistant to diseases and seldom need veterinary care, but FENP also affects them. The disease was manifested in the paws between the toes. Swelling between toes was seen, and well circumscribed furuncles (Fig. 13A) which occasionally fistulated to the dorsal skin of the paw (Fig 13 B) were detected. Poor appetite, pain, self-mutilation of the affected paw and deaths were reported.



**Figure 13.** Lesions develop in Finn raccoons in between the toes of the paws. Painful furuncles (A) may fistulate to the dorsal skin (B). Photo Pasi Arola.

## 5.1.2 GROSS PATHOLOGY FINDINGS

### 5.1.2.1 Gross pathology in mink (I)

Gross pathological lesions were detected in all mink submitted to necropsy (n=21). Lesions were mainly detected in the facial skin (Figs 14 A, B, C) and mostly around the eyes (15). Six mink had lesions in the feet, mainly in the front feet.

The areas of the lesions in the head ranged between 2 x 2 cm and 8 x 8 cm, smaller lesions were detected in the feet. The lesions were characterized by a brownish exudate with attached bedding material and crust formation. There was hyperemic inflammation with profound necrosis under the crust. These lesions were categorized as severe, chronic necrotizing pyoderma. Three lesions in the head had an alopecic ring around the lesion and one lesion in the hind leg presented mild lesions of alopecic and hyperemic area without any visible inflammation and crust formation (unpublished data). The lesions in the feet were chronic, with severe pyoderma presenting brownish exudate, crust formation, and necrosis. The lesions in feet were located on the footpads, around the nailbeds and on the dorsal skin of the paw. In two cases, the nail was missing and the inflammation had spread to the underlying bone (osteomyelitis). Splenomegaly (Fig 15) was detected in 10 mink and enlargement of mandibular lymph nodes in 7 mink. The gross pathology findings in mink are presented in Table 8. No lesions were found in healthy controls (11).

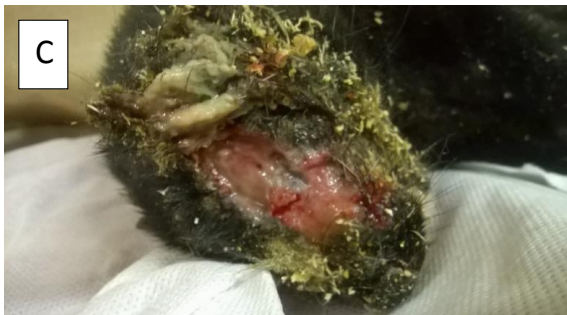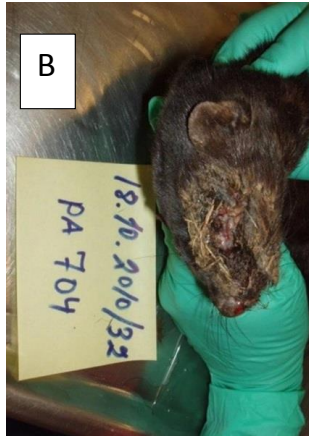
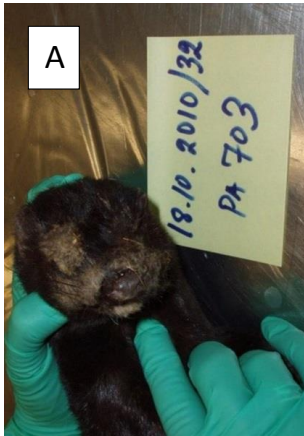**Table 8.** Gross pathology in the mink study I.

---

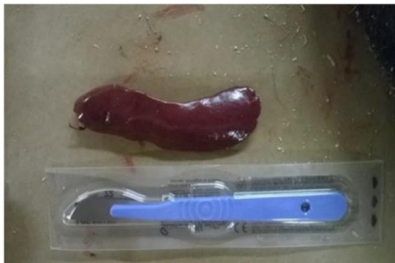| <b>Gross Pathology lesions (n=21)</b> | <b>n (%)</b>    |
|---------------------------------------|-----------------|
| <b>Lesions in the head</b>            | <b>15 (71%)</b> |
| Around eyes*                          | 10 (67%)        |
| Around ear*                           | 2 (13%)         |
| In the chin*                          | 1 (7%)          |
| Between eyes*                         | 1 (7%)          |
| On the top of the head*               | 1 (7%)          |
| <b>Lesions in the feet</b>            | <b>6(29%)</b>   |
| Front Legs*                           | 4 (67%)         |
| Hind legs*                            | 2 (33%)         |
| Splenomegaly                          | 10 (48%)        |
| Lymphadenopathy                       | 7 (33%)         |
| Congestion of the internal organs     | 4 (20%)         |
| Cachexia                              | 2 (33%)         |
| Fatty liver                           | 2 (33%)         |

---

\*Unpublished data.



**Figure 14.** The eyes and nares of mink covered with brownish exudate (A). Bedding material attached to the exudate (B). The necrotic skin peels off easily and reveals pus, haemorrhage and edema subcutaneously in the head of mink (C). Photos Pasi Arola,



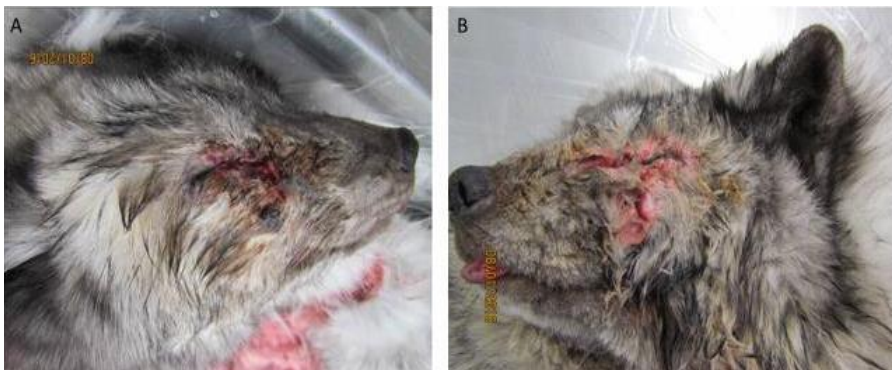**Figure 15.** Splenomegaly was a common finding in diseased animals in FENP. Spleen from a mink. The spleen was 4-5-fold that of normal mink spleen, which normally measures approximately 1.0 cm x 4.0 cm. Photo Heli Nordgren.

### 5.1.2.2 Gross pathology findings in foxes (I)

Gross pathological lesions were detected in all foxes subjected to necropsy (n= 19). Bilateral conjunctivitis was established in 17 and unilateral conjunctivitis in only two foxes. Mild inflammation with a serous discharge and edemic and hyperemic third eyelid with vesicles inside of the lid was reported in 8 foxes. Severe inflammation with a purulent discharge was detected in 11 foxes. The inflammation had spread to the eyelids and to the skin of the face in three foxes. Three cases had distinct entropion, but in other cases due to the profound edema and pus formation, it was difficult to determine if there had been entropion, ectropion, or ectopic cilia originally. In internal organs, three foxes had enlargement of the mandibular and submandibular lymph nodes, fatty liver was detected in two foxes. The gross pathology findings in foxes are presented in Table 9. No lesions were found in healthy controls (12).

**Table 9.** Gross pathology in foxes (study I)

| Gross Pathology lesions (n=19)     | n (%)    |
|------------------------------------|----------|
| Bilateral conjunctivitis           | 17 (89%) |
| Unilateral conjunctivitis          | 2 (11%)  |
| Serous discharge                   | 8 (42%)  |
| Purulent discharge                 | 11 (58%) |
| Purulent skin inflammation of face | 3 (16%)  |
| Entropion                          | 3 (16%)  |
| Lymphadenopathy                    | 3 (16%)  |
| Fatty liver                        | 2 (11%)  |



**Figure 16.** Severe dermatitis in the periorbital facial skin (A) and larger area of the face (B) in foxes (photos are not from the study but from an outbreak of FENP in January 2016). Photos Kirsi Collin.

### 5.1.2.3 Gross pathology in Finnraccoons (I)

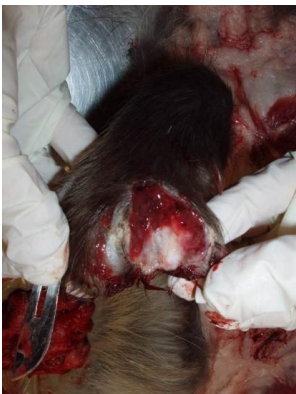Gross pathological lesions were detected in all Finnraccoons subjected to necropsy (21). Lesions were detected in the paws between the toes (Fig 17). Severe, chronic abscesses formation were detected in the front paws in 17 cases and both the front and hind paws in four cases. The number of abscesses in the paws varied from one to three abscesses in one paw. A majority of the abscesses were intact, well circumscribed from the surroundings with a capsule, but some had fistulated to the dorsal surface of the paw.

An examination of the internal organs revealed that 10 had enlarged local lymphnodes (axillary/popliteal) and 10 splenomegaly. One fatty liver and one cachectic animal were detected incidentally. Two Finnraccoons from the same farm had aplasia of the left-side kidney (unpublished data). The gross pathology findings in Finnraccoons are presented in Table 10.

One healthy control also had an abscess between the toes on the paw in the front leg. Other healthy controls (11) had no detectable lesions. All healthy controls came from the same farm. After the study, the farm was heavily affected by FENP and Finnraccoon farming was entirely disrupted due the disease (unpublished data).

**Table 10.** Gross pathology in Finnraccoons (study I)

| Gross Pathology lesions (n=21)           | n=21      |
|--|-----------|
| Abscesses in the paws                    | 21 (100%) |
| Abscesses between toes in the front-paws | 17 (81%)  |
| Abscesses in the hind-paws               | 4 (19%)   |
| Splenomegaly                             | 10 (48%)  |
| Lymphadenopathy                          | 10 (48%)  |
| Kidney aplasia                           | 2 (10%)   |
| Fatty liver                              | 1 (5%)    |
| Cachectic                                | 1 (5%)    |



**Figure 17.** Dissected abscess in the paw of a Finnraccoon in necropsy. Pus and blood can be seen draining out from the abscess. Photo Pasi Arola.

#### **5.1.2.4 Clinical signs and gross pathology in the experimental infection (II)**

Acute signs and lesions typical of FENP were induced by inoculating the bacteria subcutaneously/intradermally or to an artificially wounded skin with 1) tissue suspension of a mink with FENP, 2) with high doses of a suspension of *A. phocae* culture, and 3) a suspension of a mixture of both *A. phocae* and the novel *Streptococcus* spp. The signs and gross pathology findings of the infected mink are respectively described and shown in Table 11 and Figure 18. One mink succumbed during the adaption period.

**Table 11.** Signs and gross pathological findings in infected mink in pilot studies 1, 2, and in the main study (II).

| <b>Pilot study 1</b>        |                          |  |
|-----------------------------|--------------------------|--|
| <b>Test group (n)</b>       | <b>Dose and route</b>    | <b>Signs</b>   |
| Controls (2)                | p.o. 9 mg/ml NaCl        | No signs detected  |
| Controls (2)                | s.c./i.d. 9 mg/ml NaCl   | No signs detected  |
| Controls (2)                | No procedures            | No signs detected  |
| <i>A. phocae</i> (4)        | p.o.<br>200 c.f.u.       | No signs detected  |
| <i>A. phocae</i> (4)        | p.o.<br>10 000 c.f.u.    | A brief mild exudation from the eyes two days after inoculation (1)                          |
|                             |                          | A minor momentary discharge from the nares two days after inoculation (2) (unpublished data) |
| <i>A. phocae</i> (4)        | s.c./i.d.<br>50 c.f.u.   | No signs detected  |
| <i>A. phocae</i> (4)        | s.c./i.d.<br>2500 c.f.u. | Mild swelling of the injection site two days after inoculation (1) (unpublished data)        |
| FENP homogenized tissue (4) | p.o.                     | No signs detected  |
| FENP homogenized tissue (4) | s.c./i.d.                | 0.5 x 0.5 cm crust with purulent exudate in the inoculation site (1)                         |

**Pilotstudy 2**

| <b>Test group (n)</b> | <b>Dose and route</b>               | <b>Signs</b>  |
|-----------------------|-------------------------------------|---|
| Controls (2)          | No procedures                       | No signs detected   |
| <i>A. phocae</i> (2)  | p.o. $9 \times 10^6$ c.f.u.         | No signs detected   |
| <i>A. phocae</i> (2)  | s.c./i.d.<br>$4 \times 10^6$ c.f.u. | Severe systemic signs of lethargy, anorexia and apathy, and pyoderma with edema, hemorrhages and necrosis in the injection site, sudden death two days after inoculation (2). |



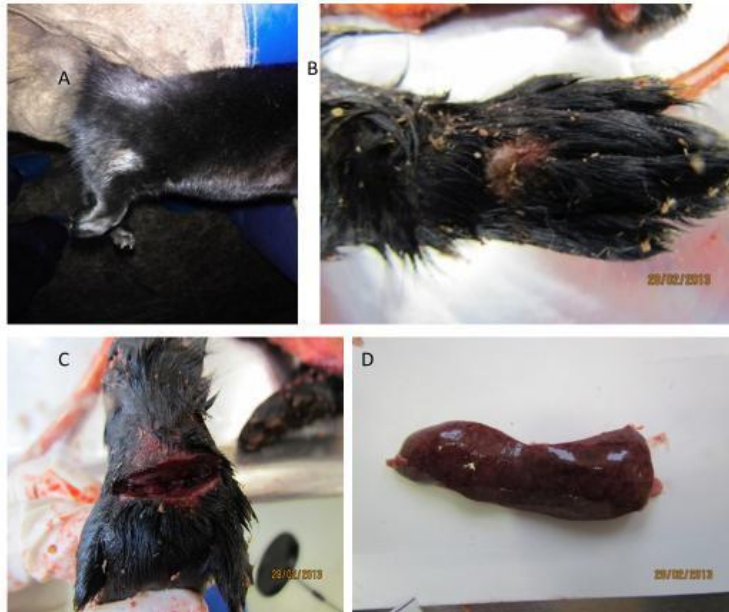
|             |   |  |
|-------------|---|--|
| Mixture (2) | p.o.<br>2 x 10 <sup>6</sup> c.f.u. (each)         | No signs   |
| Mixture (2) | s.c./i.d.<br>2 x 10 <sup>6</sup> c.f.u.<br>(each) | Severe systemic signs of lethargy, anorexia and apathy, and pyoderma with edema, hemorrhages and necrosis in the injection site, sudden death two days after inoculation (1)/ euthanized three days after inoculation (1). |

---

### The main study

| Test group (n)  | Dose and route  | Signs   |
|-----------------|---|---|
| Controls (1)    | No procedures   | No signs  |
| Controls (6)    | Artificial wound  | The lesion produced cured in few days in all controls   |
| Controls (4)    | Transferred to the cages of animals which died in the pilot study 2 | No signs  |
| A. phocae (6)   | p.o.<br>5 x 10 <sup>6</sup> c.f.u.                                  | No signs  |
| Mixture (6)     | p.o.<br>5 x 10 <sup>6</sup> c.f.u (each)                            | No signs  |
| A. phocae (6)   | s.c.<br>3 x 10 <sup>5</sup> c.f.u                                   | Severe systemic signs of lethargy, anorexia and apathy, and pyoderma with edema, hemorrhages and necrosis in the injection site, sudden death/euthanasia 1-2 days after inoculation (6) |
| A. phocae (6)   | s.c.<br>3 x 10 <sup>6</sup> c.f.u                                   | "<br>(5)  |
| A. phocae (6)   | Artificial wound 3 x 10 <sup>5</sup> c.f.u                          | "<br>(5)  |
| A. phocae (6)   | Artificial wound 3 x 10 <sup>6</sup> c.f.u                          | "<br>(5)  |
| Mixture (6)     | Artificial wound 5 x 10 <sup>5</sup> c.f.u (each)                   | "<br>(5)  |
| FENP tissue (6) | s.c.  | 0.5 x 0.5 cm crust with brownish exudate in the inoculation site (3)  |

---



**Figure 18.** In pilot study1, mink infected with FENP-tissue developed a 0.5 cm x 0.5 cm crust in the inoculation site (A). Mink inoculated with bacteria suspension developed a crust (B) and necrosis, hemorrhages, and pus in the injection site (the scission made to demonstrate the subcutaneous edema, hemorrhage and pus formation) (C). Splenomegaly indicating systemic response was often detected (enlargement of 4-5 times normal mink spleen) (D). Photos Heli Nordgren.

### 5.1.3 HISTOPATHOLOGICAL FINDINGS

#### 5.1.3.1 *Histopathological findings in mink (I)*

Skin sampled from mink displayed mainly severe chronic acute neutrophilic, necrotic deep pyoderma with ulceration, hemorrhages and crusting. Coccoid bacteria in the epidermal layer, hyperkeratosis and parakeratosis were observed as well (Fig 19, 20 A,B). The inflammation appeared to have spread to the hair follicles in some cases (perifolliculitis/folliculitis). Severe necrosis in the subcutis and the vasculitis that had led to thrombosis were detected. Some vacuolated keratinocytes and hypergranulosis were occasionally seen. The inflammatory cells were mainly neutrophilic but perivascular and periadnexal lymphoplasmacytic inflammation was also noted. In two samples, intracytoplasmatic eosinophilic material resembling inclusion bodies was detected. In special stainings (GMS and ZN) no evidence of parasites, fungi, or mycobacteria was seen. WS staining revealed no silver-stain-positive organisms.

Diseased mink had non-specific reactive changes (diffuse follicular hyperplasia, with mitotically active germinal centers, where large blast cells and macrophages predominated) in the spleen and in the local lymph nodes. Varying degrees of perivascular or peribronchial lymphocytosis in the lung specimens were detected in a few cases (Fig 20 C). One diseased mink had a severe

granulomatotic pneumonia where Langhans giant cells, syncytia, and alveolar histiocytosis was detected. The histopathology of the mink in study I is shown in table 12.

**Table 12.** Histopathological findings in the mink (I).

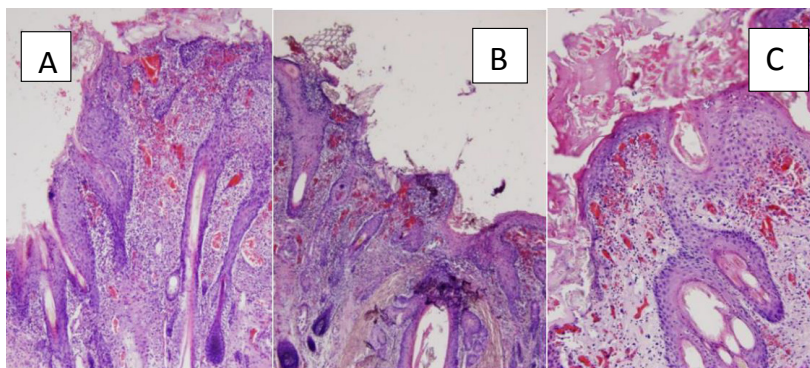
| <b>Skin samples</b>                               | <b>n=21</b> |
|---|-------------|
| Severe neutrophilic necrotic dermatitis           | 19 (90%)    |
| Ulceration, hemorrhages, and crusting             | 19 (90%)    |
| Coccioid bacteria in the epidermis                | 11 (52%)    |
| Necrosis in the subcutis                          | 11 (52%)    |
| Hyperkeratosis                                    | 10 (48%)    |
| Perivascular and periadnexal lympho-plasmacytosis | 9 (43%)     |
| Parakeratosis                                     | 8 (38%)     |
| Vasculitis  | 8 (38%)     |
| Perifolliculitis/folliculitis                     | 4 (19%)     |
| Vacuolated keratinocytes                          | 4 (19%)     |
| Hypergranulosis                                   | 4 (19%)     |
| Intracytoplasmic osinophilic material             | 2 (10%)     |

---

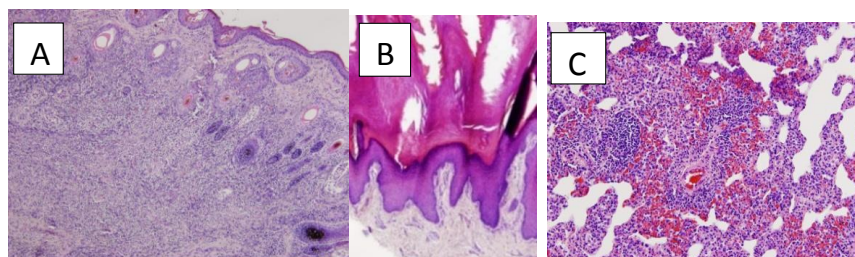
| <b>Internal organs</b>                                 |         |
|--|---------|
| Non-specific reactive changes in the spleen            | 9 (43%) |
| Non-specific reactive changes in the local lymph nodes | 3 (14%) |
| Perivascular or peribronchial lymphocytosis in lung    | 4 (19%) |
| Severe granulomatous pneumonia                         | 1(1%)   |

No inflammatory lesions were detected in the skin of controls (11). However, a mild hyperkeratosis and a mild parakeratosis were found in the footpads in 2/11 (18%) of the healthy controls from the uninfected farm, and in two out of the four (50%) clinically healthy mink from the affected farms.

In the internal organs, varying degrees of perivascular and peribronchial lymphocytosis was seen in 4/11 (36%) lung specimens of the controls. Two clinically healthy mink, from a diseased farm (2/4, 50%), had perivascular and peribronchial lymphocytosis in the lung. A fatty infiltration was detected in the liver from one mink. No specific lesions were detected in the other internal organs of any of the mink.



**Figure 19.** Facial skin sections from FENP diseased mink showed ulceration and crusting of the epidermis, severe diffuse mainly neutrophilic inflammation with haemorrhage (A, B and C) was detected in epidermis, dermis and subcutis. Photos Heli Nordgren.



**Figure 20.** Severe deep diffuse necrotizing purulent inflammation in the dermis and subcutis (panniculitis) in the facial skin sample of the mink (A). Severe orthokeratotic hyperkeratosis in a skin section taken from a mink foot (B). Hemorrhages and peribronchial and -vascular lympho-plasmacytic infiltration in lung sample of the diseased mink (C). Photos Heli Nordgren.

### 5.1.3.2 Histopathological findings in foxes (I)

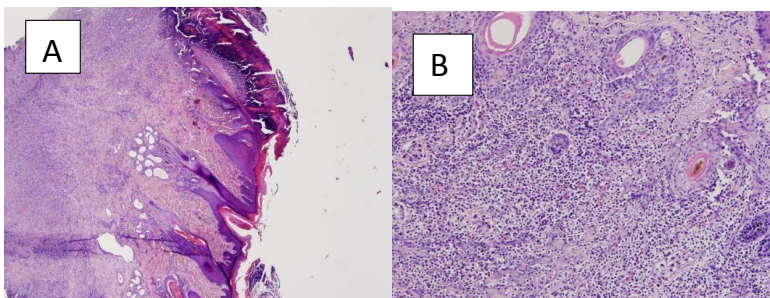
Varying degrees of chronic, lympho-plasmacytic conjunctivitis with mild to moderate, predominantly neutrophilic inflammation, which had spread from the limbus to the corneal centre, and then progressed centrally to an ulcerative keratitis, was revealed in some foxes. Phtisis, hypopyon, and conjunctival inflammation that extended into the retrobulbar/periscleral tissues were found in the most severe cases. The severe cases also had lympho-plasmacytic keratitis with serocellular crusts and coccoid bacteria. Hypereosinophilia of basal epithelia, corneal edema, and activation of keratocytes were also detected. A chronic, purulent pustular dermatitis with occasional coccoid bacteria were detected in the eyelids and facial skin of the foxes. No specific changes were observed in the internal organs of any of the foxes.

### 5.1.3.3 Histopathological findings in Finnraccoons (I)

Varying degrees of chronic-acute deep diffuse neutrophilic inflammation that also involved the subcutis (panniculitis) in the majority of the cases were found. Inflammation of the epidermis/dermis had spread to the hair follicles and caused severe furunculosis in more than half of the samples. Moderate to severe hyperkeratosis, ulceration, hemorrhage, and necrosis with coccoid bacteria was detected in the epidermis (Fig 21). A marked eosinophilia of the dermis was seen in five cases in addition to lympho-plasmacytic inflammation in three. The histopathology of the Finnraccoons is shown in Table 13. One of the Finnraccoons submitted for necropsy as a healthy control was observed to exhibit the typical macroscopic lesions of FENP. The histopathological lesions were identical to the lesions in the diseased animals. No lesions were detected in other controls (11). No specific lesions were detected in the internal organs of any of the Finnraccoons.

**Table 13.** Histopathological findings in the skin samples of Finnraccoons in (I).

| Finnraccoon                       | n=21     |
|-----------------------------------|----------|
| Neutrophilia                      | 21(100%) |
| Dermatitis including panniculitis | 18 (86%) |
| Furunculosis                      | 13 (62%) |
| Ulceration, crusting, hemorrhages | 13 (62%) |
| Coccoid bacteria in the epidermis | 13 (62%) |
| Hyperkeratosis                    | 8 (38%)  |
| Eosinophilia                      | 5 (24%)  |
| Lympho-plasmasytic inflammation   | 3 (14%)  |



**Figure 21.** A section from a diseased Finnraccoon's paw with a fistulated abscess between the toes shows chronic, deep and diffuse neutrophilic inflammation with ulceration and crusting in the epidermis (A) and necrotizing suppurative panniculitis (B). Photos Heli Nordgren.

### 5.1.4 HISTOPATHOLOGICAL FINDINGS IN THE INFECTION STUDY (II)

A total of 34 mink developed signs and gross pathological lesions after inoculation with *A. phocae*, or with mixture of both bacterial species (*A. phocae* and *Streptococcus* sp.) or tissue extract from FENP diseased mink. Thirty- three of these 34 mink, also had histological lesions. The mink that had been inoculated with *A. phocae* or mixture of *A. phocae* and *Streptococcus* sp. s.c./i.d, or to an artificially created skin trauma, showed histopathological lesion similar to the clinical cases of FENP. Subcorneal pustules, coccoid

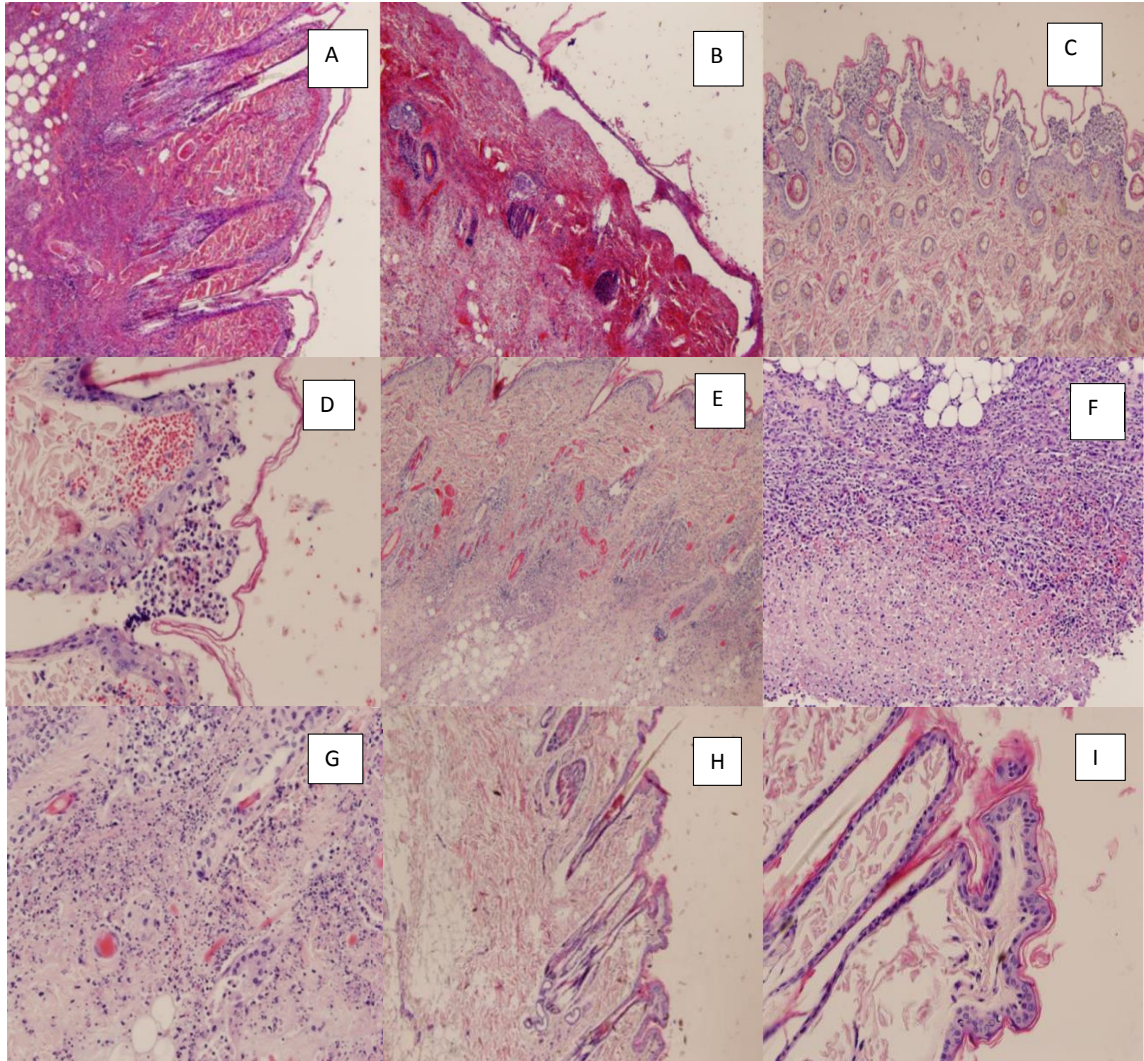
gram-positive bacteria, severe necrosis, hemorrhages, fibrin, and acute diffuse mainly-neutrophilic inflammation were detected in the epidermal layer of the skin (Fig 22). The inflammation also involved subcutis and occasionally vasculitis and micropustular inflammation were detected.

Furthermore, mink inoculated s.c./i.d. with the tissue of FENP-affected animals (4) developed histopathological lesions in the skin similar to those seen in FENP (Fig 22 F).

Acute severe necrosis, fibrin, and hemorrhages were detected in 82% (28/34) in the spleen of infected mink and 56% (19/34) had mild to moderate liver steatosis. Moreover, 47% (16/34) the lungs had congestion and moderate perivascular lympho- and plasmacytic inflammations and 32% (11/34) fibrin and neutrophilic granulocytes.

The selected control animals for necropsy (3) and one mink that had died during the adaption period were also necropsied and no gross pathological or histopathological changes were detected. In addition, eleven animals from different inoculation groups showing no signs or gross pathological changes were submitted to histopathological studies. Ten of them showed no histopathological changes, but one mink (infected with FENP tissue) showed histological changes in the skin and in the spleen, that were much milder yet similar to the diseased animals.





**Figure 22. Histopathological findings in the experimental infection (II).**

A section from the inoculation site in mink inoculated with *A. phocae* and novel *Streptococcus* sp. s.c./i.d. Acute, severe superficial and deep, diffuse neutrophilic inflammation (A). Severe hemorrhage and diffuse neutrophilic inflammation in the inoculation site in mink inoculated solely with *A. phocae* s.c./i.d. (B). A skin section from the mink inoculated with *A. phocae* and novel *Streptococcus* sp. shows subcorneal pustular inflammation with hemorrhages (C, D). More deep diffuse neutrophilic inflammation from skin section from the mink inoculated with *A. phocae* s.c./i.d. (E). Severe necropurulent inflammation in mink inoculated s.c./i.d. with tissue extract of FENP affected mink (F). Similar inflammation in mink inoculated with *A. phocae*. (G) Skin section from the control mink injected s.c./i.d. with NaCl solution shows no histopathological lesions (H, I) (Figure 22 is used in publication II).

### 5.1.5 BACTERIOLOGICAL RESULTS (I)

*Arcanobacterium phocae* was the main finding in the bacteriological cultures in the skin and eyesamples of diseased animals. Furthermore, all diseased animals were positive for *A. phocae* as detected by PCR. *A. phocae* was cultured in 16/21 of the skin samples of diseased mink, whereas the corresponding number detected by PCR was 21/21. There was significant difference in the samples taken from foxes that had a serous discharge from the eyes vs. those with a purulent discharge in microbiological culture. *A. phocae* was cultured from 5/11 in samples with purulent discharge, and only in one sample with serous discharge (1/8); from 6/19 of the diseased foxes. However, PCR revealed the presence of *A. phocae* in all diseased foxes 19/19. In diseased Finnraccoon samples *A. phocae* was cultured from 8/20 of samples, whereas PCR detected *A. phocae* in all samples 20/20. *A. phocae* was not found on any of the healthy controls of mink and foxes in cultures and it was found only in one healthy mink with low amounts by PCR. The difference between detecting *A. phocae* in diseased mink and foxes compared to their healthy controls was statistically significant for the culturing method  $p < 0.001$  for mink and  $p < 0.05$  for foxes. The corresponding differences for the PCR were  $p < 0.001$  for mink and  $p < 0.001$  for foxes. However, the healthy controls of Finnraccoons showed different results. One Finnraccoon submitted for necropsy as a healthy control exhibited the typical macroscopic and histologic lesions of FENP and it was also positive for *A. phocae* both in culture and in PCR. As many as 6/10 of clinically healthy controls were found to be positive in PCR assays (but not in culture), though the levels of bacteria were lower than in most diseased samples. The clinically healthy mink that came from a diseased farm were all negative for *A. phocae* in culture, but 3/4 were positive for PCR, albeit with low numbers of bacteria (table 14.).

*A. phocae* grew on blood agar after 24 hours as very small, pinpoint-like colonies with a strong hemolytic zone. Biochemical characteristics of the *A. phocae* are presented in table 15. In most cases (26/31) *A. phocae* was a part of a mixed culture with the other bacteria that predominantly belonged to the genus *Streptococcus* or *Staphylococcus*. *A. phocae* was also isolated as a pure culture in five (5/31) samples of diseased animals. *Streptococcus* isolates (28) were further investigated and revealed a previously unknown *Streptococcus* based on the 16S RNA gene sequence data. The sequence shows that it is closely related to streptococci of marine origin, such as *Streptococcus halichoeri*. Novel *Streptococcus* sp. grew on blood agar in 24 hours as very small, pinpoint-like colonies. Biochemical characteristics of the novel *Streptococcus* sp. are presented in table 15. The Lancefield test categorized them as group B. The finding of the cultivable streptococcal species more often in diseased mink and Finnraccoons than controls was statistically significant (table 14).



**Table 14.** Detection of *A. phocae* and *Streptococcus* spp. in fur animals with signs associated with FENP.

|                                    | PCR positive<br>for <i>A. phocae</i> | p-value | Positive for<br><i>A. phocae</i><br>in culture | p-value | Positive for<br><i>Streptococcus</i><br>pp. in culture |        |
|------------------------------------|--------------------------------------|---------|--|---------|--|--------|
| Diseased mink                      | 21 (21)                              | <0.001  | 16 (21)  | <0.001  | 16 (21)  | <0.001 |
| Healthy mink                       | 1 (11)                               |         | 0 (11)   |         | 0 (11)   |        |
| Healthy mink on a<br>diseased farm | 3 (4)                                |         | 0 (4)  |         | 0 (4)  |        |
| Diseased<br>Finnraccoon            | 20 (20)                              | <0.01   | 8 (20)   | 0.07    | 10 (20)  | <0.01  |
| Control<br>Finnraccoon**           | 6 (11)                               |         | 1 (11)   |         | 0 (11)   |        |
| Diseased fox                       | 19 (19)                              | <0.001  | 6 (19)   | 0.04    | 2 (19)   | 0.4    |
| Healthy fox                        | 0 (12)                               |         | 0 (12)   |         | 0 (12)   |        |
| All diseased<br>animals            | 60 (60)                              | <0.001  | 30 (60)  | <0.001  | 28 (60)  | <0.001 |
| All control<br>animals             | 10 (38)                              |         | 1 (38)   |         | 0 (38)   |        |

\* calculated by Fischer's exact test.

\*\* One control animal had macroscopic and histopathologic findings typical of FENP. All control Finnracons came from the same control farm.

**Table 15.** Biochemical characteristics of *A. phocae* and the novel *Streptococcus* sp.

|                         | <i>Arcanobacterium phocae</i> | Novel <i>Streptococcus</i> sp. |
|-------------------------|-------------------------------|--------------------------------|
| Gram                    | +                             | +                              |
| Hemolysis on blood agar | +                             | -                              |
| Catalase                | +                             | +                              |
| Oxidase                 | +                             | -                              |

The testing of isolates of *A. phocae* for antimicrobial susceptibility showed that isolates were susceptible to all the antibiotics available for treatment.

### 5.1.6 BACTERIOLOGICAL RESULTS (II)

Twenty three mink inoculated s.c./i.d./in artificially wounded skin with *A. phocae* developed signs and lesions. *A. phocae* was isolated in 19 skin samples of these mink; 17 in mixed culture and in two skin samples as a pure culture. Moreover, *A. phocae* could not be detected by culturing in four mink. Cultures were either overgrown with bacteria of the genus *Proteus* or abundant growth of bacteria belonging to the *Staphylococcus intermedius* group. However, *A. phocae* was detected by PCR in all mink with clinical signs and lesions (23/23). *A. phocae* was cultured from the skin sample of one mink which was inoculated, but had no clinical signs and lesions.

Seven out of eight mink inoculated (s.c./i.d. or artificially wounded skin) with a mixture of *A. phocae* and novel *Streptococcus* sp. developed signs and lesions typical for FENP. In cultures, *A. phocae* and novel *Streptococcus* sp. were isolated together in two samples, *A. phocae* was isolated alone in one sample and in three mink novel *Streptococcus* sp. was isolated alone. However, *A. phocae* was detected by PCR in all these samples (7/7). Both bacterial species were detected in the skin sample in the mink that had no signs and lesions. Four of these mink also had novel *Streptococcus* sp. growth in the internal organs (kidney, liver, spleen).

Three (3/6) mink infected with FENP-diseased tissue extract s.c./i.d./in artificially wounded skin in the main study developed signs and lesions. Novel *Streptococcus* sp. was found in cultures and *A. phocae* in PCR studies in all three mink. The novel *Streptococcus* spp. was also isolated from internal organs (liver, kidney, and lung) of two mink.

Low copy numbers for *A. phocae* were also detected by PCR in four clinically healthy control animals and in some mink inoculated perorally.

Blood samples taken before the main study showed antibodies towards *A. phocae* and novel *Streptococcus* sp. in two mink, indicating that one mink had been exposed to *A. phocae* and one to the novel *Streptococcus* sp. before inoculation.

### 5.1.7 VIROLOGICAL RESULTS (I)

No evidence of the presence of known important viral pathogens in the samples of FENP diseased animals was found in virological studies (table 16).

**Table 16.** Results of the virological studies (I)

| Test Method  | n         | Result  | Remarks                           |
|--|-----------|---|-----------------------------------|
| CDV-PCR*   | 95        | negative  |                                   |
| CDV antibodies   | 95        | negative  |                                   |
| AMDV antibodies  | 32        | negative  | Only mink tested                  |
| MEV-PCR  | 95        | 1 fox positive,   |                                   |
| MEV antibodies   | 95        | Both neg. and pos.<br>in foxes and Finnracons.<br>Antibodies found both in<br>FENP diseased animals and<br>healthy controls |                                   |
| Herpes-virus PCR   | 115       | Negative  |                                   |
| Virus culture  | 115       | Negative  |                                   |
| EM   | 12        | Negative  |                                   |
| PCR for poxvirus,<br>panpicorna, vesicular<br>stomatitis, panvesivirus<br>(calici) | 115<br>85 | negative  | No positive controls<br>available |

\* CDV=Canine Distemper virus, AMDV=Aleutian Mink Disease Virus, MEV= Mink parvovirus enteritis.

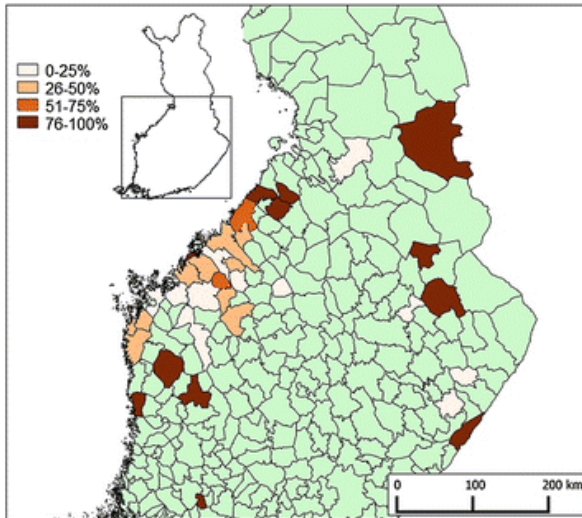
## 5.2 EPIDEMIOLOGIC STUDIES OF FENP (III)

### 5.2.1 COVERAGE OF THE RESPONDENT FARMS

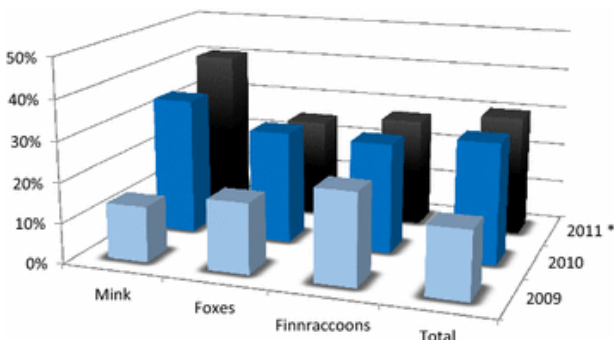
In total, 239 (25%) of the 956 farmers responded to the mail questionnaire. A comparison between study farms and farmers with all Finnish fur farms and farmers (information regarding all Finnish fur farms in 2010 was obtained from FFBA) showed that the study farms were representative for Finnish fur farms regarding farm type ( $p=0.7$ ), the age ( $p=0.3$ ) and the gender ( $p=0.96$ ) of the farmer (Fig. 2 in publication III). The study farms were located mostly in the fur farming area in Western Finland (94%), paralleling the geography of the Finnish fur farms in general (97%). The study farms were 18% mink, 45% fox, 1% Finnracons, and 36% mixed farms. The most frequent combination of mixed farms was foxes and mink (70% of the mixed farms), followed by foxes and Finnracons (17%), and 2.0% farmed mink and Finnracons and 11% farmed all three fur-animal species (Fig 1 in publication III). Most farms housed the animals in sheds, seven farms had both sheds and halls, only two farms housed all animals in halls. About 50% of the responding farms were located near other farms (under 500 meters apart) (Additional file 1 in publication III). The description of respondent farmers is shown in Figure 2 of publication III.

## 5.2.2 OCCURRENCE OF FENP IN THE STUDY FARMS

FENP had spread to all areas where fur farming was practiced in Finland during the study period (Fig. 23). Clinical signs of FENP were detected every study year and in all species. FENP was reported by 92 of the participating farms (40% of all included farms; 95% CI: 34-46%; 16 mink farms [39%; 95% CI: 26-54%], 25 fox farms [24%; 95% CI: 17-33%], and 51 mixed farms [61%; 95% CI: 50-70%]). An increase in the number of FENP-affected farms was seen during the study years (Fig.24).



**Figure 23.** Fur animal epidemic necrotic pyoderma (FENP) on participating farms. The geographic distribution of the farms and percentage of farms reporting FENP during the period from 2009 through 2011. Areas in green: no participants.



**Figure 24.** Occurrence of fur animal epidemic necrotic pyoderma (FENP) on Finnish fur farms. Occurrence of FENP in mink, fox, Finnracon and all study farms during the period from 2009 through 2011.

Overall, new animals were introduced in 89% of the farms during the study period, either as imports or of domestic origin; in 93% of the case farms and in 88% of the control farms. Imported animals were introduced in 24% of all the study farms of which 35% were case farms and 18% control farms (Additional file 1 in publication III).

Import of fur animals from Denmark was a statistically significant factor associated with disease presence in farms and was recorded in 24% of all case farms and 5% of control farms ( $p=0.001$ ). Nonetheless, importing from other countries did not increase the risk of occurrence of FENP significantly (table 1 in publication III).

Farms that had purchased from domestic sources alone had significantly more FENP than farms without any domestic purchases in 2009. However, when the entire study period was included, domestic purchases failed to significantly increase the risk (table 2 in publication III). The data demonstrates that case farms sold animals more frequently than control farms (37% vs. 28%, respectively), but the difference was non-significant ( $p=0.14$ ).

Quarantine was used in only 25% of all the importing farms and in 14% of the farms with domestic purchase. Animal premises were enclosed by a fence in 54% of the mink farms, 60% of the fox farms, and 86% of Finnraccoon farms. However, all farmers reported that birds and other wildlife were found on site of the farm area. For example, on farms with foxes, birds had been detected on the animal premises in 67% and other wild animals in 22% of the farms. Surprisingly, there were more reported observations of birds and wildlife on the animal premises on farms with fences, than on the farms without fences. In farms with mink, birds and other wildlife were seen significantly more on the fenced farms ( $p<0.0001$  and  $p=0.001$ , respectively) than on the farms without a fence. Birds were detected significantly more often on fenced fox farms ( $p<0.0001$ ). The farms were accessed by veterinarians (58% of farms), feed delivery-lorry drivers (58%), other farmers (50%), farm advisers (41%), feed lorries (84%), the vehicles collecting carcasses (67%), and vehicles collecting manure (54%) (additional file 1 in publication III).

Other diseases were also reported in the study farms. Sticky kits (42%), plasmacytosis (32%), and urolithiasis (25%) were the most common diseases in mink. The most common diseases in foxes were other eye infections than FENP (55%), fertility disorders (abortions 32%, metritis 23%), and cystitis (51%). In Finnraccoons, the most frequently observed diseases were parvovirus enteritis (11%) and abortions (11%). (Additional file 1 in publication III). Animals were treated by using injection of penicillin or tetracycline, lincomycin, and ivermectin (only fox and Finnraccoon) mixed in the feed (unpublished data).

The following procedures were performed on the study farms to treat FENP affected animals; medication, culling of all diseased animals without any medication, or both medication and culling. Penicillin as injections and tetracycline and lincomycin per orally were mostly used as medication. Ivermectin was given to foxes and to Finnraccoons as an antiparasitic treatment. According to the farmers' estimations, medication, particularly penicillin, had success in some FENP diseased animals. However, most of the farms reported that the FENP diseased animals were culled and only a few farms ( $n=31$ ) had used medication instead of culling.

Cleaning of the cages was a regular procedure on 30% of the study farms, whereas 19% of farms cleaned the cages only after a disease outbreak and 21% of the farms did not wash the cages under any circumstances. Only 7% of the study farms regularly disinfected the sheds, equipment, and cages on the farm, whereas 30% of the farms disinfected after a disease outbreak and 41% did not disinfect cages at all. The rest reported washing or disinfecting the cages after pelting, if needed or had left this question unanswered (all percentages, including missing answers are listed in the Additional file 1 in publication III)

In total, 94% of the study farms used commercial feed manufactured by the feed producers and only 4% fed with on-the-farm produced feed. Leftover feed on the cage was used for feeding other animals in 50% of mink farms, 19% fox farms, and 35% of mixed farms. Drinking water originated from public water supply systems and only 11% of the study farms reported to have private well. Drinking nipples were installed in more than 50% of the farms: 80% mink farms, 44% fox farms, and 68% mixed farms, respectively. The remainder used both nipples and cups or solely cups. Bedding material (like straw, saw dust, hay, shavings, turf) was used in mink nests (Additional file 1 in publication III).

Table 17 shows the distribution of the clinical symptoms of FENP reported by the respondents. The manifestations are well in line with the results of study I regarding the clinical signs of FENP and the pathological lesions.

**Table 17.** Observation of the clinical signs of FENP reported by the farmers of the farms included in the study, 2010.

| Clinical signs | Mink (n=32) |             | Fox (n=47) |             | Finnraccoon (n=6) |               |
|----------------|-------------|-------------|------------|-------------|-------------------|---------------|
|                | n           | (%; 95% CI) | n          | (%; 95% CI) | n                 | (%; 95% CI)   |
| Periocular     | 1           | (3; 0–16)   | 33         | (70; 56–81) | 0                 | (0; 0–39)     |
| Head           | 14          | (44; 28–61) | 26         | (55; 41–69) | 0                 | (0; 0–39)     |
| Paw            | 28          | (88; 72–95) | 2          | (4; 0–14)   | 6                 | (100; 61–100) |
| Other parts*   | 6           | (19; 9–35)  | 3          | (6; 0–17)   | 1                 | (17; 3–56)    |

\* Lesions detected in the other parts of the body than head, periocularly or in the paws.

### 5.2.3 RISK FACTORS FOR FENP IN THE STUDY FARMS

Import of fur animals was a significant risk of FENP (OR=2.3) compared to the farms without imports. A clear connection between the incidence of FENP on farm and imports from Denmark and Poland emerged, whereas imports from Norway and USA were not associated with increased risk of FENP (Table 18, additional file 2 in publication III).

The risk of FENP increased with the size of the farm. Mixed farms also had increased risk for FENP as compared to farms with only mink or only foxes. If one species on a mixed farm was affected by FENP, other fur animal species on the farm were more likely to be FENP-diseased, too. For instance, the 2009 data show that if a mixed farm with mink and foxes had FENP diseased mink or foxes, odds increased 22-fold that the other species were FENP-diseased too, compared to mixed farms with no diseased species on farm. Wildlife contacts in mink farms increased the risk of FENP (OR=6.7). Farms enclosed by fences had higher OR for FENP than farms with no fences (table 18).

The study showed that sticky kits exhibited a significant positive association and plasmacytosis in mink exhibited a negative association with development of FENP. FENP was not associated with feed producer, the use of different feeding procedures, or water source. Farms using hay as the bedding material in mink nest boxes had lower risk for FENP (OR=0.3) than farms using other bedding material (table 18). The risk of FENP did not differ between different cleaning and disinfection routines or vaccination routines on the farm. Symptoms of FENP were recorded in all color types of mink, but least in the brown color types. Blue foxes were at higher risk for FENP than other genotypes.

**Table 18.** The crude odds ratios of relevant risk factors for fur animal epidemic necrotic pyoderma (FENP)

| RISK FACTOR  | Case farms<br>(n=92) |                        | Control farms<br>(n=134) |                        | OR (95% CI)    |
|--|----------------------|------------------------|--------------------------|------------------------|----------------|
|  | Exposed<br>(n)       | Non-<br>exposed<br>(n) | Exposed<br>(n)           | Non-<br>exposed<br>(n) |                |
| <b>All farms</b>   |                      |                        |                          |                        |                |
| <b>Farm type</b>   |                      |                        |                          |                        |                |
| Mixed farm vs. mink farm   | 51                   | 33                     | 16                       | 24                     | 2.3 (1.1–5.0)  |
| Mixed farm vs. fox farm  | 51                   | 33                     | 25                       | 74                     | 4.6 (2.4–8.6)  |
| <b>Purchases</b>   |                      |                        |                          |                        |                |
| Domestic purchases   | 86                   | 2                      | 118                      | 15                     | 3.7 (0.8–17.1) |
| All imports combined   | 32                   | 56                     | 24                       | 96                     | 2.3 (1.2–4.3)  |
| Imports from Denmark   | 17                   | 71                     | 3                        | 117                    | 9.3 (2.6–33.0) |
| Imports from Poland  | 10                   | 78                     | 2                        | 118                    | 7.6 (1.6–35.5) |
| <b>Drinking system</b>   |                      |                        |                          |                        |                |
| Cup  | 22                   | 68                     | 58                       | 72                     | 0.4 (0.2–0.7)  |
| Nipple   | 67                   | 23                     | 66                       | 64                     | 2.8 (1.6–5.1)  |
| <b>Farms with mink</b> (including mixed farms)                           |                      |                        |                          |                        |                |
| Fence around the mink premises   | 38                   | 19                     | 21                       | 28                     | 2.7 (1.2–5.9)  |
| Access by birds to shelter buildings                                     | 25                   | 34                     | 10                       | 38                     | 2.8 (1.2–6.7)  |
| Access by wild animals to shelter buildings                              | 13                   | 42                     | 2                        | 43                     | 6.7 (1.4–31.3) |
| Size of the farm: >750 vs. ≤750 breeder mink                             | 39                   | 13                     | 19                       | 24                     | 3.8 (1.6–9.0)  |
| Hay as bedding material  | 9                    | 48                     | 18                       | 31                     | 0.3 (0.1–0.8)  |
| Pre-weaning diarrhea   | 31                   | 30                     | 15                       | 34                     | 2.3 (1.1–5.2)  |
| Plasmacytosis  | 13                   | 48                     | 23                       | 26                     | 0.3 (0.1–0.7)  |
| <b>Farms with foxes</b> (including mixed farms)                          |                      |                        |                          |                        |                |
| Access by wild animals to shelter buildings                              | 22                   | 44                     | 18                       | 75                     | 2.1 (1.0–4.3)  |
| Size of the farm: >320 vs. ≤320 breeder foxes                            | 44                   | 20                     | 44                       | 54                     | 2.7 (1.4–5.2)  |
| <b>Mixed farms</b>   |                      |                        |                          |                        |                |
| Size of the farm large vs. small<br>(based on the most numerous species) | 26                   | 18                     | 13                       | 19                     | 3.0 (1.2–7.9)  |
| Fence around mink premises   | 33                   | 9                      | 12                       | 13                     | 4.0 (1.4–11.7) |

Number (n) and crude odds ratios (OR, with only one factor in the logistic regression model at a time) for the most prominent risk factors for FENP. (Table 18 is used in publication III) The results of the multivariable analyses are listed in table 19. FENP was associated with the farm type, import from Denmark and Poland, access for birds and wildlife to the farm area, the drinking system, and the farm size.

Model 1 is the best model for all farms according to goodness of fit statistics and included the variables “farm type,” “imports from Denmark,” and “imports from Poland”. Model 2 is the best model for mixed farms and includes the variables “bird access to mink farm” and “nipple drinking system.” Model 3 is the best model for all mink and includes the variables “imports to the farm during 2009–2011,” “size of the farm,” and “wildlife access to mink farm.” Model 4 is the best model for all

farms with foxes and includes the variables “farm type,” “wildlife access to mink farm,” and “nipple drinking system.”

All of the variables included in the models were significant risk factors for FENP, except in model 1 for the variable “farm type” when comparing mink farms to fox farms. No interactions and only a slight multicollinearity between the variables included in the models were detected. Severe multicollinearity was found between the use of fences and wildlife and bird access to animal shelters, indicating a strong association.

**Table 19.** Multivariable logistic regression analyses of significant risk factors for fur animal epidemic necrotic pyoderma (FENP)

| Model               | Cases (n) /  |  | OR (95% CI)               | Goodness-of-fit statistics |       |       |
|---------------------|--------------|--|---------------------------|----------------------------|-------|-------|
|                     | controls (n) | Risk factors                           |                           | Test                       | Value | p     |
| Model 1             | 88/118       | Farm type:                             |                           |                            |       |       |
|                     |              | Mink farm vs. fox farm                 | 1.3 (0.5–3.1)             | McFadden's R <sup>2</sup>  | 0.147 |       |
|                     |              | Mixed farm vs. fox farm                | 3.8 (1.9–7.6)             | Cox-Snell R <sup>2</sup>   | 0.182 |       |
|                     |              | Imports from Denmark                   | 6.0 (1.6–22.8)            | Pearson                    | 0.721 | 0.608 |
|                     |              | Imports from Poland                    | 7.2 (1.4–37.3)            |                            |       |       |
| Model 2             | 42/23        | Access by birds                        | 4.6 (1.2–16.8)            | McFadden's R <sup>2</sup>  | 0.188 |       |
|                     |              | Nipple                                 | 8.4 (2.0–35.0)            | Cox-Snell R <sup>2</sup>   | 0.217 |       |
|                     |              |  |                           | Pearson                    | 0.411 | 0.675 |
| Model 3             | 42/34        | Imports                                | 5.3 (1.6–18.0)            | McFadden's R <sup>2</sup>  | 0.241 |       |
|                     |              | Access by wildlife                     | 13.6 (1.5–121.0)          | Cox-Snell R <sup>2</sup>   | 0.282 |       |
|                     |              | Size of the farm<br>>750 vs. ≤750 mink | 3.1 (1.0–9.0)             | Pearson                    | 0.561 | 0.847 |
| Model 4             | 65/90        | Mink farm vs. fox farm                 | 4.5 (2.1–9.4)             | McFadden's R <sup>2</sup>  | 0.179 |       |
|                     |              | Access of wildlife                     | 2.3 (1.0–5.4)             | Cox-Snell R <sup>2</sup>   | 0.216 |       |
|                     |              | Nipple                                 | 3.3 (1.6–7.0)             | Pearson                    | 0.658 | 0.621 |
| Model 1 = all farms |              | Model 2 = mixed farms                  | Model 3 = farms with mink | Model 4 = farms with foxes |       |       |

Number (n) of case farms and control farms in the model and odds ratios (OR) of the variables included in the model. In all of the goodness-of-fit tests, a test value of 1 indicates a particular well-fitting model; a Pearson's value p<0.05 indicates a model which should be rejected. The variable “farm type” has three categories: mink, fox, and mixed farms where fox farms serve as the reference group. Table 19 is used in publication III.



#### **5.2.4 GENERAL INFORMATION OBTAINED FROM THE SURVEY STUDY OF FINNISH FUR FARMS**

Vaccination against botulism, *Pseudomonas aeruginosa* and parvovirus enteritis is a prerequisite for certification criteria for mink farms in the Finnish certification system. Thus, the mink study farms had vaccinated mink with the triple vaccine in 91% of the mink farms. Vaccine against parvovirus and distemper is delivered by a bivalent vaccine and was used in 9% of the farms, almost exclusively in farms importing animals in order to protect the breeder animals against distemper. There was no vaccine solely against distemper available in Finland at the time of study. The Finnish certification system does not require vaccinations for foxes or Finnraccoons. However, nearly a quarter (24%) of fox farms and 60% of the Finnraccoon farms were vaccinated against parvovirus. The vaccination site, however, was not specified in the questionnaire. Manure was composted in 58% of the farms and used as a fertilizer. Carcasses and culled fur animals in Finland are destroyed by burning either on the farm in incinerators (7%) or collected by Honkajoki Oy for rendering. The carcasses were stored in freezers or cold rooms before sending them for destruction in 83% of the study farms. However, in remote parts of Finland it is allowed by legislation to establish burial sites and this procedure was used in 4% of the farms.

## 6 DISCUSSION

### 6.1 FUR ANIMAL EPIDEMIC PYODERMA

The main product of fur farming is the fur coat, thus any damage resulting in loss of the quality of the skin and fur has a direct influence on the revenue and ultimately the income of the fur farmer. Diseases also have a negative impact to the health and wellbeing of animals; the welfare of most diseased animals is reduced and absence of disease is an important part of animal welfare (Broom, 1986). Freedom of injuries, pain, and diseases is one of the “five freedoms” stated by the Farm Animal Welfare Council to ensure wellbeing of animals (Farm animal welfare council, 1992). The ways that animals are used for human benefit are currently under discussion. The welfare of fur animals has also been in focus repeatedly. FENP negatively affects the health of fur animals by causing painful skin and eye lesions as well as systemic signs, hence it is an important welfare issue in fur animal farming. It is crucial to investigate the cause and predisposing factors of FENP on the fur farms for developing control procedures, including diagnostics, treatments and preventive methods for FENP, in order to secure fur-animal welfare.

#### 6.1.1 CHARACTERISTICS OF FENP

Fur Animal Epidemic Necrotic Pyoderma (FENP) is a descriptive term for the clinical signs, pathological lesions, and the contagious nature of the disease. FENP affected all fur animal species farmed in Finland and it rapidly spread between and within fur farms and on the farms. The clinical signs of FENP diseased animals, in addition to the gross and histopathological lesions (described more in detail in results of study I) proved that necrotizing pyogenic inflammation of the skin (pyoderma) was a common feature in all FENP diseased species. In our microbiological studies, confirmed in experimental infection, we identified the bacterium *Arcanobacterium phocae*, as a possible causative agent in the pathogenesis of FENP. This bacterium had not previously been reported in fur animals.

Dermatitis in fur animals has previously not been known to be contagious, even though it may occur seasonally, as in infected biting wounds among growing kits (Jespersen et al., 2016). FENP differs from previously known bacterial fur-animal skin-diseases as it spreads epidemically. Pyodermas in small animals seldom are contagious, however, livestock are known to have contagious pyodermas, such as contagious foot rot of ruminants (Abbot and Lewis 2005)

Necrosis is a distinct finding in FENP diseased animals. Necrosis in general is a result of cell death, commonly caused by hypoxic cell injury, bacterial toxins, irritating and toxic compounds, trauma, or exposure to very cold temperatures. Cell necrosis evokes the inflammatory response, contrary to cell apoptosis (Zutterman et al., 2010). Vasculitis with thrombosis which could have led to necrosis of the skin tissue was detected in mink (I). The pathogenesis of vasculitis varies between diseases and can be caused by bacterial toxins. Shiga-like-toxin II, produced by *E.*

*coli*, causes fibrinoid necrosis of small arteries and arterioles in edema disease of pigs' (Gannon et al., 1989). Vasculitis is also seen in other bacterial infections such as erysipelas in swine and in viral diseases such as in feline infectious peritonitis (Kipar and Meli, 2014). Parasite diseases, such as equine strongylosis (Bishop, 1989) and immune-mediated diseases such as Aleutian disease in mink (Porter et al., 1973) are also known to manifest with vasculitis.

The inflammation detected in mink and foxes in this study were superficial to deep pyoderma involving the epidermis, dermis, and subcutis, whereas in Finnraccoons, abscesses were detected in the dermis and subcutis. Pyodermas are of bacterial origin, which is consistent with the hypothesis of *A. phocae* as a causative pathogen of FENP. Skin diseases including pyodermas in small animals are currently a common cause to attend veterinary care. Antimicrobials have widely been used to treat these patients, and a risk of antimicrobial resistance has emerged. Bell et al. (2016) isolated *mec-A*- positive multidrug resistant *Staphylococcus pseudointermedius* (MRSP) from a pyoderma of a dog in New Zealand. Infections with MRSP are a major problem at veterinary clinics globally, also creating a considerable public health concern (Bell et al., 2016). Therefore, when planning effective treatment strategies for bacterial fur animal skin diseases, the development of antimicrobial resistance should be considered.

#### **6.1.1.1 Predilection site**

The lesions caused by FENP in mink and foxes seem to have a predilection to mucocutaneous junctions, which in mink are around the nares, the eyes, the ears, in the corner of the mouth and around the nail beds. The FENP lesions in foxes are found in the mucocutaneous junctions of the eyelid and occasionally around the ear or the nail bed. Many diseases manifest in mucocutaneous junctions. It is the junction where epidermis of the skin transforms to the epithelium of the mucous membrane. At these sites, the cell layers are commonly thinner and the protection of the fur have diminished or even completely vanished (Bacha and Bacha, 2006), thus making the tissues more sensitive and vulnerable. Typical lesions in orf infection in sheep are first detected in mucocutaneous junctions of the mouth, usually initiated by abrasions from pasture grasses or forage (Haig and Mercer, 1997).

Mucocutaneous pyoderma of putative bacterial origin occurs in dogs. It affects a variety of breeds, but the German shepherd is thought to be predisposed. Lesions develop in the lips, the nasal planum, the nares, the perioral skin and less commonly, the eyelids, the vulva, the prepuce, and the anus in affected dogs. The pathogenesis and the etiology of this disease are still unknown (Bassett et al., 2004, Gortel 2013). A similar disease entity, an antibacterial-responsive mucocutaneous disease has also been reported in a rabbit. Lesions were detected in the mucocutaneous junctions of the lips, the nares and the vulva; bilaterally severe periocular dermatitis was also present (Benato et al., 2013). Despite some differences, similarities in clinical signs (crusting, ulceration) and histology (neutrophilic pustules, deeper lympho-plasmasytic inflammation, folliculitis) between FENP and mucocutaneous pyoderma exist and these diseases may belong to the same disease entity.

Various autoimmune diseases, in which autoantibodies target epidermal, epithelial or basement membrane antigens, manifest in the mucocutaneous junctions. Mucous membrane pemphigoid, bullous pemphigoid, epidermolysis bullosa acquisita, and cutaneous lupus (type I bullous systemic lupus erythematosus and vesicular cutaneous lupus erythematosus) have been reported in domestic animals (Olivry and Jackson, 2001). However, it is improbable that large number of animals of three different species on separate farms would develop an autoimmune disease concurrently and no diagnostic findings support this theory.

### **6.1.1.2 Fur animal species specific presentation**

Although the lesions of FENP seem to occur in mucocutaneous junctions, the location slightly differs in different species. Mink are active and exploratory by nature and readily use occupational materials in the cages (Hansen, et al. 2007). They climb willingly on the cage structures and chew any objects in the cage, which may predispose them to developing small abrasions, especially in non-furred areas around nails and in the mucous membranes of the mouth. FENP is also seen in mink feet around nails after blood sampling for plasmacytosis testing (blood samples are gathered by clipping the nail (Knuuttila et al., 2009), indicating that trauma to the nail structures when clipping too deep may act as an infection route to FENP. Stress is known to predispose animals to the diseases (Moberg, 2000) and the stress caused by handling the animals during nail clipping might also act as a predisposing factor to FENP. Likewise, handling the animals may cause the spread of *A. phocae* between the mink by the gloves and clothes of the farmer during blood sampling. Blood sampling by clipping the nail is not performed in Finnraccoons and foxes.

FENP lesions in foxes are mostly detected in the eyelids. The very massive, thick fur coat is sought in raising foxes. The irritation of the hair to the conjunctiva is more prominent in the fox than in mink which have very short fur. The structure of the eyelids of foxes also differs from minks and deformations of the fox eyelid (Kempe and Strandén, 2016) are more common. In FENP-affected fox, ectopic cilia and entropion were detected indicating that mechanical irritation to the conjunctiva may predispose to FENP. The lesions in Finnraccoon paws resemble furunculosis (interdigitalpyoderma) seen in some dog breeds. The short bristly hair between toes of dogs may predispose to the disease (Fraser, 1991). Compared to fox, the Finnraccoon paw is narrower and the toes are less splayed, thus in closer contact with each other (personal observation). The pressure of the bodyweight on the cage structures is applied to a smaller area in Finnraccoon paw, which hypothetically could cause more trauma to the interdigital space. The hair in the Finnraccoon paws may also be rougher than in fox paws, which may predispose to the development of furuncles.

### **6.1.1.3 Systemic signs**

Farmers have reported mortality due to FENP for all farmed fur animal species. Anorexia, lethargy and depression are the most often reported clinical signs occurring simultaneously with skin or eye lesions (I). Splenomegaly and enlarged local lymph nodes were detected in necropsied mink and Finnraccoons (I). The spleens were of a firm and meaty texture, and congestion was absent. Common causes of uniform splenomegaly are bacteraemia and low-grade septicaemia, as well as chronic infections, which are mostly bacterial or fungal in origin. Large lymph nodes have mostly been seen in acute and chronic lymphadenopathies (Valli et al., 2015). The findings in study I are well in line with the bacterial origin of FENP. However, *A. phocae* was rarely isolated from these organs (I) even though it was isolated from the infected skin, and the histopathology revealed predominantly non-specific reactive changes instead of splenitis or lymphadenitis. These observations could indicate a toxin-based pathogenesis in FENP-affected animals with severe systemic signs. In human skin and soft tissue inflammations, the bacterial toxins are known to have an important role in the development of systemic signs (Ki and Rotstein, 2008). Endotoxins are lipopolysaccharide chains in Gram negative bacterial cell walls. They cause the release of chemokines and they enhance T-lymphocyte activation. Massive elaboration of liposaccharides may lead to an overstimulation of host immune and inflammatory systems.

Exotoxins, secreted by both gram positive and negative bacteria may cause tissue damage: through enzymatic reactions, cellular dysregulation or pore formation, with subsequent cell lysis. The massive release of cytokines causes a grossly exaggerated inflammatory response (Ki and Rotstein, 2008, Ramachandran, 2014). More severe systemic signs are also encountered in canine toxic shock syndrome and necrotizing fasciitis due to Streptococcal or Staphylococcal infection (Prescot et al., 1997).

Bacteria phylogenetically and closely related to *A. phocae* are known to produce toxins that have an important role in their pathogenesis. *A. haemolyticum* produces a toxin, phospholipase D, which is responsible for bacterial adhesion and host cell necrosis after the bacterial invasion (Lucas et al., 2010). A toxin encoding gene, *phl* (phocaelysin) has been found in the genome of *A. phocae* (Ülbeği, 2010), although the toxin itself still needs to be described. *Phl* gene of *A. phocae* is comparable to the pyolysin encoding gene of *Truberella pyogenes* (formerly known as *Arcanobacterium pyogenes*). Pyolysin (PLO) is a member of the cholesterol-binding pore-forming family of toxins (PFT) and it has haemolytic and cytolytic effects for immune cells, including macrophages (Jost and Billington, 2005). *T. pyogenes* is related to miscellaneous pyogenic infections in animals, including mastitis, abscesses, pneumonia, and lymphadenitis (Ribeiro et al. 2015). The phocaelysin of *A. phocae* may play an important role in the pathogenesis of FENP, since it could be responsible of the necrosis as well as of the rapid development of the signs. Toxin(s) could also account for the observation that the animals dying in FENP do not commonly reveal bacteria in the internal organs in bacteriological studies. The existence of a toxin offers an opportunity and potential for producing a vaccine for controlling FENP in the future. Indeed, promising results in the experimental studies of combined DNA vaccines against *T. pyogenes* have already been achieved (Huang et al., 2015).

In addition to systemic signs, farmers have reported that litter sizes (the number of pups born per litter) had diminished from the breeding season prior to the appearance of the clinical symptoms of FENP on their farm (I). There are bacterial diseases such as listeriosis that cause infertility problems in farm animals. Inflammation of the placenta and the fetus may lead to infertility and abortions. In addition, the negative effect on fertility could also be caused by the systemic signs, such as fever. The presence of barren animals on the farm is usually not detected before the expected time of whelping. Therefore, the initiating insult to reproductive problems occurring at the beginning or during the gestation may no more be evident at whelping time. The clinical signs of FENP are mostly detected in the autumn and winter, however, not during gestation or at whelping time. It is possible that the reproductive problems and occurrence of FENP are due to same predisposing factors such as environmental factors or poor management procedures. Bacteria belonging to the genus *Arcanobacterium*, have been associated with genital infections and abortions; *A. pluranimalium* has been isolated from ovine abortion material and semen (Foster et al., 2011) as well as *A. phocisimile* from vaginal samples of harbour seals (Hijazin et al., 2013). Hence, the influence of *A. phocae* infection in the reproductive disorders of fur animals requires further investigation.

#### **6.1.1.4 Potential infection route**

Histopathological lesions in field cases often consist of ulceration of the epidermal layer. The signs are also detected in mink after nail clipping and in foxes with conjunctival irritation. Ulceration of epidermis and conjunctiva diminishes the defense mechanisms of the tissues and offers an infection route to the opportunistic pathogens (Mauldin and Peters- Kennedy, 2015). In the experimental infection, signs were detected when the bacteria were inoculated intradermally, subcutaneously, or to artificially wounded skin, but not in mink infected perorally, suggesting that trauma to the skin predisposes to

FENP. In dogs, deep pyodermas are mostly due to wounds penetrating through skin layers, but superficial pyodermas may have either hematogenous or external origin (Mauldin and Peters- Kennedy, 2015). The primary origin of FENP has probably been seal meat used in the mink feed (Bröjer, 2000). This would be indicative of a peroral infection route. A mucocutaneous infection route through small abrasions in the mouth could also be likely. In addition, mink are fed within their cage structures, and some feed usually remains on the surface of the cage wires, thus feed deposits come into contact with the feet. The more frequent occurrence of symptoms in Canadian heavier breeder males could also implicate that a split callus on the surface of the foot could have created an infection route between feet and *A. phocae* contaminated cage wires and flooring.

In the Netherlands, Molenaar et al. (2017) studied postvaccinational wounds in mink. They detected severe necrotizing to necropurulent dermatitis in the vaccination site and isolated *A. phocae* from postvaccinational wounds. This is a further evidence that penetration of the skin tissue predisposes to FENP by providing an infection route to *A. phocae*. Molenaar et al. suggest that vaccination procedures should be considered carefully at farms with FENP.

#### **6.1.1.5 Demography of FENP**

FENP seems to affect males and females equally in Finland (I). However, in the author's personal experience and that of other veterinarians treating farmed fur animals in recent outbreaks in Finnish blue fox farms, the breeder males seem to be more affected than females. The more massive hair coat and folded skin of the head of breeder male foxes may cause more irritation to the conjunctiva and predispose to FENP. Breeder mink males in Canada are also more often affected and the heavier body weight and profound mechanical stress to footpads has been speculated to predispose to pododermatitis (Bröjer, 2000). On the other hand, a Spanish study found that FENP was predominantly detected in females (Fernández-Antonio, 2008). There is a variation in female-male ratio on fur farms, as females predominate in the breeding season. After mating time (March) many of the breeder males are pelted and the number of males is altogether decreased. Females in general have enhanced immunoreactivity which provides better protection against infections, but immunoreactivity may also lead to enhanced autoreactivity and thereby contribute to the induction of autoimmune diseases (Zandman-Goddard et al., 2007). Regarding the pathogenesis of FENP, the gender of the animal is probably not a crucial factor, but the predisposing factors to FENP may differ in males and females.

FENP is seen in Finland mostly among young animals, although older breeder animals are occasionally affected as well. In general, when infectious disease enters a naïve population, animals of all ages may be equally susceptible because specific immunity towards the disease is lacking. The animal density is maximal just prior to pelting time when a majority of the animals are juveniles, under seven months-old. The high density of young animals without protective adaptive immunity may also create a favorable situation for contagious infectious diseases.

#### **6.1.1.6 Treatment trials**

Various medication trials have been conducted on Finnish fur farms to treat FENP-diseased animals. The lesions detected in foxes resemble those detected in sarcoptic mange, which sometimes affects the whole fox farm. Hence, before the diagnosis of possible bacterial

etiology of FENP was established, antiparasitic medication was administered in some cases. However, medication trials with antiparasitic medications did not eliminate the detected signs and no parasites were detected in the skin samples, which indicated that parasitism was not directly involved in the etiology and pathogenesis of FENP. Antibiotic treatment given as injections and in large doses after the symptoms were first observed was able to decrease the symptoms of FENP in some cases. The positive effect of antibiotic treatment given at an early stage further supports a bacterial etiology of FENP. However, relapses were common after treatment and the disease seemed to spread amongst the animals indicating that the causative agent and predisposing factors still persisted on the farms. The profound necrosis seen in more advanced cases probably diminishes the effect of antibiotics as the blood circulation is impaired in the inflamed tissue due to the necrosis. The relapses observed in treated animals could also suggest: 1) a secondary bacterial inflammation, if a primary pathogen, such as a virus, persists; or alternatively 2) developing antimicrobial resistance. However, no resistance has been detected hitherto in the antibiotic susceptibility tests of *A. phocae* strains isolated from fur animals and in the microbiological studies, *A. phocae* is proved to be sensitive to all used antibiotics in laboratory conditions.

The results of the epidemiologic study (III) also indicated that antibiotic treatment diminished clinical signs and made even healed some animals. However, relapses are common and therefore medicated animals may remain a potential risk for spreading of FENP. Therefore, farmers are advised to cull animals presenting severe symptoms and treat only animals with mild to moderate symptoms to avoid pain and distress suffered by the animals and to avoid the spread of *A. phocae*.

### 6.1.2 ETIOLOGY OF FENP

Similar symptoms, “pododermatitis”, in mink have been detected in North America, in the U.S.A in the early 1970s and in Canada in 1996 (Bröjer, 2000). The onset of symptoms in Canada was noticed by farmers and later confirmed in an epidemiologic study, to be linked to the initiation of use of seal by-products as an ingredient of feed for mink (Bröjer, 2000). The conclusion of the Canadian research was that the disease was due to yet unknown etiology with secondary bacterial inflammation. In our bacteriological examination, confirmed by PCR, *A. phocae* was isolated from FENP diseased animals in every species. *A. phocae* is a gram-positive bacterium and belongs to the genus *Arcanobacterium* of family *Actinomycetaceae* (Collins *et al.* in 1982). The finding of *A. phocae* was extremely interesting as it has previously been detected in suppurative skin lesions in marine mammals, such as seals, (Ramos *et al.*, 1997; Johnson *et al.*, 2003) and the link was observed earlier in North America with seal byproducts in feed (Bröjer, 2000). Previously unknown bacteria belonging to genus *Streptococcus*, a novel *Streptococcus* sp. was also detected in some FENP diseased animals, especially in mink and Finnraccoons. The novel *Streptococcus* sp. also seemed to be closely related to *Streptococcus* of marine origin, such as *Streptococcus halicoeri*. These results suggest a potential species shift of these bacteria from marine mammals to mink. Seal by-products as raw ingredients of feed given to farmed fur animals have probably served as an origin and primary source of the FENP epidemic in North-America. However, seal meat is no longer an obligatory source for the transmission of FENP infection as pathogens have transferred from marine to terrestrial mammals and the causative agent is currently transmitted between fur animals. Therefore, the disease occurs in countries and on farms with no history of seal meat utilization. Recently, Canadian researchers reported an association between *A. phocae* and

pododermatitis in Canadian farmed mink (Chalmers et al. 2015). *A. phocae* was consistently found on endemic farms with pododermatitis and at higher levels in infected footpads than in healthy tissues. Many human infectious diseases originate from animal sources, indicating a species shift between animals and humans. Wolfe et al., (2007) presented five stages through which a pathogen exclusively infecting animals may become transformed into a pathogen that exclusively infects humans.

Many pathogens are also known to have an ability to infect multiple hosts, including hosts in a variety of taxonomic orders (Cleaveland, et al., 2001). Various zoonotic pathogens; viruses (Kallio-Kokko et al., 2005), bacteria (Blancou et al., 2005), fungi (Taylor et al., 2001), and parasites (Schantz, 1991), are examples of agents that affect different species. There is evidence that a marine mammal and domestic swine share a pathogen. For instance, after experimental infection with *Elysipelothrix rhusiopathie* that was isolated from a harbor seal (*Phoca vitulina*) skin lesions, typical signs for erysipelas were induced in swine (Opriessnig et al., 2013). There is also evidence that the bacterium *Lawsonia intracellularis*, which is a pathogen causing diarrhea in swine, has been transmitted to blue foxes, a species in which it also causes proliferative enteritis (Kallio and Ahola, 2012). It is possible that the use of un-cooked or un-acidified infected intestines of swine as a raw ingredient of feed has caused species shift between these animals.

#### **6.1.2.1 Subclinical infections**

*A. phocae* was also occasionally detected in Finn raccoon controls (Study I), which originated from a farm without a reported FENP. However, one of the Finn raccoon controls presented typical gross and histopathological lesions of FENP and *A. phocae* was detected in the affected tissues. All the healthy controls of Finn raccoon originated from one farm, and after the study that farm became heavily affected by FENP. It is likely that the infection had already been introduced onto the farm and hence influenced the results of the healthy Finn raccoon controls. The clinically healthy Finn raccoon controls had no pathological lesions or presence of *A. phocae* in cultured samples, but some of them presented low numbers of *A. phocae* in the PCR studies. Samples taken from clinically healthy mink from the affected farms showed the presence of *A. phocae* at low levels in PCR studies. The results imply that these asymptomatic animals that have *A. phocae* may act as carriers and spreaders of the FENP. It is also important to emphasize that the presence of the *A. phocae* bacteria *per se* in these findings may not be sufficient to evoke FENP, which would imply that *A. phocae* is merely an opportunistic pathogen of fur animal skin. Other predisposing factors, such as skin/mucocutaneous trauma or other pathogens, may be needed to evoke FENP. This phenomenon is seen in marine mammals, where *A. phocae* is usually isolated from a wound or traumatized tissue in mixed inflammations (Ramos et al., 1997, Johnson et al. 2003).

#### **6.1.2.2 Synergetic pathogens**

*A. haemolyticum* has been suggested to have synergic effects with other bacteria (Dobinsky et al., 1999). *A. phocae* is often isolated from mixed inflammations along with the novel *Streptococcus* sp., in diseased tissues of mink and Finn raccoons. Similarly, *A. phocae* predominantly occurs in foxes along with *Streptococcus canis* or with the novel *Streptococcus* sp. In cases of pododermatitis *A. phocae* is isolated in mixed inflammation with *S. delphini* and *S. canis*. This strongly indicates that the pathogenesis of *A. phocae* may



have synergistic effects with other bacteria. However, the role of the novel *Streptococcus* sp. in the pathogenesis of FENP is still somewhat indefinite. The experimental infection (study II) showed that *A. phocae* was able to cause typical signs of FENP as the sole inoculum. Moreover, no clear difference was evident between the severity of signs and lesions in the groups infected only with *A. phocae* or a mixture of *A. phocae* and the novel *Streptococcus* sp.. The inoculation of mink with the novel *Streptococcus* sp. alone would have elucidated the role of this bacterium in the pathogenesis of FENP.

### **6.1.2.3 Searching for a virus**

The contagious nature, and the fast development, of high level morbidity and some of the primary signs detected in FENP were suggestive of a viral etiology of FENP. A serous discharge from the eyes and the vesicles on the third eyelid detected in foxes are typically lesions of viral diseases, such as herpesvirus-induced Feline herpetic keratitis, where the first manifestation is a serous discharge from the eyes (Andrew, 2001), or as vesicles detected in Foot and mouth disease (FMD) (Kitching, 2002). In some histopathology samples of mink, structures resembling viral inclusions were also detected. Viruses belonging to the family of *Poxviridae* are epitheliotropic DNA viruses (Mauldin and Peters-Kennedy, 2015), such as Contagious pustular dermatitis (orf) in sheep, which causes lesions in commissures of the mouth, oral mucosa, lips, eyelids, and feet. The vesicle stage in orf is short and clinical signs are mild so they may be easily overlooked. The subsequent pustule stage is more prominent and clinically evident (Haig and Mercer, 1997). Other viruses, such as herpesviruses, picornaviruses, rhabdoviruses (vesicular stomatitis), and caliciviruses (vesicular exanthema) are known to cause cutaneous lesions as well (Mauldin and Peters-Kennedy, 2015). The signs of FENP could be a presentation of the secondary bacterial inflammation stage following a viral infection. However, in our studies of FENP including PCR, cell culturing, and electron microscopy, no viruses were revealed and in our experimental studies typical symptoms of FENP were induced when mink were infected with inocula of *A. phocae*. Many samples in this study presented long-standing chronic changes. The chronicity might have hidden the possible participation of viral pathogens as co-factors of FENP in early stages of the disease. Thus, further studies are still needed to find or rule out the possible viral pathogens involved in the pathogenesis of FENP. However, even though there might be a virus associated with the pathogenesis, the significance of *A. phocae* in pathogenesis of FENP remains indisputable.

### **6.1.3 EXPERIMENTAL INFECTION OF *A. PHOCAE* IN MINK**

The experimental infection setup proved that *A. phocae* alone or together with the novel *Streptococcus* sp. can cause FENP in mink (II). The infection resulted in lesions that macroscopically and histopathologically resembled those detected in clinical cases of FENP by inoculating mink subcutaneously/intradermally or by an artificially created wound with cultures of *A. phocae* alone or in combination with novel *Streptococcus* sp., or as a tissue extract from a FENP-diseased mink.

It was difficult to determine the correct infection dose in the experimental protocol. The used doses were probably too low in pilot study 1, as no lesions were detected, whereas they were too high in pilot study 2. Although the doses used in the main study were lower than in pilot study 2,

the subsequent clinical signs were acute, such as sudden apathy, anorexia, and lethargy, leading to death or euthanasia of the study animals. No chronic lesions developed in study II. The bacterial inocula used in pilot study 1 were prepared at UH and the long transportation time may have influenced the viability of the bacteria. The inocula used in pilot study 2 and in the main study were prepared in Epira in Seinäjoki, which was much closer to the experimental farm site. The problem in choosing a correct infection dose was further complicated by the sudden change in weather conditions, as the temperature dropped to below  $-20^{\circ}\text{C}$  during the main study. Cold weather may have acted as an extra stress factor, which influenced the outcome and severity of FENP. This is in line with observations of the clinical cases of FENP as a peak in FENP in foxes was seen in winter when the temperature drops below  $-20^{\circ}\text{C}$ . Even though fur animals are well adapted to a cold climate, the temperature extremes and abrupt changes in weather may cause thermal stress to the animals. Thermal stress is known to cause many physical and physiological alterations in mammals (Sanin et al., 2016). In Poland, the signs of FENP are believed to be tempered by adding extra bedding material to mink nests (personal communication from polish farmers and veterinarians). Extra bedding material improves the insulation capacity of the nest box and thus diminishes the thermal stress in mink.

An infection trial conducted later in Denmark strengthened our conclusions about the role of *A. phocae* and novel *Streptococcus* sp. in the pathogenesis of FENP, as their results indicated a dose dependent pathogenicity of *A. phocae* and *Streptococcus halichoeri* in mink. The results also indicated a possible synergistic effect between *A. phocae* and *S. halichoeri*, as greatly increased severity of clinical symptom development was achieved in animals that received a high dose of combination of *A. phocae* and *S. halichoeri* (Hammer et al., 2016).

#### **6.1.3.1 Spontaneous spread of *A. phocae* in the experimental unit**

The bacteria were also detected by PCR at low levels in non-inoculated asymptomatic control animals sampled at the end of the study II, which indicates that the mink were either: 1) resistant to the infection; 2) had acquired immunity; 3) had no disease because the predisposing factor was lacking (such as skin trauma); or 4) the finding was due to the contamination of the environment. It is possible that the spread of the bacterium from infected mink to the control mink had occurred in the experimental unit immediately prior to the time of the sampling, either by the physical contacts between the mink, handling of the mink, by small rodents or birds observed to be in the animal premises during the study. The spread of FENP by wild-animal contacts was suspected in our epidemiological study (III) as an association between the occurrence of FENP and wildlife detected in the animal premises on the farm was shown. Direct or indirect contamination routes are common to viral and bacterial diseases and biosecurity measures are crucial to disease prevention and control. The studies of Fernández-Antonio (2016) on the Aleutian mink virus (AMDV) demonstrate the various possible transmission routes of AMDV, but also for other contagious pathogens, such as *A. phocae*, on a typical commercial mink farm. The spontaneous spread of *A. phocae* was possible as the experimental infection was performed in a commercial mink farm, not in animal premises designed for experimental infections. The use of common mink farm was however considered as an advantage, as FENP is likely a multifactorial disease where the environmental circumstances may influence the onset of FENP and the used facilities better resembled the housing conditions on commercial fur farms.

### 6.1.3.2 Immunity

Blood samples taken before the main study also indicated the spread of *A. phocae* and the novel *Streptococcus* sp. as antibodies were detected in the blood samples of two mink taken before their inoculation. These mink remained asymptomatic after inoculation, which indicates that they have either been more resistant in general to the FENP or they had developed immunity towards FENP. In the diseased animals (I), the reaction of the lymph nodes and the spleen is seen indicating an aroused immunological response. Finnish and Canadian farmers have observed that the morbidity and severity of FENP and pododermatitis on affected farms diminishes progressively over the years. This may indicate that after natural exposure, the acquired immunity may evolve and protect the animals. Further studies are needed to research the development of immunity to towards FENP to enable the possible development of a vaccination.

### 6.1.4 EPIDEMICAL STUDIES ON FENP

The mail survey was targeted to every fur farmer belonging to the FFBA in order to achieve the most comprehensive description of the epidemiology of FENP in Finland. The survey was introduced to farmers as a university research project and the importance of the study was explained in the cover letter. The questionnaires were sent during August-September, which is not the most pressing time on the farms. The response percentage was low (25%), despite a reminder letter and a lottery incentive. The willingness to respond was probably most influenced by the length of the questionnaire, as responding was time consuming and also required the farmer to search and provide numerical data concerning the events on the farm during the last three years (2009-2011). The length of the questionnaire probably also led to incompletely filled questionnaires, which may have led to some information bias as well as measurement error in the results (Dillman et al., 2014). Non-response error may exist in this study as farms with FENP may have been more motivated to participate in the study. Alternatively, fear of being identified may have lowered the response percentage of affected farms even though all questionnaires were handled anonymously.

Using a mixed-mode survey compounding mail survey with web survey and face to face survey might have captured more respondents (Dillman, 2014). A personal follow-up performed as a telephone interview might have also increased the response percentage and elevated the power of this study. Response success differs between studies, with an average between 20 and 30% as reported in the survey literature (Yammarino et al, 1991). Asch et al. (1997) found that the mean response percentage in mail surveys published in medical journals was much higher—approximately 60%. Conversely, low response percentage in agricultural research mail surveys among U.S farmers have been stated and studied (Pennings et al., 2002) where only a 12% response percentage was achieved in the pretest. The length of the study and the month the questionnaire was sent to the farmers influenced the response percentage most.

In this study, the number of respondents was approximately that aimed and the study captured both affected and non-affected farms. The respondent farms and farmers were also representative for Finnish farms and farmers.

No correction for the error rate  $\alpha$  for false significance (for example false discovery rate correction) in multiple testing was performed, as we aimed to disclose all possible risk factors of FENP as a detrimental fur animal disease.

In the questionnaire there was not always possible to conclude the chronological order of the events i.e. imports/purchases and the occurrence of FENP on the farm. However, in the questionnaires (additional information) some of the farmers had pointed that FENP outbreak emerged after the introduction of new animals to the farm. Also, veterinarians on the farms and farmers had reckon this same phenomena on the farms.

#### **6.1.4.1 Importance**

The survey data (III) showed that FENP is a widespread disease in Finnish fur farms as 40% of all responding farms reported signs of FENP during the study period. There are no previously collected data of the occurrence of different diseases in Finnish fur animals. Most Finnish mink farms, however, test for plasmacytosis. Antibodies to AMDV were found in 50% of Finnish mink farms during the study period (personal communication with Pirjo Aronen, FinFurlab). In our surveyed farms, other diseases detected on mink farms were sticky kits (42%), plasmacytosis (32%, which is lower than the average at the time in Finland), and urolithiasis (25%). FENP was detected on 39% of mink farms, which indicates that it is an important mink disease in Finland. The study did not specify the extent of FENP on the farms, however, as no data was collected on the proportion of the animals affected. FENP was more common on mink farms than on fox farms (24% of fox farms reported signs of FENP), which is probably due to the risk associated with importation from Denmark and Poland. However, farmers reported that when mink were imported to a mixed farm, foxes were the first species to develop signs.

#### **6.1.4.2 Risk factors**

The initial outcome of FENP has probably been seal meat. However, seal meat is not included in the raw materials of Finnish fur animals. In Canada, the spread of pododermatitis was detected when animals from an affected farm were introduced to unaffected farm. In this study (III) there was an association between importing from Denmark and Poland: farms importing from these countries had significantly more FENP compared to farms with no imports or imports only from the USA or Norway. This is in line with farmers' observations that the first FENP outbreaks in Finland occurred on farms that had imported Danish or Polish mink. This association indicates that *A. phocae* was introduced to Finnish fur animals by imported carrier animals leading to FENP outbreak in Finland in the presence of predisposing factors.

Importing fur animals to Finland is not nationally regulated or authorized as is the case for importing all other production animals. Thus, quarantine procedures on Finnish fur farms were poorly executed as only 25% of the respondent farmers reported any quarantine procedures during importing, and even less when animals from domestic sources were bought to the farm. Importing live fur animals is a risk for introducing fur animal diseases, e.g. the last two distemper outbreaks in Finland recorded in 1985-1987 and 2012 were associated with imports. The incubation time of FENP is unknown, as well as there is a seasonal occurrence of clinical signs seen, which complicates the determination of the length of the required quarantine. The occurrence of signs probably requires the presence of predisposing factors, which may also lack at the time of quarantine or from the quarantine premises. However, transportation is a stress to animals, and there is a case where FENP outbreak was detected on a quarantine farm (experiences of veterinarian in charge on quarantine farm and the results of mink submitted for necropsy).

FENP was probably spread further in Finland by trade of live Finnish fur animals. This infection route was found to be effective as our study showed that farms with signs of FENP had sold animals to other Finnish farms. At present, the fur animal industry has established a quarantine farm, where imported animals can be kept in isolation and they are monitored for signs of contagious diseases by veterinarians before further transport to the commercial farms. The FFBA has also given instructions to the farmers how to import and introduce new animals safely into their farms including vaccination and quarantine guidelines. In the control of FENP more effective preventive measurement than quarantine should be implemented including testing the imported/purchased animals for the presence of *A. phocae* or the presence of antibodies towards *A. phocae*.

The farm type seemed to influence the risk of FENP; FENP was especially prevalent on mixed farms (farms that produced fur from more than one fur animal species) as 61% of mixed farms reported signs of FENP on their farm. The risk for cross-infection from one fur species to another was notably high on mixed farms. This could indeed be due to the different sensitivity of fur animal species to FENP, as the more resistant species could act as symptomless carriers and spreaders. The farmers generally suspected that Finnraccoons would act as such carriers. The epidemiologic study results did not directly support this theory. However study I proved that *A. phocae* was isolated from the skin samples of the healthy Finnraccoons from an affected farm, indicating that the presence of *A. phocae* on the skin did not inevitably cause FENP in all *A. phocae* carrier animals. Moreover, differences in susceptibility between different species in other animal diseases have been reported. For example, small ruminants are known to be symptomless carriers and spreaders of FMD and even known to be responsible for the introduction of the disease into previously disease-free countries (Kitching and Hughes 2002).

The effect of the size of the farm was difficult to analyse statistically due to the inadequate responses to the questionnaire, but larger-sized farms (according to the number of breeder animals) seem to have an increased risk of FENP. For instance, a mink farm that has over 750 breeder mink had a greater risk of FENP compared to farms with fewer breeder mink. This could be partly caused by the tendency of the larger mink farms to import mink more than the smaller sized farms. On the other hand, Gardner et al. (2002) studied the connection between herd size and the incidence of different swine diseases on the farm; the effect of herd size on disease risk differed between different diseases in swine herds. They found that in some cases larger herd size created an increased risk but some diseases were more detected in smaller-sized farms. They also speculated that plausible reasons for a positive association between herd size and disease include a greater risk of introduction of pathogens from outside and a greater risk of transmission of pathogens within and among herds in larger sized herds. However, they also considered that owners of large herds might frequently adopt management and housing practices that mitigate this theoretically increased risk. The fur farms size can likewise be related to different management and environmental factors which may be the risk factors to FENP, such as: differences in animal density; different biosecurity procedures including the control of birds and wild life; importing; quarantine procedures; shared equipment between small farms; or different drinking systems.

#### **6.1.4.3 Biosecurity of fur animals**

Biosecurity is the attempt to keep infectious agents away from a herd and to limit or stop the spread of infectious agents within a herd. Biosecurity procedures on Finnish fur farms are not implemented as they are in other production animals in Finland. The sheds present challenges to protect animals from exterior environmental sources of pathogens. FENP spread between and within farms by birds and other wildlife in this study. Surprisingly, farms enclosed by a fence reported to have more birds and other wildlife on

the animal premises than farms without fences. According to the Finnish certification system, farms without a fence must use escape-proof shelter buildings, which prevent the escape of the fur animals and simultaneously efficiently prevent the access of wildlife invasion to the shelter buildings. Blocking the entry of birds and other wild life to the shelter buildings protects fur animals against FENP: thus, other means, such as strings between or nets under the shelter buildings should be used when the escape-proof sheds are not in use. In disease prevention against FENP, greatest success is probably achieved by using both the fence and closed shelter buildings, as well as by efficient rodent control.

There was no association found between the washing and disinfection frequency of cages and the occurrence of the FENP on the farm. However, the study documented that it is not a regular procedure to wash and disinfect the cages routinely, even after a disease outbreak on the fur farms. Farmers should be given instructions, during health care visits and education events, on how to improve their biosecurity level on their farm. In the freezing temperatures of winter the washing and disinfection is challenging and alternative cleaning methods such as recently marketed disinfection agent where propylene glycol is added to prevent the freezing, should be introduced onto fur farms.

#### **6.1.4.4 Animal and environmental risk factors**

The results obtained in this study presented some potential animal-based and human-associated environmental factors that may act as predisposing factors to FENP. In mink, FENP was reported in all color types, but with lowest risk for brown color types. The brown color type is most closely related to the wild type and is in general believed to more resistant to diseases (Belliveau et al., 1999). Among foxes, it was almost exclusively the blue foxes that were reported to have FENP, and a lower occurrence of disease in silver foxes. Our study confirmed a farmers' opinion about an association between FENP and sticky kits syndrome. Sticky kits syndrome is a multi-causal disease (Clausen and Dietz, 2004) where viral, bacterial, environmental, and also dietary factors are involved. The surviving kits are weaker and more prone to other diseases, and possibly also to FENP. *A. phocae* could in theory also be present at birth, and predispose to sticky kits syndrome. Eventough no typical lesions of *A. phocae* have been detected in kittens of sticky kit age. In theory, this connection between sticky kits and FENP could account for the farmers' observation of the drop in fertility that is indicated by the diminished pup results. The role of *A. phocae* in infertility problems still needs to be investigated. It is also probable that the same environmental risk factors, such as the hygiene level and management, predispose to both diseases and to poor reproduction. Surprisingly, the results indicated that mink farms with plasmacytosis did not have a higher risk of FENP. This result can be biased if farmers with plasmacytosis on the farm have missed the first signs of FENP if they have not inspected the animals as carefully as on plasmacytosis free farms. Plasmacytosis attenuates the immune system and thereby may predispose mink to other diseases (Porter et al., 1969). However, there is no detected increased risk of medication in mink with AMDV (Jensen, et al., 2016).

FENP was reported less on farms that used hay as a bedding material in the mink nests. This was somewhat surprising as trauma and abscesses on mucous membranes are more readily caused by sharp, short stems and straws than saw-dust and shavings, for instance, especially in the sapphire color-type (Affolter et al., 2001), and a possible connection is evident between the presence of abrasions and FENP lesions. However, good quality hay is usually soft textured. It also has good isolation properties and protects against cold, which is also a potential stress factor that predisposes to FENP, as detected in the experimental-infection study (study II).

#### **6.1.4.5 Other suspected sources**

Feed might be one potential source for FENP as the onset of similar symptoms and the feeding of mink with seal byproducts have been detected in North America. This thesis study showed no difference in FENP incidence relating to various feeding procedures and feed supply between the farms with and without FENP diseased fur animals. No differences were detected between the uses of on-farm prepared feed or commercially prepared feed, or the use of different feed producers and the detection of signs of FENP. The raw materials utilized in all feed centres or farms varied little and no byproducts of seal are used in Finland. Fish products are one of the main raw ingredients used in fur-animal feed. However, *A. phocae* is, to the best of our knowledge, only isolated from marine mammals, not from fish. The feed as an infection source is not relevant under Finnish conditions. However, the feed as an optional infection source should not be entirely ruled out.

Farms with nipple drinking systems reported more signs of FENP compared to the farms that used cups. The more intimate contact of mucous membranes to the drinking nipple might predispose the animal to FENP. Sharp objects near to the drinking nipple, such as wires, may cause abrasions to the skin of the feet or head when animals are drinking. In addition, nipple structures are not washed and disinfected as often as the cups that are washed weekly, and this in theory could lead to increased contamination of nipple structures with *A. phocae*. The spread of pathogens from nipples to water lines could facilitate the spread of FENP by the drinking water on the farm. The water lines in both human public water supplies and animal drinking systems may be contaminated by bacteria and biofilm formation may appear in the systems (Wingender and Flemming 2011, Lehtola et al., 2004). Hence, regular water sampling and disinfection of water lines when needed could improve disease control on fur farms.

## 7 CONCLUSION AND FUTURE PROSPECTS

This thesis investigation describes new insights to the incidence and pathogenicity of FENP in fur animal species in Finland in recent times. This represents the most recent and detailed account of the problem and provides fresh insight into the key issues and approaches that might address this debilitating skin disease. In particular, some key findings can be drawn from this study, including:

- The clinical signs, gross and histopathology, of a new fur animal disease FENP in different fur animal species were described in this study and *A. phocae* was identified as a causative organism for FENP (I).
- Clinical signs and lesions typical of FENP were induced by inoculating mink with *A. phocae* subcutaneously/intradermally or applied to artificially wounded superficial skin (II).
- The results indicate that the outbreak of FENP requires the presence of *A. phocae* as well as the presence of predisposing factors such as skin trauma.
- A new bacterium, novel *Streptococcus* spp., was found and is a potential synergistic co-factor in the pathogenesis of FENP (I).
- PCR is the most reliable diagnostic method for detecting *A. phocae* in skin and eye samples. It may also have a role in identifying carrier animals, for instance by testing of trade animals from skin/eye swabs. Also, detection of antibodies in the sera could be used to identify possible carriers. (I, II).
- The epidemiologic study (III) revealed a number of risk factors for FENP:
  - Import from Denmark and Poland. This suggests that *A. phocae* was initially introduced to Finnish Fur Animals by imported animals.
  - Trade of live Finnish fur animals in Finland indicating that FENP is currently spreading in Finland by *A. phocae* carrier animals.
  - The contacts between fur animals and wild birds/wildlife. The results indicated that blocking the entry of wildlife to the animal premises by using escape-proof shelter buildings protected against FENP.
  - Farm type; clinical signs of FENP were detected more commonly on farms with more than one species of fur animal (mixed farms) in comparison to farms with only one species of fur animals. If one species on a mixed farm had clinical signs of FENP, then other species experience a higher risk for FENP as well.
  - Farm size; the incidence of FENP was higher on larger farms compared to smaller farms according to the number of breeding animals.
  - Drinking system; clinical signs of FENP were detected more on farms that used drinking nipples instead of cups.
  - Bedding material; the results indicated that hay could protect against FENP.
  - Presence of other diseases; FENP had a positive association to sticky kits and a negative association to plasmacytosis.
  - Color type of the mink; FENP was seen least in the brown color type of mink.



- The results indicated that a bacterial toxin of *A. phocae* may be involved in the pathogenesis of FENP (I) and further investigations are needed to elucidate this finding.

The results (I, II, III) provide a basis for developing FENP control procedures, including treatments, new diagnostics such as antibody testing, and preventive methods including vaccines.

## REFERENCES

- Abbott, K., Lewis, C., 2005. Current approaches to the management of ovine footrot. *Vet.J.* 169(1), 28-41.
- Abramov, A. V., 2000. A taxonomic review of the genus *Mustela* (Mammalia, Carnivora). *Zoosystematica Rossica*, 8(2) 1999, 357-364. Zoological Institute, St. Petersburg.
- Affolter, T.W., Gorham, J.R., 2001. Bacterial diseases of mink. In: *Blue Book of Farming*, 32, 20-43.
- Almuzara, M.N., De Mier, C., Barberis, C.M., Mattera, J., Famiglietti, A., Vay, C., 2002. *Arcanobacterium hemolyticum*: identification and susceptibility to nine antimicrobial agents. *Clin. Microbiol. Inf.* 8(12), 828-829.
- Andrew, S., 2001. Ocular manifestations of feline herpesvirus. *J. Feline Med. Surg.* 3(1), 9-16.
- Asch, D. A., Jedrzejewski, M. K., Christakis, N. A., 1997. Response rates to mail surveys published in medical journals. *J. Clin. Epidemiol.* 50(10), 1129-1136
- Bacha, W. J., Bacha, J., 2006. Integument. In: *Color Atlas of Veterinary Histology*, 2<sup>nd</sup> ed. John Wiley & Sons. pp. 85-118.
- Barrett, T., Visser, I.K.G., Mamaev, L., Goatley, L., Van Bresse, M.F., Osterhaus, A.D.M.E., 1993. Dolphin and porpoise morbilliviruses are genetically distinct from phocine distemper virus. *Virology* 193(2), 1010-1012.
- Bassett, R., Burton, G., Robson, D., 2004. Antibiotic responsive ulcerative dermatoses in German Shepherd dogs with mucocutaneous pyoderma. *Aust. Vet. J.* 82(8), 485-489.
- Bell, A. G., Coombs, G. W., Cater, B., Douglass, C., 2016. First report of a *mecA*-positive multidrug-resistant *Staphylococcus pseudintermedius* isolated from a dog in New Zealand. *N. Z. Vet.J.* 64(4), 253-256.
- Belliveau, A., Farid, A., O'Connell, M., Wright, J., 1999. Assessment of genetic variability in captive and wild American mink (*Mustela vison*) using microsatellite markers. *Can. J. Anim. Sci.* 79(7),16
- Bemis, D.A., Bryant, M.J., Kania, S.A., Newman, S.J., 2008. Isolation of *Arcanobacterium hippocoleae* from a case of placentitis and stillbirth in a mare. *J. Vet. Diagn. Invest.* 20(5), 688-691.
- Benato, L., Stoekli, M., Smith, S., Dickson, S., Thoday, K., Meredith, A., 2013. A case of antibacterial responsive mucocutaneous disease in a seven year old dwarf lop rabbit (*Oryctolagus cuniculus*) resembling mucocutaneous pyoderma of dogs. *J. Small Anim. Pract.* 54(4), 209-212.
- Billington, S.J., Songer, J.G., Jost, B.H., 2001. Molecular characterization of the pore-forming toxin, pyolysin, a major virulence determinant of *Arcanobacterium pyogenes*. *Vet. Microbiol.* 82(3), 261-274.

- Bishop, S. P., 1989. Animal Models of Vasculitis 1. *Toxicol. Pathol.* 17(1), 109-117.
- Blancou, J., Chomel, B., Belotto, A., Meslin, F., 2005. Emerging or re-emerging bacterial zoonoses: factors of emergence, surveillance and control. *Vet. Res.* 36(3), 507-522.
- Bloom M.E., Kanno, H., Mori, S., Wolfinger, J.B., 1994. Aleutian mink disease: puzzles and paradigms. *Infect. Agents Dis.* 3, 279-301.
- Bowman A.M, Travis H.F, Warner R.G., Hogue O.E., 1968. Vitamin B<sub>6</sub> requirement of the mink. *J. Nutr.* 1968, 95, 554-562.
- Bröjer, C., 2000. Pododermatitis in farmed mink in Canada. M.Sc. Thesis. The University of Guelph, Canada.
- Broom, D., 1986. Indicators of poor welfare. *Br. Vet J.* 142(6), 524-526.
- Budd, J., 1981. Distemper. In: J.W. Davis, L.H. Karstad, D.O. Trainer (Eds.), *Infectious diseases of wild mammals* (2nd), Iowa State University Press, Iowa, pp. 31-44.
- Carmichael, L.E., Joubert, J.C., Pollock, R.V., 1980. Hemagglutination by canine parvovirus: serologic studies and diagnostic applications. *Am. J. Vet. Res.* 41(5), 784-791.
- Chalmers, G., McLean, J., Hunter, D. B., Brash, M., Slavic, D., Pearl, D. L., Boerlin, P., 2015. *Staphylococcus* spp., *Streptococcus canis*, and *Arcanobacterium phocae* of healthy Canadian farmed mink and mink with pododermatitis. *Can. J. Vet. Res.* 79(2), 129-135.
- Christensen, K., Fischer, P., Knudsen, K. E., Larsen, S., Sørensen, H., Venge, O. 1979. A syndrome of hereditary tyrosinemia in mink (*Mustela vison* Schreb.). *Can. J. Comp.Med.* 43(3), 333-340.
- Christensen, K., Henriksen, P., Sorensen, H., 1986. New forms of hereditary tyrosinemia type II in mink: Hepatic tyrosine aminotransferase defect. *Hereditas* 104(2), 215-222.
- Christodoulou, T., Tsiroyiannis, E., Papado-poulos, O., Tsangaris, T., 1970. An outbreak of Aujeszky's disease in minks. *Cornell Vet.*, 60, 65-73.
- Clausen, T.N., Dietz, H.H., 2004. Wet kits in mink, a review. In: VIII<sup>th</sup> International scientific congress in fur animal production Date, De Ruwenberg, Hertogenbosch, Netherlands. pp. 87-90.
- Cleaveland, S., Laurenson, M., Taylor, L., 2001. Diseases of humans and their domestic mammals: pathogen characteristics, host range and the risk of emergence. *Philos. Trans. R. Soc. London B Biol. Sci.* 356(1411), 991-999.
- Collins, M.D., Jones, D., Schofield, G.M., 1982. Reclassification of *Corynebacterium haemolyticum* (MacLean, Liebow and Rosenberg) in the genus *Arcanobacterium* gen.nov. as *Arcanobacterium haemolyticum* nom.rev., comb.nov. *J. Gen. Microbiol.* 128, 1279-1281.
- Council, Farm Animal Welfare, 1992. The five freedoms. London: Farm Animal Welfare Council.

- Counts, D.F., Knighten, P., Hegreberg, G., 1977. Biochemical changes in the skin of mink with Ehlers-Danlos syndrome: increased collagen biosynthesis in the dermis of affected mink. *J. Invest. Derm.* 69(6), 521-526.
- Dietz, H.H., Henriksen, P., Clausen, T. N., Chriél, M., 2013. A brief compendium of the most commonly encountered diseases in mink and foxes in Denmark. Mimeo, Denmark.
- Dillman, D.A., 2000. *Mail and Internet Surveys: The Tailored Design Method*. New York: Wiley.
- Dillman D.A., Smyth J.D., Christan L.M., *Internet, phone, mail, and mixed-mode surveys: the tailored design method*. 4th ed. Wiley. 1–18.
- Dobinsky, S., Noesselt, T., Rücker, A., Maerker, J., Mack, D., 1999. Three cases of *Arcanobacterium haemolyticum* associated with abscess formation and cellulitis. *Eur. J. Clin. Microbiol. Infect. Dis.* 18(11), 804-806.
- Ek-Kommonen, C., Sihvonen, L., Pekkanen, K., Rikula, U., Nuotio, L., 1997. Outbreak of canine distemper in vaccinated dogs in Finland. *Vet. Rec.* 141, 380-382.
- Englund, L., Chriél, M., Dietz, H.H., Hedlund, K.O., 2002. Astrovirus epidemiologically linked to pre-weaning diarrhoea in mink. *Vet. Microbiol.* 85(1), 1-11.
- Fernández- Antonio, R., Failde, L.D., Losada, A.P., López-Pena, M., Vázquez S., Bermúdez, R., Quiroga, M.I., Nieto, J.M., 2008. Pododermatitis in farmed mink (*Neovison vison*) in Spain. In: *Proceedings of the IX<sup>th</sup> international Scientific Congress in Fur Animal Production*, Halifax, Nova Scotia, Canada, 19-23-8-2008. pp. 19-23.
- Fernández- Antonio, R., Prieto, A., Díaz-Cao, J.M., López, G., Panadero, R., Díaz, P., Morrondo, P., Fernández, G., 2016. Study of distribution of AMDV load in infected mink farms environment. In: *Proceedings of the XI<sup>th</sup> International Scientific Congress in Fur Animal Production*, 23-26.8.2006. Helsinki, Finland. pp. 75-80.
- Fernández-Antonio, R., Prieto, A., Díaz-Cao, J.M., López, G., López, C., Pérez-Creo, A., Díez- Baños, P., Fernández, G., 2016. Evaluation by qPCR of personal protective equipments for visitors against AMDV. In: *Proceedings of the XI<sup>th</sup> International Scientific Congress in Fur Animal Production*, 23-26.8.2006. Helsinki, Finland, pp. 81-85.
- Foster, G., Hunt, B., 2011. Distribution of *Arcanobacterium pluranimalium* in animals examined in veterinary laboratories in the United Kingdom. *J. Vet. Diagn. Invest.* 23(5), 962-964.
- Frank, L. A., Kania, S. A., Hnilica, K. A., Wilkes, R. P., Bemis, D. A. 2003) Isolation of *Staphylococcus schleiferi* from dogs with pyoderma. *J. Am. Vet. Med. Assoc.* 222(4), 451-454.
- Gannon, V., Gyles, C., Wilcock, B., 1989. Effects of *Escherichia coli* Shiga-like toxins (verotoxins) in pigs. *Can. J. Vet. Res.* 53(3), 306.
- Gardner, I., Willeberg, P., Mousing, J., 2002. Empirical and theoretical evidence for herd size as a risk factor for swine diseases. *Anim. Health Res. Rev.* 3(01), 43-55.

- Gortel, K., 2013. Recognizing pyoderma: more difficult than it may seem. *Vet. Clin. North Am. Small Anim. Pract.* 43(1), 1-18
- Guardabassi, L., Schmidt, K.R., Petersen, T.S., Espinosa-Gongora, C., Moodley, A., Agersø, Y., Olsen, J.E., 2012. Mustelidae are natural hosts of *Staphylococcus delphini* group A. *Vet. Microbiol.* 159(3-4), 351-353.
- Guo, M., Evermann, J.F., Saif, L.J., 2001. Detection and molecular characterization of cultivable caliciviruses from clinically normal mink and enteric caliciviruses associated with diarrhea in mink. *Arch. Virol.* 146(3), 479-493.
- Haig, D., Mercer A., 1997. Ovine diseases. *Orf. Vet. Res.* 29, 311-326.
- Hammer, A., Damborg, P., Elvang, Jensen H., Clausen, T., Aalbæk, B., 2015. Cutaneous candidiasis in farm mink (*Neovison vison*). In: Nordic Association of Agricultural Scientists in Fur Animal Research 29.9. - 1.10. 2015, Turku, Finland.
- Hammer, A.S., Andresen, L., Larsen, S.V., Dalsgaard, K., Damborg, P.P., Aalbek, B., 2016. Experimental infection with *Arcanobacterium phocae* and *Streptococcus halichoeri* in farm mink (*Neovison vison*). In: Proceedings of the XI<sup>th</sup> International Scientific Congress in Fur Animal Production, 23.-26.8.2016, Helsinki, Finland, p. 33-42.
- Hammer, A.S., Jensen, H., Dietz, H., Clausen, T., 2012. Handout for the IFASA 2012 Mink necropsy workshop. University of Copenhagen, Denmark.
- Hansen, M.U., Weiss V., Clausen T., Mundbjerg B., Lassén M., 2007. Investigations in causes of death among mink kits from June to October. *Faglig Årsberetning*, 99-100.
- Hansen, S., Malmkvist, J., Palme, R., Damgaard, B., 2007. Do double cages and access to occupational materials improve the welfare of farmed mink? *Animal welfare-potters bar then Wheathampstead*. 16, 63.
- Hansen, J. E., Larsen, A. R., Skov, R. L., Chriél, M., Larsen, G., Angen, Ø., Larsen J., Lassen D., Pedersen, K., 2017. Livestock-associated methicillin-resistant *Staphylococcus aureus* is widespread in farmed mink (*Neovison vison*). *Veterinary Microbiology*.
- Hanson, K.B., 1932. Parasites of ranch foxes and their treatment. *J. Am. Vet. Med. Assoc.* 80(2), 202-209.
- Hegreberg, G.A., Padgett, G.A., Ott, R.L., Henson, J.B., 1970. A heritable connective tissue disease of dogs and mink resembling Ehlers-Danlos syndrome of man I. Skin tensile strength properties. *J. Invest. Dermatol.* 54(5), 377-380.
- Helgebostad, A., 1955. Experimental excess of vitamin A in fur animals. *Nord. Vet. Med.* 7, 297-308.
- Hijazin, M., 2012. Phenotypic and genotypic characteristics of bacteria of genera *Arcanobacterium*, *Trueperella* and *Actinomyces*, with the emphasis on *Arcanobacterium (Trueperella) pyogenes*. Ph.D. Thesis. <http://geb.uni-giessen.de/geb/volltexte/2012/8582/>. Accessed February 2017.

- Hijazin, M., Prenger-Berninghoff, E., Sammra, O., Alber, J., Lämmler, C., Kämpfer, P., Glaeser, S.P., Busse, H.J., Hassan, A.A., Abdulmawjood, A., Zschöck, M., 2012. *Arcanobacterium canis* sp. nov., isolated from otitis externa of a dog, and emended description of the genus *Arcanobacterium* Collins et al. 1983 emend. Yassin et al. 2011. Int. J. System. Evolut. Microbiol. 62(9), 2201-2205.
- Hijazin, M., Sammra, O., Ülbegi-Mohyla, H., Nagib, S., Alber, J., Lämmler, C., Kämpfer, P., Glaeser, S.P., Busse, H.J., Kassmannhuber, J., Prenger-Berninghoff, E., 2013. *Arcanobacterium phocisimile* sp. nov., isolated from harbour seals. Int. J. System. Evolut. Microbiol. 63(6), 2019-2024.
- Hoyles, L., Falsen, E., Foster, G., Rogerson, F., Collins, M.D., 2002. *Arcanobacterium hippocoleae* sp. nov., from the vagina of a horse. Int. J. System. Evolut. Microbiol. 52(2), 617-619.
- Huang, T., Zhao, K., Zhang, Z., Tang, C., Zhang, X., Yue, B., 2016. DNA vaccination based on pyolysin co-immunized with IL-1 $\beta$  enhances host antibacterial immunity against *Trueperella pyogenes* infection. Vaccine 34(30), 3469-3477.
- Ingo, R., Kangas, J., Blomstedt, L., Valtonen, M., 1988. Tutkimuksia kiharakarvaisuus eli "KEKE"- ilmiöstä (in Finnsih). Rehunvalmistajien luentopäivät. 4- 5.2.1988. Jyväskylä, Finland.
- Jespersen, A., Agger, J.F., Clausen, T., Bertelsen, S., Jensen, H.E., Hammer, A. S., 2016. Anatomical distribution and gross pathology of wounds in necropsied farmed mink (*Neovison vison*) from June and October. Acta Vet. Scand. 58(1), 6.
- Jespersen, A., Hammer, A.S., Jensen, H.E., Bonde-Jensen, N., Lassus, M.M., Agger, J.F., Larsen, P.F., 2015. Foot lesions in farmed mink (*Neovison vison*): Pathologic and epidemiologic characteristics on 4 Danish farms. Vet. Pathol. 53(3), 666-673.
- Johnson, S.P., Jang, S., Gulland, F.M., Miller, M.A., Casper, D.R., Lawrence J., Herrera, J., 2003. Characterization and clinical manifestations of *Arcanobacterium phocae* infections in marine mammals stranded along the central California coast. J. Wildl. Dis. 39, 136-44.
- Jørgensen, M., Scheutz, F., Strandbygaard, B., 1995. *Escherichia coli* and virus isolated from "sticky kits". Acta Vet. Scand. 37(2), 163-169.
- Jost, B., Billington, S., 2005. *Arcanobacterium pyogenes*: molecular pathogenesis of an animal opportunist. Antonie van Leeuwenhoek, 88(2), 87-102.
- Juokslahti T., 1989. Vitamins. In: Brandt A. (Ed.), Haematology and clinical chemistry of fur animals 1 st ed. Gummerus Kirjapaino Oy, Jyväskylä, Finland. P.95-104.
- Kallio, H., Ahola, H., 2012. *Lawsonia intracellularis* in blue foxes in Finland. A case report. European Association of Veterinary Laboratory Diagnosticians.
- Kallio-Kokko, H., Uzcategui, N., Vapalahti, O., Vaheri, A., 2005. Viral zoonoses in Europe. FEMS Microbiol. Rev. 29(5), 1051-1077.
- Kempe, R., Strandén, I., 2016. Breeding for better eye health in Finnish blufox (*Vulpes lagopus*). J. Anim. Breed. Gen. 133(1), 51-58.

- Ki, V., Rotstein, C., 2008. Bacterial skin and soft tissue infections in adults: a review of their epidemiology, pathogenesis, diagnosis, treatment and site of care. *Can. J. Infect. Dis. Med. Microbiol.* 19(2), 173-184.
- Kimman, T.G., Van Oirschot, J.T., 1986. Pathology of Aujeszky's disease in mink. *Vet. Pathol.* 23(3), 303-309.
- Kipar, A., Meli, M. L. 2014. Feline infectious peritonitis: still an enigma?. *Vet. Pathol.* 51(2), 505-526.
- Kitching, R., Hughes, G. J., 2002. Clinical variation in foot and mouth disease: sheep and goats. *Rev. Sci. Tech. Off. Int. Epiz.* 21(3), 505-510.
- Kitching, R., 2002. Clinical variation in foot and mouth disease: cattle. *Rev. Sci. Tech. Off. Int. Epiz.* 21(3), 499-502.
- Knuutila, A., Aronen, P., Saarinen, A., Vapalahti, O., 2009. Development and evaluation of an enzyme-linked immunosorbent assay based on recombinant VP2 capsids for the detection of antibodies to Aleutian mink disease virus. *Clin. Vaccine Immunol.* 16, 1360–1365.
- Larsen C., 2014. The microbiology of mink skin and wounds. In: *Proceedings of Abilgaard Symposium 2014- Fur animal welfare and health.* University of Copenhagen, 2014.
- Larsen, G., Chriél M., Pedersen K., 2016. "MRSA in mink (Neovison vison)." XIth International Scientific Congress in Fur Animal Production.
- Lawson, P.A., Falsen, E., Foster, G., Eriksson, E., Weiss, N., Collins, M.D., 2001. *Arcanobacterium pluranimalium* sp. nov., isolated from porpoise and deer. *Int. J. System. Evolut. Microbiol.* 51(1), 55-59.
- Lehtola, M., Miettinen, I., Keinänen, M., Kekki, T., Laine, O., Hirvonen, A., Vartiainen T., Martikainen, P., 2004. Microbiology, chemistry and biofilm development in a pilot drinking water distribution system with copper and plastic pipes. *Wat. Res.* 38(17), 3769-3779
- Lohi, O., Hansen, B. K., Johannessen, K-R., Smeds, K., Clausen, J., 2015. More about Beautiful Fur Animals – genetics of colours, fur, defects and diseases. Working Group for Fur Animals, Nordic Association of Agricultural Scientists, pp. 80.
- Los, F.C., Randis, T.M., Aroian, R.V., Ratner, A.J., 2013. Role of pore-forming toxins in bacterial infectious diseases. *Microbiol. Mol. Biol. Rev.* 77(2), 173-207.
- Lucas, E., Billington, S., Carlson, P., McGee, D., Jost, B., 2010. Phospholipase D promotes *Arcanobacterium haemolyticum* adhesion via lipid raft remodeling and host cell death following bacterial invasion. *BMC Microbiol.* 10(1), 270.
- Lucas, E.A., Billington, S.J., Carlson, P., McGee, D.J., Jost, B.H., 2010. Phospholipase D promotes *Arcanobacterium haemolyticum* adhesion via lipid raft remodeling and host cell death following bacterial invasion. *BMC Microbiol.* 10(1), 270.
- Lyubashenko, S.Y., Tyul'panova, A.F., Grishin, V.M., 1958. Aujeszky's disease in mink, arctic fox and silver fox. *Veterinariya*, 35, 37-44.

- Mackenzie, A., Fuite, L.A., Chan, F.T., King, J., Allen, U., MacDonald, N., Diaz-Mitoma, F., 1995. Incidence and pathogenicity of *Arcanobacterium haemolyticum* during a 2-year study in Ottawa. *Clin. Infec. Dis.* 21(1), 177-181.
- Mauldin, A., Peters- Kennedy, J., 2015. Integumentary system. In: Jubb, Kennedy, and Palmer's Pathology of Domestic Animals. Maxie, M. (ed.) 6<sup>th</sup> ed., Volume 1. Philadelphia, PA: Elsevier; pp. 509-736.
- Miller Jr, W. H., Scott, D. W., Buerger, R. G., Shanley, K. J., Paradis, M., McMurdy, M. A., Angarano, D. W., 1990. Nerolytic migratory erythema in dogs: a hepatocutaneous syndrome. *J. Am. Anim. Hosp. Assoc.* 26(6), 573-581.
- Moberg, G.P., 2000. Biological response to stress: implications for animal welfare. In: Moberg, G.P. and Mench, J.A. (eds.) The biology of animal stress. CABI Publishing, 2000. pp. 1-21.
- Molenaar, R. J., Buter, R., Sroka, A. 2017. Postvaccination wounds associated predominantly with *Arcanobacterium phocae* in mink (*Neovison vison*) at three mink farms. *Vet. Derm.* 28(2), 242.
- Mononen, J., Koistinen, T., Huuki, H., Ahola, L., 2014. Implementation of the WelFur welfare assessment: results from Finnish mink farms. In: Proceedings of the Nordic Association of Agricultural Scientists 482, Autumn meeting in fur animal research 2014, Grenå, Denmark.
- Moriello K., 1991. Overview of interdigital furunculosis. In: Fraser, C. (ed.) The Merck veterinary manual: a handbook of diagnosis, therapy, and disease prevention and control for the veterinarian.
- Mäkinen, A., 1978. Supikoiran kromosomisto (The chromosomes of raccoon dog). (In Finnish). Ph.D Theses, The University of Helsinki, Finland.
- Neagari, Y., Sakai, T., Nogami, S., Kaiho, I., Katoh, C., 1998. Incidence of antibodies in raccoon dogs and deer inhabiting suburban areas. *Kansenshogaku zasshi. J. Jpn. Assoc. Infect. Dis.* 72(4), 331-334.
- Nes, N. N., Einarsson, E. J., Lohi, O., Joergensen, G., 1988. Beautiful fur animals: their colour genetics. [Danish].
- Olivry, T., Jackson, H., 2001. Diagnosing new autoimmune blistering skin diseases of dogs and cats. *Clin. Tech. Small An. P.* 16(4), 225-229.
- Opriessnig, T., Shen, H., Bender, J., Boehm, J., Halbur, P., 2013. *Erysipelothrix rhusiopathiae* isolates recovered from fish, a harbour seal (*Phoca vitulina*) and the marine environment are capable of inducing characteristic cutaneous lesions in pigs. *J. Comp. Pathol.* 148(4), 365-372.
- Overy, D., Marron-Lopez, F., Muckle, A., Bourque, A., Lund, L., MacHattie, D., Lopez, A., 2015. Dermatophytosis in farmed mink (*Mustela vison*) caused by *Trichophyton equinum*. *J. Vet. Diagn. Invest.* 27(5), 621-626.
- Pearson, R.C., Gorham, J.R., 1987. In: Appel, M. Canine distemper virus. In: Virus infections of carnivores, 1, pp. 371-373.



- Petavy, A.F., Deblock, S., 1979. [Helminths of the common fox (*Vulpes vulpes* L.) from the Massif central (France) (author's transl.)]. *Ann. Paras. Hum. Comp.* 55(4), 379-391.
- Porter, D.D., Larsen, A.E., Porter, H. G., 1969. The pathogenesis of Aleutian disease of mink. I. In vivo viral replication and the host antibody response to viral antigen. *J. Exp. Med.* 1130, 575-89.
- Porter, D.D., Larsen, A.E. and Porter, H.G., 1973. The pathogenesis of Aleutian disease of mink. III. Immune complex arteritis. *Am. J. Pathol.* 71, 331-344.
- Prescott, J., Miller, C., Mathews, K., Yager, J., DeWinter, L., 1997. Update on canine streptococcal toxic shock syndrome and necrotizing fasciitis. *Can. Vet. J.* 38(4), 241.
- Quiroga, M.I., Vazquez, S., López Peña, M., Guerrero, F., Nieto, J.M., 1995. Experimental Aujeszky's disease in blue foxes (*Alopex lagopus*). *J.Vet. Med. Ser. A*, 42(1-10), 649-657.
- Ramachandran, G., 2014. Gram-positive and gram-negative bacterial toxins in sepsis: A brief review. *Virulence* 5(1), 213-218.
- Ramos, C.P., Foster, G., Collins, M.D., 1997. Phylogenetic Analysis of the Genus *Actinomyces* Based on 16S rRNA Gene Sequences: Description of *Arcanobacterium phocae* sp. nov., *Arcanobacterium bernardiae* comb. nov., and *Arcanobacterium pyogenes* comb. nov. *Int. J. System. Evol. Microbiol.* 47(1), 46-53.
- Ribeiro, M., Riseti, R., Bolaños, C., Caffaro, K., de Moraes, A., Lara, G., Zamprogna T., Paes, A., Listoni, F., Franco, M., 2015. *Trueperella pyogenes* multispecies infections in domestic animals: a retrospective study of 144 cases (2002 to 2012). *Vet. Quart.* 35(2), 82-87.
- Robinson W., Robinson N., 2015. Cardiovascular system. In: Jubb, Kennedy, and Palmer's Pathology of Domestic Animals. Maxie, M. (ed.) 6<sup>th</sup> ed., Volume 3. Philadelphia, PA: Elsevier; pp. 2-101.
- Roskov, Y., Abucay, L., Orrell, T., Nicolson, D., Kunze, T., Culham, A., Bailly, N., Kirk, P., Bourgoin, T., DeWalt, R.E., Decock, W., DeWever, A., eds. 2015. Species 2000 & IT IS. Catalogue of Life, 2015. Annual Checklist. Digital resource at: [www.catalogueoflife.org/annual-checklist/2015](http://www.catalogueoflife.org/annual-checklist/2015). Species 2000. Naturalis, Leiden, The Netherlands, ISSN 2405-884X.
- Rouvinen-Watt K., Clausen T., 1991. Mink diseases related to feed and feeding. In: Nordic Association of Agricultural Scientists. Report No.63.
- Sammra, O., Balbutskaya, A., Ülbegi-Mohyla, H., Nagib, S., Lämmler, C., Kämpfer, P., Glaeser, S.P., Golke, J., Busse, H.J., Prenger-Berninghoff, E., Siebert, U., 2015. *Arcanobacterium pinnipediorum* sp. nov., isolated from a harbour seal. *Int. J. System. Evolut. Microbiol.* 65(12), 4539-4543.
- Sanin, L., Zuluaga C., Morales T., 2016. Adaptive responses to thermal stress in mammals. *Rev. Med. Vet.* 31, 121-135.
- Schantz, P., 1991. Parasitic zoonoses in perspective. *Int. J. Paras.* 21(2), 161-170.

- Scott-Moncrieff, J. C., 2007. Clinical signs and concurrent diseases of hypothyroidism in dogs and cats. *Vet. Clin. North Am. Small Anim. Pract.* 37(4), 709-722.
- Shimalov, V., and Shimalov, V., 2002. Helminth fauna of the raccoon dog (*Nyctereutes procyonoides* Gray, 1834) in Belorussian Polesie. *Paras. Res.* 88(10), 944-945.
- Takashi, M., Nogami, S., Misumi, H., Maruyama, S., Shiibashi, T., Yamamoto, Y., Sakai, T., 2001. Mange caused by *Sarcoptes scabiei* (Acari: Sarcoptidae) in wild raccoon dogs, *Nyctereutes procyonoides*, in Kanagawa Prefecture, Jpn. *J. Vet. Med. Sci.* 63(4), 457-460.
- Taylor, L., Latham, S., Mark, E., 2001. Risk factors for human disease emergence. *Philos. Trans. R. Soc. London B Biol. Sci.* 356(1411), 983-989.
- Trebbien, R., Chriel, M., Struve, T., Hjulsager, C. K., Larsen, G. and Larsen, L. E., 2014. Wildlife reservoirs of canine distemper virus resulted in a major outbreak in Danish farmed mink (*Neovison vison*). *PLoS One*, 9(1), e85598.
- Ülbeği, H., 2010. Phäno-und Genotypisierung von Bakterien des Genus *Arcanobacterium* unter besonderer Berücksichtigung von *Arcanobacterium phocae*. Ph.D. Thesis. Universitätsbibliothek Giessen.
- Uwatoko, K., Sunairi, M., Nakajima, M., Yamaura, K., 1995. Rapid method utilizing the polymerase chain reaction for detection of canine parvovirus in feces of diarrheic dogs. *Vet. Microbiol.* 43(4), pp. 315-323.
- Valli, V.E.O., Kiupel, M., Bienzle D. (with Wood, R.D), 2015. Hematopoietic system. In: Jubb, Kennedy, and Palmer's Pathology of Domestic Animals. Maxie, M. (ed.) 6<sup>th</sup> ed., Volume 3. Philadelphia, PA: Elsevier; pp. 102-268.
- VanDevanter, D., Warrener, P., Bennett, L., Schultz, E., Coulter, S., Garber, R., Rose, T., 1996. Detection and analysis of diverse herpesviral species by consensus primer PCR. *J. Clin. Microbiol.* 34(7), pp. 1666-1671.
- Wingender, J., Flemming, H.C., 2011. Biofilms in drinking water and their role as reservoir for pathogens. *Int. J. Hyg. Environ. Heal.* 214(6), 4.
- Wolfe, N., Dunavan, C., Diamond, J., 2007. Origins of major human infectious diseases. *Nature* 447(7142), 279-283.
- Yammarino, F. J., Skinner, S. J., Childers, T. L. 1991. Understanding mail survey response behavior a meta-analysis. *Pub. Opin. Quart.* 55(4), 613-639.
- Yang, D., Nah, J., Kim, H., Choi, S., Kim, J.T, Park, K., Song, J., 2014. Seroepidemiological survey of Aujeszky's disease virus in wild boar (*Sus scrofa*) and raccoon dogs (*Nyctereutes procyonoides koreensis*) in Korea. *J. Bacteriol. Virol.* 44(4), 336-341.
- Yassin, A., Hupfer, H., Siering, C., Schumann, P., 2011. Comparative chemotaxonomic and phylogenetic studies on the genus *Arcanobacterium* Collins et al. 1982 emend. Lehnen et al. 2006: proposal for *Trueperella* gen. nov. and emended description of the genus *Arcanobacterium*. *Int. J. Syst. Evol. Microbiol.* 61(6), 1265-1274.
- Zutterman, N., Maes, H., Claerhout, S., Agostinis, P., Garmyn, M., 2010. Deregulation of cell-death pathways as the cornerstone of skin diseases. *Clin. Exp. Derm.* 35(6), 569-575.

Zur, G., White, S. D., 2011. Hyperadrenocorticism in 10 dogs with skin lesions as the only presenting clinical signs. *J. Am. Anim. Hosp. Assoc.* 47(6), 419-427.

# ORIGINAL PUBLICATIONS