

Bilateral scapulothoracic osteochondromas in a patient with hereditary multiple exostosis: a case report and review of the literature

Markus Rupp,^{1,2} Jendrik Harges,³
Michael J. Raschke,² Adrian Skwara⁴

¹Department of Trauma-, Hand- and Reconstructive Surgery, University Hospital Giessen and Harburg, Campus Giessen; ²Department of Trauma-, Hand- and Reconstructive Surgery, Muenster University Hospital; ³Clinic for General Orthopedics and Tumor Orthopedics, Muenster University Hospital; ⁴Orthopedic Practice, Borken, Germany

Abstract

Hereditary multiple exostosis (HME) is an autosomal dominant disorder characterized by two or more benign growing, cartilage capped tumors of long bones called osteochondromas. If abnormal growth and clinical symptoms of osteochondromas newly appear in adults, malignant transformation of the usually benign growing tumors should be suspected and diagnostic testing should be initiated. Against the background of hypothesized higher malignant transformation of osteochondromas into chondrosarcoma in individuals with shoulder exostoses, we report a case of bilateral scapulothoracic osteochondromas in a patient suffering from HME. A 60-year-old female with HME complained of chest pain while being hospitalized for bilateral femoral fractures. A computed tomography scan of the chest was performed to rule out pulmonary embolism. However, bilateral osteochondromas in the scapulothoracic spaces were detected. Due to absence of radiographic evidences for malignant transformation in the patient, invasive diagnostic procedures such as biopsy and histological examination were recommended in order to exclude malignant transformation of both osteochondromas. Physicians should be aware that patients with HME who present with shoulder pain should be examined for osteochondromas in the scapulothoracic space. Due to possible sarcomatous transformation, regular follow-ups are necessary for adolescents and adults.

Introduction

Hereditary multiple exostosis (HME) is a

rare disease. Since Boyer first described a family suffering from HME in 1814, epidemiological studies generate the prevalence of the orphan disorder affecting at least one in 50,000 people.^{1,4} Most often located in the proximal humerus, distal femur and proximal tibia, cartilaginary exostoses arise from metapysal regions of enchondral growing bones.^{2,5,6} Osteochondromas increase in size throughout childhood and stop growing when skeletal maturity is reached. Number and size of osteochondromas differ widely in individuals and families with known history of HME. While mean numbers of locations in individuals suffering from HME differ between 6 to 18, osteochondromas usually occur either pedunculated or are broad based around areas of active bone growth.^{2,6} Although osteochondromas are often clinically asymptomatic, symptoms like pain and orthopedic deformities *i.e.* differences in bone length, forearm deformities and varus-valgus malposition of the knee usually lead to the diagnosis of HME in the first decade of life.⁷ If growth and clinical symptoms of osteochondromas newly appear in adults, malignant transformation of the usually benign growing tumors should be suspected. In up to 8% the malignant degeneration to chondrosarcoma is described.⁸ Thus, regular monitoring and, if malignant tumor growth is diagnosed, surgical treatment of patients suffering from HME is necessary.^{8,9} Against the background of hypothesis that severely affected patients with HME are associated with palpable shoulder exostoses, we report for the first time a coincidentally found bilateral formation of osteochondromas in the scapulothoracic spaces in a patient suffering from HME.¹⁰ Hitherto, no case of bilateral osteochondromas arising from the scapula forming a scapulothoracic neojoint is described in the literature.

Case Report

A 60-year-old woman suffering from hereditary multiple exostosis was referred to our clinic with bilateral femoral shaft fractures after falling on ground out of a wheelchair. Due to an osteochondroma in the cervical spinal canal resulting in paraplegia of the lower extremities, the patient was already bound to the wheelchair for more than 20 years. Thus, sedentary osteoporosis of the 60-year-old lady most likely resulted in the bilateral femoral fracture after inadequate trauma in home environment. Besides suffering from a cervical spine osteochondroma resulting in paraplegia of the lower extremities, cartilaginary exostosis around both knees and the left proximal humerus were also reported. In 1976 a resection of the humeral cartilaginary exostosis was performed due to malignant transfor-

Correspondence: Markus Rupp, Department of Trauma-, Hand- and Reconstructive Surgery, University Hospital Giessen and Harburg, Campus Giessen, Rudolf-Buchheim-Straße 7 35392 Giessen, Germany.
Tel: +49.170.388.1487. E-mail: m_rupp@gmx.net

Key words: Osteochondroma; hereditary multiple exostosis; scapulothoracic pain; malignant transformation; mesenchymal tumor.

Contributions: MR and AS participated in the design, performance and interpretation of the present manuscript. In addition, they participated in drafting and revising the manuscript. Moreover, MR performed the patient education as well as the physical examination. JH and MJR provided administrative, technical and supervisory support. Furthermore, they participated in the interpretation and revising the manuscript.

Conflict of interest: the authors declare no potential conflict of interest.

Received for publication: 9 March 2016.

Revision received: 30 July 2016.

Accepted for publication: 31 July 2016.

This work is licensed under a Creative Commons Attribution NonCommercial 4.0 License (CC BY-NC 4.0).

©Copyright M. Rupp et al., 2016

Licensee PAGEPress, Italy

Orthopedic Reviews 2016;8:6501

doi:10.4081/or.2016.6501

mation. This resulted in the movement impairment of both, elevation and anteversion of the left upper extremity up to 90 degrees. The patient also had a positive family history sharing HME with her father and daughter.

After open reduction and internal plate fixation of both femoral fractures the patient was mobilized in our surgical ward. Weight bearing restrictions were imposed for 12 weeks postoperatively. To prevent thrombosis the current standard-of-care therapy with enoxaparin 40 mg per day was administered to the patient. During the postoperative treatment the patient showed typical symptoms of pulmonary embolism as described by Hunt and Bull.¹¹

As further diagnostics a computed tomography (CT) (Siemens Somatom Definition System, Siemens Medical Solutions, Forchheim, Germany) was performed. CT parameters were as follows: detector collimation 40×0.6 mm, pitch 1.3, rotation time 0.5 s, slice thickness 2 mm and tube voltage 120 kV. Online tube current modulation was employed to reduce patient dose. Despite of no evidence for pulmonary embolism, bilateral osteochondromas arising from both shoulder blades forming a neojoint in the scapulothoracic space were detected (Figures 1 and 2). Interestingly the patient also showed no signs of malignant growth. In addi-

tion, neither cortical destruction, moth-eaten and permeative osteolysis, nor endosteal scalloping was detected. After recognition of this rare finding, the upper extremity of the patient was examined in detail. Compared to normal anatomy a bilateral prominence was marginally visible, which was well palpable on both sides above the scapula body. Range of motion of the right shoulder was not impaired, whereas the movement of the left shoulder was impaired for more than 30 years as described above. Pressure pain or movement pain along with motor and sensible deficits were absent during physical examination. While hospitalized due to bilateral femoral fractures pain management and patient positioning were optimized thereby resulting in relief of the symptoms. In context with the detected bilateral scapulothoracic osteochondromas a magnet resonance imaging (MRI) scan was initiated, but could not be performed due to patient's claustrophobia. Further diagnostics such as biopsy of the bilateral tumors was recommended but refused by the patient as well.

Discussion

The existence of a variety of synonyms, in relation to the primarily benign tumor forming disease, indicates a diverse research interest. Multiple hereditary osteochondromas, multiple osteochondromatosis, multiple cartilaginous exostosis, multiple osteochondromatosis, familial exostosis and Bessel-Hagen disease are the most common.^{2,7} Although 200 years have elapsed since its first description as hereditary disease, the origin of HME was not discovered until the 1990s. Studies could show a lack of *EXT1* and *EXT2* genes causes HME.¹²⁻¹⁵ Later loss of function of the *EXT3* gene was also identified to be associated with multiple osteochondromatosis.¹⁶ Different kinds of *EXT1* and *EXT2* gene mutations were identified resulting in impaired heparan sulphate synthesis by lack of exostosin 1 and 2 proteins.^{13,17} Heparan sulphate proteoglycans (HSPG) are important mediators for growth factor binding to chondrocytes. Thus, biosyn-

thesis of HSPGs is in turn a regulatory process for signal cascades influencing differentiation and apoptosis of chondrocytes.^{18,19} Because development of HME mainly occurs due to lack of *EXT1*, *EXT2* or *EXT3* genes, *EXT* genes are designated as tumor suppressor genes.²⁰ However, up to 10-25% HME cases manifests in families without known history of HME caused by new mutations (*de novo* mutation). Moreover, manifestation of HME seems to be higher in males (male to female ratio: 1.5:1). Despite limited information to support *EXT* gene penetrance in female subjects, no difference in penetrance due to sex is described as well.^{1,2,7,20-22} While individuals with a mutation in the *EXT1* gene are reported to be more severely affected by HME, the manifestation of shoulder exostoses also seems to be more likely in these patients. In addition, malignant sarcomatous change seems to be most likely in patients suffering from palpable shoulder exostoses relative to any other anatomic site.¹⁰ Hence, beside its importance as diagnostic tool, clinical examination even has a prognos-

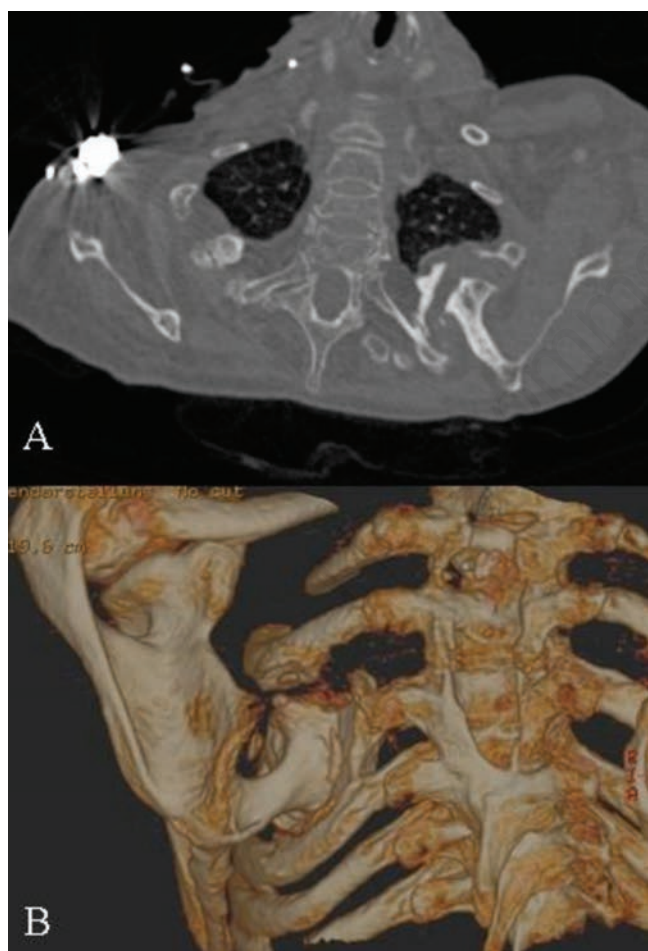


Figure 1. Axial (A) and 3D reconstructed (B) computed tomography scan. A and B show an osteochondroma rising from the left ventral scapula body forming a scapulothoracic neojoint.

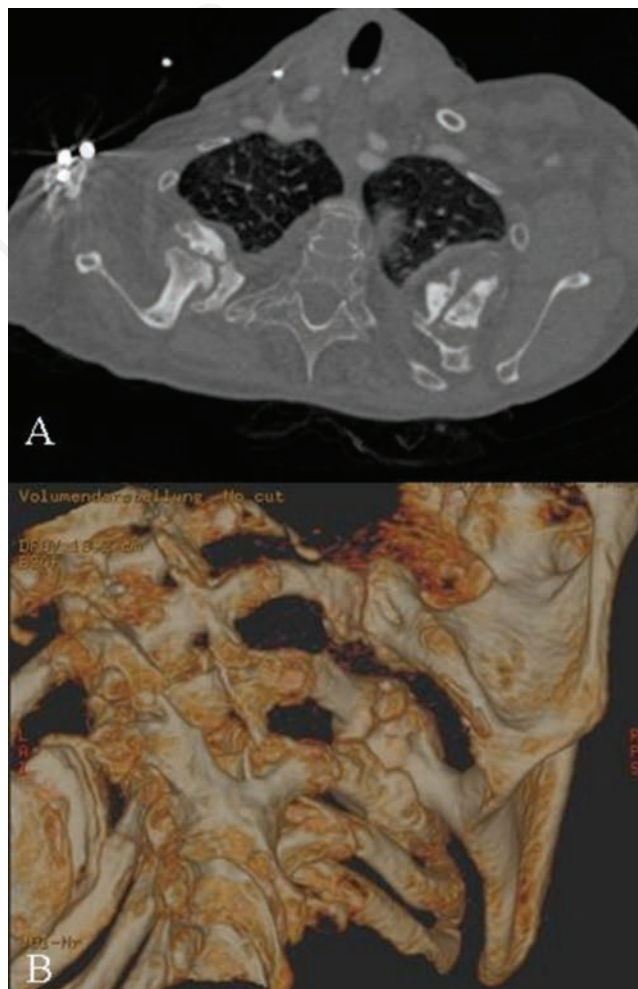

Figure 2. Axial (A) and 3D reconstructed (B) computed tomography scan showing an osteochondroma in the right scapulothoracic space.

Table 1. Studies reporting rare complications caused by chest wall osteochondromas.

Study	Year	N. patients	Age	Location	Symptom/complication
Twersky <i>et al.</i> ³³	1975	3	12 - 13 - 11	Vertebral - Costal	Spinal cord compression
Harrison <i>et al.</i> ³⁴	1994	1	36	Costal	Hemothorax
Simansky <i>et al.</i> ³⁵	1997	1	17	Costal	Diaphragm laceration
O'Brien <i>et al.</i> ³⁶	2011	1	12	Costal	Thoracic outlet syndrome
Imai <i>et al.</i> ³⁷	2014	1	16	Costal	Pneumothorax
Chen <i>et al.</i> ³⁸	2014	1	7	Costal	Pleural effusion, chest pain
Rodrigues <i>et al.</i> ³⁹	2015	1	18	Costal	ACS, coronary artery compression

ACS, acute coronary syndrome

tic relevance. Against this background it is not unexpected that the patient described above has a malignant sarcomatous transformation in her medical history.

Furthermore, the presented case shows the topographic occurrence of osteochondromas in patients suffering from HME. Cartilaginous exostoses are most likely located around the knee. The probability of involvement of the knee in affected individuals is described with 94%.² Besides location of osteochondromas close to the knee the cartilage capped bone tumors are most likely located in the proximal humerus (50%), proximal forearm (radius 38%, ulna 37%) and distal ulna (80%).^{5,23,24} The risk that a patient with HME has a spinal lesion is described with 27%.²⁵ Numerous case presentations of vertebral osteochondromas in children and adults suffering from HME result in cervical myelopathy thereby showing its clinical relevance.²⁶⁻³¹ Therefore a routinely performed spinal image screening of HME patients is recommended.^{26,32} Concerning shoulder exostoses, which are most likely associated with *EXT1* gene mutation, and thus predisposed for sarcomatous change are of special clinical interest, the reported prevalence ranges from 14 to 45%.^{2,5,10} Among the rare but severe complications caused by chest wall osteochondromas as described in the literature such as spontaneous hemothorax, pneumothorax, extrinsic coronary compression and spinal cord compression (Table 1),³³⁻³⁹ malignant transformation is the most feared situation for patients suffering from HME. According to the possible fateful diagnosis, a standardized clinical evaluation criteria should be met as it is usual for bone tumors in general.^{40,41} A standardized screening of patients suffering from HME is recommended. Besides taking patient's history and performing a detailed physical examination plain radiographs of areas that cannot be manually examined, *i.e.* the chest, pelvis and scapula, should be performed. If differences are seen in the regularly performed examinations, further imaging diagnostics like conventional radiographs should be carried out, followed by cross-sectional imaging techniques, such as CT and MRI. If the diagnosed tumor seems to be aggressive in growth in any case, a MRI

should be done to detect the dimension of the lesion before performing a biopsy by an orthopedic or surgical specialist. Often growth of the cartilage cap of an osteochondroma indicates malignant transformation. A millimeter thick cartilage normally caps the projecting bone. Although a strict cut-off in terms of thickness of the cartilaginous cap being pathognomonic of malignancy does not exist, a rare transformation of the normally benign tumor into an epixostotic chondrosarcoma should be suspected, if the cartilage cap is wider than 2 cm and has grown after adolescence.⁴²⁻⁴⁷ In case of confirmed malignancy, surgical resection of the tumor is necessary as far as possible. Following which confirmation of tumor free margins of the resected tissue has to be done by an experienced pathologist. En-bloc resection and confirmed complete margin-free resection show an excellent long-term clinical result.^{9,48} As a result of surgical resection due to sarcomatous change, pain, functional problems due to nerve and vessel compression, deformities or even early degenerative arthritis may require further orthopedic surgical therapy. For conservative treatment, in addition to the standardized pain management, use of bisphosphonates is considered to be helpful in management of refractory pain in patients suffering from HME.^{49,50} If conservative treatment is exhausted, depending on the anatomical site different operative strategies are discussed.^{23,51,52} In regard to shoulder exostoses different kinds of surgical techniques, open as well as endoscopic minimally invasive procedures, are described.^{46,53-55} Due to possible malignant transformation and limited non surgical treatment options in chondrosarcoma, endoscopic minimally invasive procedures should be regarded with a critical eye.

Conclusions

In summary, patients suffering from HME along with shoulder pain should remind examiners of osteochondromas for being the responsible cause for motion induced pain. The possibility of sarcomatous change should

be the reason for regular examinations of patients suffering from HME by specialists. Hitherto, surgical treatment is the appropriate measure in case of malignant degeneration and if necessary for refractory pain and functional impairment.

References

1. Bovee JV. Multiple osteochondromas. *Orphanet J Rare Dis* 2008;3:3.
2. Schmale GA, Conrad EU 3rd, Raskind WH. The natural history of hereditary multiple exostoses. *J Bone Joint Surg Am* 1994;76:986-92.
3. Boyer A. *Trait des maladies chirurgicales*. Paris: Ve Migneret; 1814.
4. Alba A, Carleton L, Dinkel L, et al. Increased lead levels in pregnancy among immigrant women. *J Midwifery Womens Health* 2012;57:509-14.
5. Shapiro F, Simon S, Glimcher MJ. Hereditary multiple exostoses. Anthropometric, roentgenographic, and clinical aspects. *J Bone Joint Surg Am* 1979;61:815-24.
6. Hennekam RC. Hereditary multiple exostoses. *J Med Genet* 1991;28:262-6.
7. Solomon L. Hereditary multiple exostosis. *Am J Hum Genet* 1964;16:351-63.
8. Jundt G, Baumhoer D. Hereditary bone tumors. *Pathologie*. 2010;31:471-6. [Article in German]
9. Hameetman L, Bovee JV, Taminiau AH, et al. Multiple osteochondromas: clinicopathological and genetic spectrum and suggestions for clinical management. *Hered Cancer Clin Pract* 2004;2:161-73.
10. Clement ND, Ng CE, Porter DE. Shoulder exostoses in hereditary multiple exostoses: probability of surgery and malignant change. *J Shoulder Elbow Surg* 2011;20:290-4.
11. Hunt JM, Bull TM. Clinical review of pulmonary embolism: diagnosis, prognosis, and treatment. *Med Clin North Am* 2011;95:1203-22.
12. Cook A, Raskind W, Blanton SH, et al. Genetic heterogeneity in families with

- hereditary multiple exostoses. *Am J Hum Genet* 1993;53:71-9.
13. Jennes I, de Jong D, Mees K, et al. Breakpoint characterization of large deletions in EXT1 or EXT2 in 10 multiple osteochondromas families. *BMC Med Genet* 2011;12:85.
 14. Ahn J, Ludecke HJ, Lindow S, et al. Cloning of the putative tumour suppressor gene for hereditary multiple exostoses (EXT1). *Nat Genet* 1995;11:137-43.
 15. Stickens D, Clines G, Burbee D, et al. The EXT2 multiple exostoses gene defines a family of putative tumour suppressor genes. *Nat Genet* 1996;14:25-32.
 16. Le Merrer M, Legeai-Mallet L, Jeannin PM, et al. A gene for hereditary multiple exostoses maps to chromosome 19p. *Hum Mol Genet* 1994;3:717-22.
 17. Pei Y, Wang Y, Huang W, et al. Novel mutations of EXT1 and EXT2 genes among families and sporadic cases with multiple exostoses. *Genet Test Mol Biomarkers* 2010;14:865-72.
 18. Hameetman L, David G, Yavas A, et al. Decreased EXT expression and intracellular accumulation of heparan sulphate proteoglycan in osteochondromas and peripheral chondrosarcomas. *J Pathol* 2007;211:399-409.
 19. McCormick C, Duncan G, Goutsos KT, et al. The putative tumor suppressors EXT1 and EXT2 form a stable complex that accumulates in the Golgi apparatus and catalyzes the synthesis of heparan sulfate. *Proc Natl Acad Sci USA* 2000;97:668-73.
 20. Heinritz W, Pretzsch M, Koall S, et al. Hereditary multiple exostoses. Molecular genetic analysis of the EXT1 gene in an unusual family. *Orthopade* 2005;34:470-6. [Article in German]
 21. Legeai-Mallet L, Munnich A, Maroteaux P, et al. Incomplete penetrance and expressivity skewing in hereditary multiple exostoses. *Clin Genet* 1997;52:12-6.
 22. Wicklund CL, Pauli RM, Johnston D, et al. Natural history study of hereditary multiple exostoses. *Am J Med Genet* 1995;55:43-6.
 23. Vogt B, Tretow HL, Daniilidis K, et al. Reconstruction of forearm deformity by distraction osteogenesis in children with relative shortening of the ulna due to multiple cartilaginous exostosis. *J Pediatr Orthop* 2011;31:393-401.
 24. Masada K, Tsuyuguchi Y, Kawai H, et al. Operations for forearm deformity caused by multiple osteochondromas. *J Bone Joint Surg Br* 1989;71:24-9.
 25. Roach JW, Klatt JW, Faulkner ND. Involvement of the spine in patients with multiple hereditary exostoses. *J Bone Joint Surg Am* 2009;91:1942-8.
 26. Roach JW. Hereditary multiple exostoses with spine involvement in a 4-year-old boy. *Am J Med Genet A* 2010;152A:1263.
 27. Burki V, So A, Aubry-Rozier B. Cervical myelopathy in hereditary multiple exostoses. *Joint Bone Spine* 2011;78:412-4.
 28. Tahasildar N, Sudesh P, Goni V, et al. Giant osteochondroma of axis in a child with multiple hereditary exostoses: case report and review of literature. *J Pediatr Orthop B* 2012;21:280-5.
 29. Patel A, Thacker MM. Cervical spinal canal compromise in a 14-year-old girl with hereditary multiple exostoses. *Pediatr Radiol* 2010;40:S158.
 30. Ezra N, Tetteh B, Diament M, et al. Hereditary multiple exostoses with spine involvement in a 4-year-old boy. *Am J Med Genet A* 2010;152A:1264-7.
 31. Giudicissi-Filho M, de Holanda CV, Borba LA, et al. Cervical spinal cord compression due to an osteochondroma in hereditary multiple exostosis: case report and review of the literature. *Surg Neurol* 2006;66:S7-S11.
 32. Aldea S, Bonneville F, Poirier J, et al. Acute spinal cord compression in hereditary multiple exostoses. *Acta Neurochir (Wien)* 2006;148:195-8.
 33. Twersky J, Kassner EG, Tenner MS, et al. Vertebral and costal osteochondromas causing spinal cord compression. *Am J Roentgenol Radium Ther Nucl Med* 1975;124:124-8.
 34. Harrison NK, Wilkinson J, O'Donohue J, et al. Osteochondroma of the rib: an unusual cause of haemothorax. *Thorax* 1994;49:618-9.
 35. Simansky DA, Paley M, Werczberger A, et al. Exostosis of a rib causing laceration of the diaphragm: diagnosis and management. *Ann Thorac Surg* 1997;63:856-7.
 36. O'Brien PJ, Ramasunder S, Cox MW. Venous thoracic outlet syndrome secondary to first rib osteochondroma in a pediatric patient. *J Vasc Surg* 2011;53:811-3.
 37. Imai K, Suga Y, Nagatsuka Y, et al. Pneumothorax caused by costal exostosis. *Ann Thorac Cardiovasc Surg* 2014;20:161-4.
 38. Chen J, Nelson S, Tzung B, et al. Costal osteochondroma spicule associated with pleural effusion. *Pediatr Surg Int* 2014;30:357-9.
 39. Rodrigues JC, Mathias HC, Lyen SM, et al. A novel cause of acute coronary syndrome due to dynamic extrinsic coronary artery compression by a rib exostosis: multimodality imaging diagnosis. *Can J Cardiol* 2015;31:1303.e9- e11.
 40. Balach T, Stacy GS, Peabody TD. The clinical evaluation of bone tumors. *Radiol Clin North Am* 2011;49:1079-93.
 41. Garcia RA, Inwards CY, Unni KK. Benign bone tumors—recent developments. *Semin Diagn Pathol* 2011;28:73-85.
 42. Bernard SA, Murphey MD, Flemming DJ, et al. Improved differentiation of benign osteochondromas from secondary chondrosarcomas with standardized measurement of cartilage cap at CT and MR imaging. *Radiology* 2010;255:857-65.
 43. Lin PP, Moussallem CD, Deavers MT. Secondary chondrosarcoma. *J Am Acad Orthop Surg* 2010;18:608-15.
 44. Jundt G, Baumhoer D. Cartilage tumors of the skeleton. *Pathologe* 2009;30:457-60. [Article in German]
 45. Brien EW, Mirra JM, Luck JV Jr. Benign and malignant cartilage tumors of bone and joint: their anatomic and theoretical basis with an emphasis on radiology, pathology and clinical biology. II. Juxtacortical cartilage tumors. *Skeletal Radiol* 1999;28:1-20.
 46. Soldatos T, McCarthy EF, Attar S, et al. Imaging features of chondrosarcoma. *J Comput Assist Tomogr* 2011;35:504-11.
 47. Parlier-Cuau C, Bousson V, Ogilvie CM, et al. When should we biopsy a solitary central cartilaginous tumor of long bones? Literature review and management proposal. *Eur J Radiol* 2011;77:6-12.
 48. Mavrogenis AF, Ruggieri P, Mercuri M, et al. Dedifferentiated chondrosarcoma revisited. *J Surg Orthop Adv* 2011;20:106-11.
 49. Winston MJ, Srivastava T, Jarka D, et al. Bisphosphonates for pain management in children with benign cartilage tumors. *Clin J Pain* 2012;28:268-72.
 50. World Health Organization. WHO's cancer pain ladder for adults. 2011. Available from: www.who.int/cancer/palliative/pain-ladder/en/.
 51. Rupprecht M, Spiro AS, Rueger JM, et al. Temporary screw epiphyseodesis of the distal tibia: a therapeutic option for ankle valgus in patients with hereditary multiple exostosis. *J Pediatr Orthop* 2011;31:89-94.
 52. Ofiram E, Eylon S, Porat S. Correction of knee and ankle valgus in hereditary multiple exostoses using the Ilizarov apparatus. *J Orthop Traumatol* 2008;9:11-5.
 53. Perez D, Ramon Cano J, Caballero J, et al. Minimally-invasive resection of a scapular osteochondroma. *Interact Cardiovasc Thorac Surg* 2011;13:468-70.
 54. Fukunaga S, Futani H, Yoshiya S. Endoscopically assisted resection of a scapular osteochondroma causing snapping scapula syndrome. *World J Surg Oncol* 2007;5:37.
 55. Frost NL, Parada SA, Manoso MW, et al. Scapular osteochondromas treated with surgical excision. *Orthopedics* 2010;33:804.