



Received: 2017.01.10
Accepted: 2017.02.10
Published: 2017.10.20

Authors' Contribution:

- A** Study Design
- B** Data Collection
- C** Statistical Analysis
- D** Data Interpretation
- E** Manuscript Preparation
- F** Literature Search
- G** Funds Collection

A Rare Case of Caudal Regression Syndrome in a Foetus of Non-Diabetic Mother: A Case Report

Gurnihal Singh Chawla^{ABE}, Purva Mahesh Agrawal^A, karanbir Singh Bajwa^A

Department of Radiology, NKP Salve Institute of Medical Sciences and Lata Mangeshkar Hospital, Nagpur, India

Author's address: Gurnihal Singh Chawla, Department of Radiology, NKP Salve Institute of Medical Sciences and Lata Mangeshkar Hospital, Nagpur, India, e-mail: gurnihal.chawla1@gmail.com

Summary

Background:

Caudal regression syndrome (CRS) is an uncommon disorder in which there is abnormal development of the caudal end of the foetal spine along with many associated anomalies. Manifestations of this syndrome can vary from the absence of a few terminal coccygeal segments to complete lumbosacral agenesis. Its overall incidence is 1 in 60000 live births. It is more commonly seen in infants of diabetic mothers, with a 200-fold increased risk as compared to the general population.

Case Report:

We present a case of CRS in a foetus of a non-diabetic mother and discuss the role of radiology in early diagnosis and timely management. We also correlate initial abnormalities of the nervous system found on imaging with postnatal clinical deficits.

Conclusions:

This case highlights the rarity caudal regression syndrome in a foetus of a non-diabetic mother. Early diagnosis of CRS is important for appropriate management.

MeSH Keywords:

Lumbosacral Region • Prenatal Diagnosis • Spinal Dysraphism • Diabetes Mellitus

PDF file:

<http://www.polradiol.com/abstract/index/idArt/903275>

Background

Caudal regression syndrome is an uncommon malformation with an overall incidence of 1 in 60,000 live births [1,2] However, it occurs more commonly in children of diabetic mothers, with a 200-fold increase in incidence [1]. CRS commonly arises around the 7th gestational week due to failure in formation of caudal elements of the embryo [3]. In this case report, many of the findings associated with CRS were observed on prenatal sonography and were confirmed on magnetic resonance imaging (MRI) [1]. Genetic defects are the most common aetiology in the pathogenesis of CRS, and they include mutations in the coding sequences of *HOXD13*, *CYP26A1*, and *HLXB9* genes [4]. Chromosomal abnormalities, hyperglycaemia, vascular hypoperfusion, and exposure to trimethoprim-sulfamethoxazole or minoxidil are other contributing factors [4].

Case Report

We present a case of a 25-year-old female, primigravida, who was referred for routine obstetric sonography from the department of gynaecology. The patient gave no history

of diabetes, asthma, hypertension, or any illicit drug use. The glucose test was within normal limits. No abnormalities were observed in routine laboratory examinations. The patient gave history of not taking folate tablets during the antenatal period.

Her first obstetric ultrasound (US) was abnormal and showed a singleton foetus of gestational age of 21 weeks, 0 days, with normal amniotic fluid volume. On axial sections, abrupt termination of the spine was noted just above the level of fundic bubble (Figure 1B). The ossific ring of the spinal canal was not visualized. On sagittal sections, the lumbosacral spine was not visualized (Figure 1C). However, CNS examination was within normal limits; posterior fossa structures were normal; there was no evidence of lemon or banana sign that are seen in cases of neural tube defects (spina bifida). No evidence of ventriculomegaly was noted (Figure 1D, 1E). On a Doppler examination, a single umbilical artery was found (Figure 1A). On MRI, these findings were confirmed (Figure 2A, 2B), and some additional findings were noted, such as flexion contractures of the hip and knee joints, giving "frog-like" appearance, and the presence of club feet (Figure 2E). The spinal cord was visualized and

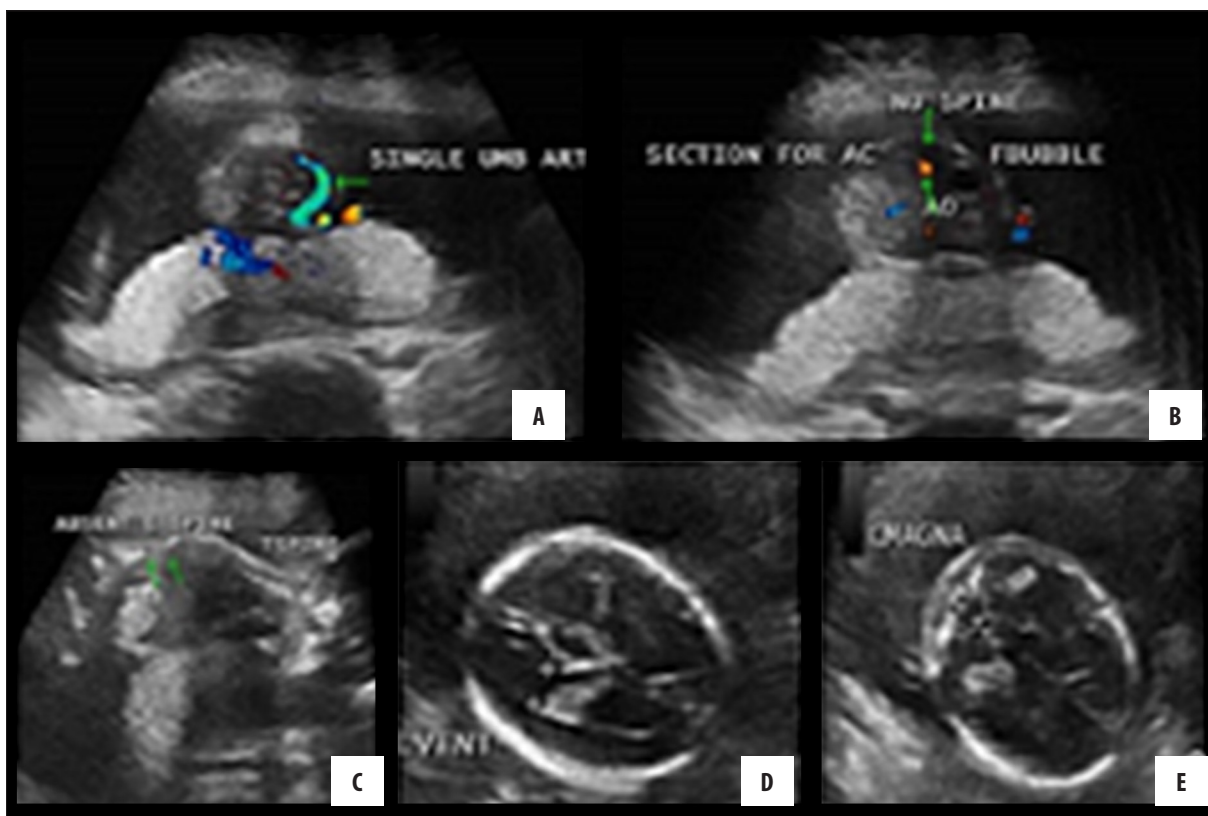


Figure 1. Doppler ultrasound images: (A) Axial section of the foetus showing single umbilical artery. (B) Axial section of the abdomen at the level of fundic bubble showing absence of the spine. (C) Sagittal section of the foetus showing absence of the lumbar and sacral spine. (D, E) Axial sections of the foetus showing normal left ventricle measuring 7.6 mm and normal cisterna magna measuring 5.5 mm.

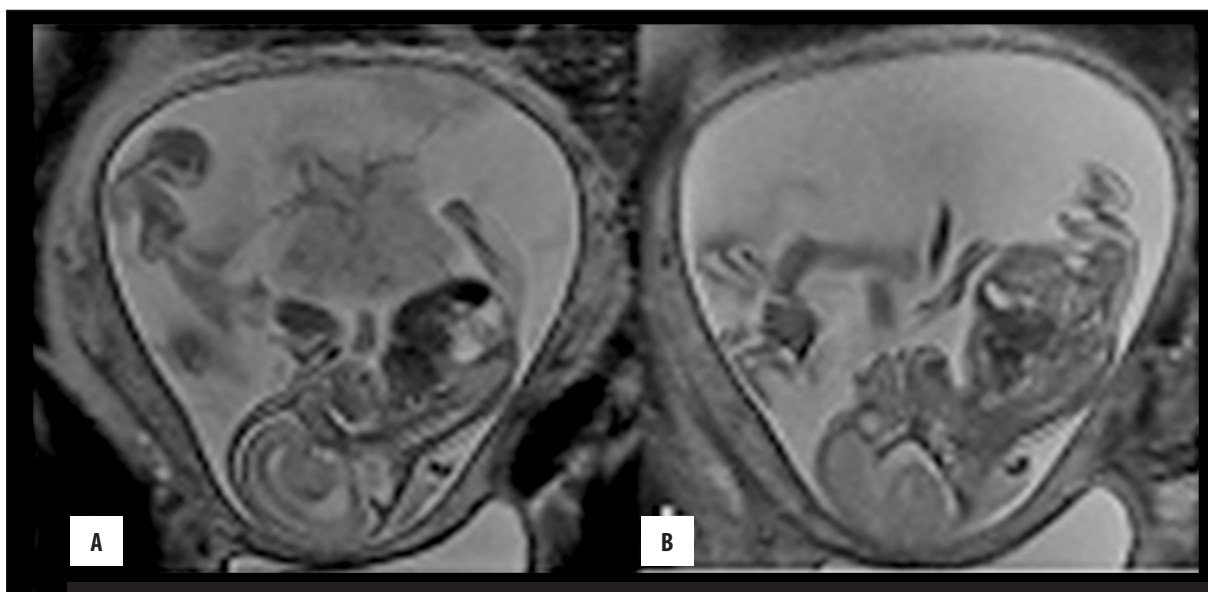
was seen terminating above the level of the fundic bubble (Figure 2C, 2D). The diagnosis of caudal regression syndrome was made.

Subsequently, the patient was informed about the disease and counselled accordingly. An elective termination of pregnancy was performed thereafter. A foetus weighing 650 grams was delivered without any complications

(Figure 3). The autopsy findings were in line with the pre-natal imaging findings, thereby confirming the diagnosis of caudal regression syndrome.

Discussion

Caudal regression syndrome is a rare disorder with an incidence of 1: 60,000 live births [2,5]. It consists of



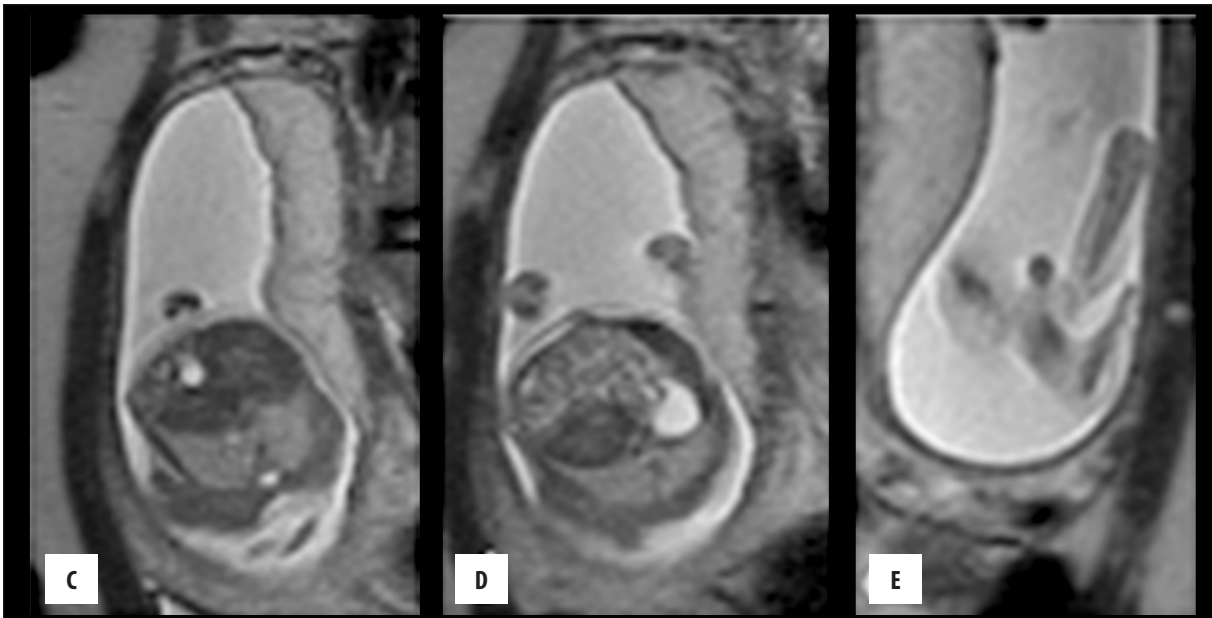


Figure 2. Foetal T2WI MRI (non-contrast images): (A, B) Sagittal sections of the foetus showing abrupt termination of the spinal cord and absence of the lumbosacral spine. (C, D) Axial sections of the foetal abdomen showing abrupt termination of the spine at the level of the stomach bubble. (E) Section of the foetal limbs showing clubbed feet.

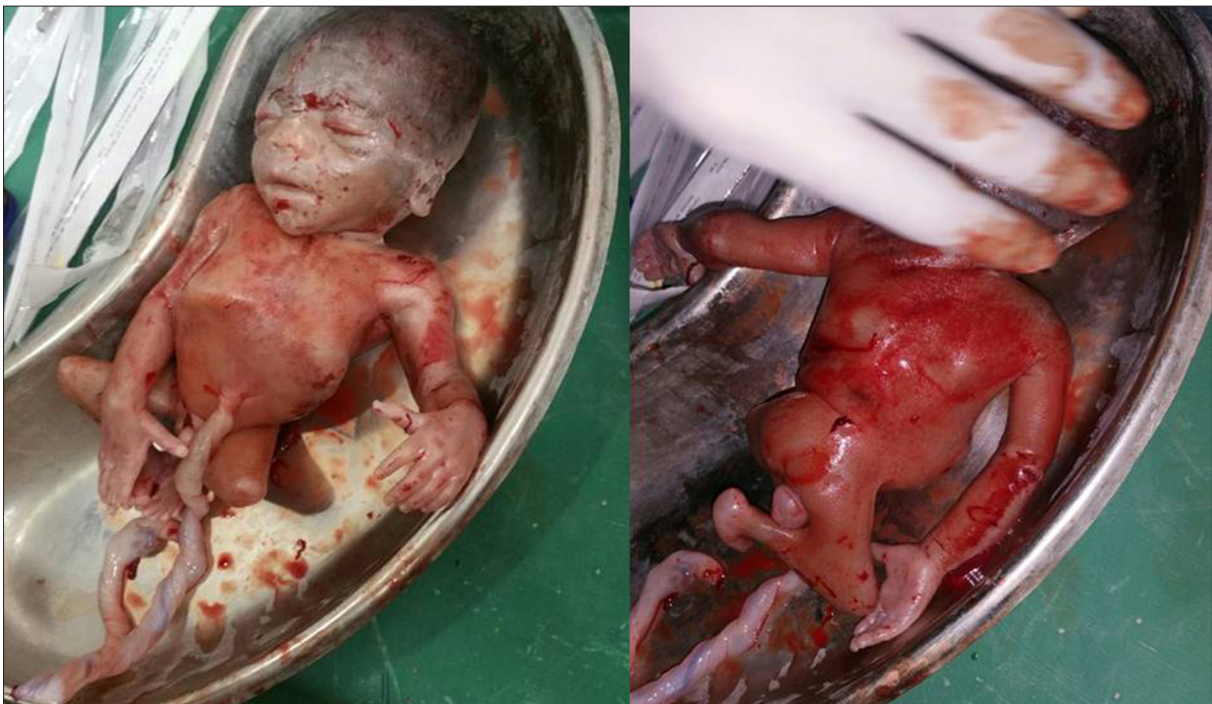

Figure 3. Clinical picture of the delivered foetus confirming the imaging findings

developmental anomalies of the caudal vertebrae, lower limbs, digestive and urogenital organs, and it causes significant neural tube defects. The severity of this syndrome varies from the absence of the coccyx to the involvement of sacrum or complete lumbosacral agenesis. Other anomalies associated with this syndrome are orthopaedic, anorectal (imperforate anus), vertebral, genitourinary (bladder exstrophy), and cardiopulmonary. Other anomalies include the VACTERL syndrome (anomalies of vertebrae, anus, cardiovascular system, tracheoesophageal fistula, renal agenesis,

and involvement of limb buds) [2]. In our case, orthopaedic complications were also found, including flexion contractures of lower extremities and club feet [3]. Caudal regression syndrome is a consequence of an embryologic defect occurring at the midposterior axial mesoderm, which results in the induction of the syndrome before the fourth gestational week [3,5]. Abnormalities in the *HLBX9* homeobox gene on chromosome 7q36 are implicated in CRS. The same gene is also expressed in the pancreas, which might result in co-occurrence of CRS and diabetic hyperglycaemia

Table 1. Renshaw classified.

S. No.	Type	Characteristic features
1.	Type I	Total or partial unilateral sacral agenesis
2.	Type II	Partial/complete lumbar and total sacral agenesis; the iliac blades joining with lateral aspects of the lowest vertebra
3.	Type III	Partial/complete lumbar and total sacral agenesis associated with fuse ilia; or iliac amphiarthrosis acting as a base for caudal end of the most distal vertebra
4.	Type IV	Soft tissues of the lower limbs are fused
5.	Type V	Sirenomelia associated with single femur and single tibia

[2]. Notably, CRS occurs more commonly in infants of diabetic mothers, with an increased risk of about one in 350, representing a 300-fold increase in incidence as compared to the general population [3]. In our case the mother was non-diabetic.

Renshaw classified the spectrum of caudal regression syndrome into five types [1,6] (Table 1).

Sirenomelia is usually associated with absent anus and fewer leg bones, and it presents with oligohydroamniotic fluid which hinders the diagnosis in the third trimester [3]. In such cases, MRI is a useful tool in making the correct diagnosis.

CRS can also be diagnosed in the first trimester based on the short crown-rump length [1]; however, the definitive diagnosis is usually made in the second trimester. Detailed evaluation of the foetal spine and lower extremities is very important in making timely diagnosis and administering appropriate management [3]. In our case, the abnormality was detected at 21 weeks of pregnancy and therefore timely termination of pregnancy was possible.

The major differential diagnoses of CRS are segmental spinal dysgenesis (SSD) and body-wall complex with caudal defects. The latter disease includes bladder exstrophy, spinal dysraphism, omphalocele, and sacral myelomeningocele [3].

Both caudal regression syndrome and SSD involve segmental malformations of the spine and spinal cord, thereby representing two aspects of a single spectrum. The extent of spinal involvement correlates with neuroradiologic findings, clinical severity, and residual cord function [3]. It is difficult to differentiate SSD and caudal regression syndrome based solely on radiological findings [3].

Conclusions

The present case highlights the rarity of caudal regression syndrome in a foetus of a non-diabetic mother. Early diagnosis of CRS is important, and the radiologist is often the first to suggest an in utero diagnosis. Ultrasound is a useful tool for early diagnosis of caudal regression syndrome, particularly in patients with normal amniotic fluid. MRI can give a definitive diagnosis independent of the amniotic fluid volume. Familiarity with the range of findings in different imaging modalities is critical for timely prenatal counselling, appropriate management, and effective post-natal treatment.

Conflict of interest

The authors declare that they have no conflict of interest relevant to the publication of this article.

References:

- Sen KK, Patel M: Caudal regression syndrome. *Medical Journal Armed Forces India*, 2007; 63(2): 178-79
- Knight B: Caudal regression syndrome: A case report. *AANA Journal*, 2011; 79(4): 281-82
- Aslan H, Yanik H, Celikaskan N et al: Prenatal diagnosis of caudal regression syndrome: A case report. *BMC Pregnancy Childbirth*, 2001; 1(1): 8
- Negrete LM, Chung M, Carr SR, Tung GA: In utero diagnosis of caudal regression syndrome. *Radiol Case Rep*, 2015; 10(1): 1049
- Temizkan O, Abike F, Ayvaci H et al: Prenatal diagnosed caudal regression syndrome. *Open Journal of Obstetrics and Gynecology*, 2013; 3(02): 227
- Renshaw TS: *Sacral agenesis. The pediatric spine – principles and practice*. New York: Raven Press, 1994; 1: 2214