

Evaluation of the biological tolerability of the starch-based medical device 4DryField[®] PH *in vitro* and *in vivo* a rat model

Daniel Poehnert¹, Mahmoud Abbas², Lavinia Maegel², Franziska Sambale³, Antonina Lavrentieva³, Hans-Heinrich Kreipe², Jürgen Klempnauer¹ and Markus Winny¹

Abstract

Purpose: To evaluate *in vitro* cytotoxicity/biocompatibility as well as *in vivo* tolerability of the novel polysaccharide 4DryField[®] PH, certified for haemostasis and adhesion prevention.

Methods: *In vitro* cytotoxicity/viability testing according to ISO EN 10,993 using murine and human tumour cell lines incubated with 4DryField[®] PH (PlantTec Medical GmbH). Using a rat model the impact of 4DryField[®] PH on animals viability and *in vivo* effects were macro- and micropathologically assessed.

Results: *In vitro* testing revealed no cytotoxic effect of 4DryField[®] PH nor enhancement of viability to tumour cell lines. *In vivo* viability of rats was unimpaired by 4DryField[®] PH. Bodyweight loss in animals with abdominal injury plus treatment with 4DryField[®] PH was in the range of controls and less than in injured rats without treatment. At day 7 after surgery no formation of adhesions, neither macroscopic nor histological remnants nor signs of foreign body reaction were present in animals without injury. In animals with peritoneal injury and 4DryField[®] PH application, histopathological observation revealed minor residuals of polysaccharide in the depth of wound cavity embedded in a thickened subperitoneal layer; however, with a suggested intact neoperitoneum. The presence of mononuclear cells surrounding polysaccharide particles in varying states of degradation was observable as well.

Conclusion: 4DryField[®] PH is not cytotoxic and does not enhance viability of tumour cell lines. High dose of 4DryField[®] PH of 1.09 g/kg bodyweight is well tolerated and reduces weight loss in animals with peritoneal injury. The biocompatibility of 4DryField[®] PH can be rated as being excellent.

Keywords

4DryField[®] PH, polysaccharide, haemostatic agent, adhesion prevention agent, biocompatibility, cytotoxicity, rat model

Introduction

If conventional measures for haemostasis like compression, cautery and suturing are not applicable or successful, other techniques such as the use of topical haemostats have to be taken into consideration.¹ Most of these are cellulose-based or derived from mammalian and/or human components. They exert their effect in various ways like primary improvement of haemostasis, stimulation of fibrin formation or providing pro-coagulant substances on vehicles such as collagen.¹ The use of modified starch particles for haemostasis is a relatively recent addition to the haemostatic arsenal. Applied as powder to bleeding

areas, polysaccharide particles absorb water from the wound blood resulting in concentration of plasmatic fibrinogen and accelerating the natural blood clotting process.^{2–4} In a situation of diffuse bleeding, a larger

¹Department of General, Abdominal and Transplantation Surgery, Hannover Medical School, Germany

²Department of Pathology, Hannover Medical School, Germany

³Institute of Technical Chemistry, Leibniz University Hannover, Germany

Corresponding author:

Daniel Poehnert, Department of General, Abdominal and Transplant Surgery, Hannover Medical School, Carl-Neuberg-Straße 1, D-30625 Hannover, Germany.

Email: poehnert.daniel@mh-hannover.de

quantity of haemostatic agent might be of necessity, raising the question of biocompatibility of those agents.

Adhesions can be a result of previous surgery. They might lead to considerable patient morbidity and are a mounting burden for surgeons, patients and the health care system.⁵⁻⁷ Prophylaxis of adhesions including the use of biodegradable agents gains more and more awareness.^{7,8} Extensive abdominal and pelvic surgery including operations for symptomatic adhesions can result in large peritoneal defects necessitating large quantities of adhesion prevention agents. Again the question of biocompatibility arises.

The novel agent 4DryField® PH (PlantTec Medical GmbH, Bad Bevensen, Germany) is certified for haemostasis and adhesion prevention, both actions based on its excellent capability to absorb water. A study investigating the haemostatic effect of 4DryField® PH revealed that blood clots formed in the presence of 4DryField® PH have the same physical properties like genuine clots even if there is 50% haemodilution by a relative increase of coagulation factors by water absorption.³ With respect to adhesion prevention it was shown that a gel formed from 4DryField® PH is highly effective as a barrier against adhesion formation.^{9,10}

This study investigates the biocompatibility of 4DryField® PH. With *in vitro* testing on murine and human cells, a potential cytotoxic effect of 4DryField® PH is analysed. For the *in vivo* testing a previously described rat model is used.^{10,11} Biocompatibility is assessed with viability scoring, course of bodyweight and macroscopic and histopathological investigations.

Materials and methods

In vitro cytotoxicity tests

To evaluate the impact of 4DryField® PH on cell growth and viability, two assays were performed.

The MTS assay is a standard procedure to estimate the viability of mammalian cell cultures. In the conducted assay a CellTiter 96 Aqueous One Solution Cell Proliferation Assay kit (Promega, USA) was used. For viability testing murine fibrosarcoma L929 cells were cultivated in 96-well plates in Roswell Park Memorial Institute (RPMI) 1640 cell culture medium with 10% fetal calf serum. The metabolic rate was standardised to background signals of culture medium without cells (blank). As control, negative (aged cell culture medium), not cytotoxic (reference material in accordance with ISO 10993-12) and cytotoxic (reference material in accordance with ISO 10993-12) controls were conducted. The mean viability score of the negative control was defined as 100% viability. Eight replicates were performed for each sample. In the assay,

4DryField® PH was applied to the culture medium as an extract prepared as followed:

In accordance with ISO EN 10,993-12-2009, a material to extraction ratio of 0.2 g/mL was used plus additional 15 mL absorption volume per 1 g 4DryField® PH. Therefore, 1 g 4DryField® PH per 20 mL RPMI 1640 cell culture medium with 10% fetal calf serum (0.05 g/mL) was used and the solution was incubated for 24 h at 37°C, 5% CO₂ and 92% humidity. After this procedure, the saturated 4DryField® PH solution was centrifuged and the resulting supernatant was termed '100% extract'. Dilutions of the extract were prepared with RPMI medium and incubated for 24 h at 37°C. According to ISO EN 10,993-5, cytotoxicity should be considered where the viability value falls below 70% of the negative control. Viability results obtained with 4DryField® PH referred to negative controls.

To evaluate the impact of 4DryField® PH powder on the viability of human cells using a standard Cell Titer 96® Non-Radioactive Cell Proliferation Assay (Promega, Germany), 4DryField® PH was applied as a powder directly on the surface of A549 cells. A standardised MTT assay was performed. Human A549 cells were grown in 24-well or 96-well plates in concentrations of 40,000–15,000 cells per plate in RPMI cell culture medium. Before 4DryField® PH application, a 24–72 h cell adhesion and recovery phase was carried out, followed by the evaluation of cell viability after 24 h of 4DryField® PH exposition. 4DryField® PH was added as a powder directly to adherent A549 cells in concentrations varying from 0.001–15 mg/mL 4DryField® PH per total culture medium. Each concentration was tested as triplicate. Viability scores refer to controls without 4DryField® PH powder in culture medium as 100% viability.

In vivo testing for 4DryField® PH tolerability

Preoperative preparation. To assess the tolerability of 4DryField® PH *in vivo*, male Lewis rats were used in this study. All protocols were conducted in accordance with animal protection laws. Animal experiments were performed at Zentrales Tierlabor of Hannover Medical School (MHH, Hanover, Germany), providing the knowledge (housing, caretaking, etc.) to assure life quality of laboratory animals. The Lower Saxony State Office for Consumer Protection and Food Safety (LAVES) approved this study. Rats had continuous access to fresh water and were fed *ad libitum*. Animals' welfare was assessed by monitoring of bodyweight and behavioural changes with the use of a standard observation chart (body condition scoring, GV-SOLAS, Charité-Universitätsmedizin Berlin) (Table 1).

Table 1. Viability scheme covering days 1–7 after surgery according to GV-SOLAS.

Grade	Quality	Criteria
1	Agile, active	Typical fast movement, curiosity, feed and water intake
2	Active	Typical movement, rarely persistent, normal feed and water intake
3	Limited active	Reaction to environmental stimulus, frequent persistence, limited feed and water intake (loss of weight < 20%)
4	Retarded	Sleepiness, retarded movement and reaction, excessive limited feed and water intake (loss of weight > 20%)
5	Lethargical	No activity, no reaction, no feed and water intake

Surgical procedure. General anaesthesia was achieved by intraperitoneal injection of 80 mg/kg bodyweight Ketamine and 5 mg/kg Xylazine. The required level of narcosis for surgery was reached if flexor reflexes failed to appear. The abdomen was shaved and disinfected. A 3 cm median laparotomy was performed to gain access to the abdominal cavity. After treatment according to grouping (see Test groups), the abdomen was closed using a two-layer closure technique and a consecutive suture. All animals were sacrificed at trial day 7 by carbon dioxide narcosis followed by cervical dislocation. The peritoneal cavity was re-entered via an incision remote to the former laparotomy scar. The abdominal cavity was thoroughly explored and healing of provoked abdominal injuries was evaluated. Sample material of the cecum and abdominal wall for histological assessment was taken according to a standard protocol.

Postoperative management. After surgery, animals were monitored until complete awakening and kept warm with an infrared lamp. Concerning expectable postoperative pain in the postoperative period, animals received Novalminulfon (non-recurring subcutaneously after surgery with 200 mg/kg bodyweight and continuously by mixing 1 g in 500 mL drinking water).

Test groups. Prior to the surgical intervention, rats were separated into four groups: 10 animals received only laparotomy and closing of the abdomen (group 1). These animals were used as controls to assess the impact of surgical procedure on animal behaviour and weight course. Additional eight rats received 300 mg of 4DryField® PH in the lower right abdomen in addition to the laparotomy (group 2). Group 2 was used to evaluate the impact and safety of 4DryField® PH given into the unimpaired abdomen. In addition, the effect of 4DryField® PH on animals with a severe abdominal lesion and its subsequent healing process was analysed. In both lesion groups (groups 3 and 4), abrasion of the cecum and a wound in the opposite abdominal wall were created to simulate bleeding and to form trauma areas. Therefore, the cecum was treated

with a gauze swab to remove visceral peritoneum and provoke capillary bleeding in an area of 1 × 2 cm. Additionally, an about 1 × 2 cm sized patch of parietal peritoneum with its underlying inner muscular layer was resected off the right abdominal wall lateral to the midline laparotomy. Of those treated, 15 rats served as control to evaluate regular wound healing and bodyweight courses (group 3). Another 14 rats were treated in the same manner followed by application of 300 mg of 4DryField® PH (group 4). 4DryField® PH powder was given in the area of injury (group 4) or rather in the right lower abdominal quadrant (group 2). All animals received 1.5 ml saline solution 0.9% in the peritoneal cavity at the end of surgery. If 4DryField® PH was applied, this procedure was used to transform the starch powder into a gel.

Evaluation parameters. Animals' constitution was subjected to daily routine observations and was scored according to GV-SOLAS (Table 1). Bodyweight was determined at trial day 0 (before surgical procedure) and at least on trial day 7. Upon autopsy at postoperative day 7, the abdominal cavity in general, as well as the areas of cecum and the abdominal sidewall in particular, were macroscopically evaluated and searched for polysaccharide remnants.

Histology. Specimen for histological examinations were collected from all animals to evaluate whether 4DryField® PH had an impact on unimpaired tissue and wound healing and to investigate 4DryField® PH degradation characteristics. Samples were excised en bloc and fixed in 4% formaldehyde solution. After processing, specimens were embedded in paraffin blocks. Serial sections were stained with haematoxylin and eosin or Alcian blue and PAS stain kit (Sigma-Aldrich, St. Louis, USA), respectively, and visualised by light microscopy. 4DryField® PH polysaccharide remnants were detected by PAS staining (blue/purple colour of polysaccharides). Both, the macroscopic and the histopathological observers were blinded to the study.

Statistical analysis. Statistical analyses of bodyweight courses were performed using GraphPad PRISM software for a two-way multi-comparison ANOVA corrected for multiple comparison with Turkeys post-hoc test. Significance levels were set as $p < 0.05$.

Results

In vitro cytotoxicity assays

Two different *in vitro* cytotoxicity assays were conducted to reveal 4DryField® PH impact on cell viability. On L929 cells the 100% 4DryField® PH extract resulted in a mean viability score of $86.5 \pm 4.8\%$ in the used MTS assay. Extract dilutions of 50%, 25% and 12.5% revealed viability scores of $103.7 \pm 5.4\%$, $100 \pm 6.9\%$ and $99.1 \pm 6.7\%$, respectively. These results indicated no cytotoxicity of 4DryField® PH extract (Table 2).

Table 2. Median, mean and standard deviation of murine tumour cell line L929 viability after incubation for 24 h with 4DryField® PH-RPMI extract in different concentrations.

Concentration of extract (%)	Median	Mean value \pm standard deviation	Result
100	86.6	86.5 ± 4.8	Not cytotoxic
50	104.1	103.7 ± 5.4	Not cytotoxic
25	99.5	100.0 ± 6.9	Not cytotoxic
12.5	99.2	99.1 ± 6.7	Not cytotoxic

Varying amounts of 4DryField® PH powder were applied directly on the surface of adherent A549 cells to analyse cell viability of human cells in direct contact with 4DryField® PH powder. Figure 1 shows testing of different amounts of 4DryField® PH powder in culture medium and its subsequent influence on cell viability referring to a control without 4DryField® PH. 4DryField® PH amounts ranging from 0.001 to 15 mg/mL 4DryField® PH were applied, resulting in viability scores between 111% and 72% with a mean cell viability of $87.8 \pm 15.5\%$.

Thus, *in vitro* testing of 4DryField® PH when administered to tumour cell lines in an extract form or a powder showed neither cytotoxic nor beneficial effects on tumour cell viability.

In vivo 4DryField® PH tolerability

On the first day after surgery, all rats were graded with a GV-SOLAS viability score of 1 and/or 2 (Table 1). Throughout the remaining study all animals were graded with a viability score of 1 (Table 3), meaning that neither the surgical procedure nor the 4DryField® PH application did sustainably influence animals' viability.

Surgery was performed without complications, and due to a plain postoperative course no animal had to be sacrificed or died during the course of investigations. Table 4 summarises the animal grouping and preoperative bodyweight. All rats of groups 2 and 4 received the same amount of 4DryField® PH (300 mg). Preoperative

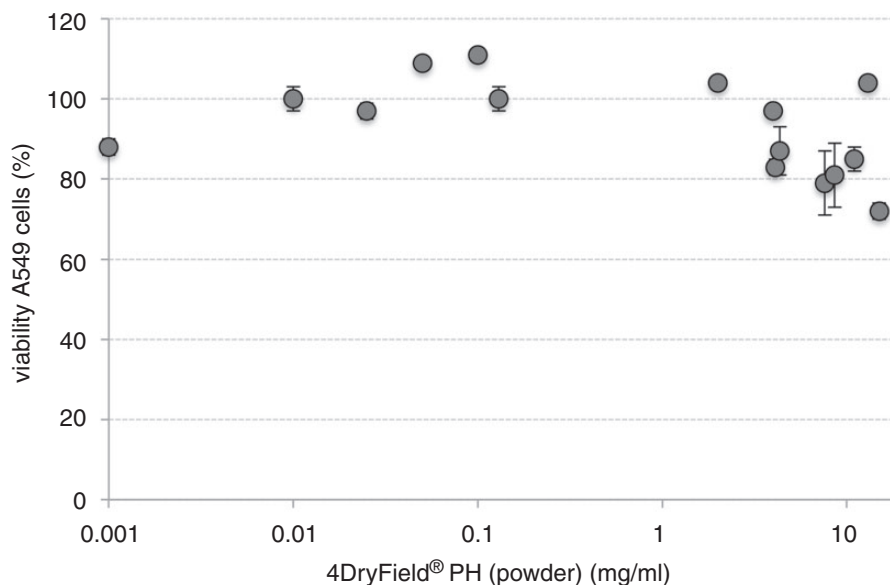


Figure 1. Influence of varying amounts of 4DryField® PH powder on cell viability of human tumour cell line A549 in a standardised MTT assay after incubation for 24 h.

bodyweight of these animals was in a range of 276–431 g. Hence, the amount of 4DryField® PH given varied from 0.7 to 1.09 g 4DryField® PH/kg bodyweight.

The average bodyweight loss of all rats was $4.6 \pm 3.8\%$ one week after surgery (Table 5). Weight loss was most pronounced in animals with cecal abrasion and abdominal wall defect but without 4DryField® PH treatment (group 3, mean weight loss 23 g; 7.2%) (Figure 2). In contrast, in group 1 mean weight loss was 10 g (2.9%), 14 g (3.4%) in group 2 and 14 g (3.7%) in group 4. Interestingly, the animals with surgical lesions and 4DryField® PH treatment (group 4) revealed a course of bodyweight similar to groups 1 and 2 without lesions (Figure 2). Statistical analyses showed a significant difference between animals of group 1 and group 3

with increased weight loss in group 3 ($p=0.04$). Additionally, group 3 showed a significantly increased weight loss compared to animals of group 4 ($p=0.04$).

By defining bodyweight depending cohorts (Table 6) mean values of 0.72–1.06 g 4DryField® PH / kg bodyweight were applied. The amount of 4DryField® PH administered seemed to have no adverse effect on the course of viability and bodyweight, even when applied in a concentration of 1.09 g/kg. Furthermore, 4DryField® PH exhibited a beneficial effect on course of bodyweight in animals with severe surgical injury (group 4).

Macroscopic inspection of the abdominal cavity of animals with sole laparotomy (group 1) appeared inconspicuous. In particular, 4DryField® PH-treated animals (group 2) showed no distinctive features, e.g. polysaccharide remnants, signs of dehydration or foreign body reactions. Rats with cecal abrasion and an abdominal wall defect (group 3) showed massive adhesions as a result of injured peritoneal tissue. In contrast, animals with additional 4DryField® PH treatment of group 4 had a normal abdominal cavity and apparently no adhesions, revealing an anti-adhesive effect of 4DryField® PH in injured peritoneal areas. Here the zones of surgical injury had regained a shiny surface, appearing like healthy mesothelium. In the area of the abdominal wall defect, some zones appeared whitish (so called Winny effect, named after its discoverer).

Histopathological assessment of 4DryField® PH impact on tissue structure is visualised in a representative animal of group 2 in Figure 3(c) and (d). The overall impression of cecum and abdominal wall tissue structure and layering appeared normal as compared to animals of group 1 (Figure 3(a) and (b)). Besides few accumulations of mononuclear cells in some regions of submesothelial layer of the abdominal wall the administration of 4DryField® PH in the healthy abdominal cavity revealed no abnormalities (Figure 3(d)).

In rats of group 3, the abdominal and cecal wall tissue layers were agglutinated with fibrous tissue sections and, thus, did not show normal tissue layering or

Table 3. Postoperative viability scoring of animals.

Group	Mean viability grade		n
	Day 1	Day 7	
(1) Control	1.1	1.0	10
(2) 4DryField® PH	1.1	1.0	8
(3) Control lesion	1.0	1.0	15
(4) 4DryField® PH lesion	1.2	1.0	14

Table 4. Preoperative bodyweight data of complete cohort of rats.

Group	Weight (g)	Mean weight (g)	4DF / BW ^a
(1) Control	327–361	343 ± 11	
(2) 4DryField® PH	393–431	409 ± 13	0.73 ± 0.02
(3) Control lesion	270–358	321 ± 29	
(4) 4DryField® PH lesion	276–423	358 ± 59	0.86 ± 0.15

^aMean amount of 4DryField® PH (4DF) in gram per kilogram bodyweight (BW).

Table 5. Comparison of pre- and postoperative bodyweight.

Group	Mean bodyweight (g)			Δ	(% Weight loss)
	Day 0	Day 7			
(1) Control	343 ± 11	333 ± 11		10 ± 7	2.9 ± 2.1
(2) 4DryField® PH	409 ± 13	395 ± 17		14 ± 6	3.4 ± 1.4
(3) Control lesion	321 ± 29	297 ± 30		23 ± 17	7.2 ± 5.6
(4) 4DryField® PH lesion	358 ± 59	344 ± 54		14 ± 7	3.7 ± 1.6
All rats	351 ± 47	335 ± 48		16 ± 12	4.6 ± 3.8

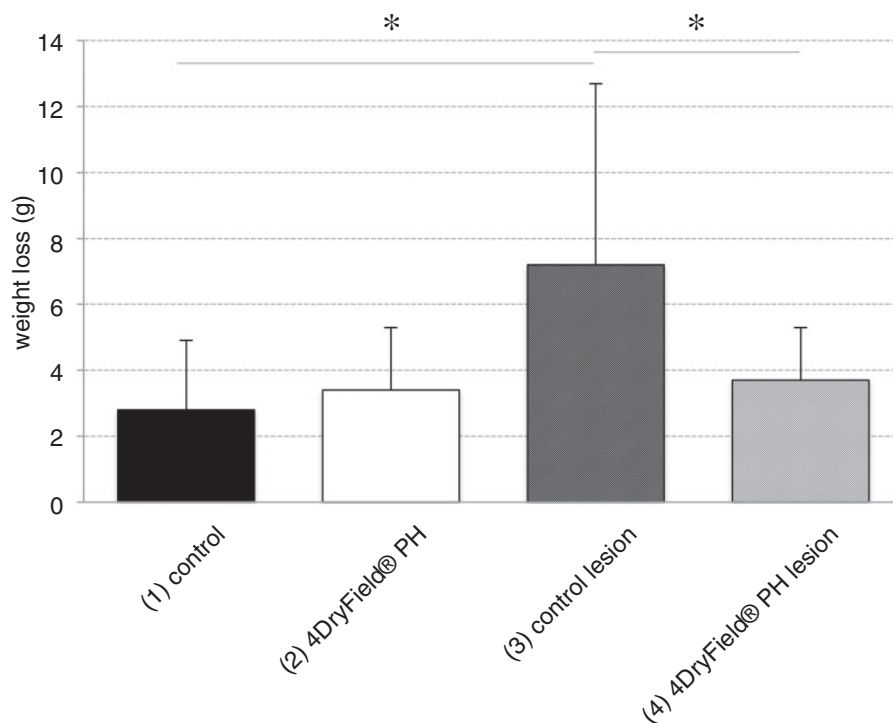


Figure 2. Relative bodyweight loss and standard deviation of animals with sole laparotomy without (group 1, control) and with 4DryField® PH treatment (group 2, 4DryField® PH) and weight loss of animals with cecal abrasion and abdominal wall defect (group 3, control lesion) and with 4DryField® PH treatment (group 4, 4DryField® PH lesion).

Table 6. Influence of 300 mg 4DryField® PH given intraperitoneally on animal viability and weight loss in different weight cohorts.

Weight cohorts	n	Mean weight (g) d0	Weight loss (%) d0–d7	4DF / BW ^a
250–300	4	284.5 ± 9.5	–2.9 ± 1.8	1.06 ± 0.04
301–350	3	330.6 ± 13.7	–2.8 ± 0.5	0.91 ± 0.04
351–400	4	392.8 ± 6	–4 ± 1.7	0.76 ± 0.01
401–450	11	415.8 ± 7.4	–3.9 ± 1.5	0.72 ± 0.02

^aMean amount of 4DryField® PH (4DF) in gram per kilogram bodyweight (BW).

functionality (Figure 3(e) and (f)). 4DryField® PH-treated animals of group 4 revealed a normal tissue layering (despite of the surgical muscular defect) with separated abdominal wall and intestine. The former lesion areas showed a thickening of submesothelial layers (Figure 3(g) and (h)) as an indicator of active healing processes. Interestingly, the visceral and parietal peritoneum seemed to be reconstituted.

In higher magnification of healed abdominal wall lesion areas of group 4, a few isolated polysaccharide particles could be found in varying levels of degradation (Figure 4). Figure 4(a) and (b) shows a single remnant particle, surrounded and invaded by mononuclear cells. After complete absorption of

4DryField® PH particles, normal granulating tissue was seen (Figure 4(c)).

Discussion

Several topical haemostatic agents are currently available exerting their effect in improving primary haemostasis, stimulating fibrin formation or inhibiting fibrinolysis.¹ Oxidised cellulose or oxidised regenerated cellulose have been used as haemostats for decades and are still substantially present on the market.¹ As plant-based agents, they are quite well biocompatible bearing a low risk of allergic reactions or transferal of diseases caused by foreign proteins and/or blood born

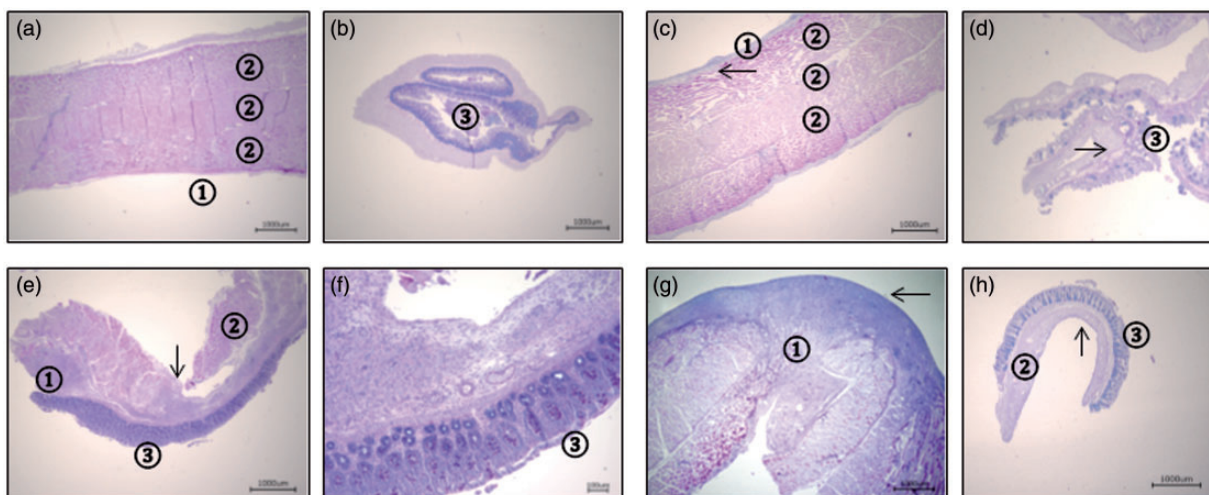


Figure 3. Representative Alcian blue stained histologies of cecal and abdominal wall biopsies seven days after 4DryField® PH application in rat abdomen of a representative animal of group 1 (a, b), group 2 (c, d), group 3 (e, f) or group 4 (g, h), respectively. Pictures (a) and (b) demonstrate normal abdominal wall (①: peritoneum, ②: intact muscle layers) and cecal anatomy (③: cecal mucosa). (c and d) Abdominal wall and cecum after laparotomy and application of 4DryField® PH showed normal peritoneum ①, muscle layers ② and cecal mucosa ③. After application of 4DryField® PH abdominal wall and cecum showed an accumulation of mononuclear cells in the subperitoneal space (arrow), otherwise no pathological features were seen. (e, f) demonstrate a high level adhesion after creation of an abdominal wall defect (①: mononuclear cells as a sign of inflammation due to healing processes, ②: defect in abdominal wall muscle layers, ③: cecal mucosa). (g) Abdominal wall after creating an abdominal wall defect (① defect in muscle layer) and treatment with 4DryField® PH seemed to have an intact neoperitoneum (arrow) with slightly enlarged subperitoneal granulating tissue. (h) Cecal wall after peritoneal abrasion and treatment with 4DryField® PH showed normal cecal mucosa and submucosa ③. The intact neoperitoneum (arrow) had an enlarged subperitoneal fibrous tissue with infiltrating mononuclear cell ②.

pathogens. However, they have a degradation time of about 3–4 weeks.¹ If left in the body in significant amounts, they can be the focus of severe adverse events including adhesion formation.^{1,12–16} Their appearance as granulomata leads to the suggestion that degradation time might even be longer than weeks.¹⁷

Since 1970, mammalian derived products mostly based on bovine, porcine, or other domestic animal albumin, collagen or gelatin have been used.^{1,18,19} These agents are often combined with human agents like thrombin, fibrinogen or other coagulation factors. Despite improved technologies of screening, transfer of diseases can still not be ruled out completely.¹

Mammalian-based products can be the basis of allergy and immunologic reaction²⁰ and transient granulomatous inflammation of variable intensity.^{17,21} Degradation times of 3–4 weeks and longer for collagen- and gelatin-based haemostats implies the patients' metabolism being faced with foreign proteins for a substantial period of time. The property of cellulose- and mammalian-based agents to induce granuloma formation has been shown in an experimental comparative study.¹⁷ If haemostats include components like glutaraldehyde, degradation time can be massively prolonged; in spinal surgery this type of haemostat has been reported to persist for 2 years.²²

Current polysaccharide-based haemostatic agents act by their capability to absorb water leading to a relative enrichment of coagulation factors. They have a short retention time in the body^{1,17} and, thus, exhibit a low risk to cause a granulomatous reaction.¹⁷

A non-pharmacological approach to prevent adhesions is the use of temporary or permanent barriers to separate the injured tissue from the surrounding organs throughout the critical time for adhesion formation during peritoneal healing.⁵ Since post-surgical regeneration of the peritoneum occurs within days,²³ a timely degradation or excretion of devices is desirable to decrease the risk of an immunological response or foreign body reaction.

4DryField® PH is a new device being certified for both, haemostasis and adhesion prevention.^{3,9,10} In case of diffuse bleeding or extensive peritoneal defects, higher amounts of 4DryField® PH (exceeding one surgical unit at 5 g powder) might be indicated and the question of biocompatibility arises.

Cytotoxicity tests of 4DryField® PH indicate that even in the pure extract there is only a slight decrease of cell viability far from the level of cytotoxicity (defined as 70% baseline level) according to the European and US American regulatory administrations. On the other hand and importantly, viability was not elevated in direct contact and/or extract

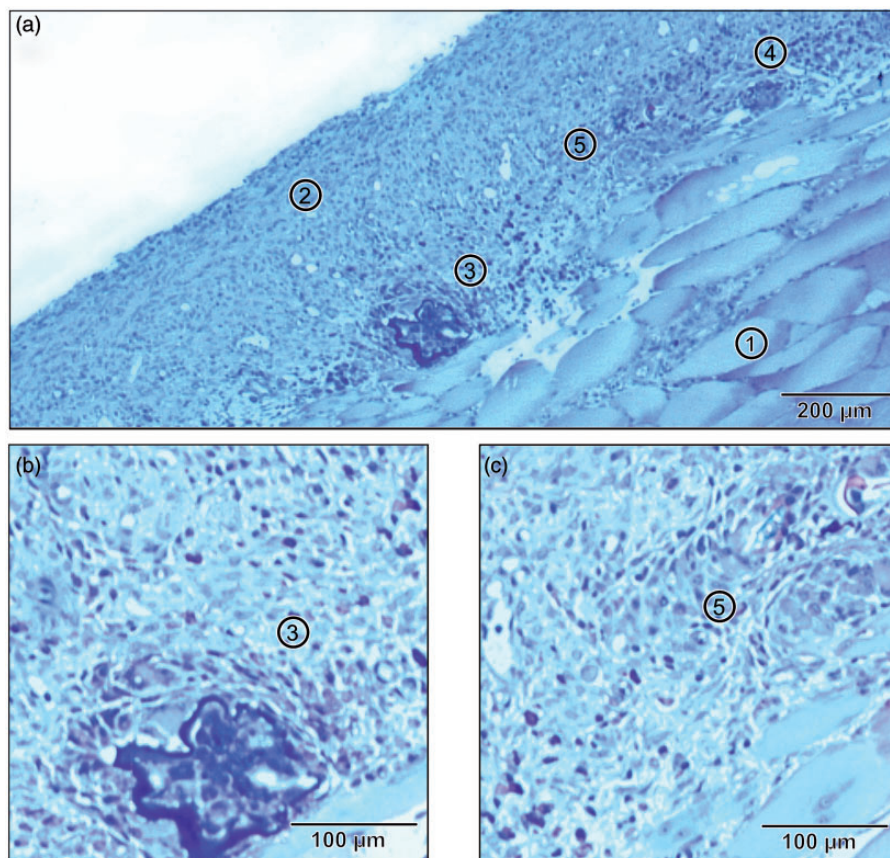


Figure 4. Histology of mesothelial site of abdominal wall at day 7 after creation of a multilayer abdominal wall defect and 4DryField[®] PH application in a representative animal of group 4 (Alcian blue and PAS staining). The peritoneal wall was already healed with a continuous neoperitoneum. (a) Overview with ① skeletal muscle of abdominal wall, ② inner surface of the abdominal wall with intact neoperitoneum and an enlarged submesothelial layer; ③, ④ and ⑤ show different stages of degradation of polysaccharide particles. (b) Higher magnification of residual polysaccharide particle ③, which is surrounded by mononuclear cells. (c) Higher magnification of resolving groups of mononuclear cells after degradation of polysaccharide particles ⑤.

dilutions which indicates that tumour derived cell lines from sarcoma and adenocarcinoma do not profit from the presence of 4DryField[®] PH. By this 4DryField[®] PH as powder or gel can be considered in tumour surgery.

Application of 4DryField[®] PH to peritoneal cavity of rats revealed that the polysaccharide powder did not induce adverse events, including adhesion formation. Since no remnants of 4DryField[®] PH could be found micro- and macroscopically in rats with unimpaired abdomen, it can be assumed that 4DryField[®] PH gel disperses on the intact peritoneum; some accumulation of mononuclear cells subperitoneally indicate that degradation processes might occur there.

Interestingly, animals with abdominal injury by cecal abrasion combined with a multi-layer abdominal wall defect and 4DryField[®] PH treatment had a course of bodyweight comparable to animals with only laparotomy. In contrast, rats with abdominal lesion and without 4DryField[®] PH treatment revealed a significant increased loss of bodyweight, suggesting that

4DryField[®] PH gel given on the injured area might enhance recovery.

The few 4DryField[®] PH remnants in the area of the former peritoneal wall defect are the result of a combined effect: 4DryField[®] PH was given there into a deep wound and trapped additionally by the suture fixed cecum, resulting in a local enrichment. Overall, the amount of 4DryField[®] PH found 7 days after surgery can be judged minor with only few single particles left surrounded by mononuclear cells. This indicates that 4DryField[®] PH is degraded within days even if large quantities are locally present. Overall, the data show that 4DryField[®] PH in amounts of 0.7–1.09 g/kg bodyweight is well tolerated and contributes to favourable peritoneal healing.

Conclusion

In vitro cytotoxicity testing indicates that 4DryField[®] PH is not cytotoxic and that on the other hand human

and murine tumour cell lines do not profit from the presence of 4DryField® PH. The *in vivo* studies in rats with unimpaired abdomen show that doses of up to 1.09 g/kg bodyweight of 4DryField® PH are well tolerated and are mainly degraded within days. 4DryField® PH has no negative impact on animals' general wellbeing nor on normal peritoneal tissue. Animals with abdominal injury do gain a benefit from the application of 4DryField® PH by showing reduced adhesion formation and a favourable course of bodyweight. The biocompatibility of 4DryField® PH can be rated excellent.

Acknowledgements

The authors thank Anneke Loos and Eveline Sowa-Söhle, Biocompatibility Laboratory, BioMedimplant, Hanover Medical School for technical assistance and their critical review of this work.

Declaration of Conflicting Interests

The author(s) declared no potential conflicts of interest with respect to the research, authorship, and/or publication of this article.

Funding

The author(s) received no financial support for the research, authorship, and/or publication of this article.

References

- Syednejad H, Imani M, Jamieson T, et al. Topical haemostatic agents. *Br J Surg* 2008; 95: 1197–1225.
- Robinson K. Controlling bleeding in the field: Hemostatic powders and dressings debut in the prehospital setting. *J Emerg Nurs* 2004; 30: 160–161.
- Hanke AA, Flöricke F, Sieg L, et al. Effects of a new microporous polysaccharide powder on viscoelastic characteristics of clot formation. In: *American society of anesthesiologists annual meeting*, Chicago, 2011.
- Bjorses K and Holst J. Various local hemostatic agents with different modes of action; an *in vivo* comparative randomized vascular surgical experimental study. *Eur J Vasc Endovasc* 2007; 33: 363–370.
- Hirschelmann A, Tchartchian G, Wallwiener M, et al. A review of the problematic adhesion prophylaxis in gynaecological surgery. *Arch Gynecol Obstet* 2012; 285: 1089–1097.
- Menzies D and Ellis H. Intestinal obstruction from adhesions-how big is the problem? *Ann R Coll Surg Engl* 1990; 72: 60–63.
- Ray NF, Denton WG, Thamer M, et al. Abdominal adhesiolysis: Inpatient care and expenditures in the United States in 1994. *J Am Coll Surg* 1998; 186: 1–9.
- Kamel RM. Prevention of postoperative peritoneal adhesions. *Eur J Obstet Gynecol Reprod Biol* 2010; 150: 111–118.
- Korell M. Combined hemostasis and adhesion prevention with the novel agent 4DryField® PH—Initial observations. *Surg Sci* 2014; 5: 533–539.
- Pöhnert D, Abbas M, Kreipe HH, et al. Marked reduction of peritoneal adhesion formation in rat model of cecal abrasion by a novel anti-adhesive agent, 4DryField® PH. In: Jähne J (ed.) *131st Congress of the German society for surgery*, Berlin, Germany, 2014, pp. 371–413.
- Pöhnert D, Abbas M, Kreipe HH, et al. High reproducibility of adhesion formation in rat with meso-stich approximation of injured cecum and abdominal wall. *Int J Med Sci* 2015; 12: 1–6.
- Gao HW, Lin CK, Yu CP, et al. Oxidized cellulose (Surgicel (TM)) granuloma mimicking a primary ovarian tumour. *Int J Gynecol Pathol* 2002; 21: 422–423.
- Henry MCW, Tashjian DB, Kasowski H, et al. Postoperative paraplegia secondary to the use of oxidized cellulose (Surgicel). *J Pediatr Surg* 2005; 40: E9–E13.
- Ibrahim MF, Aps C and Young CP. A foreign body reaction to Surgicel® mimicking an abscess following cardiac surgery. *Eur J Cardio-Thorac* 2002; 22: 489–490.
- Iwabuchi S, Koike K, Okabe T, et al. Iatrogenic paraplegia caused by Surgicel used for hemostasis during a thoracotomy: Report of a case. *Surg Today* 1997; 27: 969–970.
- Sandhu GS, ElempuruCamiruaga JA and Buckley S. Oxidized cellulose (Surgicel®) granulomata mimicking tumour recurrence. *Br J Neurosurg* 1996; 10: 617–619.
- Ereth MH, Schaff M, Ericson EE, et al. Comparative safety and efficacy of topical hemostatic agents in a rat neurosurgical model. *Neurosurgery* 2008; 63: 369–372.
- Schonauer C, Tessitore E, Barbagallo G, et al. The use of local agents: Bone wax, gelatin, collagen, oxidized cellulose. *Eur Spine J* 2004; 13: S89–S96.
- Zwischenberger JB, Brunton RL, Swann JR, et al. Comparison of two topical collagen-based hemostatic sponges during cardiothoracic procedures. *J Invest Surg* 1999; 12: 101–106.
- Rothwell SW, Sawyer E, Dorsey J, et al. Wound healing and the immune response in swine treated with a hemostatic bandage composed of salmon thrombin and fibrinogen. *J Mater Sci Mater Med* 2009; 20: 2155–2166.
- Barbolt TA, Odin M, Leger M, et al. Pre-clinical subdural tissue reaction and absorption study of absorbable hemostatic devices. *Neurol Res* 2001; 23: 537–542.
- Yuen T and Kaye AH. Persistence of Bioglue® in spinal dural repair. *J Clin Neurosci* 2005; 12: 100–101.
- diZerega GS and Campeau JD. Peritoneal repair and post-surgical adhesion formation. *Hum Reprod Update* 2001; 7: 547–555.